

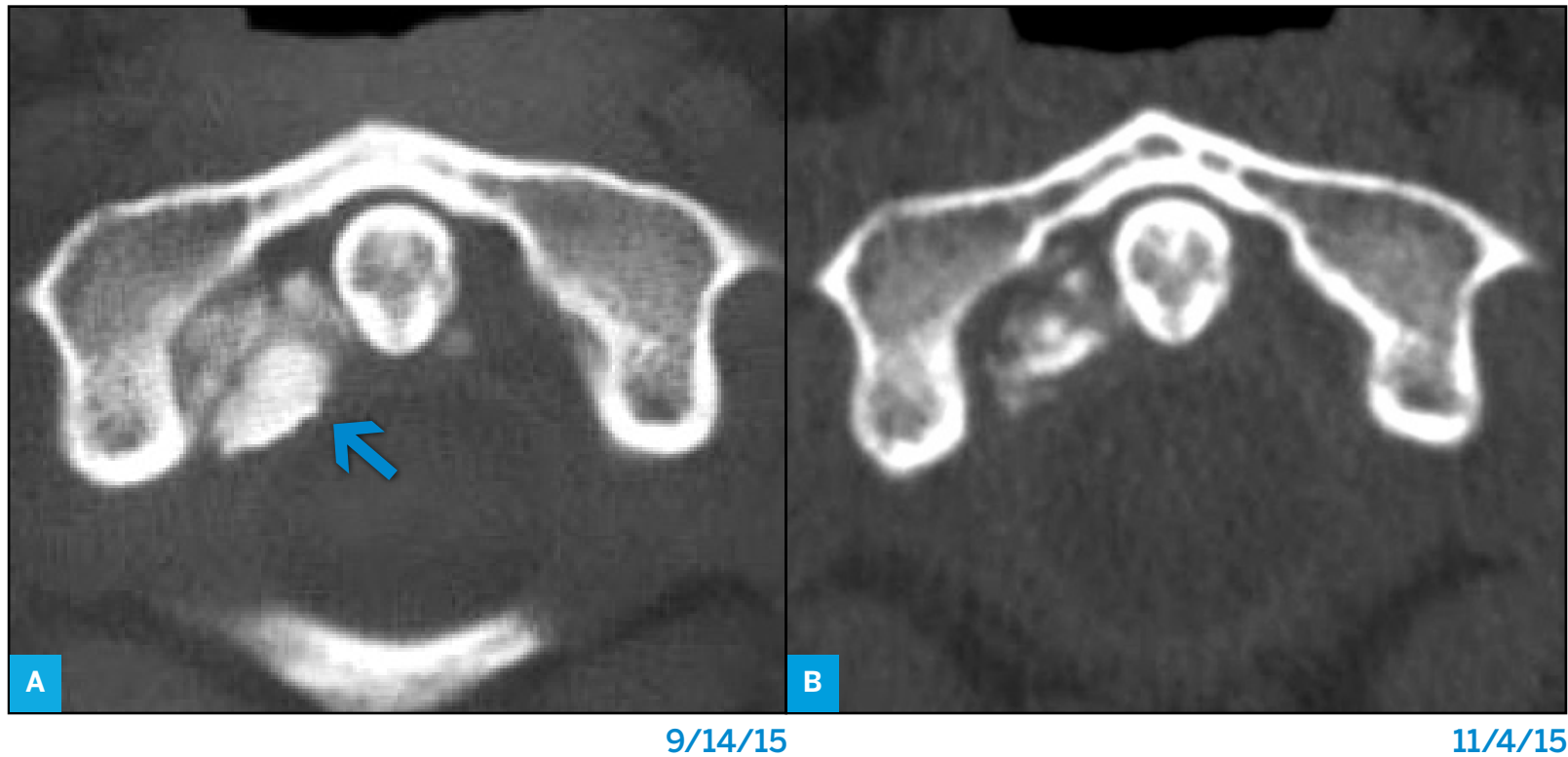Figure 1: Lateral (a), and extension (b) cervical spine X-rays demonstrating fixed cervical kyphosis measuring 77 and 74 degrees respectively. Anterior-posterior x-ray (c) shows fixed rotatory occipital cervical deformity.

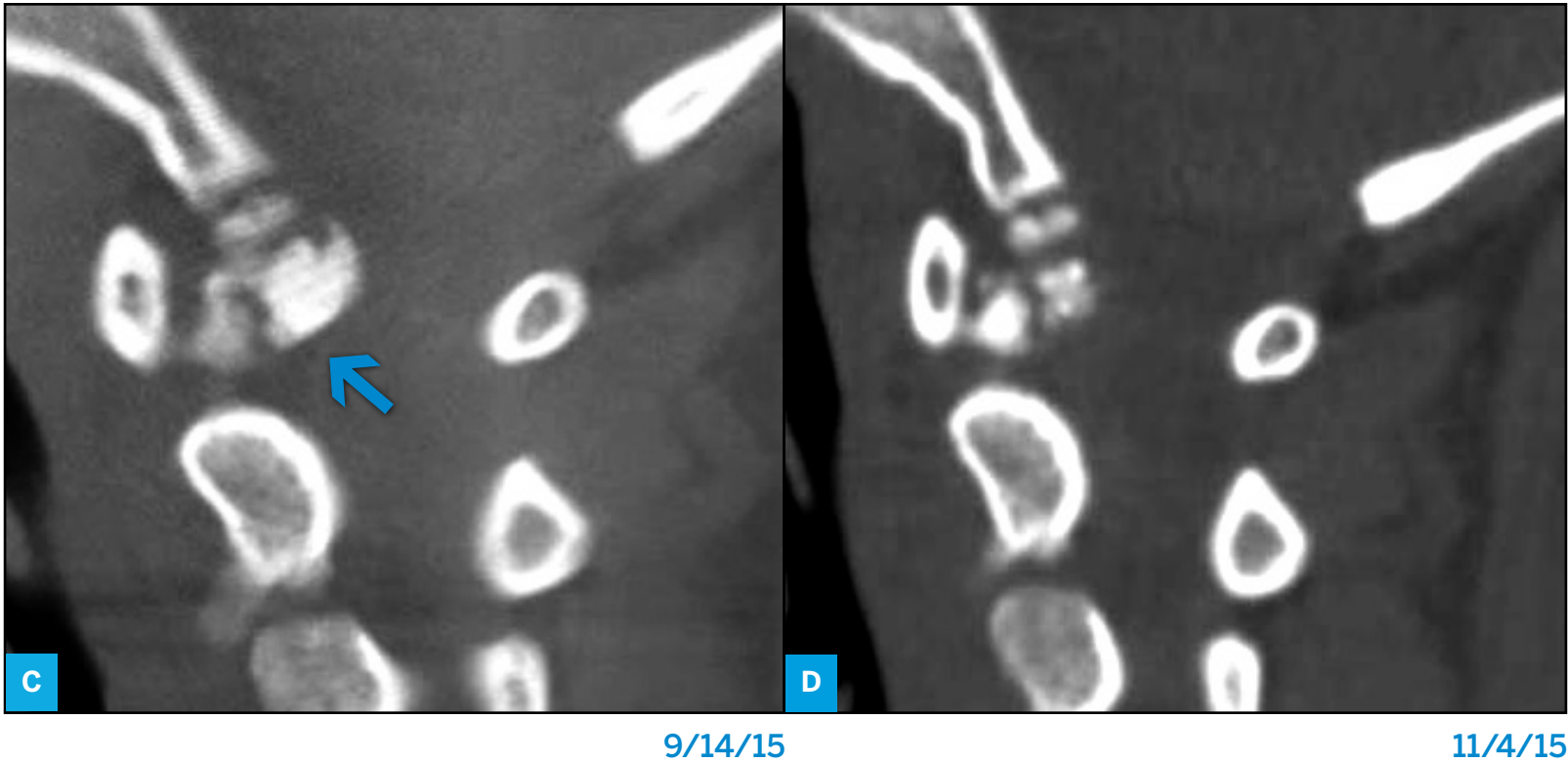

Figure 2: Sagittal view at baseline (C) and 2 months later (D) showing fragmentation and partial dissolution of the mass.

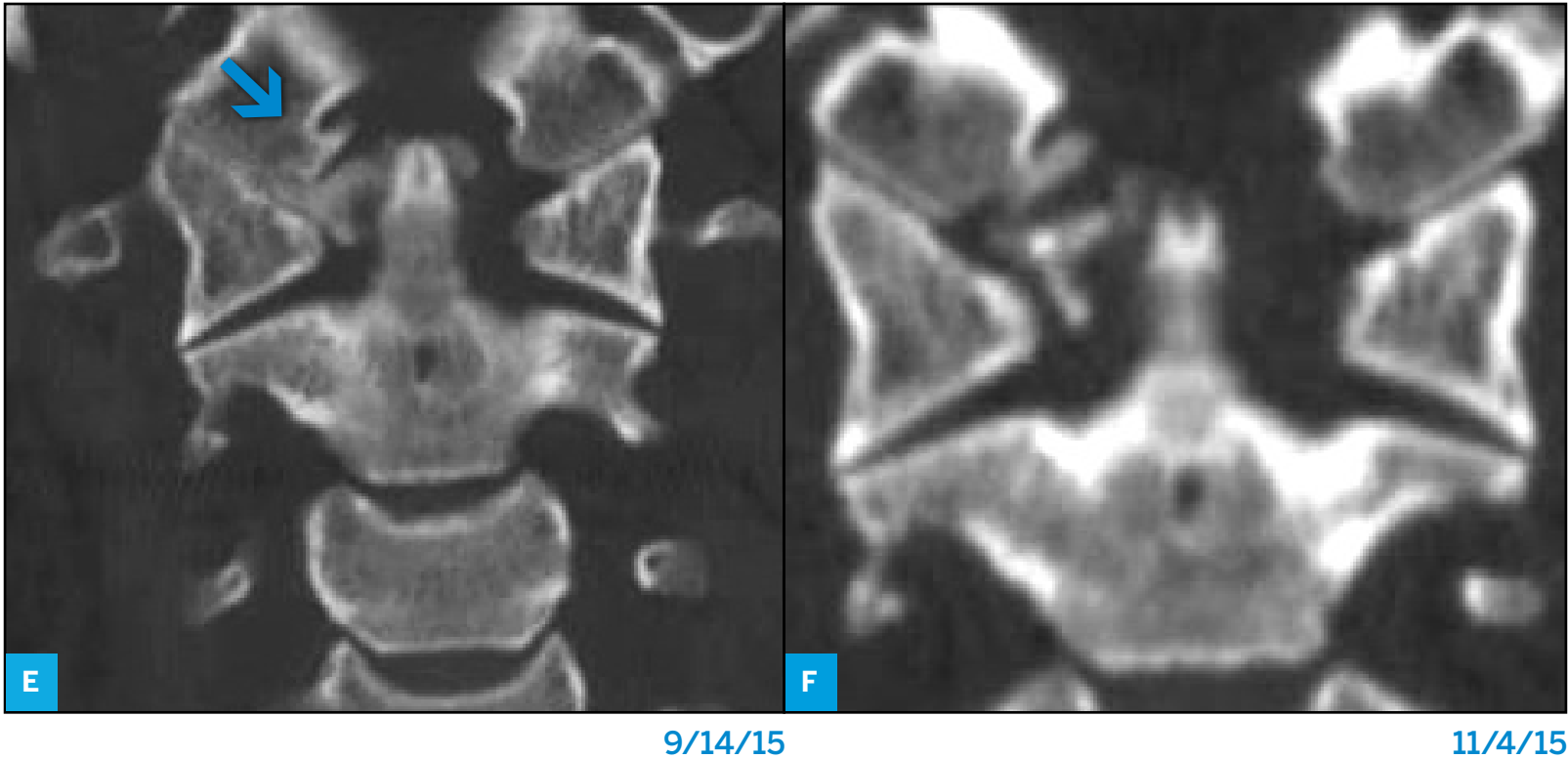


Figure 2 Continued: Coronal view at baseline (E) and 2 months later (F) showing fragmentation and partial dissolution of the mass.