

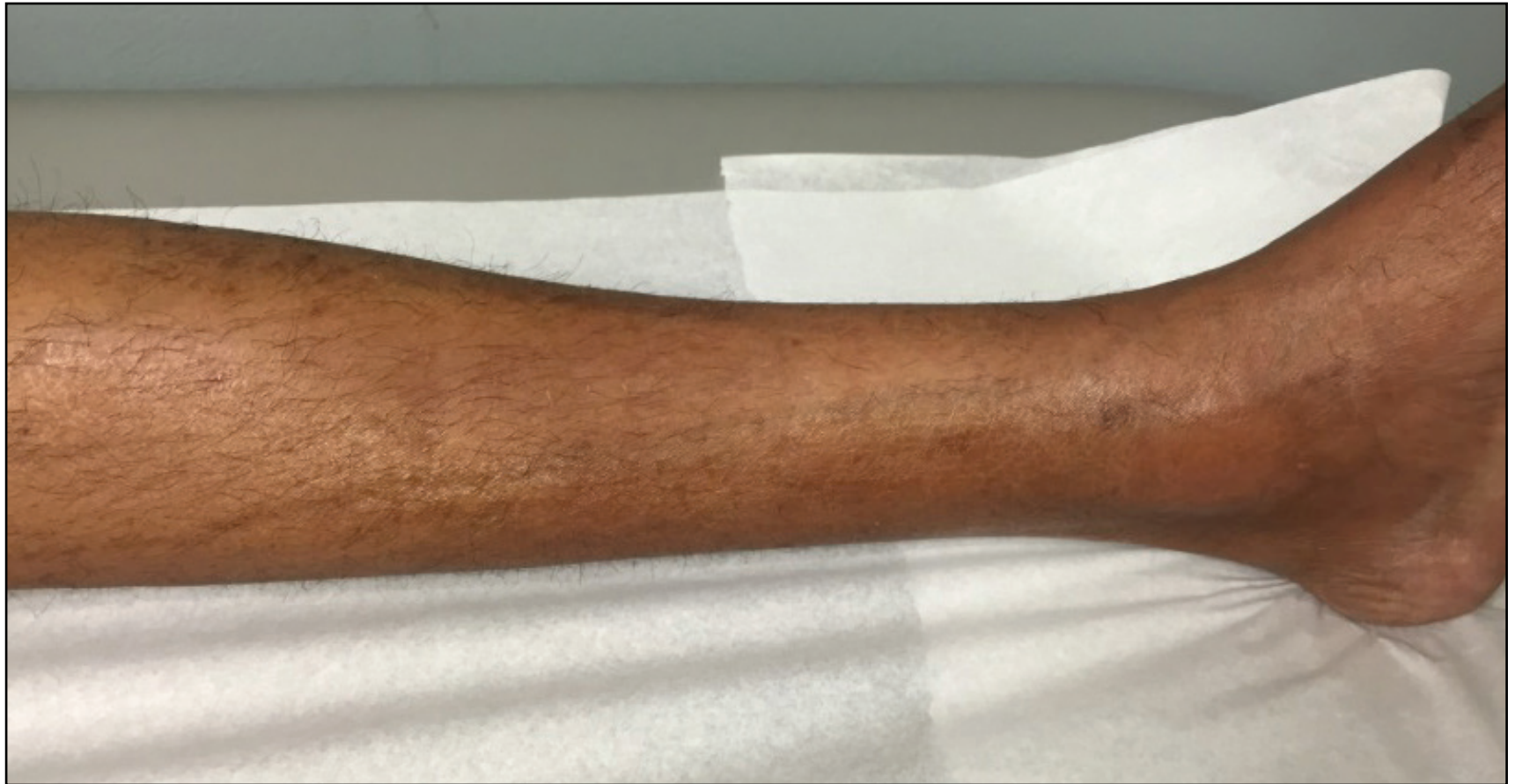

Figure 1: Photograph of the left leg demonstrating a “groove sign” along the path of a superficial vein.

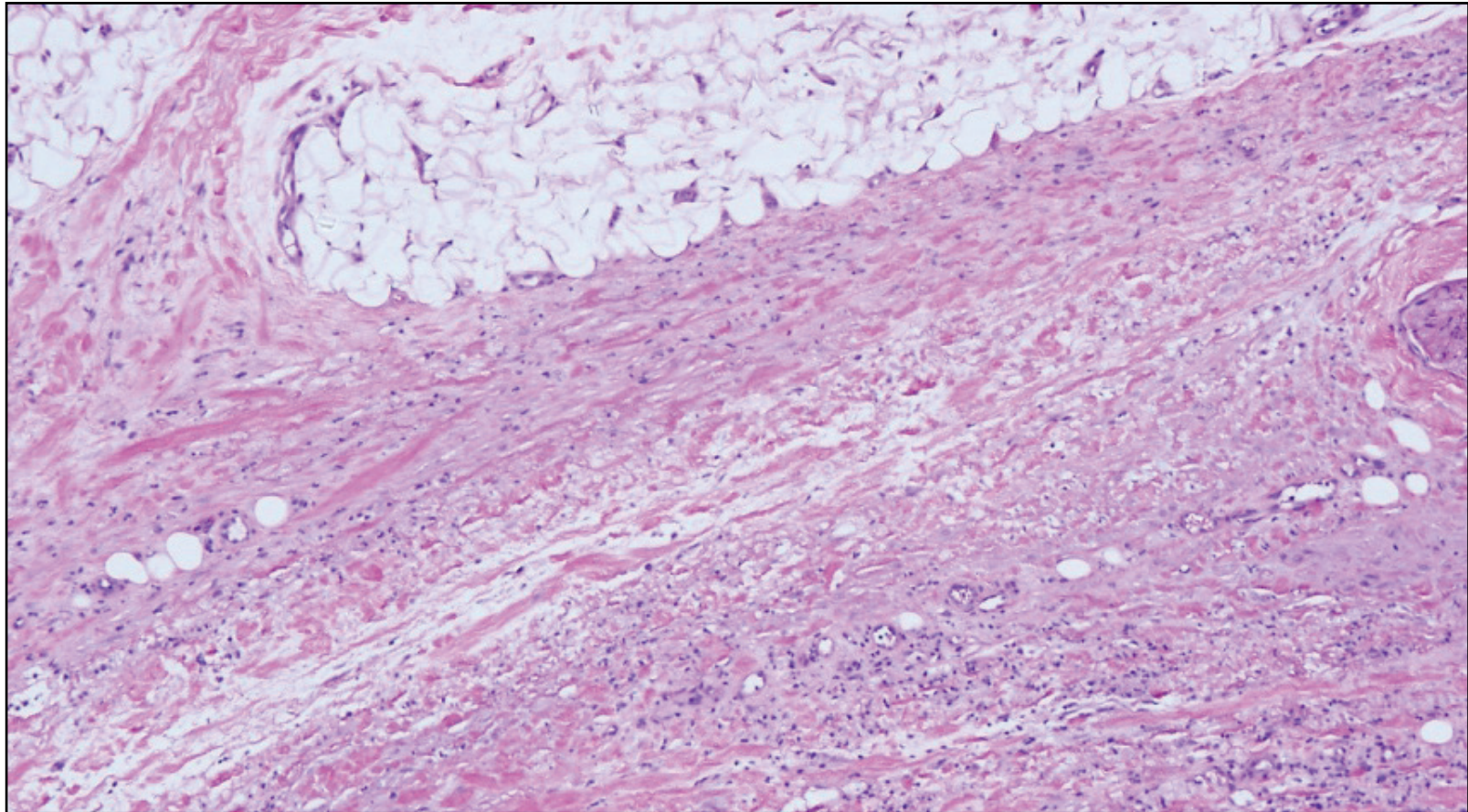


Figure 2: Deep skin biopsy demonstrating broad, hyalinized collagen bundles within the fascia with deposition of mucin and a lymphocytic and plasma cell infiltrate.