

Figure 1: Extensive retiform purpuric lesions on patient's bilateral lower extremities Day 5.

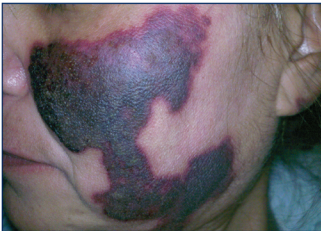

Figure 2: Deep purple lesions on cheek.

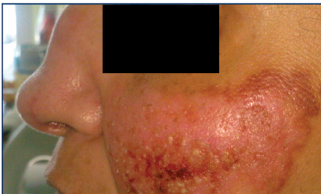

Figure 3: Saddle nose deformity. Resolving retiform purpura on cheeks.

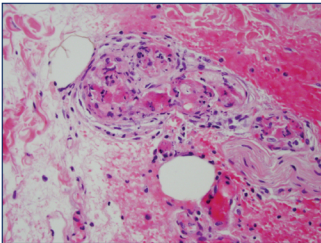


Figure 4: Skin biopsy shows a very distinctive intravascular occlusion without vasculitis primarily targeting capillaries and venules.