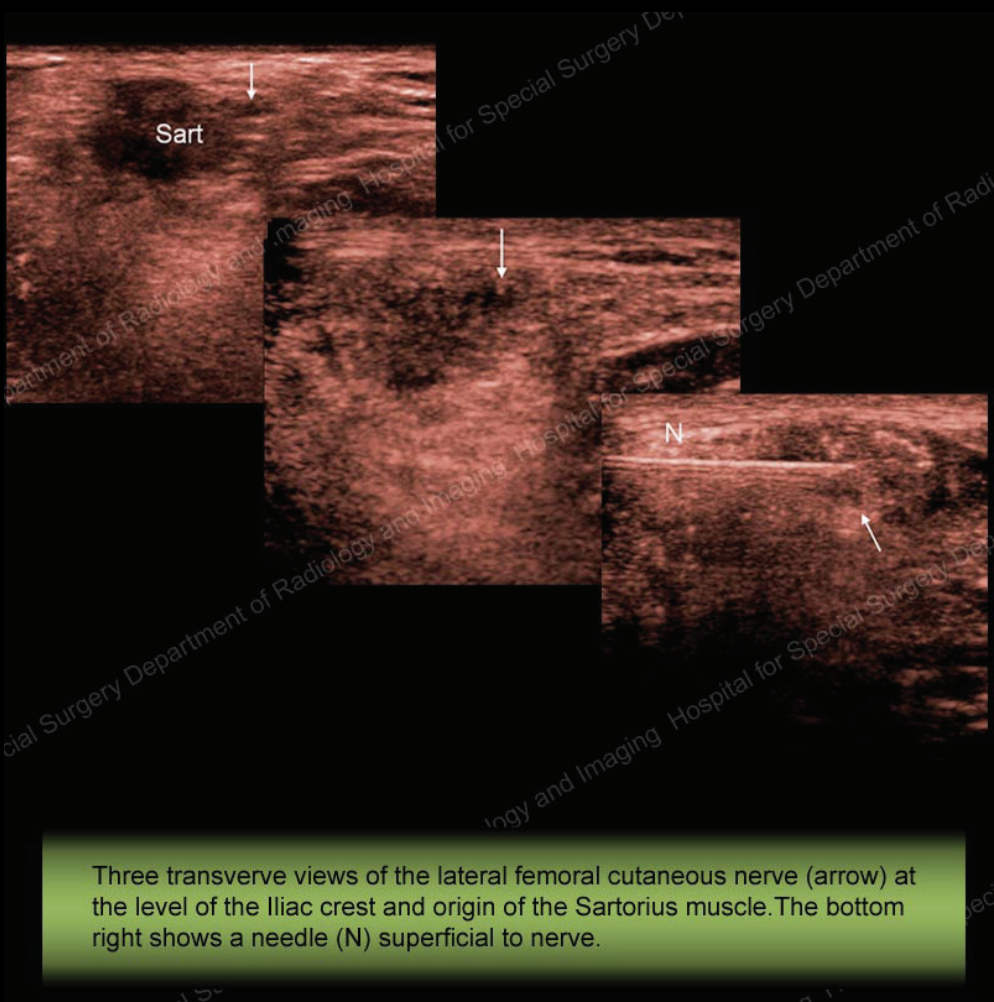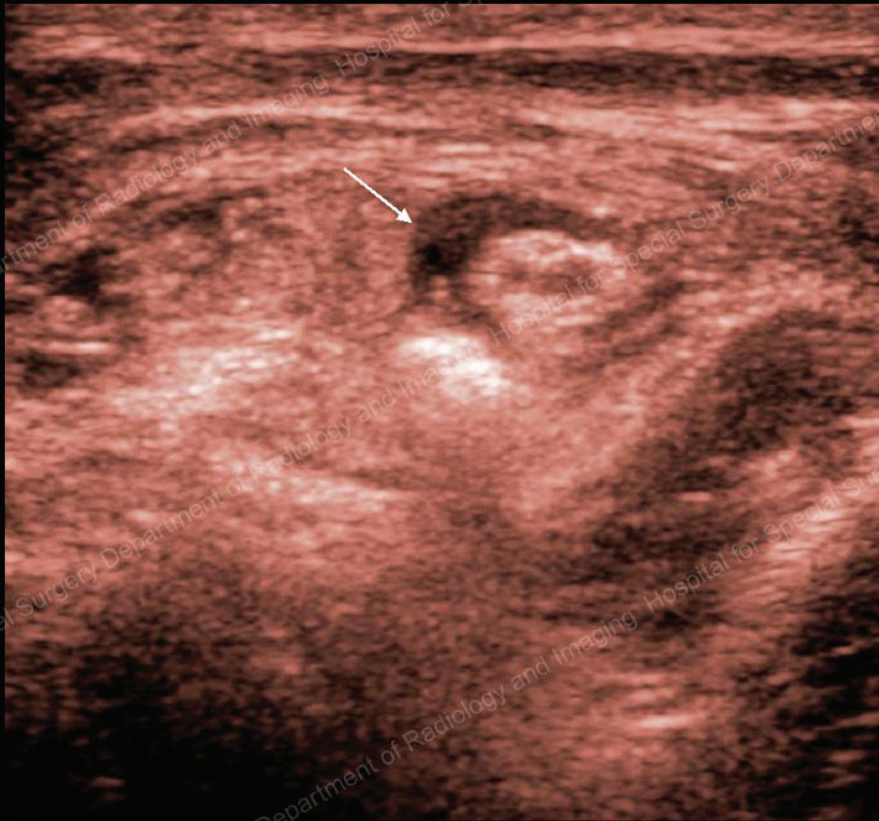


History

62 y/o male with right lateral thigh numbness (neuralgia paresthetica).



Injected therapeutic mixture surrounds the nerve (arrow) following injection

Diagnosis: Lateral femoral cutaneous nerve entrapment

Initial imaging shows hypoechoic scarring surrounding the nerve near the Iliac crest and Sartorius origin. Ultrasound guided perineural injection was Performed resulting in symptomatic relief.