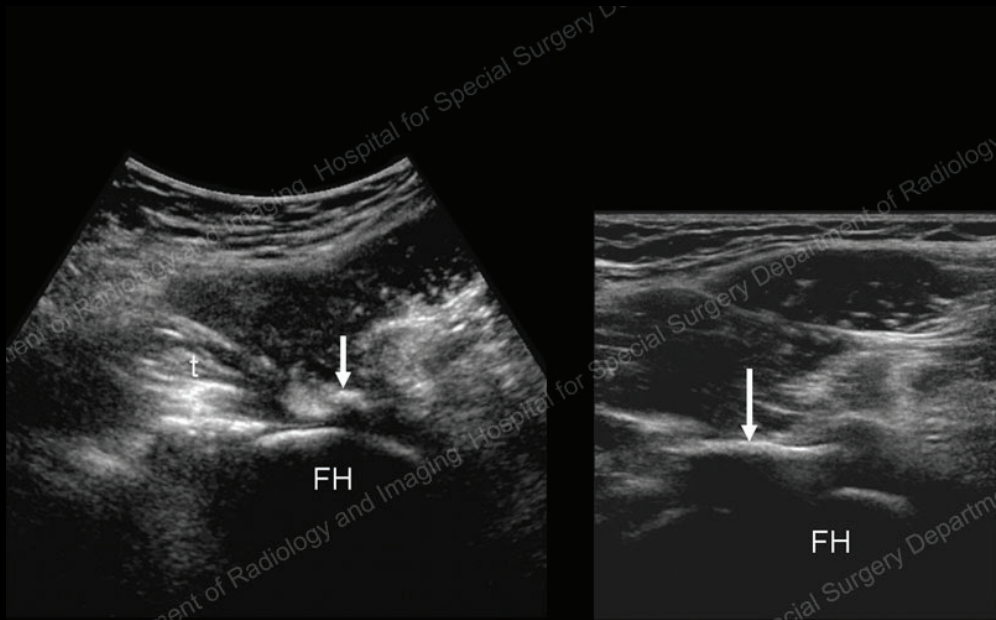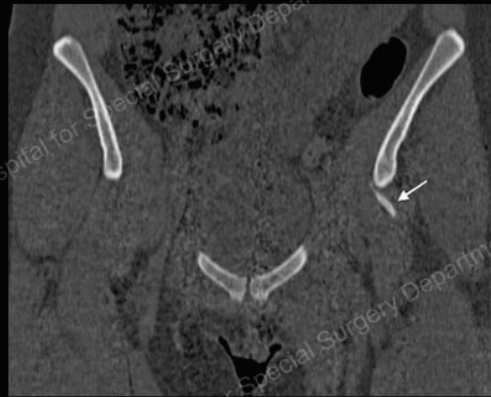
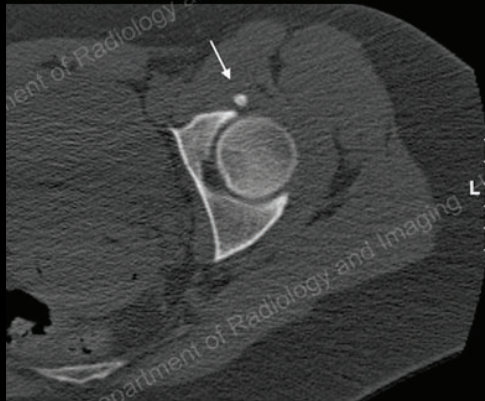


Transverse sonogram (left) show echogenic focus with shadowing (arrow) suggestive of calcification over the joint capsule. Longitudinal sonogram (right) shows linear calcification over the anterior joint capsule. The iliopsoas tendon (t) appeared normal at this level (left). FH = femoral head.

History

21 y/o female status post hip surgery for labral tear with persistent groin pain sent to ultrasound to assess for iliopsoas pathology. Outside MR read as unremarkable.



Axial (left) and coronal (right) CT images obtained after the ultrasound show linear calcified fragment (arrows) corresponding to ultrasound findings

Diagnosis:

Linear calcification in anterior joint capsule producing anterior impingement and pain.