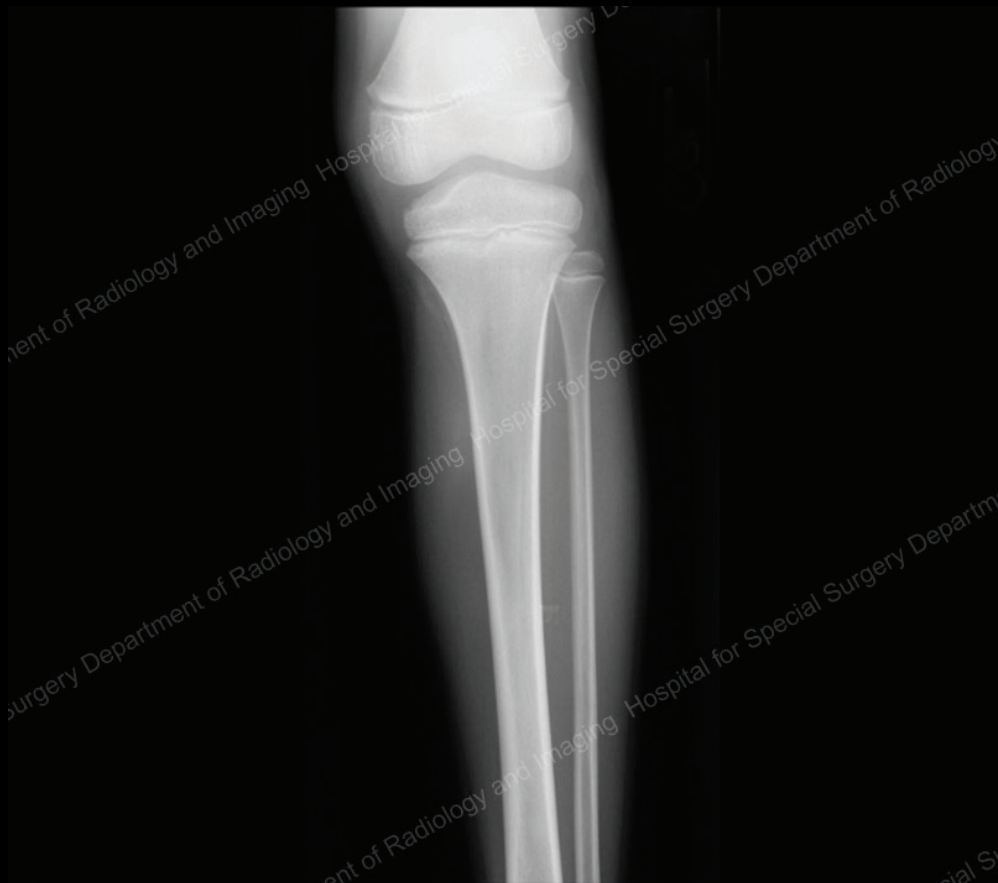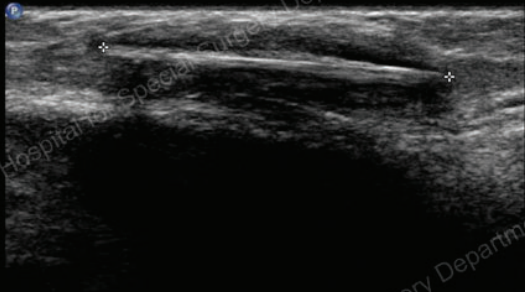

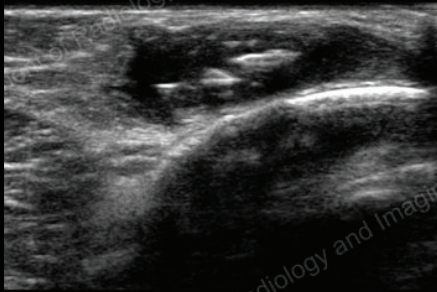


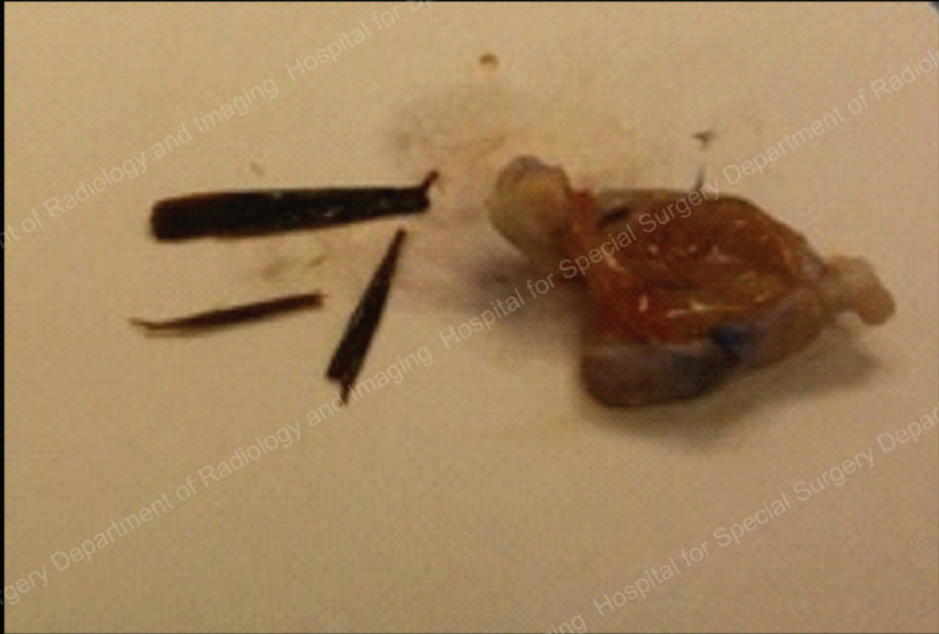Initial radiographic examination interpreted as normal

## History

10 year old active male with localized swelling over the left tibia sent to ultrasound to evaluate for possible cyst.



Longitudinal and transverse sonograms obtained at the site of soft tissue swelling over the proximal medial tibia shows a hypoechoic mass containing multiple linear echogenic structures



Inflammatory soft tissue mass removed containing multiple wooden splinters

# Diagnosis:

**Large foreign body granuloma containing multiple foreign bodies.**