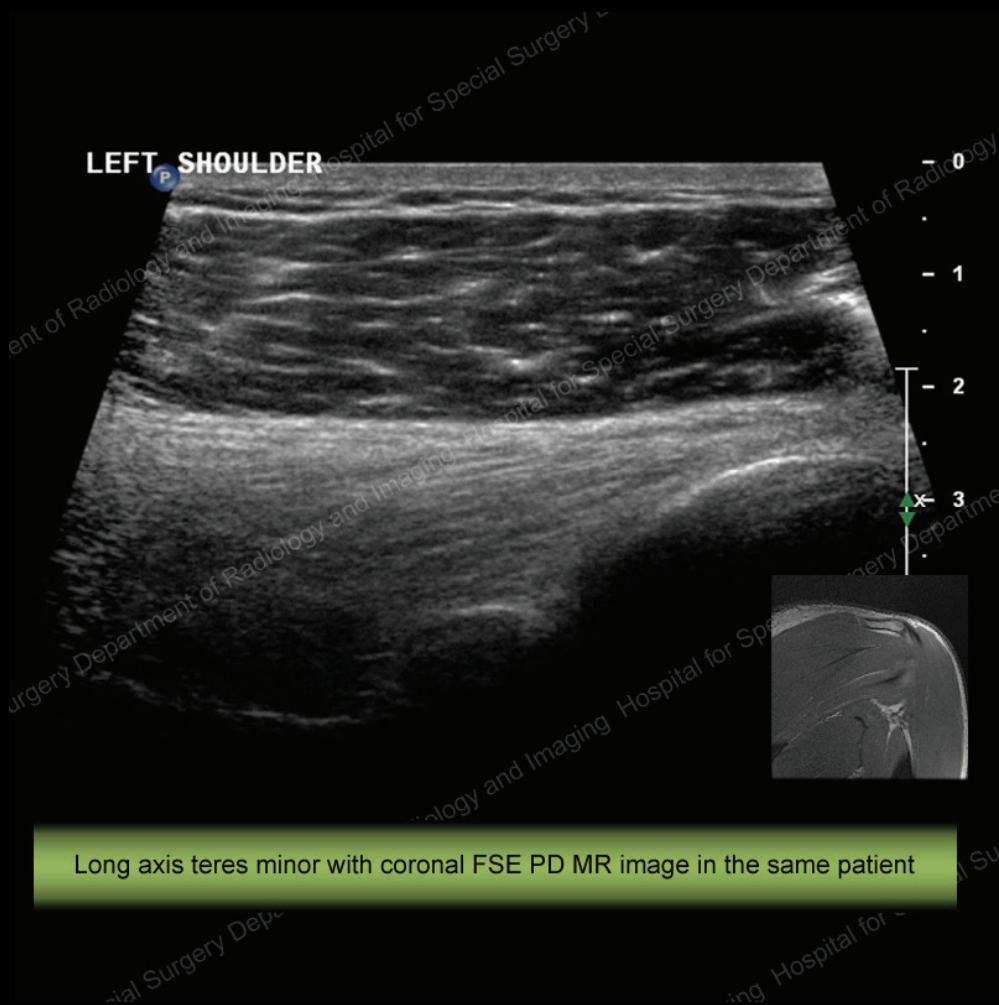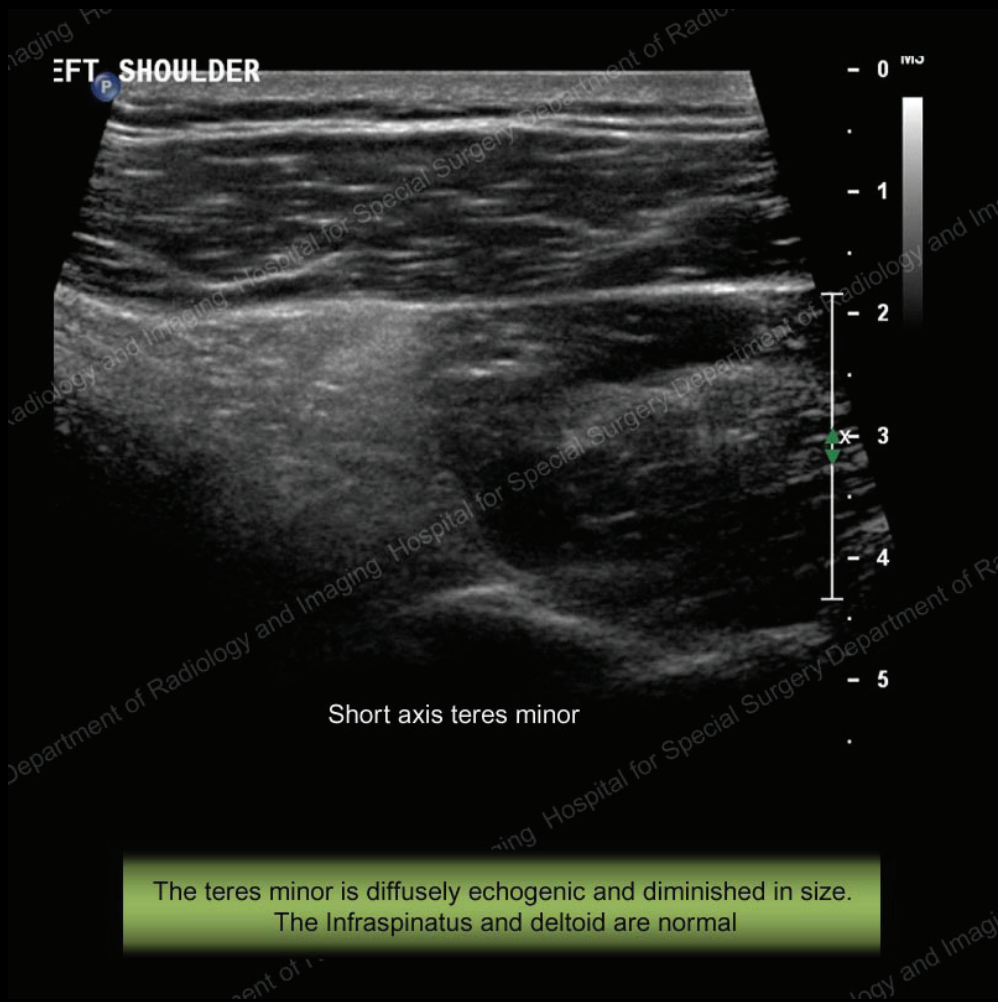


History

37 y/o male with left shoulder pain.



Diagnosis: Isolated teres minor atrophy

- Atrophic muscle appears echogenic and diminutive in size
- Normal muscle is hypoechoic on ultrasound
- Teres minor atrophy often due to injury of the axillary nerve as it passes through the quadrilateral space