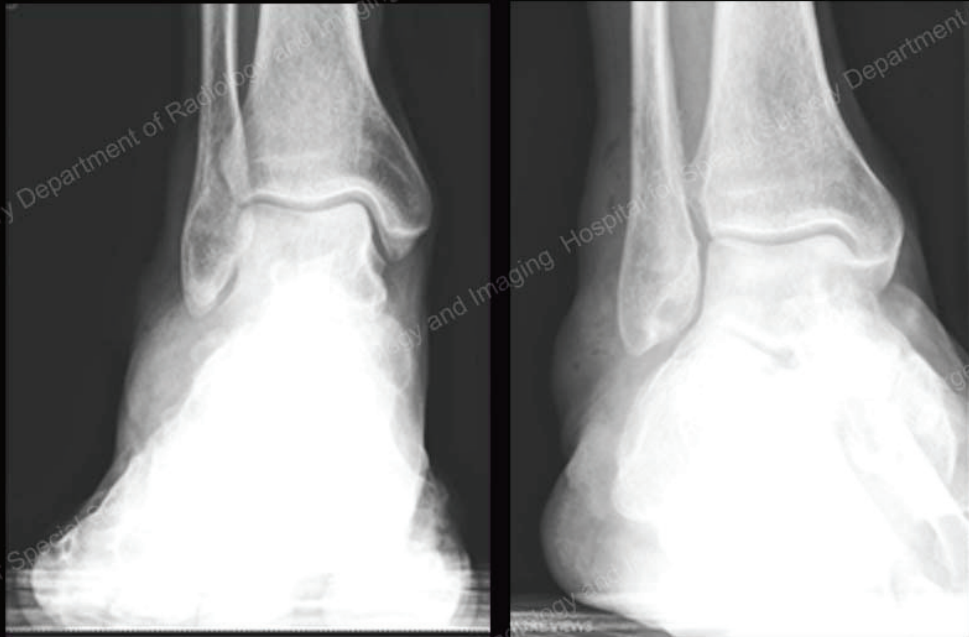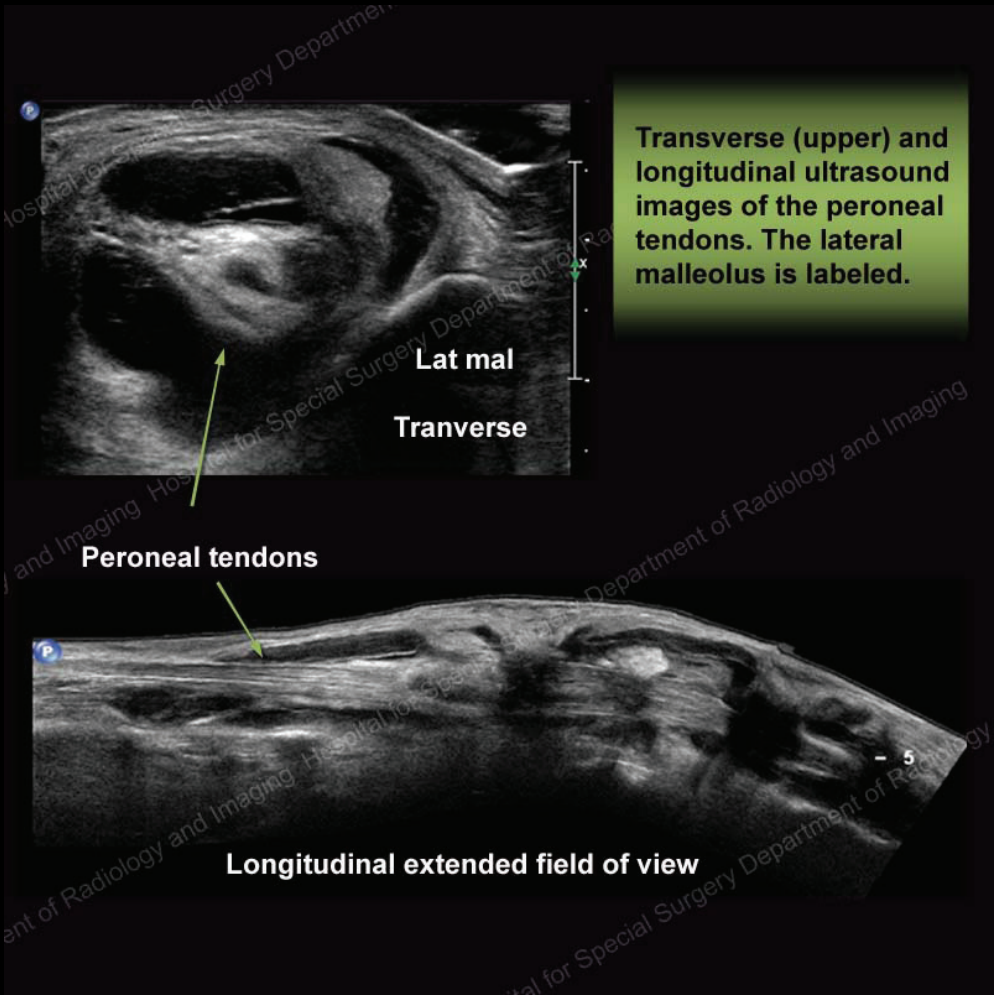




Soft tissue swelling evident over the lateral aspect of the ankle

History

54 y/o male with lateral ankle pain and swelling.



Diagnosis: Peroneal tenosynovitis

Ultrasound shows fluid and nodular soft tissue surrounding the peroneal tendons giving rise to the soft tissue swelling seen on radiographs.