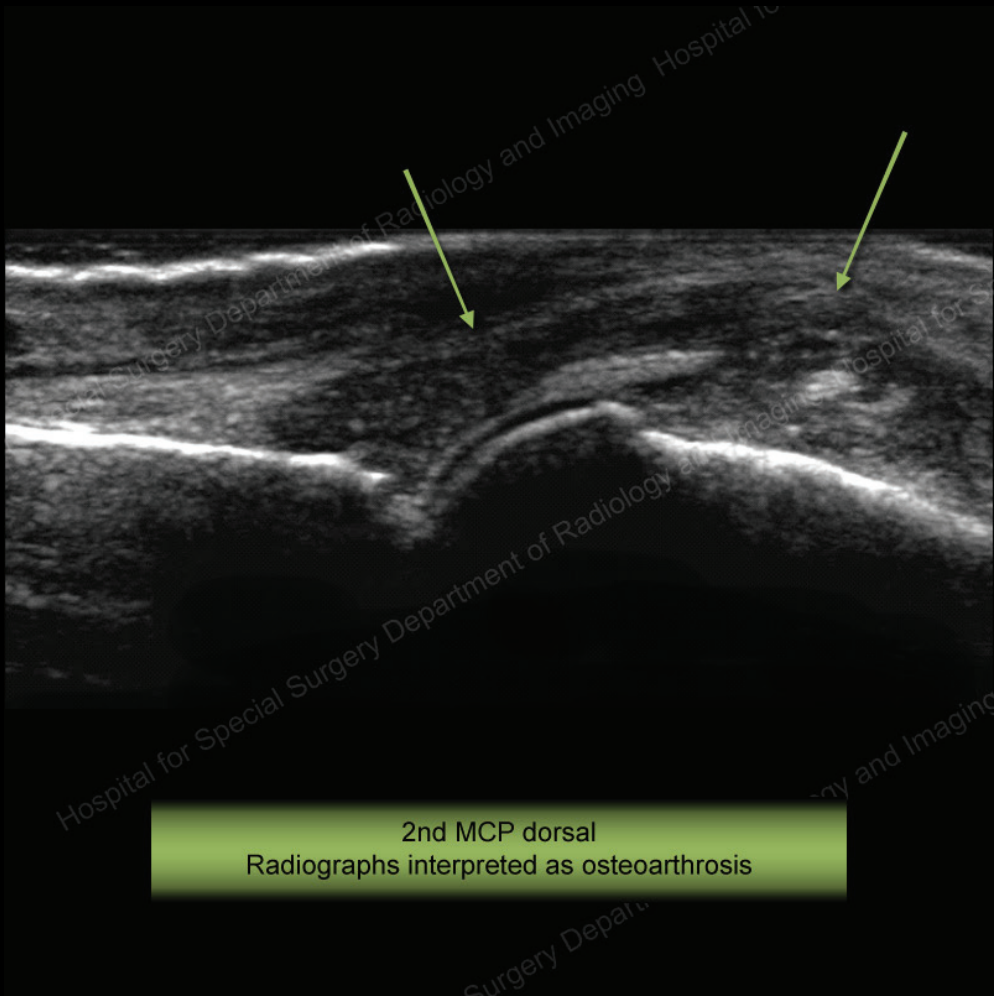

## History

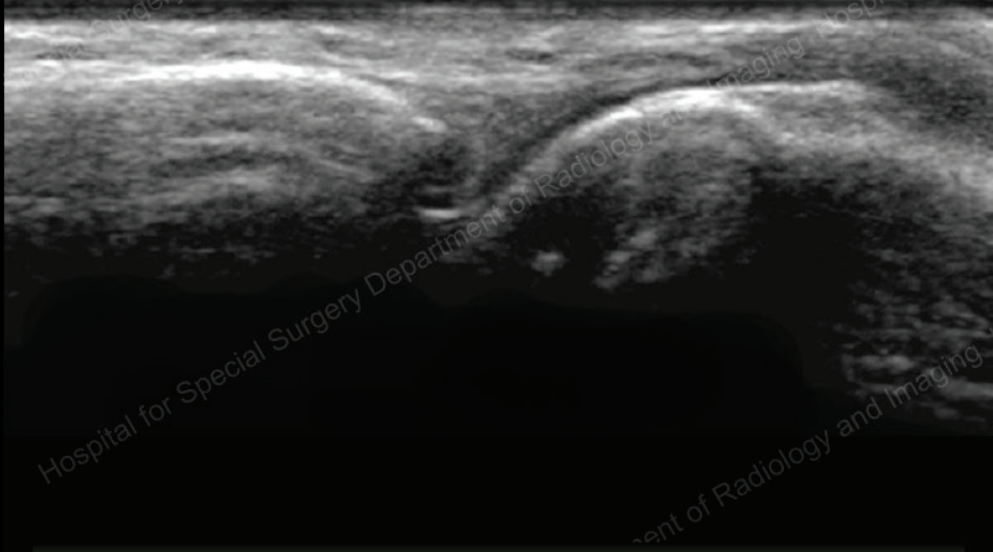
67 year old man with bilateral hand and wrist pain and swelling sent to ultrasound for diagnostic evaluation and aspiration.

# Findings

**There is distension of the dorsal recess by hypoechoic soft tissue containing multiple tiny echogenic foci (white arrows).**

**The articular cartilage has a nodular frosted appearance which is contiguous with more nodular appearing echogenic material.**

## Normal MCP joint



Thin hypoechoic band of articular cartilage parallels the cortical surface of the metacarpal head. Echogenic fat situated between articular cartilage and the thin echogenic joint capsule.

# Diagnosis

Sonographic appearances suggestive of gout. Confirmed on ultrasound guided aspiration.