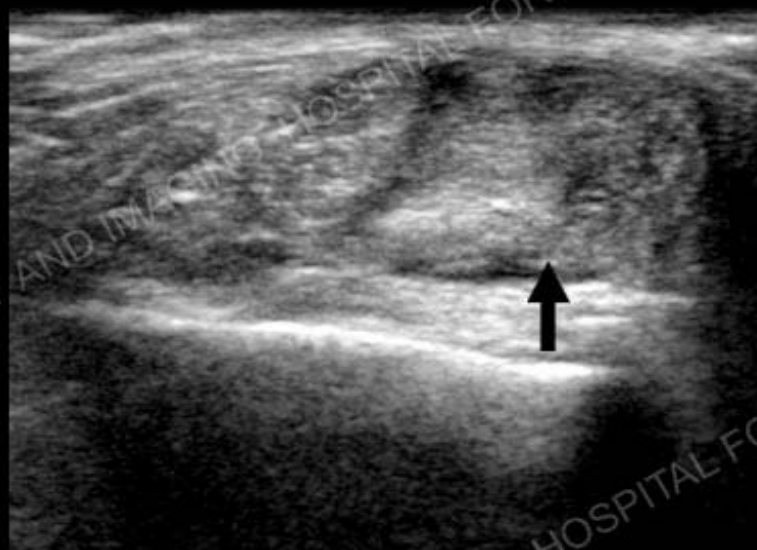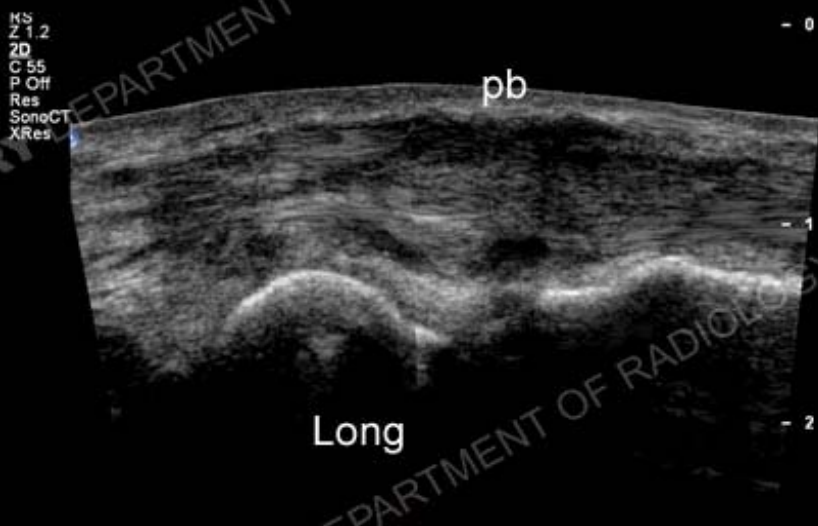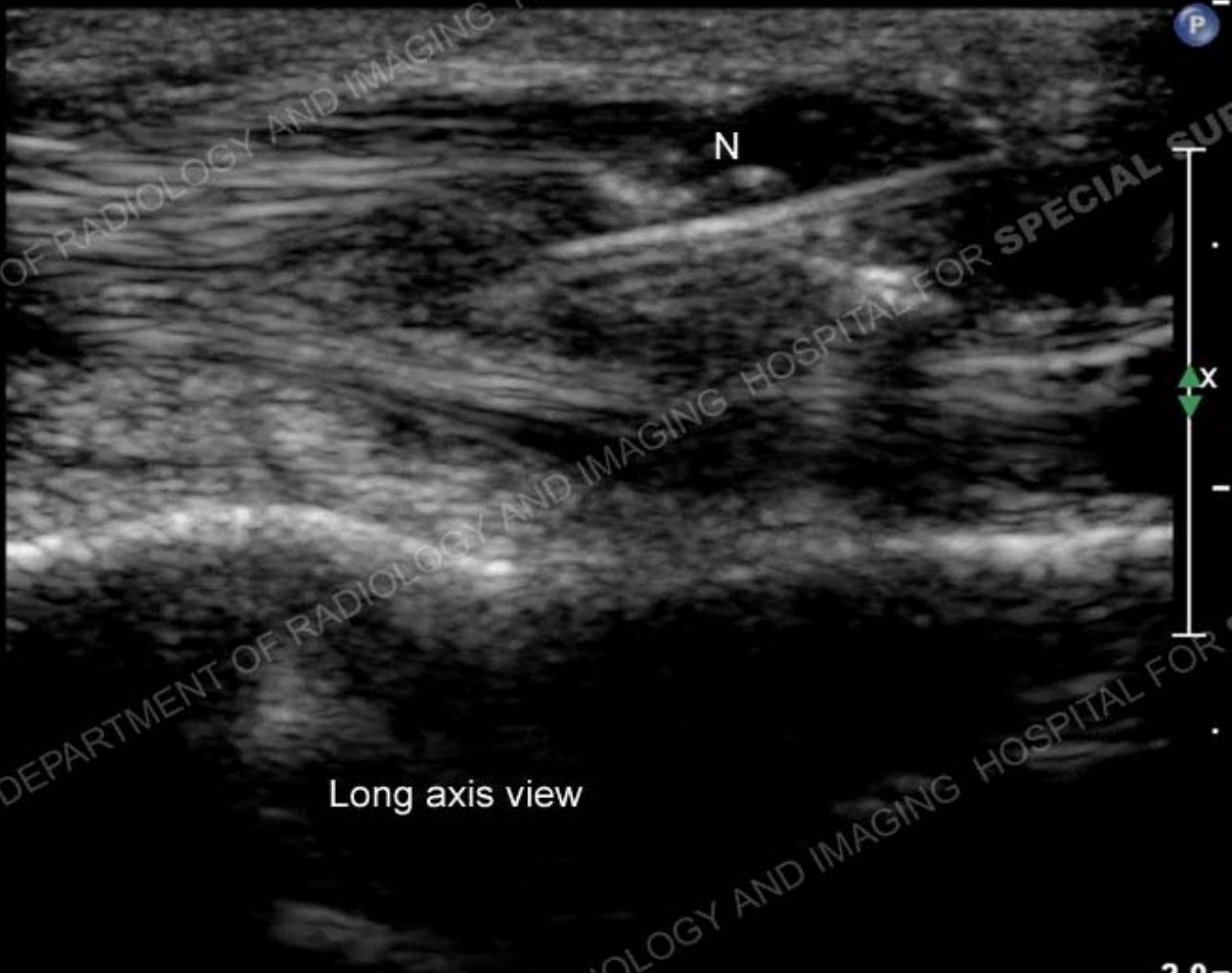


Longitudinal (long) and short axis image of peroneus brevis tendon (pb) shows marked thickening and inhomogeneity with a longitudinal split tear (arrow)




Long axis view

Right Peroneus Brevis

2.0-

Patient referred for ultrasound-guided platelet rich plasma injection in the Department of Radiology. A needle (N) is present within the substance of the peroneus brevis tendon during fenestration of the tendon and injection



Baseline

4 months following PRP injection

Image above depicts baseline at time of injury. Image to the right shows marked morphologic improvement 4 months following ultrasound-guided procedure. The patient was functionally much improved and resumed dance

Diagnosis

Traumatic peroneus brevis tear status post ultrasound guided PRP injection with healing response

