HSS

Grand Rounds from HSS

Management of Complex Cases

Orthopaedic Surgery
July 2019 | Volume 8 Issue 2

HSS Authors

Constantine A. Demetracopoulos, MD
Assistant Attending Orthopaedic Surgeon
Hospital for Special Surgery
Assistant Professor of Orthopaedic Surgery
Weill Cornell Medicine

Mark C. Drakos, MD
Assistant Attending Orthopaedic Surgeon
Hospital for Special Surgery
Assistant Professor of Orthopaedic Surgery
Weill Cornell Medicine

Scott J. Ellis, MD
Associate Attending Orthopaedic Surgeon
Hospital for Special Surgery
Associate Professor of Orthopaedic Surgery
Weill Cornell Medicine

HSS Co-authors

James Davies, MD
Orthopaedic Surgery Clinical Fellow
Hospital for Special Surgery

Amelia Hummel, BA
Research Assistant
Foot and Ankle Service
Hospital for Special Surgery

Aoife MacMahon, BA
MD Candidate, Class of 2020
Weill Cornell Medicine

Lauren E. Roberts, MD, MSc, FRCSC
Attending Orthopaedic Surgeon
University of British Columbia, Vancouver, British Columbia, Canada
Orthopaedic Surgery Clinical Fellow
Class of 2018
Hospital for Special Surgery

From the Editor

Edward C. Jones, MD, MA
Editor

The foot and ankle, our weight-bearing pedestal, are also one of the most common sources of functional limitation, intractable pain, and progressive disability. The congruous interaction of so many essential structures in the foot and ankle provides balanced support for a range of activities, from walking to running to vigorous sports—remarkable, when you consider the foot and ankle may repeatedly bear up to five times body weight while walking and up to 13 times body weight during activities such as running.

We rarely give this much thought until things begin to go wrong. Often, when a structure is injured or undergoes progressive wear, balanced function is disrupted, and other co-dependent structures may deteriorate. Foot and ankle specialists are quite innovative, treating a broad range of patients at all stages of life, from newborns with foot deformity to active teens, adults, and seniors.

As the cases presented in this volume demonstrate, foot and ankle specialists are often confronted with complex conditions that include articular cartilage wear, bone fracture and deformity, ligamentous incompetence, and tendon rupture or insufficiency. HSS surgeons are prominently involved in research that leads to new techniques that improve treatment outcomes for these conditions.

In this issue, we highlight how HSS foot and ankle surgeons have expertly evaluated and corrected anatomical deficiencies in managing three very challenging conditions.

In Case 1, **Scott J. Ellis, MD**, **Lauren E. Roberts, MD**, and **Aoife MacMahon, BA**, describe reconstruction of complex flatfoot deformity with a dorsal bunion. In Case 2, **Mark C. Drakos, MD**, and **James Davies, MD**, explain the innovative soft tissue procedures required to repair a large Achilles tendon defect using quadruple-bundle hamstring autograft with flexor hallucis longus transfer. In Case 3, **Constantine Demetracopoulos, MD**, and **Amelia Hummel, BA**, describe a two-stage procedure to carry out a complex total ankle arthroplasty in a patient with flatfoot deformity and deltoid insufficiency.

Previous volumes of *Grand Rounds from HSS: Management of Complex Cases* are available on **hss.edu/complexcases**, where you will find enlarged and additional images, references, and links to related articles. We hope you find these cases to be of interest and the principles presented informative. Comments are always welcome at **complexcases@hss.edu**.

Eward C. Jones, MD, MA
Assistant Attending Orthopaedic Surgeon

In This Issue

Case 1
Reconstruction of Complex Flatfoot Deformity with a Dorsal Bunion

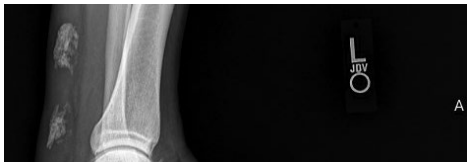

Case 2
Open Repair of a Large Achilles Tendon Defect Using Quadruple-Bundle Hamstring Autograft with Flexor Hallucis Longus Transfer

Case 3
Total Ankle Arthroplasty in Flatfoot Deformity with Deltoid Insufficiency

Case 1

Case presented by Aoife MacMahon, BA, Lauren E. Roberts, MD, and Scott J. Ellis, MD

Reconstruction of Complex Flatfoot Deformity with a Dorsal Bunion

Case Report A 27-year-old man was evaluated in March 2016 for left foot pain in the setting of severe left flatfoot deformity and a dorsal bunion (Fig. 1). He stated that his foot had been deformed since a sledding accident at 4 years of age; he had been placed in a long leg cast after a femur injury, but no foot injury had ever been noted.

The patient's pain was noted primarily at the sinus tarsi and along the medial arch. His past medical history included congenital pulmonary stenosis and growth delay requiring growth hormone supplementation. He previously smoked half a pack of cigarettes a day, which he stopped in order to decrease his perioperative risk. Initial conservative treatment including shoe lifts and orthotics had not alleviated his foot pain, and although he reported short-term relief with an ultrasound-guided corticosteroid injection into the subtalar joint in June 2016, these conservative measures ultimately failed.

On examination, he had subtle left-hindfoot valgus, pain at the sinus tarsi with forefoot supination, and an elevated first ray with a very prominent dorsal bunion and flexion contracture at the first metatarsophalangeal joint. He had overpull of the anterior tibial tendon, minimal eversion strength/motion, and limited inversion strength/motion. A weight-bearing computed tomographic (CT) scan showed talocalcaneal impingement at the angle of Gissane along with talonavicular arthritis (Fig. 2). There was significant midfoot deformity with shortening of the medial column, a 45° plantarflexion deformity of the talus, and a 45° dorsiflexion deformity through the naviculocuneiform joint in the sagittal plane with elevation of the first and second metatarsals. Talar head uncoverage was noted at the talonavicular joint with flattening of the talar head. A bony irregularity at the anterior aspect of the talocalcaneal joint—a superior projection of the distal aspect of the talus known as talar beaking—suggested a nonosseous coalition.

Surgery was performed in April 2018. The subtalar joint was prepared and realigned through a sinus tarsi approach and fused with two partially threaded cannulated screws. The dorsal bunion was corrected through realignment arthrodesis of the naviculocuneiform and talonavicular joints. The navicular was translated medially and plantarly to correct forefoot abduction and dorsal translation. An 8-mm dorsal wedge was placed from the medial approach into the naviculocuneiform joint (apex plantar). This was fixed with three cannulated compression screws and two locked compression plates (Fig. 3). The tibialis anterior was transferred with maximal length from the first ray to the lateral cuneiform, which reduced the deforming force on the first metatarsal yet maintained ankle dorsiflexion. The extensor hallucis longus was lengthened to allow great toe flexion. The forefoot was then plantigrade and well aligned (Fig. 3).

Postoperatively, the patient was placed in a short leg splint, which was changed to a short leg cast at 2 weeks and a controlled ankle movement boot at 7 weeks. At 12 weeks a CT scan showed well-maintained alignment and hardware placement, with good bony ingrowth at the dorsal wedge and fusion sites, and the patient began partial weight bearing. At 6 months he progressed to wearing regular shoes and had no pain. At 1 year he could work full time and occasionally run and play basketball, all pain free. Examination showed neutral hindfoot alignment, correction of forefoot abduction, and markedly improved first ray alignment (Fig. 4).

Discussion This complex case of flatfoot deformity with a dorsal bunion was managed with subtalar, talonavicular, and naviculocuneiform fusions; tibialis anterior transfer; and extensor hallucis longus lengthening.

The dorsal bunion was first described by Lapidus in 1940 as a dorsiflexion deformity of the first ray associated with flexion of the great toe at the first metatarsophalangeal joint [2]. Dorsal bunion deformity is rare, with reports in the literature limited to case series, usually in children [3]. It is most often seen after operative correction of clubfoot deformity, but other causes include paralytic foot conditions and severe congenital flatfoot [1, 2]. Although our patient reported no history of congenital foot disorders, he may have had a congenital flatfoot or coalition that remained subclinical until his childhood trauma. He may also have experienced a post-traumatic flatfoot deformity [4].

To correct the dorsal bunion, we performed a plantarflexion arthrodesis of the naviculocuneiform joint with interposition of a dorsal wedge and a talonavicular fusion [1]. Transfer of the tibialis anterior also permitted rebalancing of the deforming force of dorsiflexion [1]. This reconstruction has been described, involving the addition of a second tricortical allograft bone-block wedge into the first and second intercuneiform joints, which produced good outcomes [1].

This case also highlights the utility of weight-bearing CT scan (Fig. 2), now routinely available at our institution and elsewhere. The images indicated the need for a subtalar fusion based on the lateral impingement identified and also allowed for preoperative planning specific to wedge grafting of the naviculocuneiform fusion. ■

Images and references on the next page

Figure 1A

Figure 1: Weight-bearing radiographs at initial presentation showed significant flatfoot deformity, including (A) anteroposterior view with significant talar head uncovering and talonavicular joint arthritis and (B) lateral view showing a plantarflexed talus with an apex plantar midfoot deformity and an elevated first ray.

Figure 1B

Figure 2A

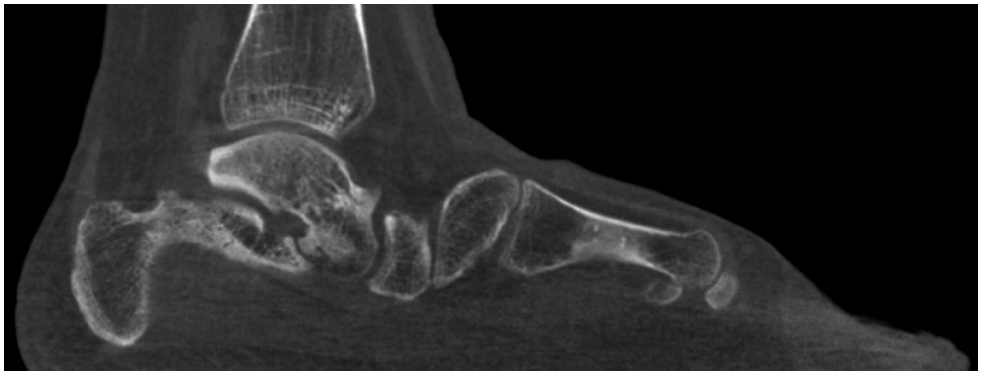

Figure 2B

Figure 2C

Figure 2: Preoperative weight-bearing CT scan showed (A) sagittal view with marked plantar sagging of the head of the talus and navicular with elevation of the first ray at the naviculocuneiform joint, (B) sagittal view with a subtalar non-osseous coalition with talar beaking, and (C) coronal view with lateral impingement.

Figure 3A

Figure 3B

Figure 3C

Figure 3: Radiographs at 1 year postoperatively showed healed (A) subtalar and (B) midfoot fusions and (C) improved hindfoot alignment.

Figure 4A

Figure 4B

Figure 4C

Figure 4: Postoperative (A) anterior, (B) lateral, and (C) hindfoot alignment clinical views at 1 year showed improved midfoot, first ray, and hindfoot alignment of the left foot.

Case 2 References

1. Johnson JE, Thomson AB, Yu JR. Double bone-block arthrodesis for the correction of a dorsal bunion deformity. *Tech Foot Ankle Surg.* 2007;6(3):170–174.
2. Lapidus PW. "Dorsal bunion": its mechanics and operative correction. *J Bone Joint Surg Am.* 1940;22(3):627–637.
3. McKay D. Dorsal bunions in children. *J Bone Joint Surg Am.* 1983;65(7):975–980.
4. Nelson DR, Younger A. Acute posttraumatic planovalgus foot deformity involving hindfoot ligamentous pathology. *Foot Ankle Clin*. 2003;8(3):521–537.

Case 2 Case presented by James Davies, MD, and Mark C. Drakos, MD

Open Repair of a Large Achilles Tendon Defect Using Quadruple-Bundle Hamstring Autograft with Flexor Hallucis Longus Transfer

Case Report A 60-year-old man presented for evaluation a week after experiencing a "pop" with pain in the area of the left Achilles tendon while playing tennis. He reported a history of left Achilles tendon rupture over 30 years ago that was treated nonoperatively. The patient did well after this injury, resuming tennis until he experienced this sudden onset of pain and difficulty with plantarflexion of the left ankle. He reported a history of hypertension, osteoarthritis, and peripheral vascular disease.

On examination, the patient had pain over the musculotendinous junction of the Achilles tendon and a palpable gap in the tendon through an area of calcification from his previous rupture. The patient also had swelling, ecchymosis, and tenderness to palpation in the affected area. There was a positive result on the Thompson squeeze test. Lateral plain X-ray showed calcification at the site of the prior Achilles rupture and evidence of probable acute tendon rupture (Fig. 1).

Given the large gap in the Achilles through this area of dense calcification, we determined that the patient would benefit from operative intervention. We recommended open Achilles repair with excision of the calcified tendon and harvest of the hamstring tendon for the repair, along with flexor hallucis longus (FHL) tendon transfer to the distal Achilles insertion to improve muscle recruitment [4, 5]. The patient agreed to this plan.

Intraoperatively, the patient was placed in the prone position. With the knee flexed, the hamstrings were harvested through an anterior approach to the proximal tibia at their insertion. The tendons were prepared on the back table, including the removal of residual muscle and tubularization of the graft. After we prepared the graft, we made a 7-cm incision just medial to the midline over the Achilles tendon. The ends of the tendon were mobilized. The patient had an approximately 6-cm area of tendinopathy, with a 5-6-cm area of calcified Achilles tendon. He had fractured through the calcification and had 2 cm of diastases between the calcified ends of the tendon.

We then harvested the FHL tendon, taking care to open up the deep posterior compartment. After we excised the calcified portion of the tendon, we attached the hamstring tendon autograft to the base of the calcaneus. The FHL tendon was also placed in this tunnel. It was held in place using a Bio-Tenodesis Screw™ (Arthrex, Inc., Naples, FL). We then brought both limbs of the hamstring autograft proximally and performed a standard Pulvertaft-type maneuver, with approximately 10° to 15° of ankle plantarflexion [1]. The autograft was then tubularized with a suture tape (Fig. 2). We then brought the hamstring tendon back down distally and attached the new Achilles tendon reconstruction, with tension in about 10° to 15° of ankle plantarflexion. We were able to get the ankle to neutral, passive dorsiflexion. Thus, we had created a quadruple-bundle hamstring autograft to reconstruct the Achilles tendon, augmented with the FHL tendon (Fig. 2).

Next, we placed a modified Bunnell stitch in the distal aspect of the tendon, exiting proximally and further tightening the repair [7]. At this point, we had excellent tension on our repair and negative Thompson squeeze test.

The patient adhered to the following postoperative protocol:

- Days 0–14: remain non-weight bearing in a splint with strict elevation
- Weeks 2–6: shift to non-weight bearing in a controlled ankle movement (CAM) boot with heel lift; active dorsiflexion range of motion to neutral position
- Weeks 6–12: begin formal physical therapy and partial weight bearing in a CAM boot
- Months 3–6: transition to a sneaker; return to activities of daily living; continue physical therapy
- Months 6–12: return to sports

Discussion Large Achilles tendon defects can arise from a variety of causes and, along with chronic Achilles tendinopathy, can cause debilitating symptoms for patients and pose a difficult challenge for surgeons. The literature has noted rupture usually occurs 4–6 cm above the calcaneal insertion in a hypovascular region [2].

As this case demonstrates, hamstring autograft offers a viable surgical solution to address this difficult problem. Multiple reconstruction techniques have been described, including the use of Achilles allografts with or without attached calcaneal allograft and V-Y turndown [3, 6]. This case demonstrates the utility of using ipsilateral hamstring autograft with FHL augmentation to address large tendon defects and allow for return to pre-injury level of activity. ■

Images and references on the next page

Figure 1

Figure 2

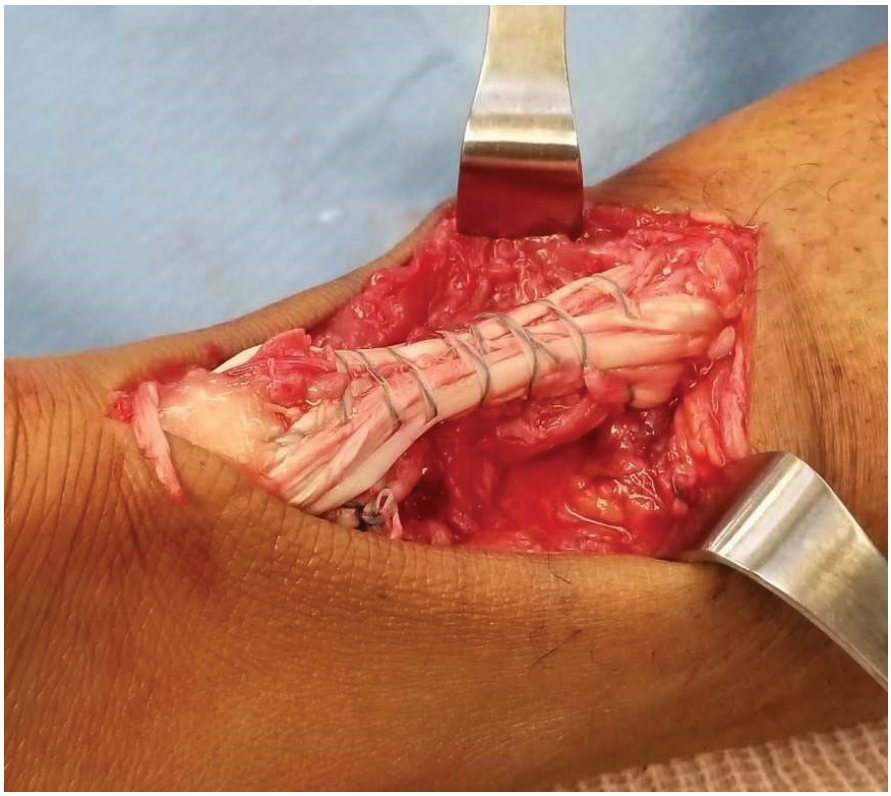

Figure 1: Lateral X-ray view of the left ankle at initial presentation demonstrating evidence of probable Achilles tendon rupture through chronic calcification at prior Achilles rupture site.

Figure 2: Intraoperative images showing hamstring autograft with Pulvertaft weave through proximal and distal Achilles stump, spanning the gap after the area of chronic calcification was excised.

Case 2 References

1. Brown SH, Hentzen ER, Kwan A, Ward SR, Fridén J, Lieber RL. Mechanical strength of the side-to-side versus Pulvertaft weave tendon repair. *J Hand Surg.* 2010;35(4):540–545.
2. Chen TM, Rozen WM, Pan WR, Ashton MW, Richardson MD, Taylor GI. The arterial anatomy of the Achilles tendon: anatomical study and clinical implications. *Clin Anat*. 2009;22(3):377–385.
3. Elias I, Besser M, Nazarian LN, Raikin SM. Reconstruction for missed or neglected Achilles tendon rupture with VY lengthening and flexor hallucis longus tendon transfer through one incision. *Foot Ankle Int*. 2007;28(12):1238–1248.
4. Hahn F, Meyer P, Maiwald C, Zanetti M, Vienne P. Treatment of chronic Achilles tendinopathy and ruptures with flexor hallucis tendon transfer: clinical outcome and MRI findings. *Foot Ankle Int.* 2008;29(8): 794–802.
5. Karnovsky SC, Drakos MC. Revision Achilles reconstruction with hamstring autograft and FHL tendon transfer in an athlete. *HSS J.* 2017;13(3):302–306.
6. Lee DK. Achilles tendon repair with acellular tissue graft augmentation in neglected ruptures. *J Foot Ankle Surg.* 2007;46(6):451–455.
7. Saxena A. Surgery for chronic Achilles tendon problems. *J Foot Ankle Surg.* 1995;34(3):294–300.

Case 3

Case presented by Amelia Hummel, BA, and Constantine A. Demetracopoulos, MD

Total Ankle Arthroplasty in Flatfoot Deformity with Deltoid Insufficiency

Case Report In January 2017, a 69-year-old man with a history of severe flatfoot deformity presented with persistent, localized pain at the anterior aspect of the right ankle, causing progressive disability and difficulty with ambulation. Two years prior, he underwent subtalar and talonavicular arthrodesis, as well as first tarsometatarsal arthrodesis and a gastrocnemius recession to address his flatfoot deformity.

On physical examination, the patient stood with slight valgus alignment in his right hindfoot and ambulated with an antalgic gait. His first ray was stable. He had tenderness at the ankle and talonavicular joints, with a range of 5° of dorsiflexion and 20° of plantarflexion at the ankle. There was no appreciable motion at the hindfoot. Weight-bearing radiographs revealed end-stage arthritis in the ankle joint, with radiolucency and failed hardware at the talonavicular joint (Fig. 1). Single-photon-emission computed tomography (SPECT) demonstrated increased activity at the ankle, as well as at the talonavicular joint, thus confirming the presence of talonavicular joint nonunion (Fig. 2).

In May 2017, the patient underwent total ankle replacement and revision talonavicular arthrodesis. A percutaneous Achilles tendon lengthening was performed in order to restore dorsiflexion at the tibiotalar joint.

A fixed bearing, modular stem ankle replacement implant was used to achieve sufficient fixation within the tibia and talus, given the patient's history of hindfoot arthrodesis. A revision talonavicular arthrodesis was performed through the anterior ankle approach; autograft from the tibial cut, as well as recombinant human platelet-derived growth factor BB (rhPDGF-BB), augmented healing (Fig. 3).

The patient's initial postoperative course was without complication. At the 12-week postoperative visit, weight-bearing radiographs of the ankle demonstrated valgus tilt at the tibiotalar prosthesis (Fig. 4). The patient denied pain at that time and was ambulating fully in a sneaker. A hindfoot alignment view radiograph also indicated slight valgus at the hindfoot (Fig. 5). Weight-bearing CT confirmed the valgus deformity at the tibiotalar joint and demonstrated osseous union of the talonavicular joint with intact hardware.

Given the severity of the valgus tilt at the tibiotalar prosthesis and concern for the longevity of the prosthesis, reoperation was indicated to reconstruct the deltoid ligament, and a medializing calcaneal osteotomy was indicated to improve hindfoot alignment.

Four months after the total ankle arthroplasty, the patient underwent surgery to restore alignment to the ankle and hindfoot. The polyethylene was removed from the tibiotalar prosthesis. A deltoid ligament reconstruction was performed using a semitendinosus allograft that was docked distally at the sustentaculum tali, tensioned through the tibia and secured with a biotenodesis screw. The polyethylene insert was upsized by 2 mm.

A medializing calcaneal osteotomy was then performed through an oblique incision along the lateral aspect of the calcaneus, and the heel was translated medially to achieve a neutral hindfoot alignment.

One year after the procedures to restore ankle and hindfoot alignment, the patient was doing well, with a well-aligned, balanced ankle prosthesis and a neutral hindfoot (Fig. 6). He ambulated without pain and reported great satisfaction with his overall outcomes.

Discussion This case of severe flatfoot deformity in conjunction with progressive ankle arthritis was managed with three surgical procedures. It highlights the importance of ligamentous stability with proper alignment of the hindfoot in ensuring a successful outcome of ankle arthroplasty in a patient with flatfoot deformity and deltoid ligament insufficiency.

In treating ankle arthritis accompanied by significant foot deformity, there is controversy over whether a staged approach is necessary and whether the ankle arthritis or the foot deformity should be addressed first. Although in this case ankle arthritis was noted at the time of the original flatfoot reconstruction surgery, the surgeon performed hindfoot arthrodesis because the majority of pain and deformity was in the hindfoot. Dodd and Daniels describe the necessity of staging procedures in patients who have both flatfoot deformity and end-stage ankle arthritis [3]. They note that one major bony procedure with a total ankle replacement is generally safe, although multiple bony procedures increase the risk of complications. Chan et al. found that the medializing calcaneal osteotomy is the primary determinant of hindfoot valgus correction in flatfoot reconstruction [1]. In addition, Conti et al. showed that achieving 0 to 5 mm varus heel alignment correlated with the best clinical outcomes scores in patients with flatfoot deformity [2].

This case exemplifies a complex deformity requiring management of both bony deformities and ligamentous incompetence. After ankle replacement and revision talonavicular arthrodesis, the talar component tilted into valgus, revealing deltoid ligament insufficiency not appreciated at the time of the ankle arthroplasty. Deltoid insufficiency can occur in patients with longstanding flatfoot deformity. Arthrodesis of the hindfoot increases the lever arm of the talus, thus placing a greater strain on the deltoid ligament. In this case, with early recognition of this problem, a second surgery resolved the deltoid insufficiency and hindfoot valgus, with good results for the patient. ■

Images and references on the next page

Figure 1

Figure 1: Weight-bearing lateral radiograph at initial presentation indicating end-stage arthritis in the ankle joint, with radiolucency and failed hardware at the talonavicular joint.

Figure 2

Figure 2: SPECT images showing increased uptake at the talonavicular and tibiotalar joints, confirming the presence of talonavicular joint nonunion.

Figure 3

Figure 3: Intraoperative images from May 2017, showing a fixed-bearing, modular stem ankle replacement implant and a revised talonavicular arthrodesis.

Figure 4

Figure 4: Postoperative weight-bearing radiograph of the ankle demonstrating valgus tilt of the tibiotalar prosthesis and hindfoot.

Figure 5

Figure 5: Postoperative radiograph demonstrating valgus alignment of the hindfoot.

Figure 6A

Figure 6B

Figure 6: Final postoperative radiographs of the ankle and hindfoot showing (A) a well-aligned, balanced ankle prosthesis and (B) the hindfoot in neutral position.

Case 3 References

1. Chan JR, Williams BR, Pallavi N, et al. The contribution of medializing calcaneal osteotomy on hindfoot alignment in the reconstruction of the stage II adult acquired flatfoot deformity. *Foot Ankle Int.* 2013;34(2):159–166.
2. Conti M S, Elli, SJ, Chan JR, Do HT, Deland JT. Optimal position of the heel following reconstruction of the stage II adult-acquired flatfoot deformity. *Foot Ankle Int.* 36(8):919–927.
3. Dodd A, Daniels TR. Total ankle replacement in the presence of talar varus or valgus deformities. *Foot Ankle Clin.* 2017;22(3):277–300.