



Figure 1: Radiograph of initial presentation of right Congenital Short Femur with 14cm of shortening. This shows a healed pelvic osteotomy, and intertrochanteric osteotomy with radiographic evidence of a nonunion and significant varus angulation.

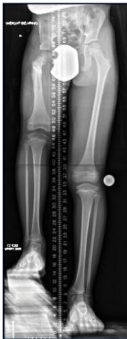

Figure 2: Radiograph showing well healed corrective valgus osteotomy after plate removal.

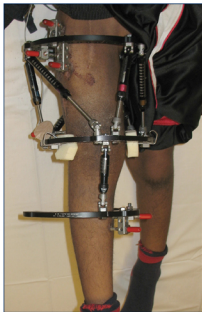


Figure 3: After a femoral diaphyseal osteotomy, a Taylor Spatial Frame (TSF) was applied to the femur and spanned across the knee joint.

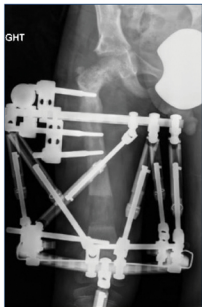

Figure 4: After femoral diaphyseal osteotomy, TDSF application and 5cm lengthening.

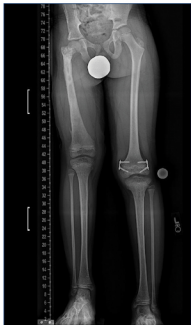

Figure 5: After removal of TSF and contralateral distal femoral epiphysiodesis with residual 8cm discrepancy.