

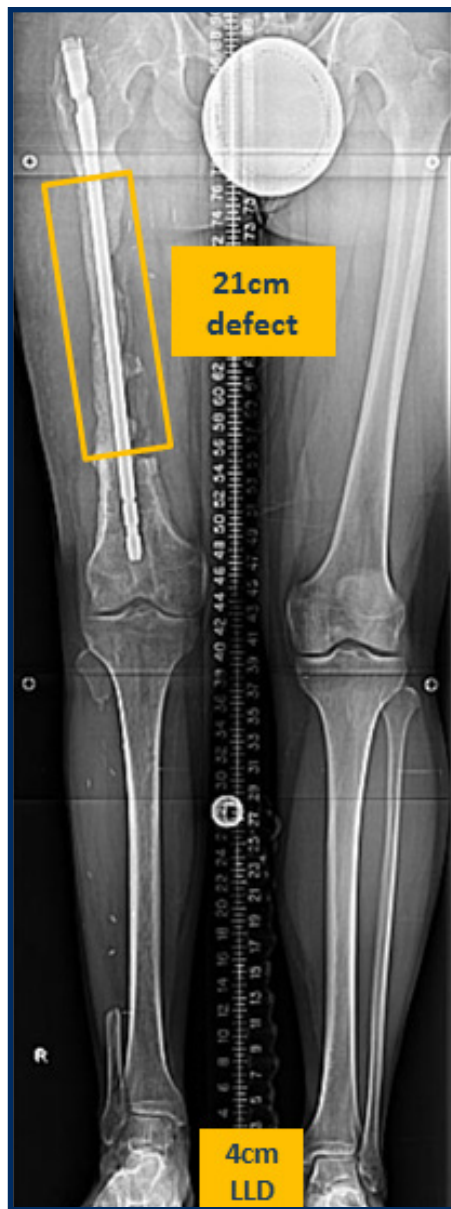

Figure 1 – Preoperative x-ray showing a 21cm femur defect spanned with IM rod and cement plus additional LLD of 4cm.

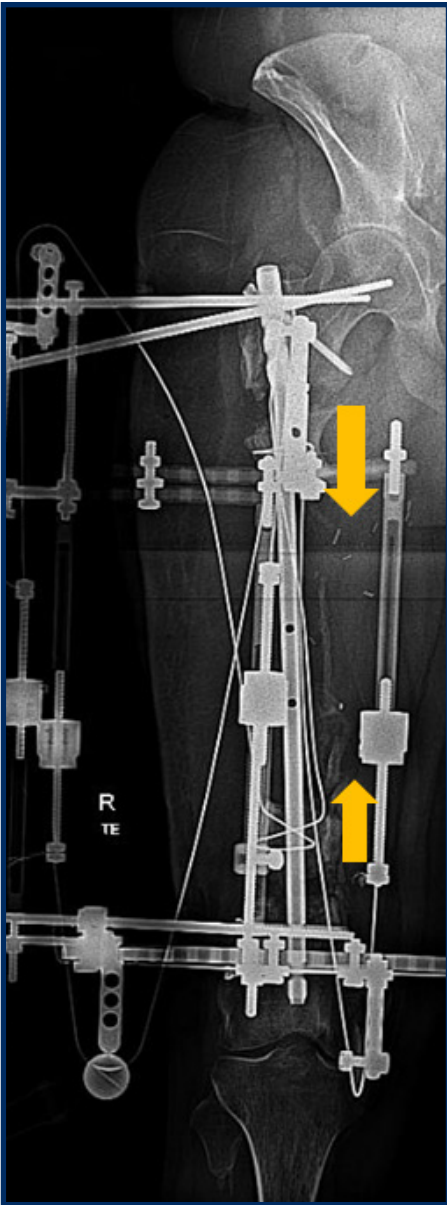


Figure 2 – Femur x-ray showing bone transport with cable wires and pulleys.

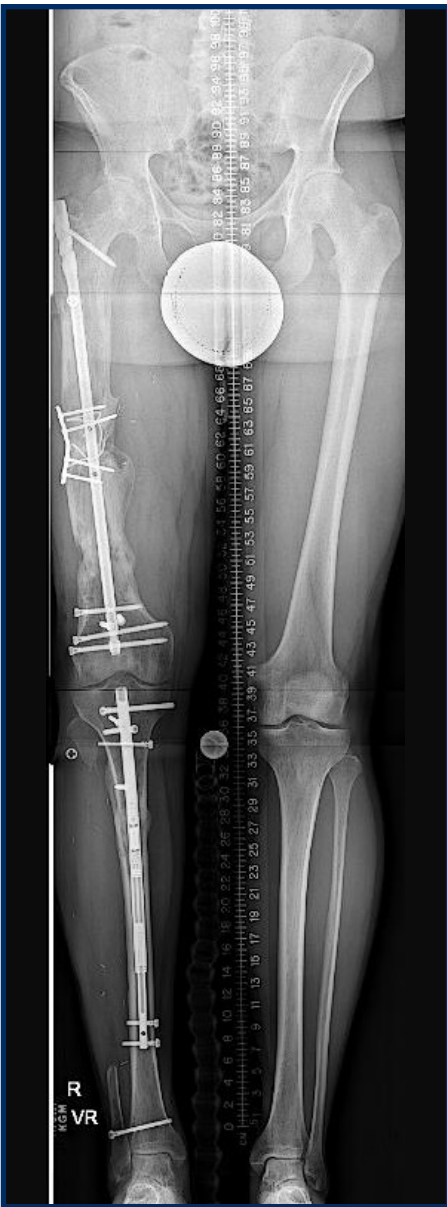

Figure 3 – Follow-up standing x-ray showing equal leg lengths following femur reconstruction and tibial lengthening with a motorized IM nail.

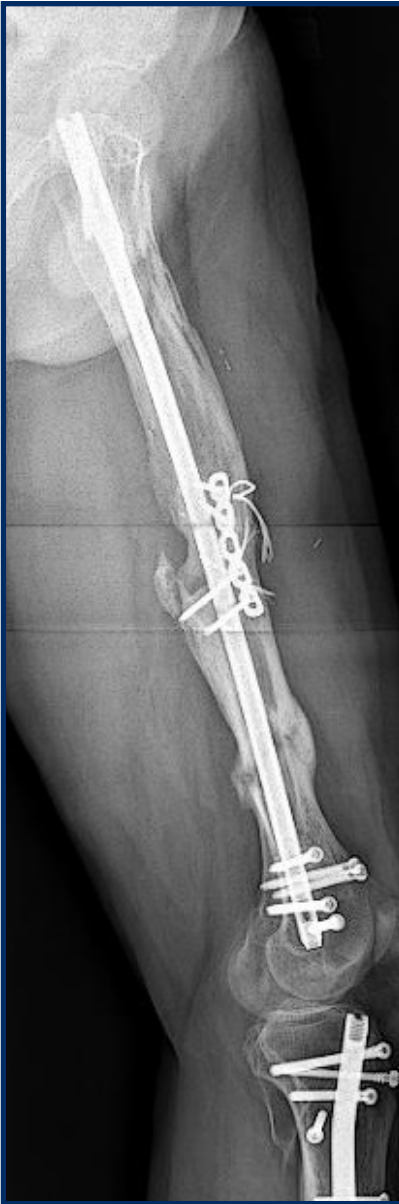

Figure 4 – Follow-up lateral x-ray of the femur showing bone union following trifocal bone transport.

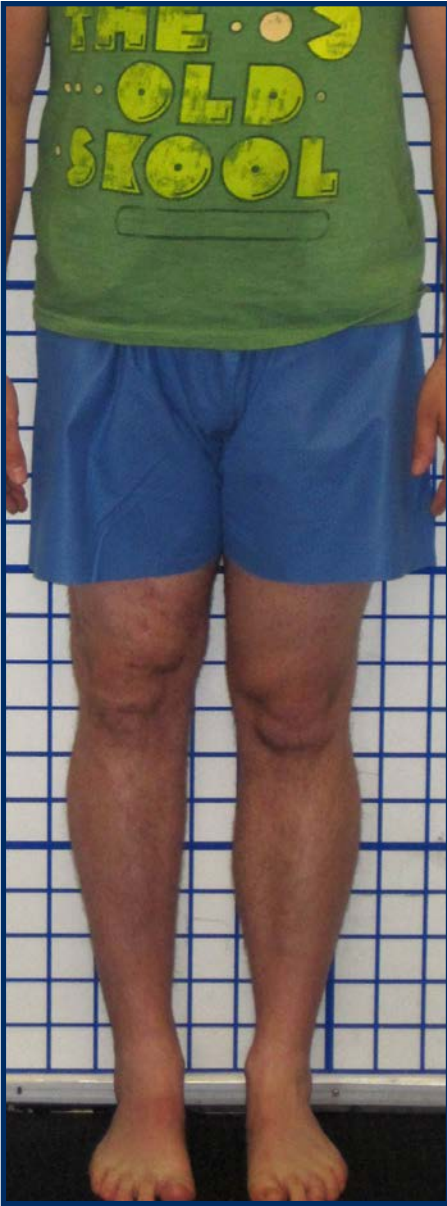

Figure 5 – Follow-up clinical photo showing normal alignment and equal leg lengths.