HOSPITAL FOR SPECIAL SURGERY

Grand Rounds from HSS

MANAGEMENT OF COMPLEX CASES

March 2016 | Volume 6 Issue 2

AUTHORS

Todd J. Albert, MD
Surgeon-in-Chief and Medical Director
Korein-Wilson Professor of
Orthopaedic Surgery
Hospital for Special Surgery
Chairman and Professor of
Orthopaedic Surgery
Weill Cornell Medicine

Federico P. Girardi, MD
Attending Orthopaedic Surgeon
Professor of Orthopaedic Surgery
Weill Cornell Medicine

Han Jo Kim, MD
Assistant Attending Orthopaedic Surgeon
Assistant Professor of Orthopaedic Surgery
Weill Cornell Medicine

CO-AUTHORS

Stelios Koutsoumbelis, MD
Orthopaedic Surgery Fellow
Spine Service
Hospital for Special Surgery

Craig D. Steiner, MD
Orthopaedic Surgery Fellow
Spine Service
Hospital for Special Surgery

From the Editor

Edward C. Jones, MD, MA

This volume of *Grand Rounds from HSS* offers three complex cervical spine cases successfully managed by HSS spine specialists. The evolution of evidence based medicine has no doubt guided and improved general medical care. But spine specialists are frequently challenged to treat patients with very complicated conditions for which there is no standard play-book prescription for effective care. Evident in these cases is the comprehensive knowledge, innovation and technical skill required to successfully manage these extremely disabling conditions.

In the first case, **Todd Albert** corrects a post-traumatic fixed spinal deformity with cervical spinal osteotomy and fusion. Dr. Albert's admonition that "an individualized approach with careful attention to the bony, neural, and vascular anatomy is necessary to optimize outcomes and minimize complications" applies to all cases in this series.

Next is **Federico Girardi's** case using anterior cervical decompression and fusion, followed by posterior spinal fusion, for the treatment of refractory idiopathic cervical dystonia. Spasmodic torticollis, the etiology usually enigmatic, is a perplexing problem that causes intolerable discomfort and disability. Dr. Girardi's multifaceted surgery exemplifies the systematic approach needed to effectively treat this condition.

In the third case, **Han Jo Kim** successfully reverses the overwhelming neurological deficit caused by basilar invagination in a patient with untreated rheumatoid arthritis. Seasoned orthopaedic surgeons will recall the constant concern for atlantoaxial instability in patients with rheumatoid arthritis before the advent of Disease-Modifying Anti Rheumatic Drugs. Now a rare occurrence, Dr. Kim surgically reestablished and stabilized this critical brainstem juncture, restoring limb function and sensation in a very grateful patient.

All volumes of *Grand Rounds from HSS* are available on **www.hss.edu/complexcases**, where you will find enlarged and additional images, references and links to related articles. We hope you find these cases to be of interest and the principles presented informative. Comments are always welcome at **complexcases@hss.edu**.

Edward C. Jones, MD, MA
Assistant Attending Orthopaedic Surgeon

In This Issue

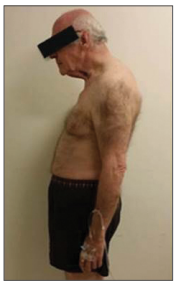

Case 1

Cervical Spinal Osteotomy for Treatment of Post-Traumatic Fixed Spinal Deformity

Case 2

Cervical Spine Fusion for the Treatment of Refractory Idiopathic Cervical Dystonia

Case 3

Surgical Treatment of Basilar Invagination Under the Setting of Progressive Quadriparesis

Case 1

Case presented by Craig D. Steiner, MD, Han Jo Kim, MD, and Todd J. Albert, MD

Cervical Spinal Osteotomy for Treatment of Post-Traumatic Fixed Spinal Deformity

Case Report A 71-year-old male presented for evaluation of progressive spinal deformity. He had, several years prior to presentation, fallen off of a cliff while climbing in the Himalayas. At that time he sustained a C5-C6 facet fracture dislocation without neurologic injury. The injury was managed conservatively, and after recovery he was able to return to work. Over the year prior to presentation, he noted progressive chin on chest deformity and an inability to maintain horizontal gaze for any length of time. His ambulatory tolerance became limited to less than a block secondary to neck pain, periscapular pain, fatigue, and paresthesias in the distal lower extremities during ambulation. He had no upper extremity neurologic complaints. He had failed conservative treatment.

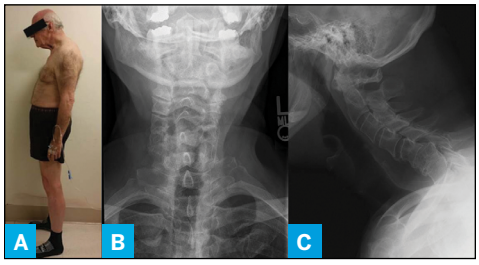

Figure 1

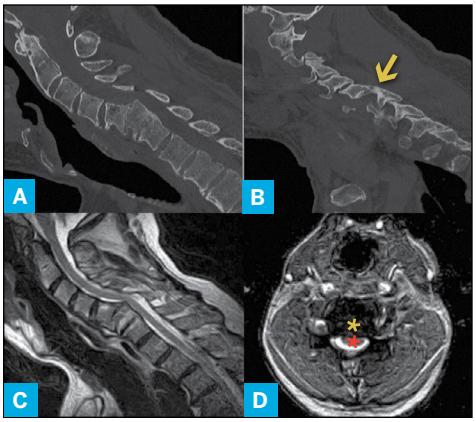

Figure 2

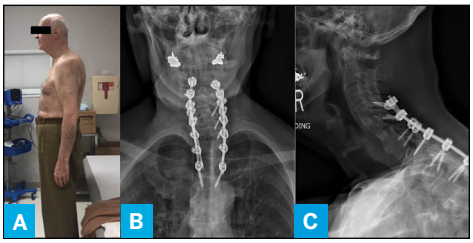

Figure 3

View enlarged images at
www.hss.edu/complexcases

On physical exam the patient had a cervicothoracic kyphotic deformity. He was unable to bring his gaze to horizontal (Figure 1a). He fatigued quickly while attempting to compensate for his deformity. He was able to ambulate a short distance without assistance. The patient had full motor strength throughout the bilateral upper and lower extremities. Sensation was slightly diminished, symmetrically, on the plantar aspects of both feet, otherwise preserved throughout. There were neither pathologic reflexes nor long tract signs on examination.

X-rays of the cervical spine demonstrated cervical kyphosis without coronal plane deformity (Figure 1b and 1c). The C5-C6 fracture dislocation had healed in a kyphotic orientation. CT imaging revealed fusion of C5-C7 with a fixed focal kyphosis of approximately 40° across those segments as well as fusion of the posterior elements of C5-C6 (Figure 2a and 2b). Sagittal T2 MRI demonstrated the spinal cord draped over the apex of the kyphus (Figure 2c). Axial MRI demonstrated loss of ventral CSF space and abutment of the cord (Figure 2d).

The patient, having failed conservative treatment, elected for surgical intervention. The surgical plan called for a posterior-anterior-posterior cervical osteotomy, decompression and cervicothoracic fusion undertaken in a single surgical session. With the patient in the prone position, the first stage included a posterior cervicothoracic approach. Posterior instrumentation was performed with lateral mass screws at C4 and C5, pedicle screws were used from C7-T5. Laminectomy was performed from C5-C7. A posterior column osteotomy was performed at C5-C6, completely releasing and partially resecting the fused posterior elements. Temporary skin closure was performed and the patient was turned supine. Anterior cervical discectomy and fusion using structural allograft was performed at the C4-C5 disc space. An anterior osteotomy was performed through the C5-C6 fusion mass to enable mobilization. The C5-C6 space was sequentially distracted and a large structural allograft was placed. The anterior wound was closed in the standard manner and the patient was turned prone for the final stage. The C5-C6 posterior osteotomy was completely closed down as a result of the correction. Rods were placed and posterior arthrodesis was performed from C4-T5.

Figure 1: Clinical photograph (a), anterior-posterior and lateral radiographs demonstrating post-traumatic kyphotic cervical spine deformity (b and c).

Figure 2: Sagittal CT demonstrating C5-C6 listhesis, and fusion anterior across C5-C7 (a), as well as fusion across the posterior elements at C5-C6 (b, arrow). Sagittal MRI demonstrating cord draped over deformity (c) and axial MRI at the apex demonstrating loss of ventral CSF signal and abutment of the cord (red asterisk) against the bony apex of the deformity (yellow asterisk) (d).

Figure 3: Postoperative clinical photo demonstrating improvement of the deformity and restoration of horizontal gaze (a). Postoperative radiographs (b and c).

Postoperative radiographs demonstrated a correction of the focal kyphosis by 42° and restoration of overall cervical alignment from 22° of kyphosis to 17° of lordosis (Figure 3c). Clinically, the patient was able to walk upright without limitation, and maintain horizontal gaze indefinitely without discomfort (Figure 3a).

Discussion Cervical deformities requiring surgical treatment are relatively uncommon compared to those in the thoracolumbar region. They are often, however, quite debilitating and significantly affect quality of life. The patient was fortunate at the time of the initial trauma in that he avoided a catastrophic spinal cord injury and healed uneventfully. Over time, however, the compensatory mechanisms fail due to excessive energy expenditure and the muscles are exhausted, resulting in progressive deformity and impaired function.

Osteotomies for cervical deformity correction can be performed anteriorly, posteriorly, or utilizing combined approaches. A comparison of cervical osteotomy techniques found anterior osteotomy in combination with a posterior column osteotomy provided equivalent correction to pedicle subtraction osteotomy (PSO) with less blood loss and equivalent operative time [1]. Cervical PSOs are typically performed at the C7 level, where

Continued on page 4

Case 2

Case presented by Stelios Koutsoumbelis, MD, and Federico P. Girardi, MD

Cervical Spine Fusion for the Treatment of Refractory Idiopathic Cervical Dystonia

Case Report A 41-year-old female presented with a 2.5 year history of neck pain, discomfort in her shoulders and severe neck dystonia with fixed kyphosis. The symptoms began after an atraumatic neck muscle strain; she felt a pulling in the neck that was followed by awaking the following morning with her neck in a rigid forward flexed position. The patient has been unable to correct he neck position since then. She had been seen by multiple physicians and had undergone unsuccessful Botox injections and manipulations under anesthesia.

The patient complained primarily of neck pain, but also had pain that radiated to both shoulders and scapulae. She also experienced thoracic spine pain and recurrent headaches. Her neck was flexed forward and rotated toward the right shoulder and she was unable to hold her head in a functional position. She reported her pain to be 7/10. The patient was able to sit up in a chair, but could not lie in the supine position. Her symptoms were aggravated by prolonged sitting, walking, bending and pushing objects; persistent pain and disability that made activities of daily living intolerable. The patient denied any history of trauma to the neck, head, or shoulders. She had also never been treated for psychiatric disorder, nor had she ever taken any psychotropic medications or illicit drugs.

On physical exam the patient stood with a significant cervical, chin on chest, deformity. She was unable to lift her chin unassisted. Her gait was normal and she had intact balance and proprioception. The patient was neurologically intact with no focal motor or sensory deficits. Long track signs, including Babinski's and Hoffman's, Spurling's and Lhermitte's, were negative.

Radiographs revealed rigid cervical kyphosis from C2 to C7 with significant angulation involving the occipitocervical area (Figure 1). Full length standing radiographs demonstrated the chin on chest deformity and CT imaging showed the fixed C1-C2 deformity (Figure 2). MR imaging and myelogram were performed and revealed no abnormalities or significant cord signal changes.

The patient underwent an anterior cervical decompression and fusion (ACDF) from C3 to T2, followed by a posterior spinal fusion from the occiput to T2 with use of iliac crest bone autograft. This surgery was done in one sitting. During the procedure, the patient also underwent a tenotomy of the right sternocleidomastoid. Postoperatively she was placed in a rigid cervical orthosis and transitioned to a soft collar after two weeks. At 3 months the patient reported that her overall preoperative symptoms had improved by 60% and at 6 months her neck pain had improved by 90% and overall alignment by 95%. Postoperative x-rays show successful fusion with restored neck alignment (Figure 3).

Discussion Cervical dystonia (CD), also called spasmodic torticollis, is the most common of the focal dystonias [1]. In CD, the muscles in the neck that control the position of the head are affected, causing the head to turn to one side or be pulled forward or backward [1, 2]. Cervical dystonia can occur at any age, although most individuals first experience symptoms in middle age [1, 2]. Females are 1.5 times more likely to develop spasmodic torticollis than males [1]. Worldwide, the incidence rate of CD is at least 1.2 per 100,000 person years, at a prevalence rate of 57 per 1 million [3]. It often begins slowly and usually reaches a plateau over a few months or years. About 10 percent of those with torticollis may experience a transient, spontaneous remission, but this usually does not last and there is recurrence [2, 3]. Trauma to the neck, head, or shoulder can also precede the onset of CD; none of which were reported by this patient. Treatment with certain anti-psychotic medications and the abuse of illicit psychotropic agents can also induce CD, again not reported in this case. Treatment for CD can range from stretching, Botox injection and Deep Brain stimulation. Surgical correction is usually indicated to treat rigid deformities, including cervical kyphosis and atlantoaxial rotatory instability [4, 5]. Presented here is a case of idiopathic cervical dystonia that led to muscular torticollis, rotatory instability, and chronic fixed cervical deformity.

This case illustrates the multifaceted approach necessary to treat refractory cervical dystonia with concomitant rigid cervical kyphosis, in the face of

Continued on page 4

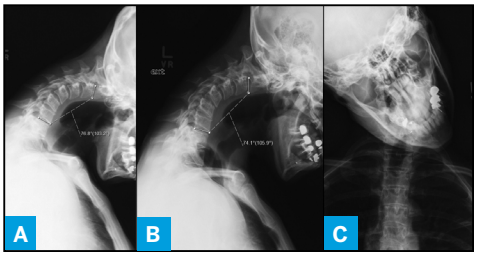

Figure 1: Lateral (a), and extension (b) cervical spine X-rays demonstrating fixed cervical kyphosis measuring 77 and 74 degrees respectively. Anterior-posterior x-ray (c) shows fixed rotatory occipital cervical deformity.

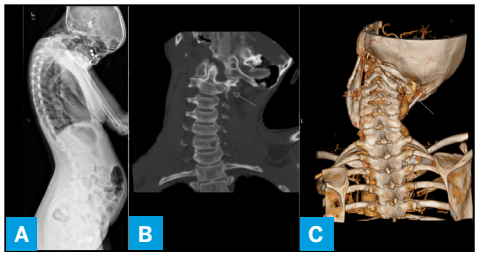

Figure 2: Lateral scoliosis x-ray demonstrating chin-on-chest deformity (a). CT coronal imaging (b) and a 3D reconstruction (c), viewed from behind, illustrating right C1-C2 fixed deformity and atlantoaxial rotatory instability.

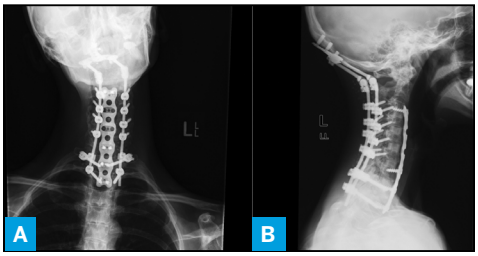

Figure 3: Anterior-posterior (a) and lateral (b) radiographs after anterior-posterior spinal fusion and right sternocleidomastoid tenotomy.

View enlarged images at **www.hss.edu/complexcases**

Case 3

Case presented by Stelios Koutsoumbelis, MD, and Han Jo Kim, MD

Surgical Treatment of Basilar Invagination Under the Setting of Progressive Quadriparesis

Case Report A 49-year-old female presented with acute quadriparesis. The patient had a history of long standing rheumatoid arthritis for which she had not had medical treatment. In the weeks preceding presentation she had an evolving neurologic decline; at the time of first evaluation she had been quadriplegic for three weeks.

On physical exam, the patient was markedly short in stature; she had obvious gross deformity in all extremities, and diffuse muscle wasting. Her muscle grade was 0/5 in all extremities and she was unable to shrug her shoulders. Light touch was diminished or absent in all extremities. The patient had lost bladder function; however, bowel function was intact per report. Although weak, rectal tone was present and perineal sensation was diminished.

The patient was initially placed in halo traction, gradually increased over 4 days to 40lbs. After traction, the patient's physical exam improved. Eventually, bilateral deltoid and biceps muscle strength improved to 2-3/5. She was able to shrug her shoulders, and sensation was completely restored. However, this interval of traction did not restore the patient's lower extremity motor function.

Lateral C-Spine radiographs were taken pre and post halo distraction (Figure 1). MRI revealed diffuse cervical stenosis and basilar invagination to the pontine-medullary junction (Figure 2). CT arteriogram of the neck showed an aberrant vertebral artery on the left (Figure 2). There was complete obliteration of the C1 lateral mass, resulting in the occipital condyle articulating directly onto C2 (Figure 2).

After approximately one week of traction the patient's condition stabilized, was felt to be optimized, and she was medically cleared for surgery. The patient was taken to the operating room and underwent an occiput to T5 posterior spinal fusion. Laminectomy of C1 and C3 to C6 was performed, utilizing a posterior distraction technique, originally described by Goel [3] (Figure 3). Post-operatively the patient was placed in a rigid cervical orthosis and closely monitored. During her three week post-operative hospitalization she had dramatic improvement in motor strength, as well as return of lower extremity function. Post-operative imaging confirmed reduction of the basilar invagination and decompression of the brainstem and cervical spine (Figure 4). With physical therapy, the patient was able to perform assisted transfers and was discharged to a regional spinal cord injury rehab facility.

At two month follow up the patient was able to stand with a walker with one person assistance and had marked neurologic improvement. She was very pleased with her recovery and felt she was continuing to improve. X-rays were taken at this visit (Figure 5).

Discussion Basilar invagination is a rare clinical condition characterized by upward protrusion of the odontoid process into the foramen magnum, leading to bulbo-medullary compression. This is often encountered in adults with rheumatoid arthritis [1,2]. Patients frequently present with neurologic symptoms and deficits, and warrant surgical treatment to prevent progression. Debate over surgical approach and technique has been described in the literature; that being either anterior trans-oral or endoscopic

Continued on page 4

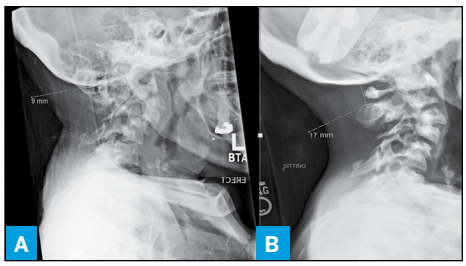

Figure 1

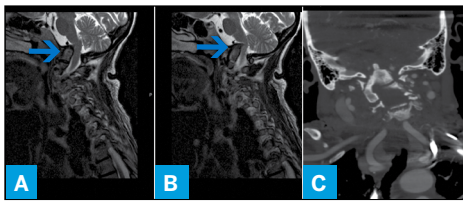

Figure 2

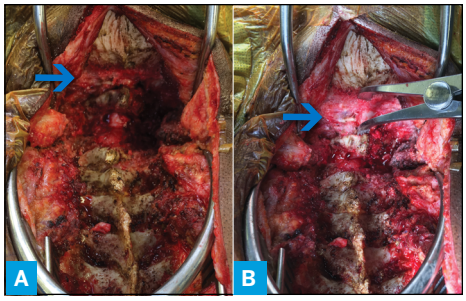

Figure 3

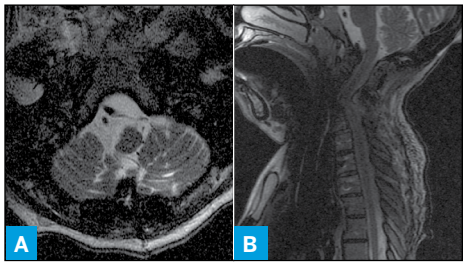

Figure 4

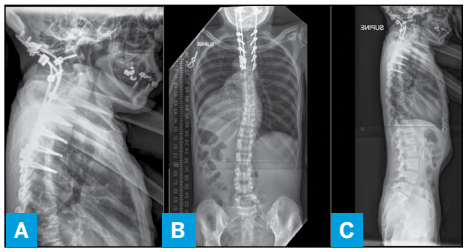

Figure 5

Figure 1: Lateral C-Spine x-rays: (a) on initial presentation and b) following halo traction, gradually increased to 40lbs. Basilar invagination and loss of cervical alignment are evident (a), as well as diffuse changes resulting from severe inflammatory (rheumatoid) arthritis.

Figure 2: MRI demonstrating basilar invagination, and compression onto the medulla with subaxial cervical spinal stenosis (a and b, blue arrows). CTA of the neck showing an aberrant left vertebral artery and coronal plane images demonstrated erosion of the C1 lateral mass on that side (c).

Figure 3: Intraoperative photo before (a) and after (b) application of posterior distraction (blue arrows). Laminar spreader is placed on base of skull and superior aspect of the C2 lamina, C1 arch has been removed.

Figure 4: Post-operative T2 MRI sagittal (a) and axial (b) select cuts confirming reduction of the basilar invagination and decompression of the brainstem and cervical spine.

Figure 5: Lateral C-spine (a); anterior-posterior (b) and lateral scoliosis (c) radiographs two months following surgery. Due to the erosion of the lateral masses from the patient's inflammatory arthritis, C2 translaminar fixation and pedicle screws were utilized.

View enlarged images at **www.hss.edu/complexcases**

Case 1 Continued

the vascular and neuroanatomy are more favorable [2]. A C7 PSO in this patient would correct global alignment but would not have addressed the focal deformity nor provide decompression at that level. An anterior-posterior approach is frequently an option for cervical deformity correction [3]. In the current case, fusion of the posterior elements necessitated a dedicated initial posterior column osteotomy to both allow and create space for the anterior corrective maneuver as well as to decompress and decrease the risk to the cord upon correction.

This case illustrates the management of a focal post-traumatic cervical kyphosis. Cervical deformity surgery is technically challenging and can result in significant complications [4]. An individualized approach with careful attention to the bony, neural, and vascular anatomy is necessary to optimize outcomes and minimize complications. ■

REFERENCES:

1. Kim HJ, Piyaskulkaew C, Riew KD. Comparison of Smith-Petersen osteotomy versus pedicle subtraction osteotomy versus anterior-posterior osteotomy types for the correction of cervical spine deformities. *Spine (Phila Pa 1976)* 2015;40:143-146.
2. Wollowick AL, Kelly MP, Riew KD. Pedicle subtraction osteotomy in the cervical spine. *Spine (Phila Pa 1976)* 2012;37:E342-E348.
3. Kim HJ, Piyaskulkaew C, Riew KD. Anterior cervical osteotomy for fixed cervical deformities. *Spine (Phila Pa 1976)* 2014;39:1751-1757.
4. Smith JS, Ramchandran S, Lafage V, et al. Prospective multicenter assessment of early complication rates associated with adult cervical deformity surgery in 78 patients. *Neurosurgery* In press. PMID 26595429

AUTHOR DISCLOSURES:

Dr. Craig D. Steiner does not have a financial interest or relationship with the manufacturers of products or services.

Dr. Han Jo Kim does not have a financial interest or relationship with the manufacturers of products or services.

Dr. Todd J. Albert does not have a financial interest or relationship with the manufacturers of products or services.

Case 2 Continued

neuromuscular pathology. Proper patient selection, consultation with pain management and neurology, and realistic patient expectations are crucial to successful and sustained correction of CD with rigid cervical deformity. ■

REFERENCES:

1. Dystonias fact sheet. National Institute of Neurological Disorders and Stroke. http://www.ninds.nih.gov/disorders/dystonias/detail_dystonias.htm. Accessed Jan 20, 2016.
2. Geyer HL, Bressman SB. (2006). The diagnosis of dystonia. *The Lancet Neurology* 5 (9): 780–790. doi:10.1016/S1474-4422(06)70547-6.
3. Claypool DW, Duane DD, Ilstrup DM, Melton LJ (September 1995). Epidemiology and outcome of cervical dystonia (spasmodic torticollis) in Rochester, Minnesota. *Mov. Disord.* 10 (5): 608–14. doi:10.1002/mds.870100513. PMID 8552113.
4. Brashear A. (2004). Treatment of cervical dystonia with botulinum toxin. *Operative Techniques in Otolaryngology—Head and Neck Surgery* 15 (2): 122–7. doi:10.1016/j.otot.2004.03.004.
5. Wang et al. (2015) Atlantoaxial Rotatory Fixed Dislocation: Report on a Series of 32 Pediatric Cases. *Spine (Phila Pa 1976)* 2015 Dec 24 [Epub ahead of print]

AUTHOR DISCLOSURES:

Dr. Stelios Koutsoumbelis does not have a financial interest or relationship with the manufacturers of products or services.

Dr. Federico P. Girardi does not have a financial interest or relationship with the manufacturers of products or services.

Case 3 Continued

trans-nasal for direct ventral decompression, verses posterior decompression and cervical distraction to indirectly decompress the brain stem and foramen magnum [1].

While direct ventral decompression may be necessary for basilar invagination that cannot be reduced with cervical traction, posterior cervical stabilization is always necessary afterwards [1, 2]. This case exemplifies an all posterior approach that adequately decompresses the ventral brain stem, while allowing for solid posterior stabilization in the same setting. Originally described by Goel et al. [3], an atlantoaxial facet distraction technique can be used for the surgical treatment of reducible basilar invagination. In Goel's description, the facets are distracted and intra-articular wedges are placed, followed by direct articular joint atlantoaxial fixation. In this case, the authors modified this technique because of the patient's anatomy; C1 stenosis, and anomalous unilateral vertebral artery. After the atlantoaxial capsules were released to provide mobility, distraction was applied from the base of the skull to C2. Fluoroscopic views were then used to confirm reduction of the odontoid. More importantly, in this case, the technique utilized compression and distraction of the posterior instrumentation to control the dens in the flexion/extension plane, allowing the authors to achieve necessary indirect ventral decompression of the brainstem.

In addition to the progressive neurological deficit found with basilar invagination, there is also a sequence of long-standing musculoskeletal changes that ensue. Short neck, exaggerated neck lordosis, torticollis, cervical spondylotic changes and spontaneous fusions are all commonly seen [4]. With appropriate surgical decompression and stabilization, as seen here, both the neurologic recovery and the reversal of musculoskeletal changes can be profound.

With the advent of DMARDs (Disease-Modifying Anti Rheumatic Drugs) the incidence of devastating rheumatoid arthritis and the associated basilar invagination has dramatically decreased; making this once commonly encountered pathology for a spinal surgeon into a true rarity [5]. This case illustrates a systematic approach to the treatment of this uncommonly encountered pathology, with excellent outcome. ■

REFERENCES:

1. Chaudhry NS, Ozpinar A, Bi WL, Chavakula V, Chi JH, Dunn IF Basilar Invagination: Case Report and Literature Review. *World Neurosurg*. 2015 Jun;83(6):1180.e7-11. doi: 10.1016/j.wneu.2015.02.007.
2. Smith JS, Shaffrey CI, Abel MF, Menezes AH. Basilar invagination. *Neurosurgery*. 2010 Mar;66(3 Suppl):39-47.
3. Goel A. Progressive basilar invagination after transoral odontoidectomy: treatment by atlantoaxial facet distraction and craniovertebral realignment. *Spine (Phila Pa 1976)*. 2005 Sep 15;30(18):E551-5.
4. Goel A, Shah A. Reversal of longstanding musculoskeletal changes in basilar invagination after surgical decompression and stabilization. *J Neurosurg Spine*. 2009 Mar;10(3):220-7. doi: 10.3171/2008.
5. Ramiro S, Gaujoux-Viala C, Nam JL, Smolen JS, Buch M, Gossec L, van der Heijde D, Winthrop K, Landewé R. Safety of synthetic and biological DMARDs: a systematic literature review informing the 2013 update of the EULAR recommendations for management of rheumatoid arthritis. *Ann Rheum Dis*. 2014 Mar;73(3):529-35. doi: 10.1136/annrheumdis-2013-204575.

AUTHOR DISCLOSURES:

Dr. Stelios Koutsoumbelis does not have a financial interest or relationship with the manufacturers of products or services.

Dr. Han Jo Kim does not have a financial interest or relationship with the manufacturers of products or services.

Grand Rounds from HSS MANAGEMENT OF COMPLEX CASES

HOSPITAL FOR SPECIAL SURGERY

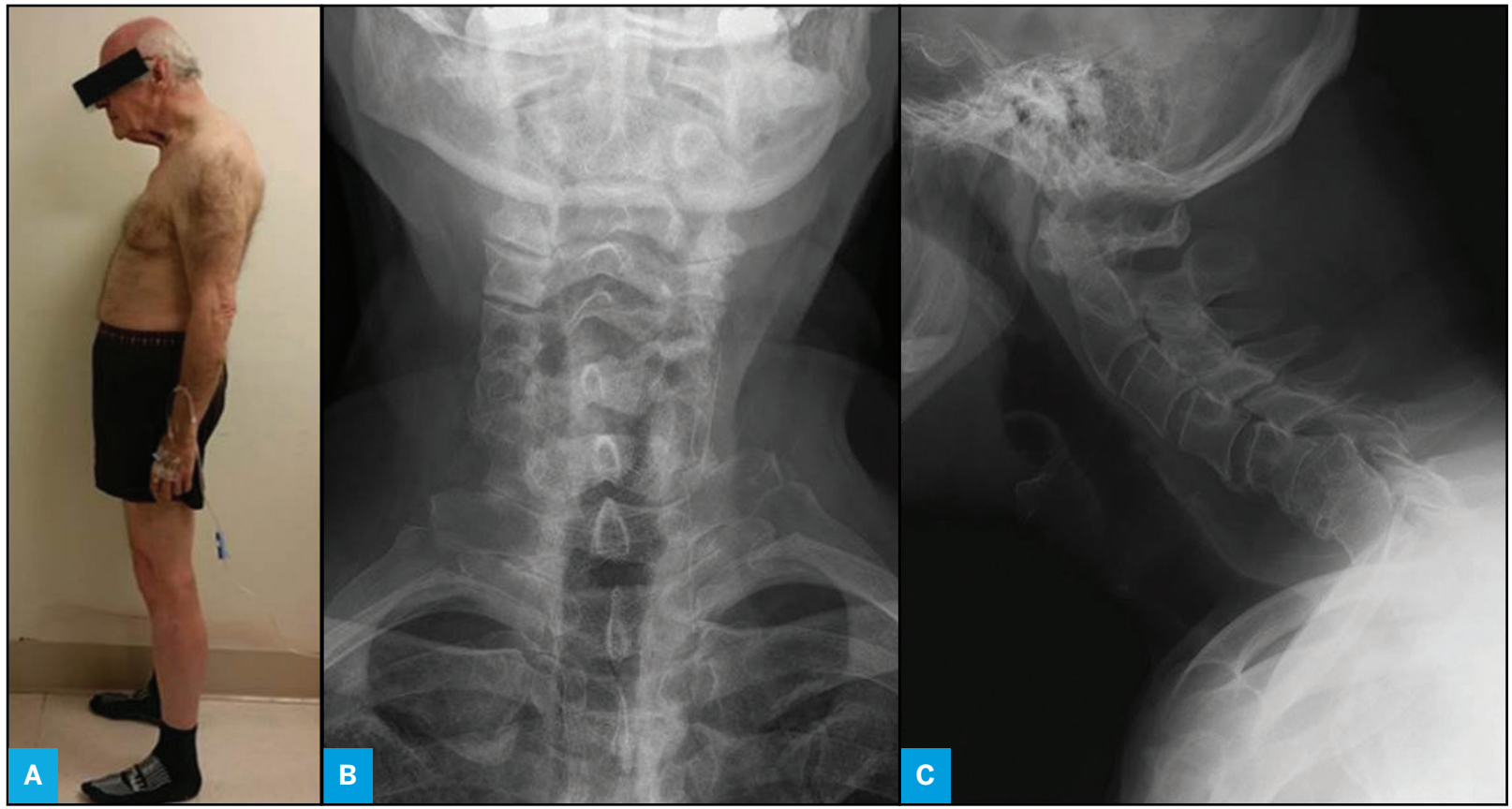

Figure 1: Clinical photograph (a), anterior-posterior and lateral radiographs demonstrating post-traumatic kyphotic cervical spine deformity (b and c).

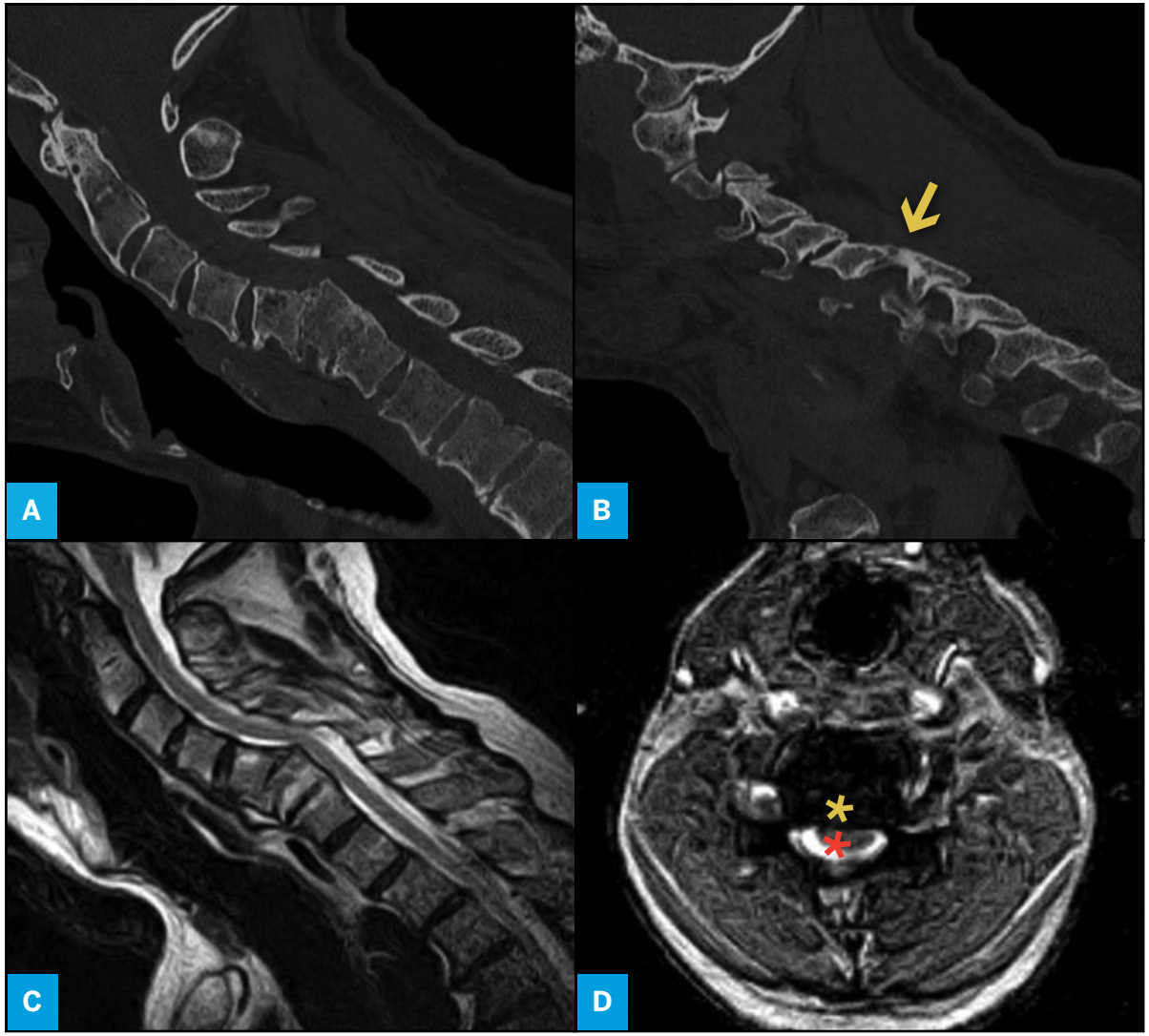

Figure 2: Sagittal CT demonstrating C5-C6 listhesis, and fusion anterior across C5-C7 (a), as well as fusion across the posterior elements at C5-C6 (b, arrow). Sagittal MRI demonstrating cord draped over deformity (c) and axial MRI at the apex demonstrating loss of ventral CSF signal and abutment of the cord (red asterisk) against the bony apex of the deformity (yellow asterisk) (d).

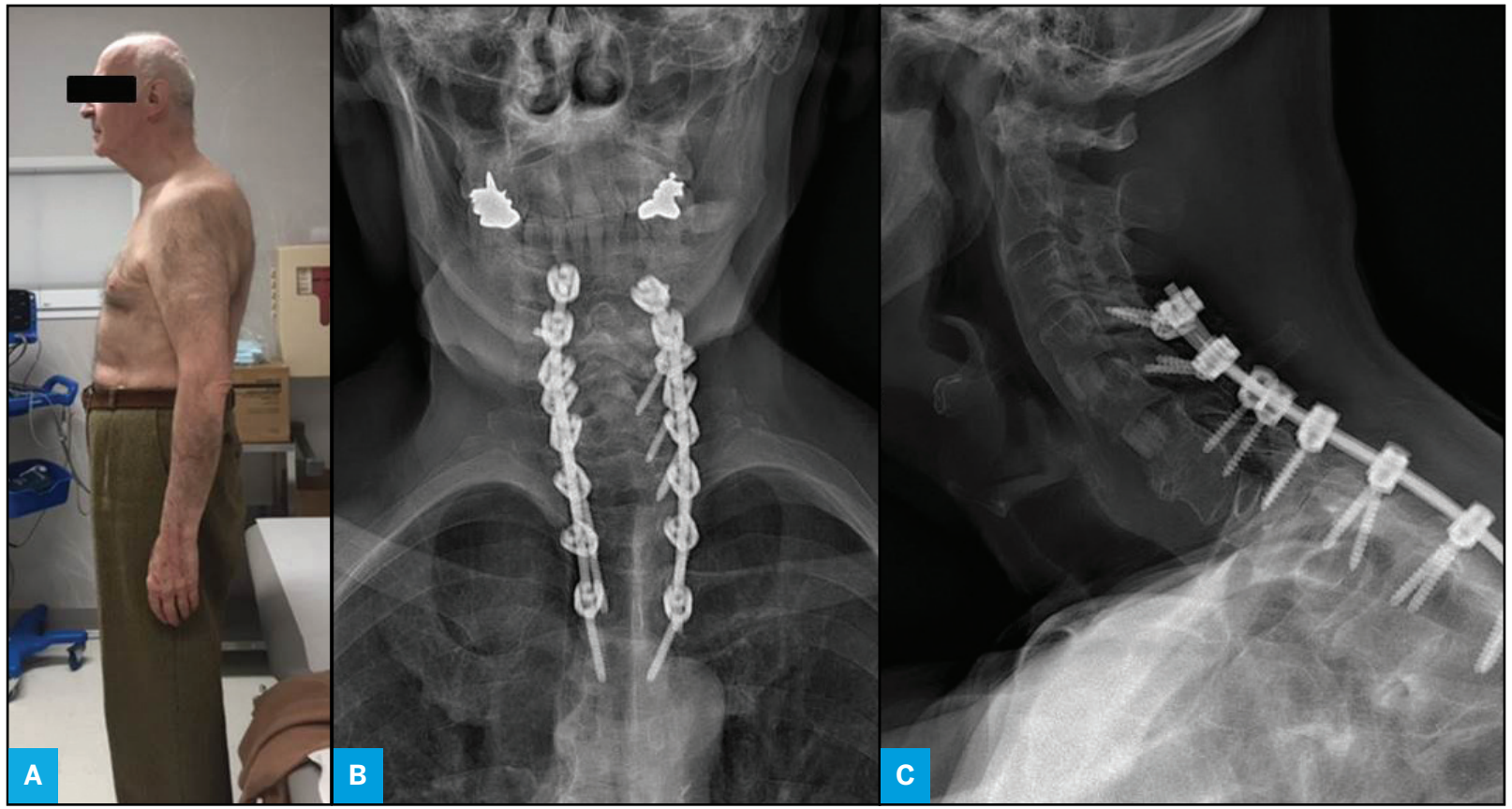

Figure 3: Postoperative clinical photo demonstrating improvement of the deformity and restoration of horizontal gaze (a). Postoperative radiographs (b and c).

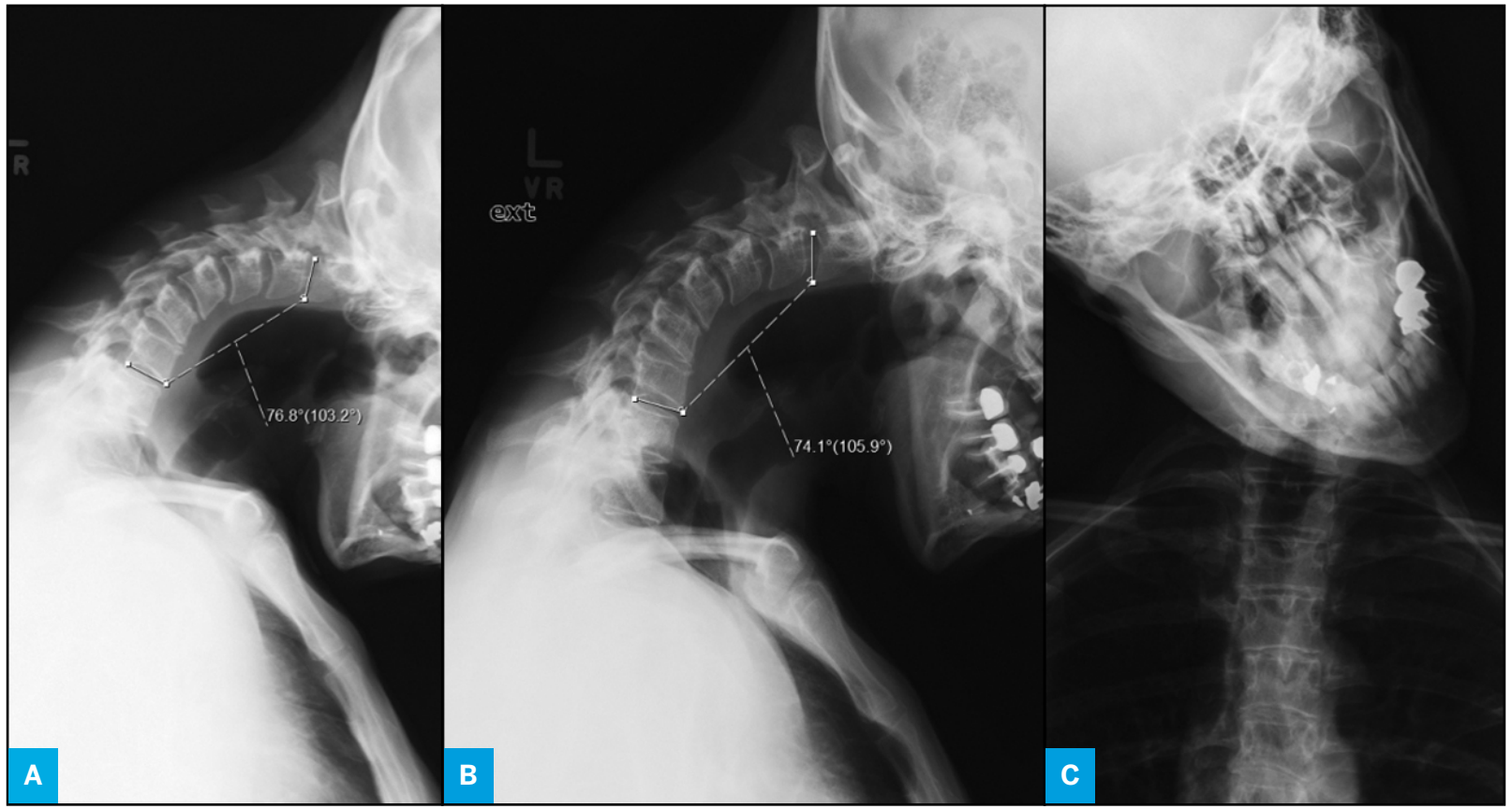

Figure 1: Lateral (a), and extension (b) cervical spine X-rays demonstrating fixed cervical kyphosis measuring 77 and 74 degrees respectively. Anterior-posterior x-ray (c) shows fixed rotatory occipital cervical deformity.

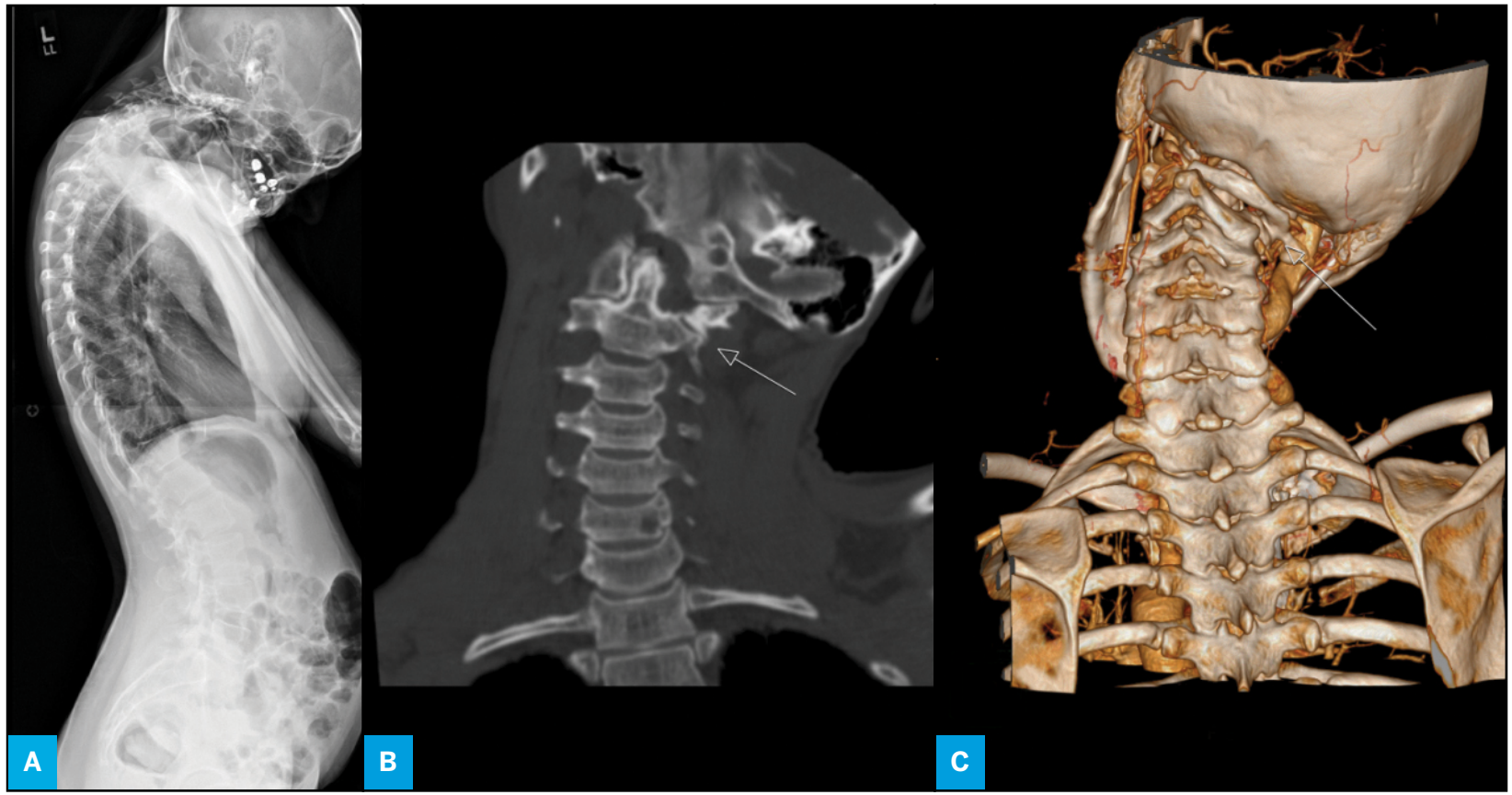

Figure 2: Lateral scoliosis x-ray demonstrating chin-on-chest deformity (a). CT coronal imaging (b) and a 3D reconstruction (c), viewed from behind, illustrating right C1-C2 fixed deformity and atlantoaxial rotatory instability.

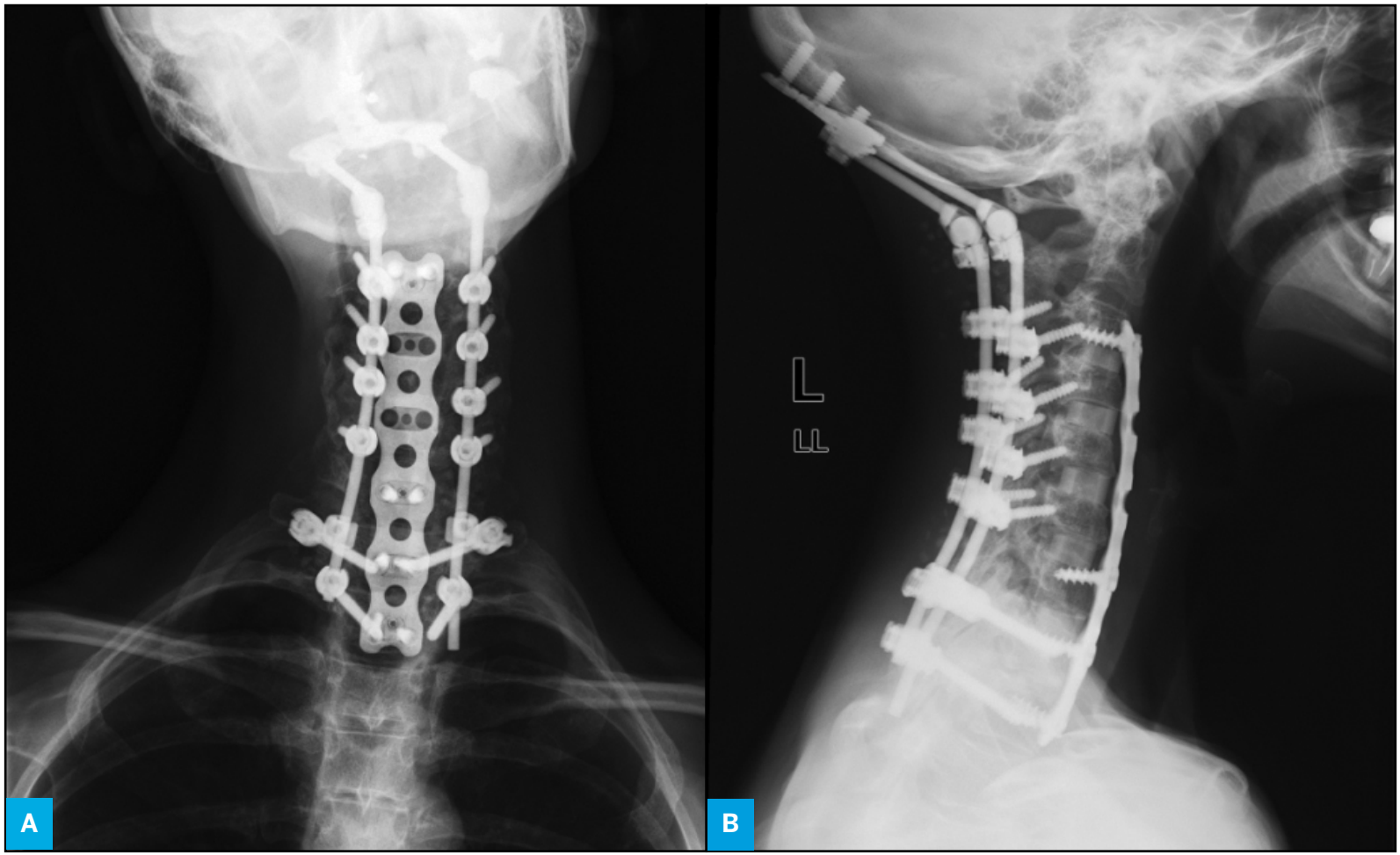

Figure 3: Anterior-posterior (a) and lateral (b) radiographs after anterior-posterior spinal fusion and right sternocleidomastoid tenotomy.

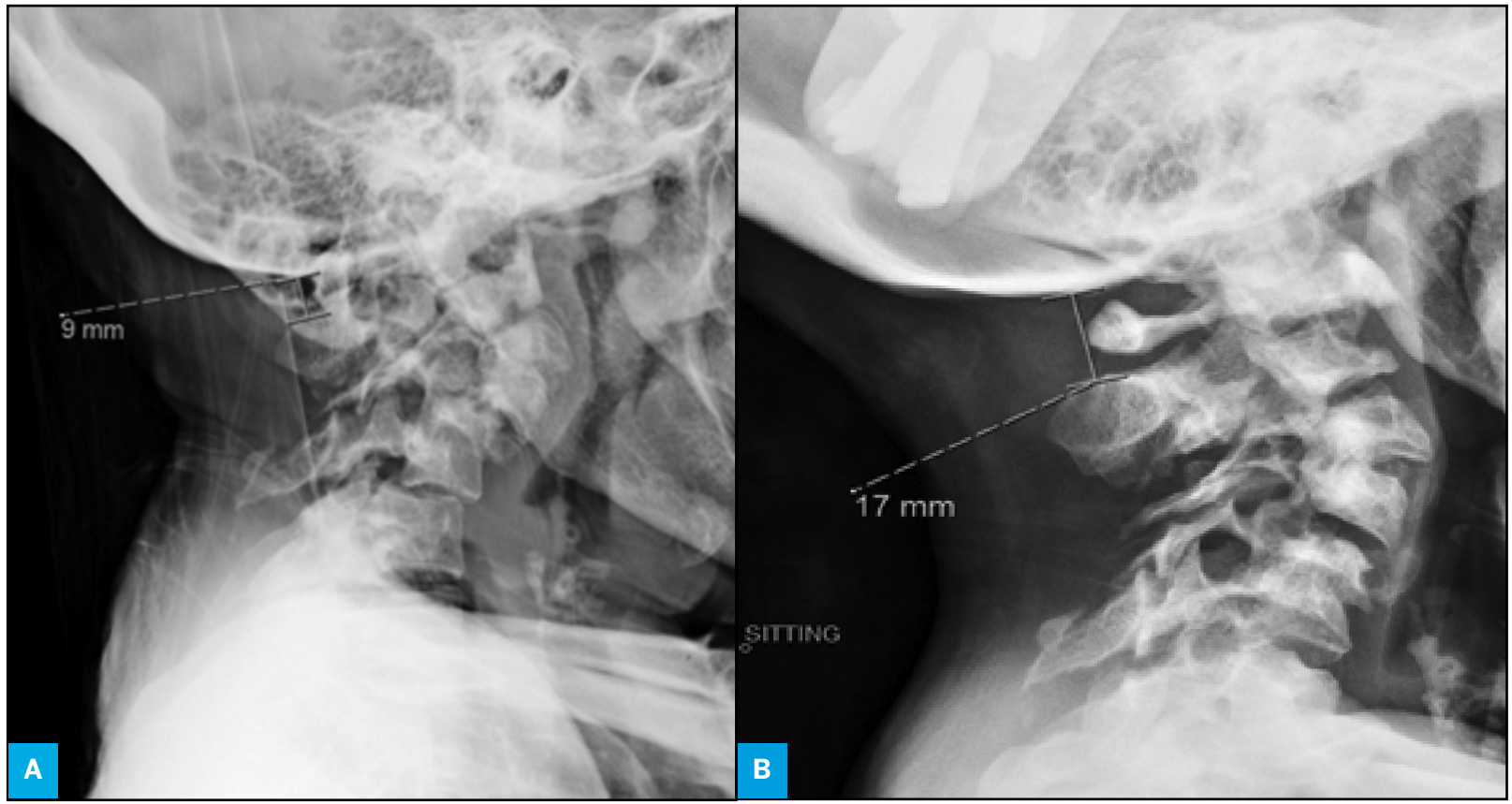

Figure 1: Lateral C-Spine x-rays: (a) on initial presentation and b) following halo traction, gradually increased to 40lbs. Basilar invagination and loss of cervical alignment are evident (a), as well as diffuse changes resulting from severe inflammatory (rheumatoid) arthritis.

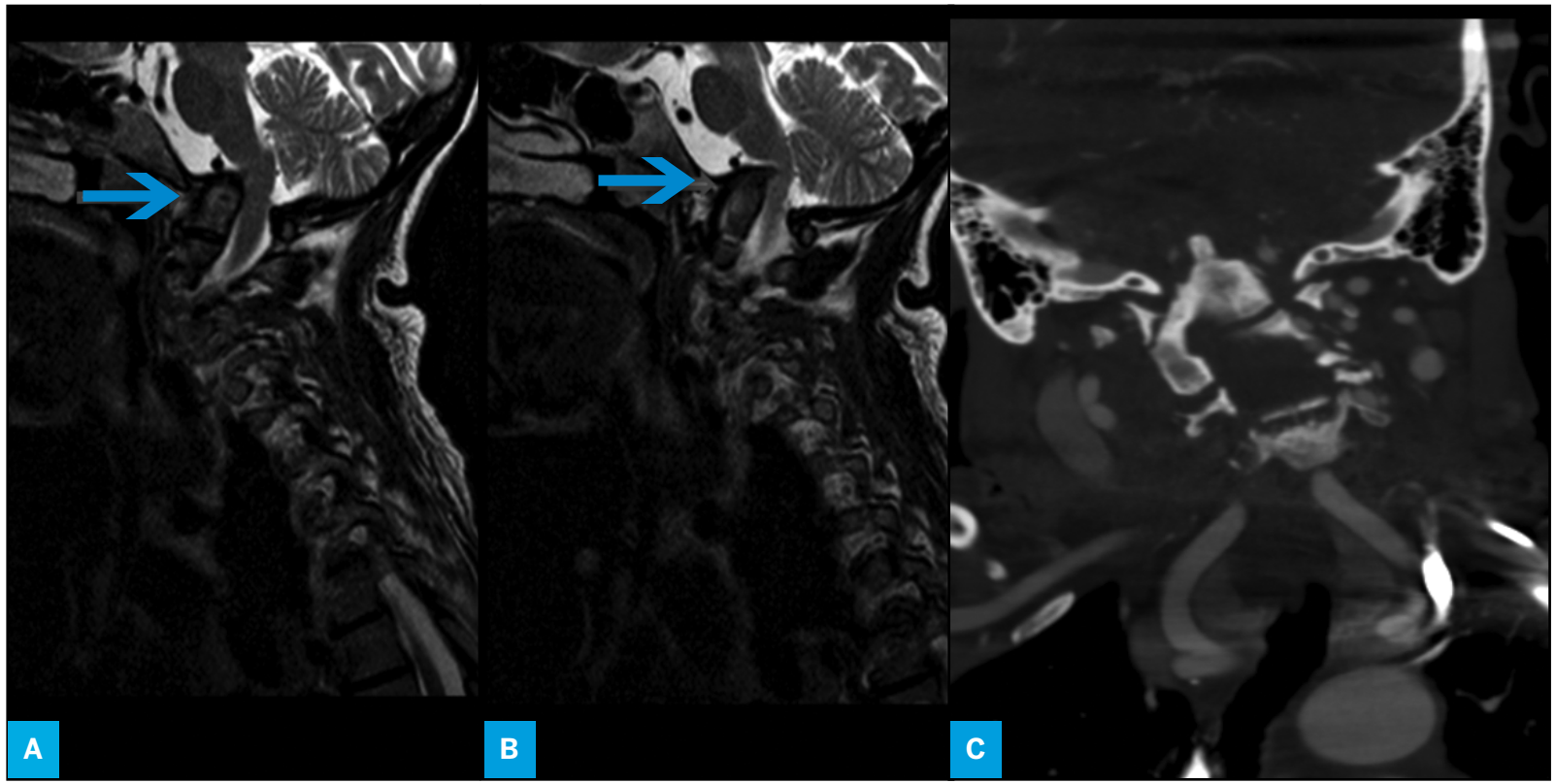

Figure 2: MRI demonstrating basilar invagination, and compression onto the medulla with subaxial cervical spinal stenosis (a and b, blue arrows). CTA of the neck showing an aberrant left vertebral artery and coronal plane images demonstrated erosion of the C1 lateral mass on that side (c).

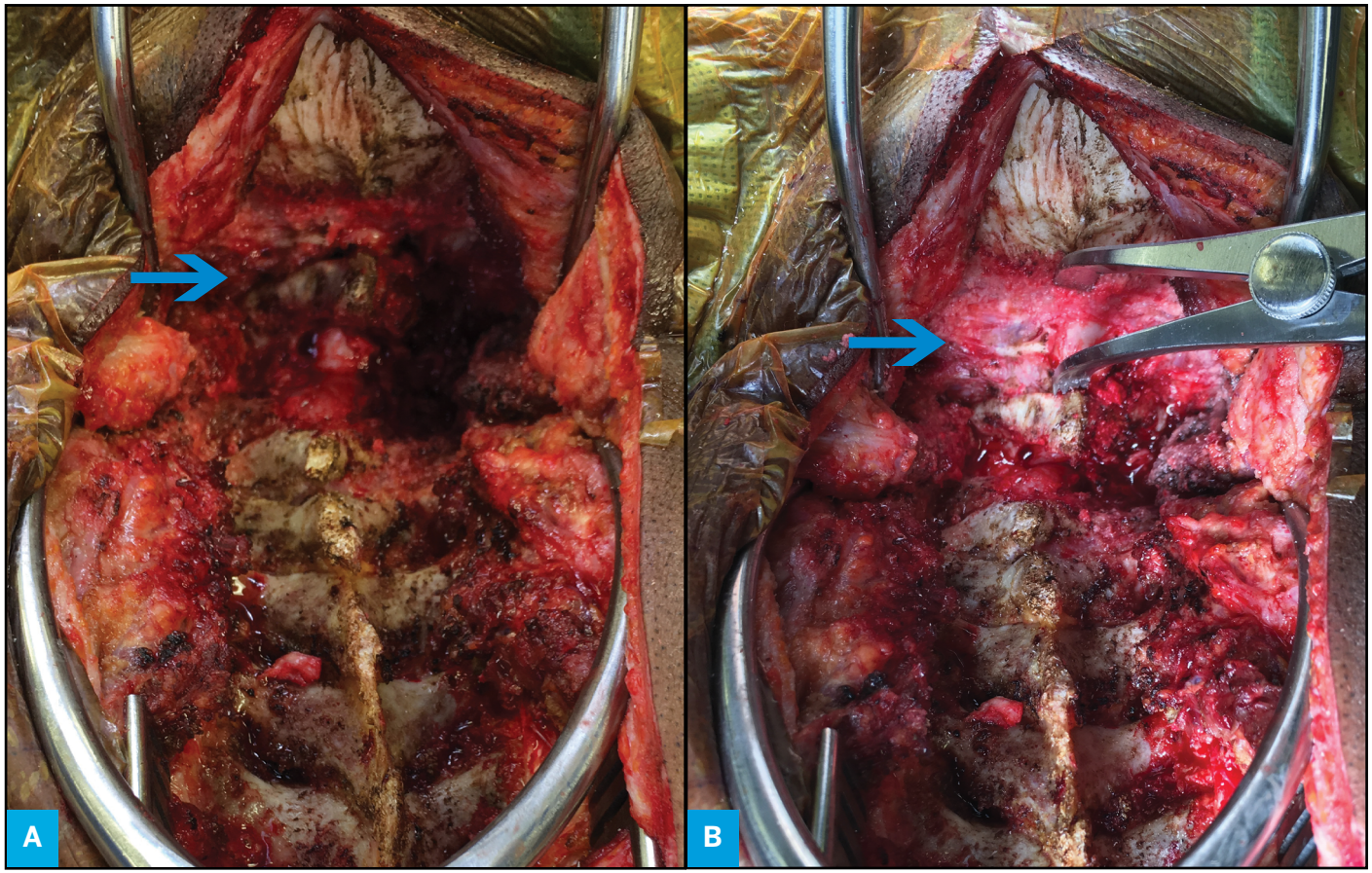

Figure 3: Intraoperative photo before (a) and after (b) application of posterior distraction (blue arrows). Laminar spreader is placed on base of skull and superior aspect of the C2 lamina, C1 arch has been removed.

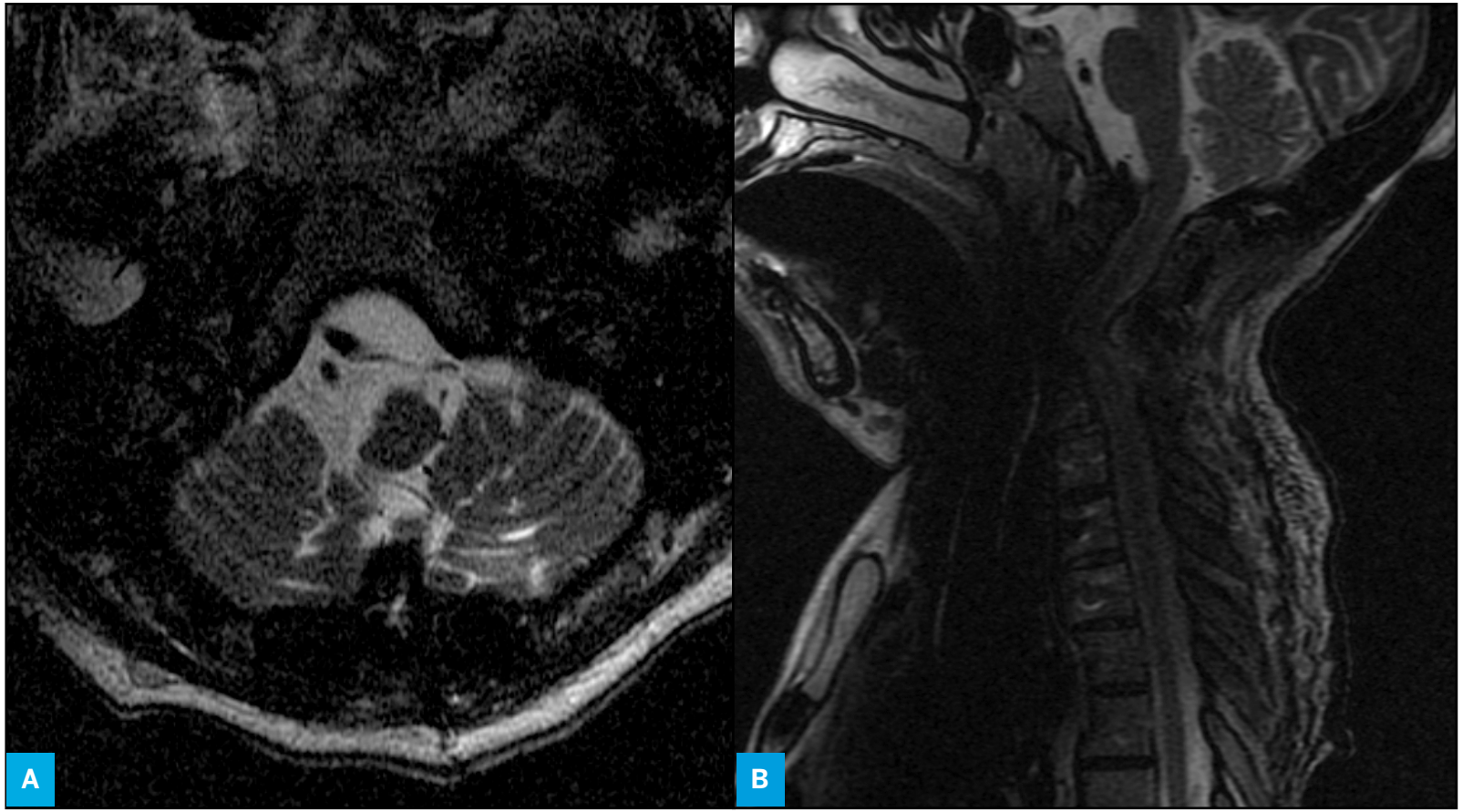

Figure 4: Post-operative T2 MRI sagittal (a) and axial (b) select cuts confirming reduction of the basilar invagination and decompression of the brainstem and cervical spine.

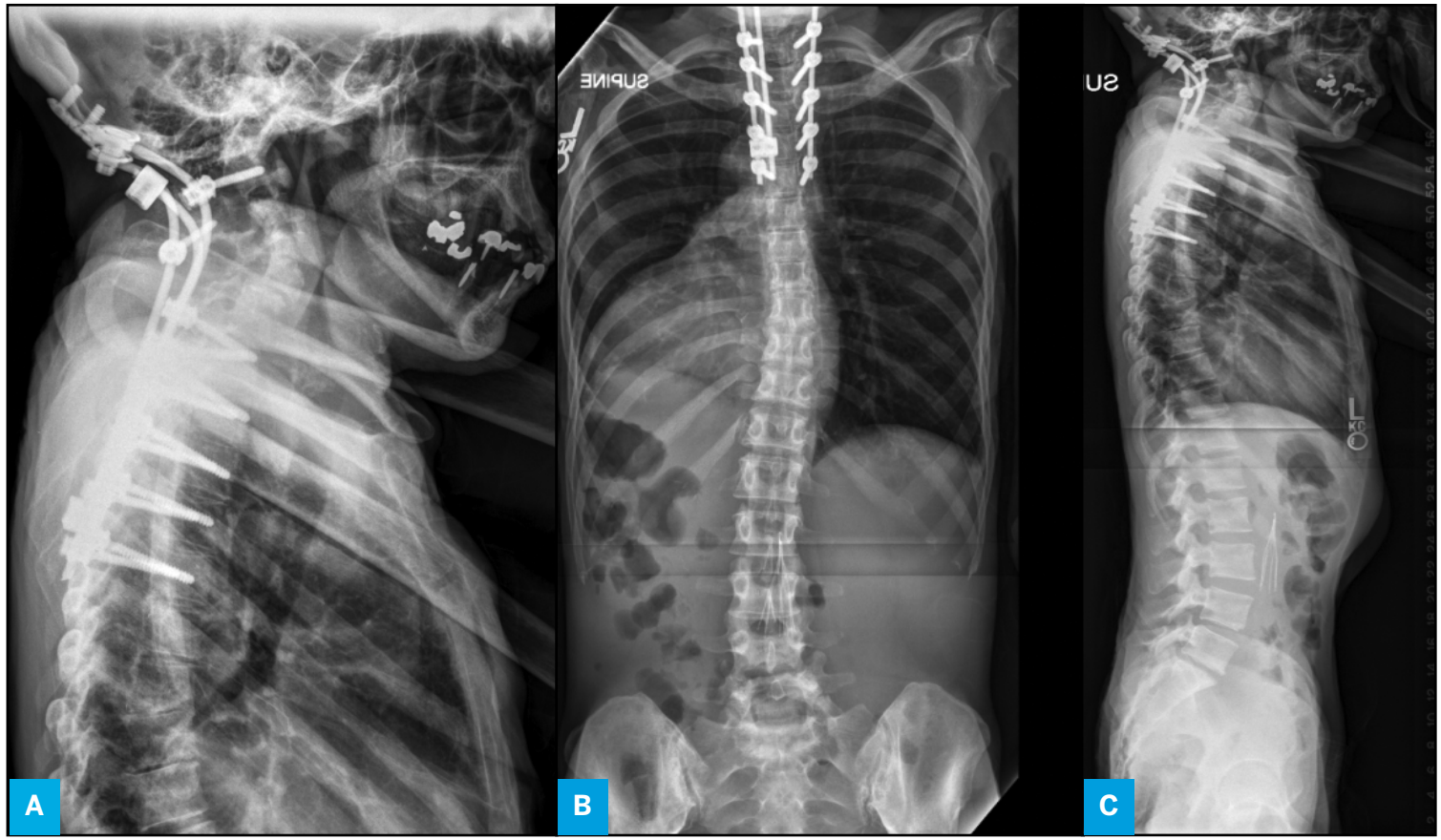

Figure 5: Lateral C-spine (a); anterior-posterior (b) and lateral scoliosis (c) radiographs two months following surgery. Due to the erosion of the lateral masses from the patient's inflammatory arthritis, C2 translaminar fixation and pedicle screws were utilized.