HOSPITAL FOR SPECIAL SURGERY

Grand Rounds from HSS

MANAGEMENT OF COMPLEX CASES

September 2015 | Volume 6 Issue 1

AUTHORS

Constantine A. Demetracopoulos, MD
Assistant Attending Orthopaedic Surgeon
Assistant Professor of Orthopaedic Surgery
Weill Cornell Medical College

Mark C. Drakos, MD
Assistant Attending Orthopaedic Surgeon
Assistant Professor of Orthopaedic Surgery
Weill Cornell Medical College

Scott J. Ellis, MD
Associate Attending Orthopaedic Surgeon
Associate Professor of Orthopaedic Surgery
Weill Cornell Medical College

Austin T. Fragomen, MD
Associate Attending Orthopaedic Surgeon
Associate Professor of
Clinical Orthopaedic Surgery
Weill Cornell Medical College

Matthew M. Roberts, MD
Associate Attending Orthopaedic Surgeon
Chief, Foot and Ankle Service
Associate Professor of Clinical
Orthopaedic Surgery
Weill Cornell Medical College

CO-AUTHORS

Elizabeth A. Cody, MD
Orthopaedic Surgery Resident
Hospital for Special Surgery

Dylan Soukup, BS
Clinical Research Assistant
Orthopaedic Surgery, Foot and Ankle Service
Hospital for Special Surgery

From the Editor

Edward C. Jones, MD, MA

This volume of *Grand Rounds from HSS* focuses on foot and ankle surgery. We offer challenging cases presented by HSS Foot and Ankle specialists; three patients who presented with malalignment, instability and disabling pain who had previously undergone unsuccessful procedures for relatively common conditions. Each case required diagnostic acumen and multifaceted revision surgery in order to restore proper alignment and comfortable function for these very encumbered patients.

In the first case, Chief of the HSS Foot and Ankle Service, **Matthew Roberts**, **Scott Ellis** and **Elizabeth Cody** revised a failed triple arthrodesis in a 66-year-old woman with severe flatfoot deformity.

The second case involved a 75-year-old woman who presented with progressive valgus deformity of the ankle along with worsening pain, one year after a failed triple arthrodesis and deltoid ligament reconstruction. **Scott Ellis** and **Constantine Demetracopoulos**, assisted by **Dylan Soukup**, performed total ankle replacement, using a stemmed, fixed-bearing prosthesis. First tarsometatarsal fusion was also necessary to achieve neutral forefoot alignment.

In the final case, Foot and Ankle specialist **Mark Drakos** collaborated with Limb Lengthening and Complex Reconstruction specialist **Austin Fragomen** in performing complex, staged revision surgery on a 27-year-old woman after failed cavovarus hindfoot reconstruction.

All volumes of this publication also available on **www.hss.edu/complexcases**, where you will find additional images and references as well as links to related articles. We hope you find these cases to be of interest and the principles presented informative. Comments are always welcome at **complexcases@hss.edu**.

Edward C. Jones, MD, MA

Assistant Attending Orthopaedic Surgeon

In This Issue

Case 1

Revision of Failed Triple Arthrodesis for Flatfoot Deformity

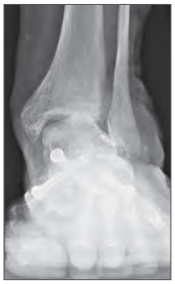

Case 2

Total Ankle Replacement for Valgus Deformity Correction Following Triple Arthrodesis and Failed Deltoid Ligament Reconstruction

Case 3

Staged Revision Surgery for Failed Cavovarus Hindfoot Reconstruction

Case 1

Case presented by Elizabeth A. Cody, MD, Matthew M. Roberts, MD, and Scott J. Ellis, MD

Revision of Failed Triple Arthrodesis for Flatfoot Deformity

Case Report: A 66-year-old woman presented initially for consultation at Hospital for Special Surgery (HSS) in February 2012 with severe right flatfoot deformity (Figure 1). She had a 6-year history of right foot pain, without any history of trauma. Her medical history was notable for well-controlled type 2 diabetes. Past surgical history was notable for distal metatarsal osteotomy for hallux valgus. In October 2012, the patient elected to undergo triple arthrodesis for her pes planovalgus deformity at another hospital.

She returned to HSS for another consultation in 2014 due to persistent deformity, swelling and stiffness, as well as increasing ankle pain. On examination, she had a severe, rigid pes planovalgus deformity. Ankle range of motion was well-preserved, with no signs of ankle instability. X-rays and computed tomography showed fusion of the talonavicular and calcaneocuboid joints and non-union of the subtalar arthrodesis. Also noted was persistent forefoot abduction and hindfoot valgus (Figure 2).

Figure 1

Figure 2

Figure 3

Given significant residual deformity and subtalar nonunion, the decision was made to perform a revision triple arthrodesis. In August 2014, the patient underwent removal of hardware, revision triple arthrodesis, and concomitant medializing calcaneal osteotomy. The nonunited subtalar joint was debrided. The fused calcaneocuboid joint was osteotomized with an oscillating saw. The fused talonavicular joint was osteotomized with a curved osteotome. The talonavicular joint was reduced first to correct the forefoot abduction. The subtalar joint was then reduced with the aid of a laminar spreader placed in the sinus tarsi, which helped translate the joint medially. Given residual hindfoot valgus, a medializing calcaneal osteotomy was performed. All bony work was held provisionally with Kirschner wires.

After excellent correction of the forefoot abduction and hindfoot valgus was confirmed, attention was turned to final fixation. Two 6.5mm partially threaded screws were placed so as to traverse the calcaneal osteotomy as well as the subtalar joint. Another 6.5mm partially threaded screw was placed from the medial navicular into the talus; this was supplemented by a claw plate to secure the talonavicular joint. The calcaneocuboid osteotomy was secured with a second claw plate. Ten cc of demineralized bone matrix was combined with autogenous iliac crest bone marrow aspirate and used to augment the fusions and osteotomies prior to final fixation.

Postoperatively, the patient was placed in a short leg splint, changed to a short leg cast at 2 weeks. At 6 weeks, she was transitioned to a Cam boot and allowed to progress weight bearing. At 10 weeks, all three joints and the calcaneal osteotomy showed radiographic healing. By 6 months, she had minimal symptoms, and examination showed significantly improved hindfoot and forefoot alignment with good ankle range of motion (Figure 3).

Figure 1: Initial X-rays from 2012 show severe flatfoot deformity: (A) greater than 50% uncoverage of the talar head is seen on the AP view; (B) the lateral view shows the plantarflexed talar head and subtalar joint subluxation.

Figure 2: Preoperative X-rays, following triple arthrodesis done at an outside institution, show minimal change in alignment.

Figure 3: X-rays taken 6 months after revision surgery show healed fusion and osteotomy sites, with marked improvement in forefoot abduction. The ankle joint is well preserved.

Discussion: This is a case of malunited triple arthrodesis for a severe flatfoot deformity, managed with revision triple arthrodesis and calcaneal osteotomy. Triple arthrodesis is indicated in cases of severe, rigid flatfoot deformity due to posterior tibial tendon dysfunction. The goals are a painless, plantigrade foot with neutral hindfoot alignment.

The rate of failure of triple arthrodesis requiring revision surgery is historically fairly low. Mäenpää et al. analyzed 307 arthrodeses, of which 21 failed. They found that the most common cause of failure was surgical misjudgment, with inadequate correction of deformity and resultant malnunion. [1]

For failed triple arthrodeses, a midfoot osteotomy can be used as a salvage procedure. Toolan described a biplanar, opening-closing osteotomy of the midfoot, with good results reported in five patients. [2] Haddad et al. described using a calcaneal osteotomy in combination with revision of the transverse tarsal arthrodesis, tailored to each patient's deformity, also with good results. [3] Given the subtalar nonunion and the severity of hindfoot deformity in the case described here, a midfoot osteotomy alone would have been insufficient.

In cases such as this, achieving a neutral hindfoot is critical, as progressive valgus leads to deltoid insufficiency and ultimately, ankle arthritis. Hyer et al. showed that valgus collapse occurs following triple arthrodesis if the hindfoot is left in any residual valgus. Some of the feet did not develop progressive valgus, but almost all of these started with neutral alignment. [4] As in the case described here, a calcaneal osteotomy can be used if necessary for additional correction. This case illustrates the importance of a careful, individualized approach to the painful flatfoot deformity, with close attention to correcting forefoot as well as hindfoot alignment. ■

Continued on page 4

Case 2

Case presented by Dylan Soukup, BS, Constantine A. Demetracopoulos, MD, and Scott J. Ellis, MD

Total Ankle Replacement for Valgus Deformity Correction Following Triple Arthrodesis and Failed Deltoid Ligament Reconstruction

Case Report: A 75-year-old retired female with a history of flatfoot deformity presented for evaluation due to significant lateral ankle pain, compromised gait, and severe valgus heel alignment of the left foot. Triple joint arthrodesis, lateral ligament imbrication, and medial deltoid ligament reconstruction using allograft had been performed one year prior at an outside institution leading to transient deformity correction and symptom relief. However, a valgus deformity of the ankle along with worsening pain subsequently developed. Failed conservative treatment using a brace led her to seek another opinion.

Initial examination revealed significant hindfoot valgus, ankle instability, and forefoot supination upon passive correction of the ankle to a neutral position. There was no range of motion in the triple joint complex, though ankle range of motion remained full in large part due to recurrent hypermobility. Radiographs revealed significant ankle arthritis with approximately 25° of talar valgus and screw fixation of the triple joint complex (Figure 1). CT scan demonstrated solid fusion of the subtalar joint and sufficient fusion of both the talonavicular and calcaneocuboid joints despite poor fixation, while MRI showed complete degenerative failure of the deltoid ligament reconstruction (Figure 2).

Total ankle replacement (TAR) was performed, using a stemmed, fixed-bearing prosthesis. This prosthesis was selected to correct the significant valgus ankle deformity; achieving realignment through the stability of a long-stem intramedullary implant with a thick polyethylene bearing. Sustained forefoot supination after implantation of the TAR, along with hypermobility of the first ray required first tarsometatarsal (TMT) fusion in a plantar-flexed position to achieve neutral forefoot alignment.

At 2 weeks postoperatively, a partial fracture of the medial malleolus was noted on radiographic imaging and confirmed by CT scan. Given the patient's history of failed deltoid reconstruction, she was subsequently returned to the OR for percutaneous fixation of the fracture using two cannulated screws to protect the medial malleolus. At 3 months postoperatively, the patient reported complete resolution of preoperative pain, the capacity to weight bear and walk several blocks pain-free, and improved ankle motion. Clinical examination demonstrated a stable first ray touching the floor, neutral hindfoot and forefoot alignment, and excellent ankle range of motion (Figures 3 and 4).

Discussion: Total ankle replacement is beginning to show good intermediate to long-term outcomes [1] and improvements in implants are providing better outcomes. [2] This case highlights several important principles for performing TAR in the setting of ankle deformity including determining deformity severity, understanding the effect of concomitant foot pathologies, choosing between replacement and fusion, balancing the foot, and selecting the correct implant.

Patient selection for TAR is important for a successful outcome. Severe coronal deformity is considered a relative contraindication for TAR in patients with preoperative varus or valgus, though the degree of deformity at which TAR is contraindicated has not been clearly defined. While some studies suggest that deformity greater than 15 or 20° of coronal plane deformity contraindicates TAR, there is evidence to suggest that patients with up to 30° of varus or valgus can safely undergo TAR with equivalent results to patients with neutral preoperative hindfoot alignment. [3] The present case with 25 degrees of valgus deformity represents a borderline case for the use of TAR, but the deformity severity must also be weighed with the implications of concomitant foot pathologies.

Preexisting triple arthrodesis provides a challenge in the treatment of ankle arthritis by removing hindfoot motion in the subtalar and talonavicular joints.

While ankle fusion provides a definitive treatment option for ankle arthritis and the outcomes of replacement versus arthrodesis remain controversial, the combination of triple arthrodesis and ankle fusion leaves the patient with a virtually non-functional foot. Patients with ipsilateral hindfoot arthrodeses have been shown to receive significant improvements in pain and functional outcome following TAR, though it remains unclear whether they attain the

Continued on page 4

Figure 1: Preoperative AP (A), hindfoot (B), and lateral (C) radiographs demonstrate preoperative valgus ankle deformity, hindfoot valgus, triple joint fixation, and arch collapse.

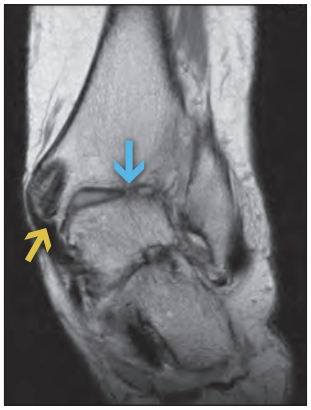

Figure 2: Preoperative coronal MR image demonstrates chronic scarring of the deltoid ligament (yellow arrow), and advanced tibiotalar osteoarthritis (blue arrow) with valgus deformity.

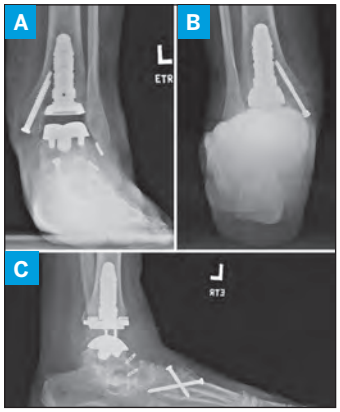

Figure 3: Postoperative AP (A), hindfoot (B), and lateral (C) radiographs demonstrate total ankle replacement, ankle deformity correction, and neutral hindfoot alignment.

Figure 4: Postoperative AP (A) and hindfoot (B) clinical views demonstrate grossly neutral alignment.

Case 3

Case presented by Mark C. Drakos, MD and Austin T. Fragomen, MD

Staged Revision Surgery for Failed Cavovarus Hindfoot Reconstruction

Case Report: A 27-year-old female presented to HSS for evaluation of her left ankle in 2013, reporting a long-standing history of left ankle problems. She initially sprained her ankle in 2009 and went on to experience recurrent ankle sprains and chronic ankle instability. The patient had initially been diagnosed with a cavovarus foot deformity which likely predisposed her to this condition. She eventually had a foot and ankle reconstruction in May of 2011 performed by an outside physician. This procedure consisted of cavovarus foot reconstruction with a lateralizing calcaneal osteotomy, first ray dorsiflexion osteotomy, Brostrom Gould type ankle stabilization with suture anchors [1], peroneus longus to brevis transfer and exostectomy. The patient denied any post-operative complications but experienced persistent pain in the ankle after surgery. In spite of treatment with various braces and orthotics, the patient reported that the condition was getting progressively worse. In addition to persistent discomfort, the patient experienced frequent episodes of instability; as well as clicking, catching and locking.

On physical examination the patient's gait was heel to toe, but severely antalgic, and she walked on the lateral border of her foot. She had a significant callous pattern along the lateral border of her foot. The patient was unable to toe walk and heel walk without difficulty.

The patient had functional range of motion of the hips, knees and ankles. The hindfoot alignment was significant cavovarus. Ankle strength testing revealed 3/5 strength in dorsiflexion, 5/5 plantar flexion, 5/5 inversion and 4/5 eversion. The patient pointed to the anterior ankle joint line as the predominant site of pain and had positive signs of anterior impingement. Peroneal tendons were located. She had a 2+ anterior drawer.

X-rays of the lower extremity (Figure 1) and MRI (Figure 2) revealed cavovarus alignment. The patient had a 20° varus deformity at the ankle. She has significant ankle instability with a positive stress testing. There were also full thickness osteochondral defects on the medial talar dome and medial tibial plafond, as well as marginal osteophytes and loose bodies. There was also an adduction deformity of the midfoot.

We recommended surgical management beginning with ankle arthroscopy and cartilage repair using denovo allograft with bone marrow aspirate concentrate from the patient's iliac crest. In addition, a supramalleolar osteotomy with ankle distraction to be performed with a Taylor spatial frame [2]. We also recommended staging a lateral ligament reconstruction with hamstring autograft, revision calcaneal osteotomy and posterior tibial lengthening to address the adduction deformity.

The patient underwent arthroscopy with removal of loose body and articular cartilage repair with a denovo allograft, along with a distal tibial osteotomy and distraction as described (Figure 3). She was initially non-weight bearing; at 6 weeks progressing weight bearing as tolerated. The valgus producing supramalleolar osteotomy healed and the frame was removed at 3 months.

When the frame pin sites had healed the patient was re-assessed. Although her overall alignment was improved, she still had some hindfoot varus and a 2+ anterior drawer (Figure 4). At approximately 6 months after the initial procedure, a second stage procedure was performed. This consisted of lateral ligament reconstruction with hamstring autograft and posterior tibial tendon lengthening. Revision lateralizing calcaneal osteotomy and peroneal tendon repair where performed as well.

The patient was initially treated in a cast and then advanced to a CAM boot with partial weight bearing at 2 months, followed by a Ritchie Brace at 4 months. She was able to walk without any assistive devices by 6 months.

Figure 1: AP standing radiograph demonstrating a severe varus deformity of the ankle, narrowing of the joint space over the medial talar dome and hardware from the prior procedure.

Figure 2: Sagittal fat suppressed MRI demonstrating severe cartilage loss, subchondral edema and anterior ankle osteophytes. Arrow points to a large anterior osteophyte and corresponding ankle effusion.

Figure 3: Mortise standing radiograph demonstrating the ankle status post supramalleolar osteotomy and distraction with the Taylor spatial frame in place.

Figure 4: AP standing radiograph demonstrating correction of the varus deformity of the ankle, improved medial joint space and a plantigrade foot.

Her pain was minimal. Radiographs of the lower extremity revealed a slight valgus alignment at the ankle, as intended to over-correct at this level. The patient's foot was plantigrade, with neutral heel alignment and good stability on stress testing (Figure 5).

Discussion: This case illustrates several key concepts when addressing chronic ankle instability in a mal-aligned foot. Although a neurologic cause had been evaluated and ultimately ruled out, this patient had significant

Continued on page 4

Figure 1

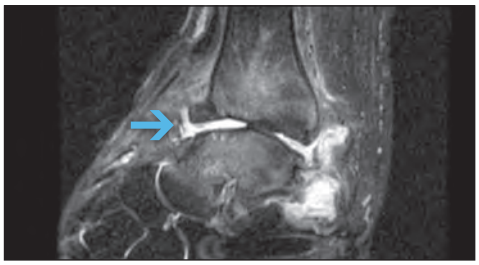

Figure 2



Figure 3

Figure 4

Case 1 Continued

REFERENCES:

1. Maenpaa H, Lehto MU, Belt EA. What went wrong in triple arthrodesis? An analysis of failures in 21 patients. *Clinical Orthopaedics & Related Research* (391)218-23, 2001 Oct.
2. Toolan BC. Revision of failed triple arthrodesis with an opening-closing wedge osteotomy of the midfoot. *Foot & Ankle International* 2004 Jul;25(7):456-61.
3. Haddad SL, Myerson MS, Pell RF 4th, Schon LC. Clinical and radiographic outcome of revision surgery for failed triple arthrodesis. *Foot & Ankle International* 1997 Aug;18(8):489-99.
4. Hyer CF, Galli MM, Scott RT, Bussewitz B, Berlet GC. Ankle valgus after hindfoot arthrodesis: a radiographic and chart comparison of the medial double and triple arthrodeses. *Journal of Foot & Ankle Surgery* 2014 Jan-Feb;53(1):55-8.

AUTHOR DISCLOSURES:

Elizabeth A. Cody, MD, does not have a financial interest or relationship with the manufacturers of products or services.

Dr. Matthew M. Roberts holds a leadership position:
- Board Member, New York State Society of Orthopaedic Surgeons

Dr. Scott J. Ellis does not have a financial interest or relationship with the manufacturers of products or services.

Case 2 Continued

same level of improvement as patients undergoing TAR without concomitant hindfoot fusions. [4,5] Regardless, the importance of balancing the foot for the success of TAR in all cases is widely acknowledged and provides the rationale in this patient for the first TMT fusion in a plantar-flexed position to correct the forefoot supination that presented upon ankle deformity correction.

While the literature comparing the outcomes of various prostheses is sparse, we believe the choice of implant system plays an important role in treating ankle arthritis particularly in the setting of concomitant coronal plane deformity. The intramedullary prosthesis chosen in this case uses a sturdy external alignment jig to allow for significant correction and holds the desired position when making the bone cuts for implant placement. The use of an intramedullary referencing system, as opposed to extramedullary referencing used with many other TAR systems, may have further implications for tibial component alignment, though it has only been shown to improve sagittal plane alignment. [6] Additionally, we believe the long-stem intramedullary implant may reduce likelihood of talar component loosening in the setting of ankle deformity and the use of a large polyethylene bearing likely provides ankle stabilization in the properly aligned position.

This case illustrates the multifaceted approach necessary to treat ankle arthritis with concomitant ankle deformity and existing hindfoot pathology. Proper patient selection, balancing of the foot, and implant choice are crucial to successful and sustained correction of ankle deformity with a TAR. ■

REFERENCES:

1. Daniels TR, Mayich DJ, Penner MJ. Intermediate to Long-Term Outcomes of Total Ankle Replacement with the Scandinavian Total Ankle Replacement (STAR). *J. Bone Joint Surg. Am.* 2015;97(11):895-903. doi:10.2106/JBJS.N.01077.
2. Lewis JS, Green CL, Adams SB, Easley ME, DeOrio JK, Nunley JA. Comparison of First- and Second-Generation Fixed-Bearing Total Ankle Arthroplasty Using a Modular Intramedullary Tibial Component. *Foot Ankle Int.* March 2015:1071100715576568. doi:10.1177/1071100715576568.
3. Hobson SA, Karantana A, Dhar S. Total ankle replacement in patients with significant pre-operative deformity of the hindfoot. *J. Bone Joint Surg. Br.* 2009;91-B(4):481-486. doi:10.1302/0301-620X.91B4.20855.
4. Kim BS, Knupp M, Zwicky L, Lee JW, Hintermann B. Total ankle replacement in association with hindfoot fusion OUTCOME AND COMPLICATIONS. *J. Bone Joint Surg. Br.* 2010;92-B(11):1540-1547. doi:10.1302/0301-620X.92B11.24452.
5. Lewis JS, Adams SB, Queen RM, DeOrio JK, Nunley JA, Easley ME. Outcomes After Total Ankle Replacement in Association With Ipsilateral Hindfoot Arthrodesis. *Foot Ankle Int.* 2014;35(6):535-542. doi:10.1177/1071100714528495.
6. Adams SB, Demetracopoulos CA, Viens NA, et al. Comparison of Extramedullary Versus Intramedullary Referencing for Tibial Component Alignment in Total Ankle Arthroplasty. *Foot Ankle Int.* 2013;34(12):1624-1628. doi:10.1177/1071100713505534.

AUTHOR DISCLOSURES:

Dylan Soukup, BS, does not have a financial interest or relationship with the manufacturers of products or services.

Dr. Constantine A. Demetracopoulos does not have a financial interest or relationship with the manufacturers of products or services.

Dr. Scott J. Ellis does not have a financial interest or relationship with the manufacturers of products or services.

Case 3 Continued

muscle imbalance which may have contributed to the malalignment. Sometimes, in severe cases, such as this one, the conventional cavovarus foot reconstructions are inadequate to address the deformity. Moreover, this was a young patient with early arthritis in which reconstruction options such as fusion or ankle replacement are less than ideal with potential long-term ramifications. This multifaceted, staged approach allowed for joint preservation and re-alignment with less morbidity than some of the other potential options. Given the patient's young age she would have likely worn out an ankle replacement and require a revision in the future [3]. If we had chosen a fusion for this individual, she would have a 90% chance of adjacent joint arthritis (Talonavicular or subtalar joint) within 10 years [4]. The lack of other long-term viable options was the main reason we chose a joint preserving approach. Furthermore, it did not preclude other procedures in the future should the cartilage ultimately continue to degrade over time necessitating other procedures such as ankle replacement when the patient is older and potentially has less demand on the implant. ■

REFERENCES:

1. Idiopathic cavovarus and lateral ankle instability: recognition and treatment implications relating to ankle arthritis. Fortin PT, Guettler J, Manoli A 2nd. *Foot Ankle Int.* 2002 Nov;23(11):1031-7.
2. Supramalleolar osteotomy using circular external fixation with six-axis deformity correction of the distal tibia. Horn DM, Fragomen AT, Rozbruch SR. *Foot Ankle Int.* 2011 Oct;32(10):986-93.
3. The Scandinavian total ankle replacement: long-term, eleven to fifteen-year, survivorship analysis of the prosthesis in seventy-two consecutive patients. Brunner S, Barg A, Knupp M, Zwicky L, Kapron AL, Valderrabano V, Hintermann B. *J Bone Joint Surg Am.* 2013 Apr 17;95(8):711-8. doi: 10.2106/JBJS.K.01580.
4. Investigating the relationship between ankle arthrodesis and adjacent-joint arthritis in the hindfoot: a systematic review. Ling JS, Smyth NA, Fraser EJ, Hogan MV, Seaworth CM, Ross KA, Kennedy JG. *J Bone Joint Surg Am.* 2015 Mar 18;97(6):513-20

AUTHOR DISCLOSURES:

Dr. Mark C. Drakos does not have a financial interest or relationship with the manufacturers of products or services.

Dr. Austin T. Fragomen does have a financial interest or relationship with the manufacturers of products or services.
- Consultant: Smith & Nephew, Synthes
- Royalties: Stryker

Figure 5: Lateral standing radiograph demonstrating reduction of the calcaneal pitch, elimination of anterior osteophytes and plantigrade alignment.

HSS eAcademy®
HOSPITAL FOR SPECIAL SURGERY

For more information, visit **www.hss.edu/eAcademy**.

Now Available

Featured Online CME Symposia

The field of musculoskeletal medicine is highly dynamic and rapidly changing. These modules are designed to help orthopaedic professionals remain informed of current issues affecting musculoskeletal medicine.

- Implant Removal
- Total Knee
- Lumbar Stenosis and Concurrent Discogenic Pain*
- Total Ankle Replacement: Innovations, Management, and Case Discussion*
- Clinical Outcomes and Survivorship of Total Ankle Arthroplasty*

New Surgical Videos

- Patellofemoral Joint Replacement*
- Cemented THR Acetabular and Femur Posterior Exposure*
- TKR Correction of Valgus Deformity*

Conversations with Experts

Lawrence Levin, MD, Chief of Cardiology at HSS, discusses beta blockers use with **Chad Craig, MD**.

- Beta Blockers*

*Non-accredited modules

Hospital for Special Surgery holds Accreditation with Commendation, the highest level of recognition offered by the Accreditation Council for Continuing Medical Education (ACCME).

For You and Your Patients

WEBINARS AND PODCASTS

Encourage your patients to watch and learn through our on-demand webinars.

Visit **www.hss.edu/pped-webinars** to learn more.
Podcasts are available at **www.hss.edu/podcasts.asp**.

Topics include:

- Advances in Lupus Research: Spotlight on Treatment
- Lupus Care: The Past, the Present and the Future
- Osteoarthritis: Today's Options
- Family Caregivers and Healthcare Team: A Challenging Partnership
- Annual Bone Health Education Seminar: Healthy Bones—Build Them for Life

Grand Rounds from HSS MANAGEMENT OF COMPLEX CASES

HOSPITAL FOR SPECIAL SURGERY

Follow us on:

Hospital for Special Surgery is an affiliate of NewYork-Presbyterian Healthcare System and Weill Cornell Medical College.

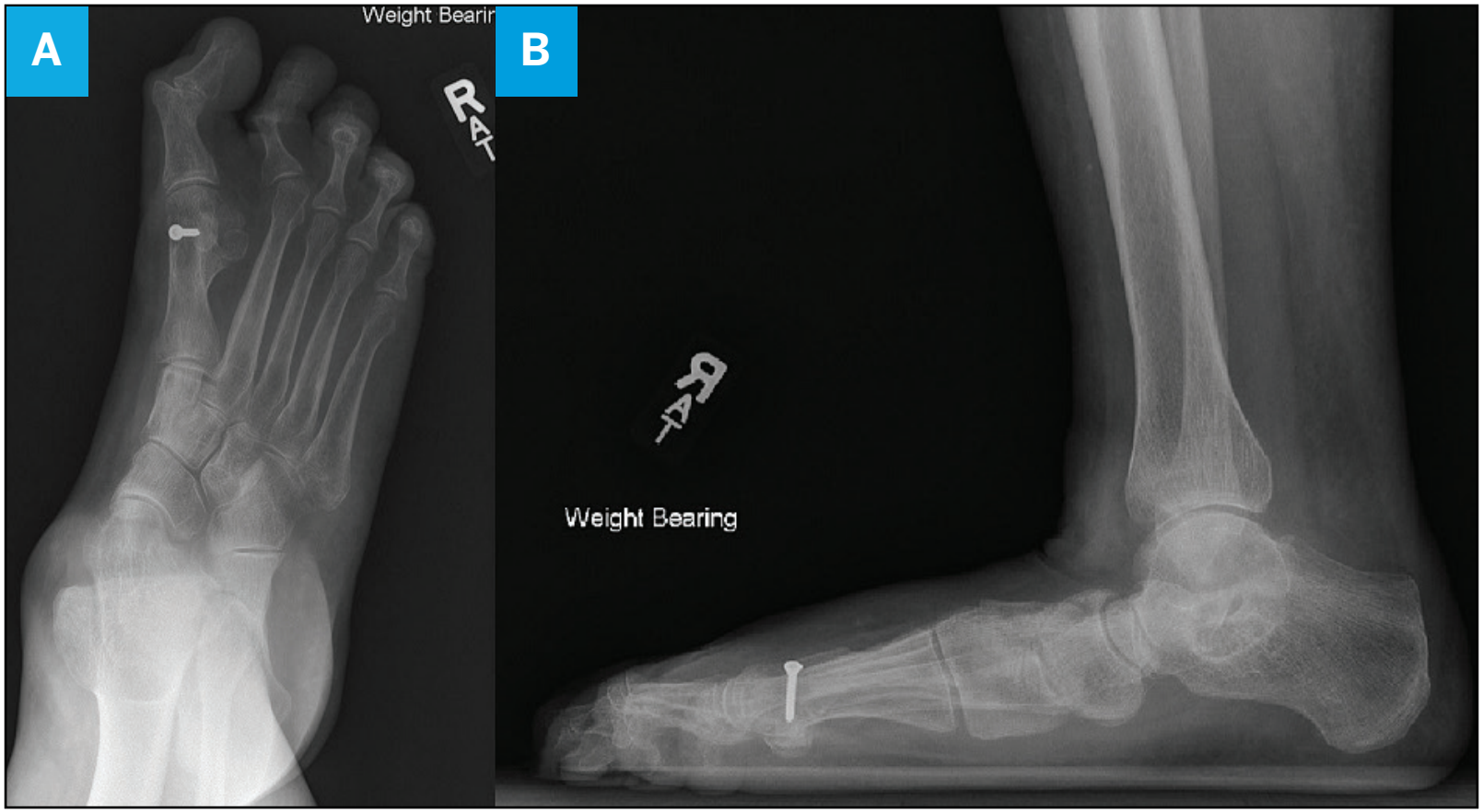

Figure 1: Initial X-rays from 2012 show severe flatfoot deformity: (A) greater than 50% uncoverage of the talar head is seen on the AP view; (B) the lateral view shows the plantarflexed talar head and subtalar joint subluxation.

Figure 2: Preoperative X-rays, following triple arthrodesis done at an outside institution, show minimal change in alignment.

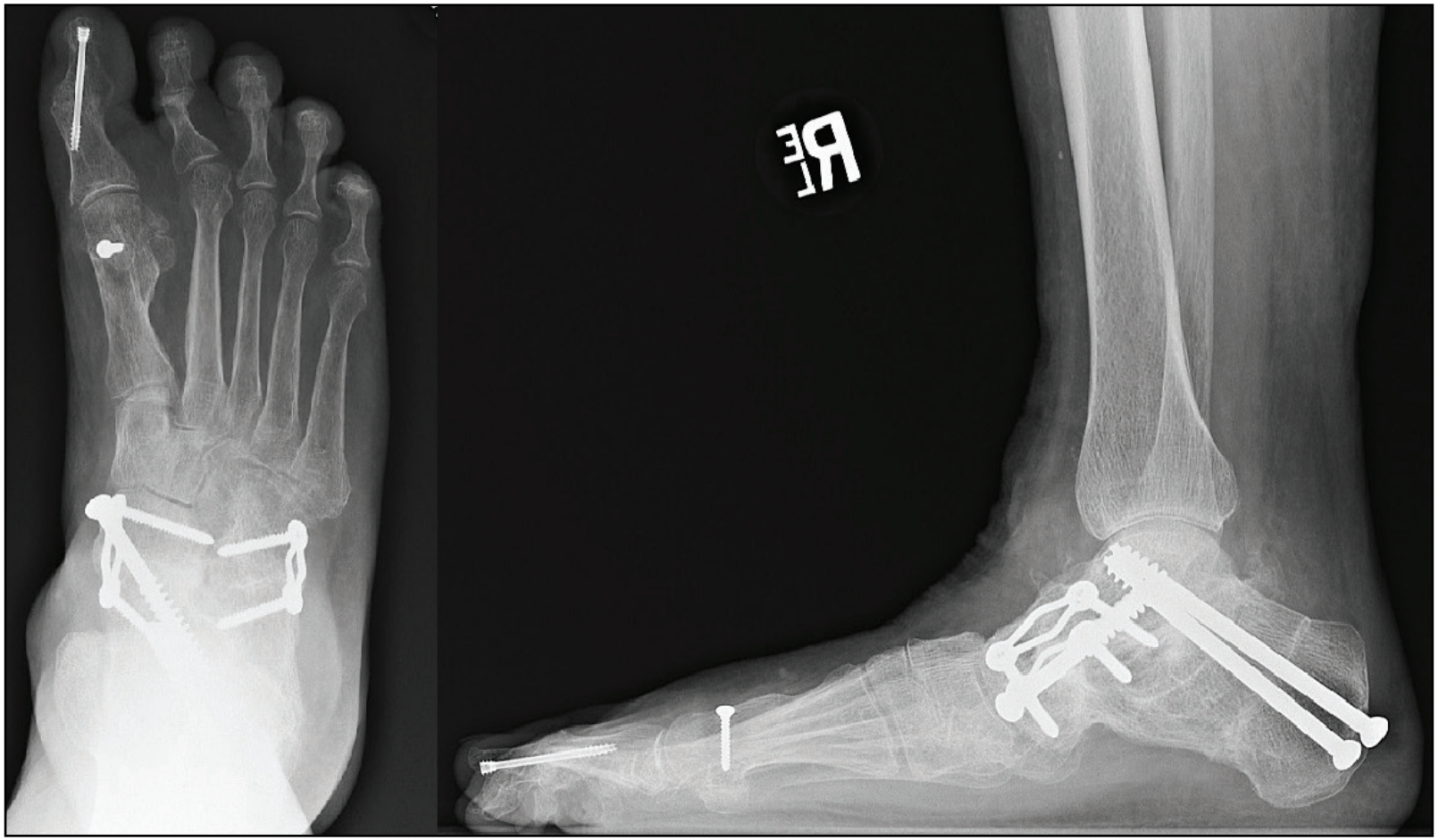

Figure 3: X-rays taken 6 months after revision surgery show healed fusion and osteotomy sites, with marked improvement in forefoot abduction. The ankle joint is well preserved.

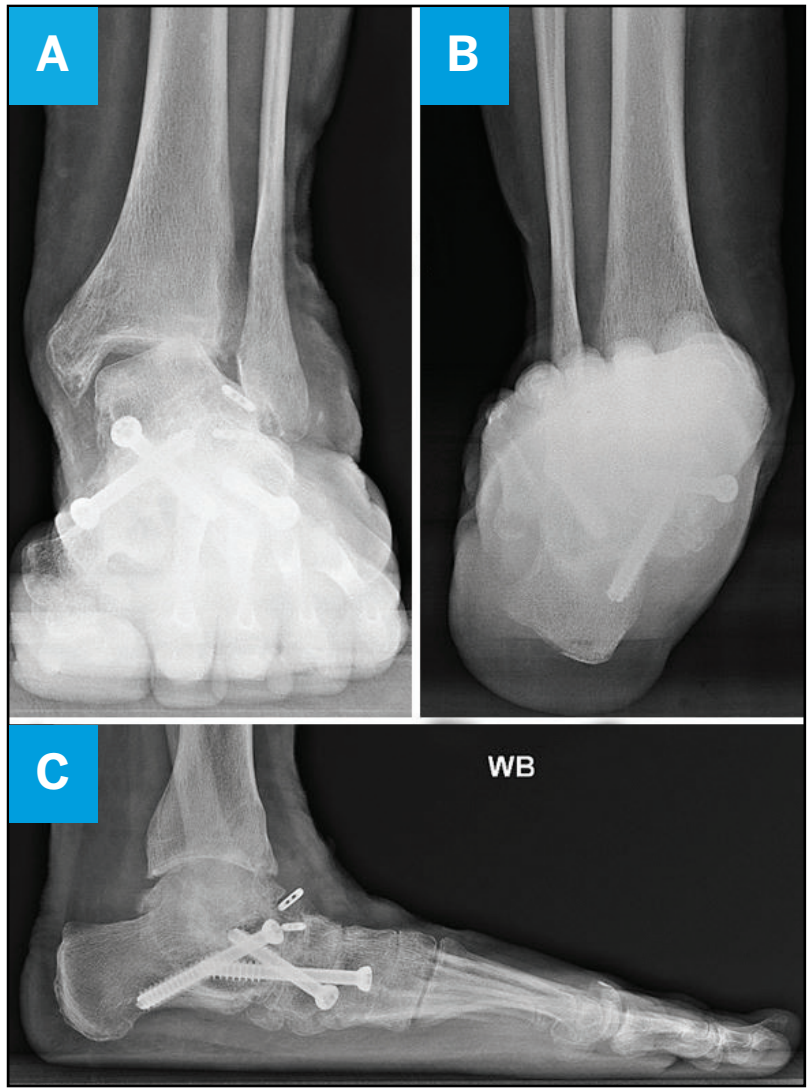

Figure 1: Preoperative AP (A), hindfoot (B), and lateral (C) radiographs demonstrate preoperative valgus ankle deformity, hindfoot valgus, triple joint fixation, and arch collapse.

Figure 2: Preoperative coronal MR image demonstrates chronic scarring of the deltoid ligament (yellow arrow), and advanced tibiotalar osteoarthritis (blue arrow) with valgus deformity.

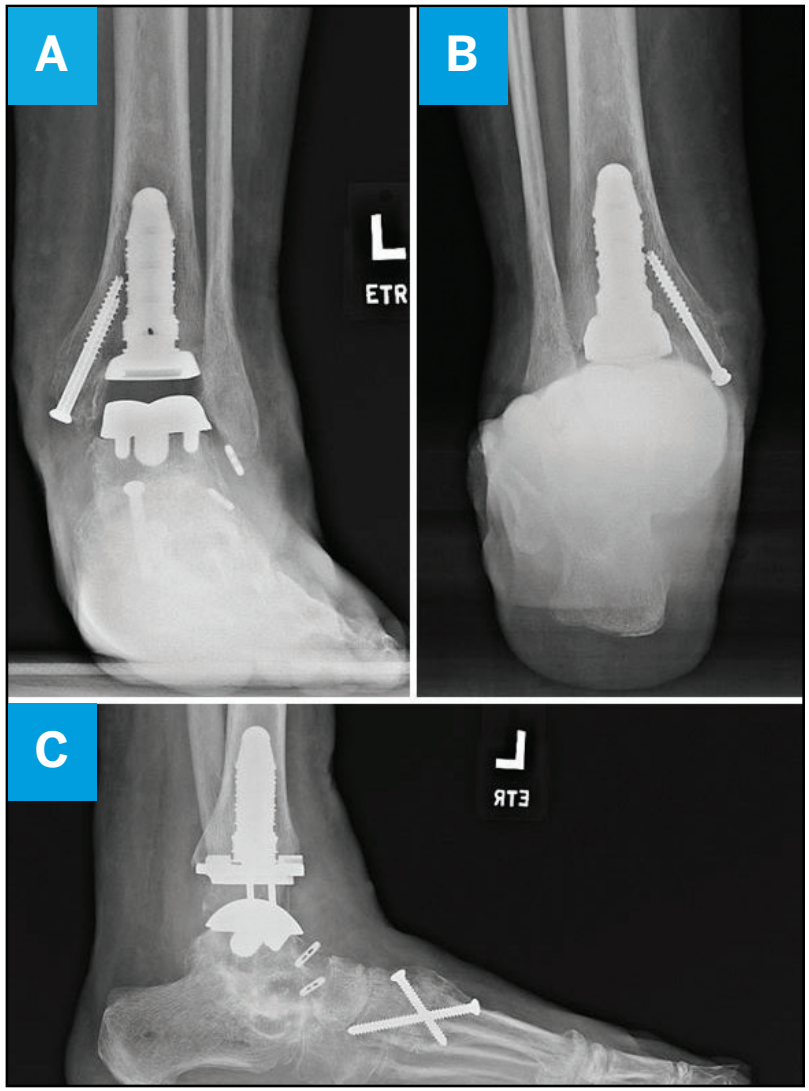

Figure 3: Postoperative AP (A), hindfoot (B), and lateral (C) radiographs demonstrate total ankle replacement, ankle deformity correction, and neutral hindfoot alignment.

Figure 4: Postoperative AP (A) and hindfoot (B) clinical views demonstrate grossly neutral alignment.

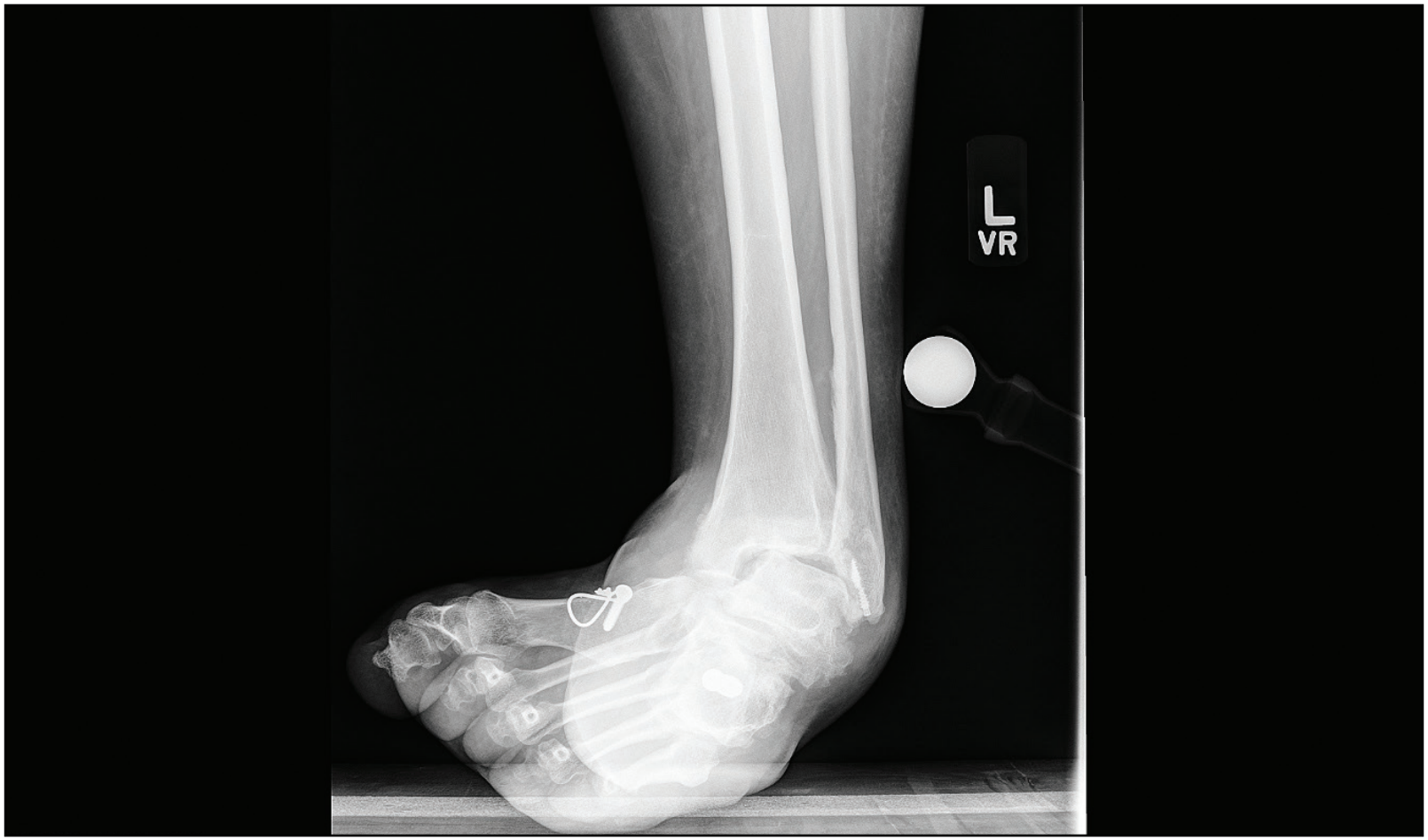

Figure 1: AP standing radiograph demonstrating a severe varus deformity of the ankle, narrowing of the joint space over the medial talar dome and hardware from the prior procedure.

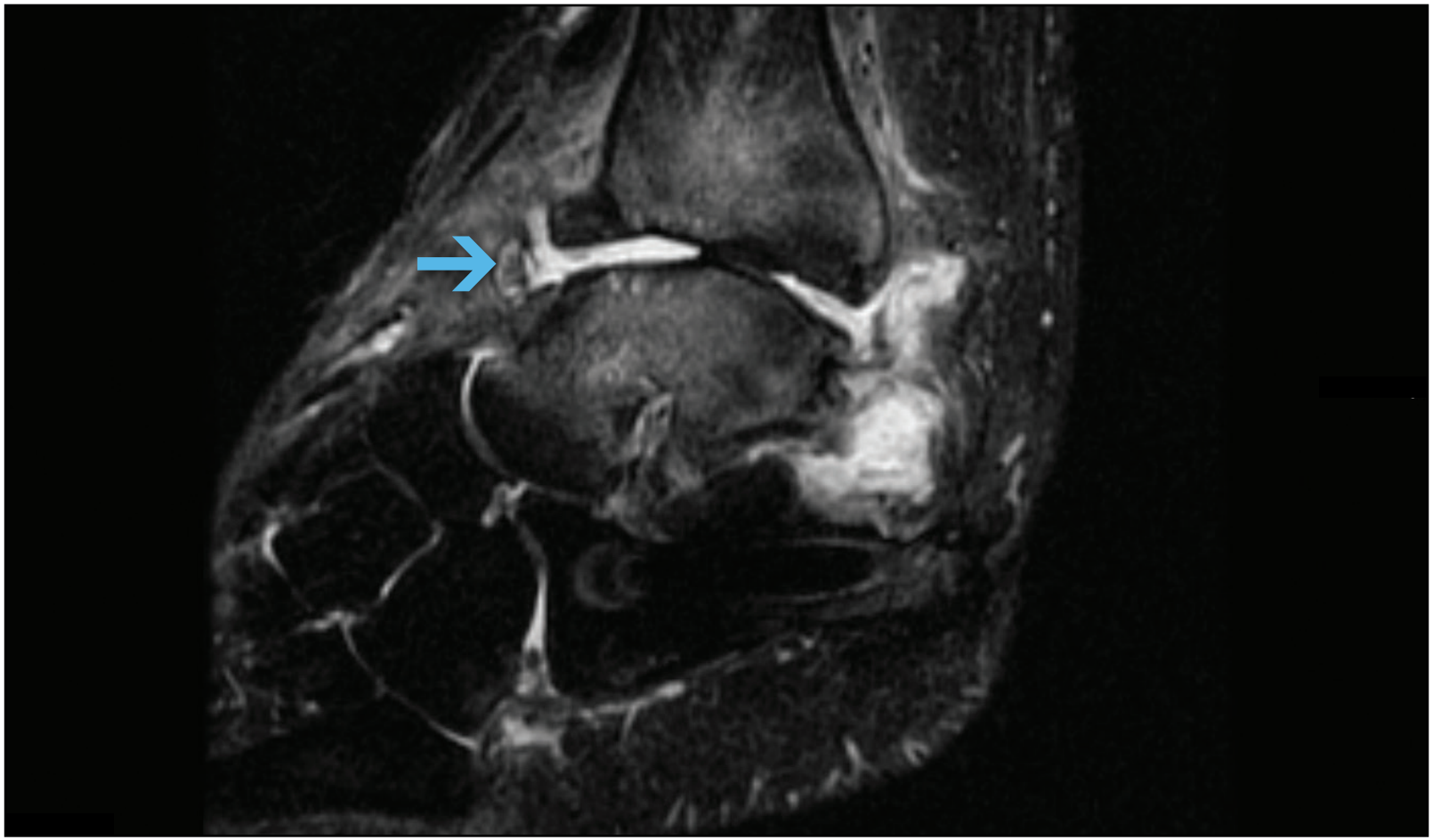

Figure 2: Sagittal fat suppressed MRI demonstrating severe cartilage loss, subchondral edema and anterior ankle osteophytes. Arrow points to a large anterior osteophyte and corresponding ankle effusion.

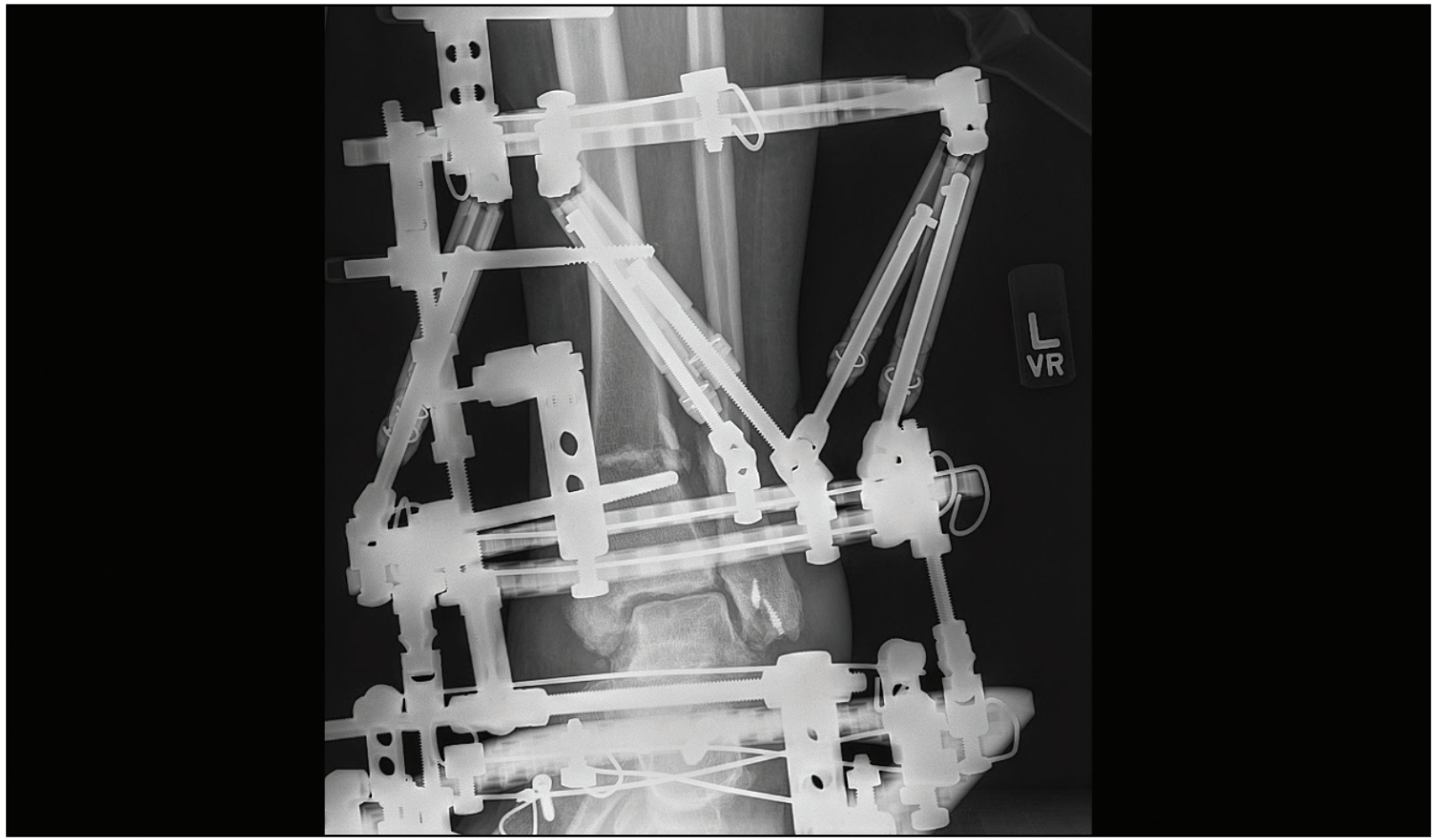

Figure 3: Mortise standing radiograph demonstrating the ankle status post supramalleolar osteotomy and distraction with the Taylor spatial frame in place.

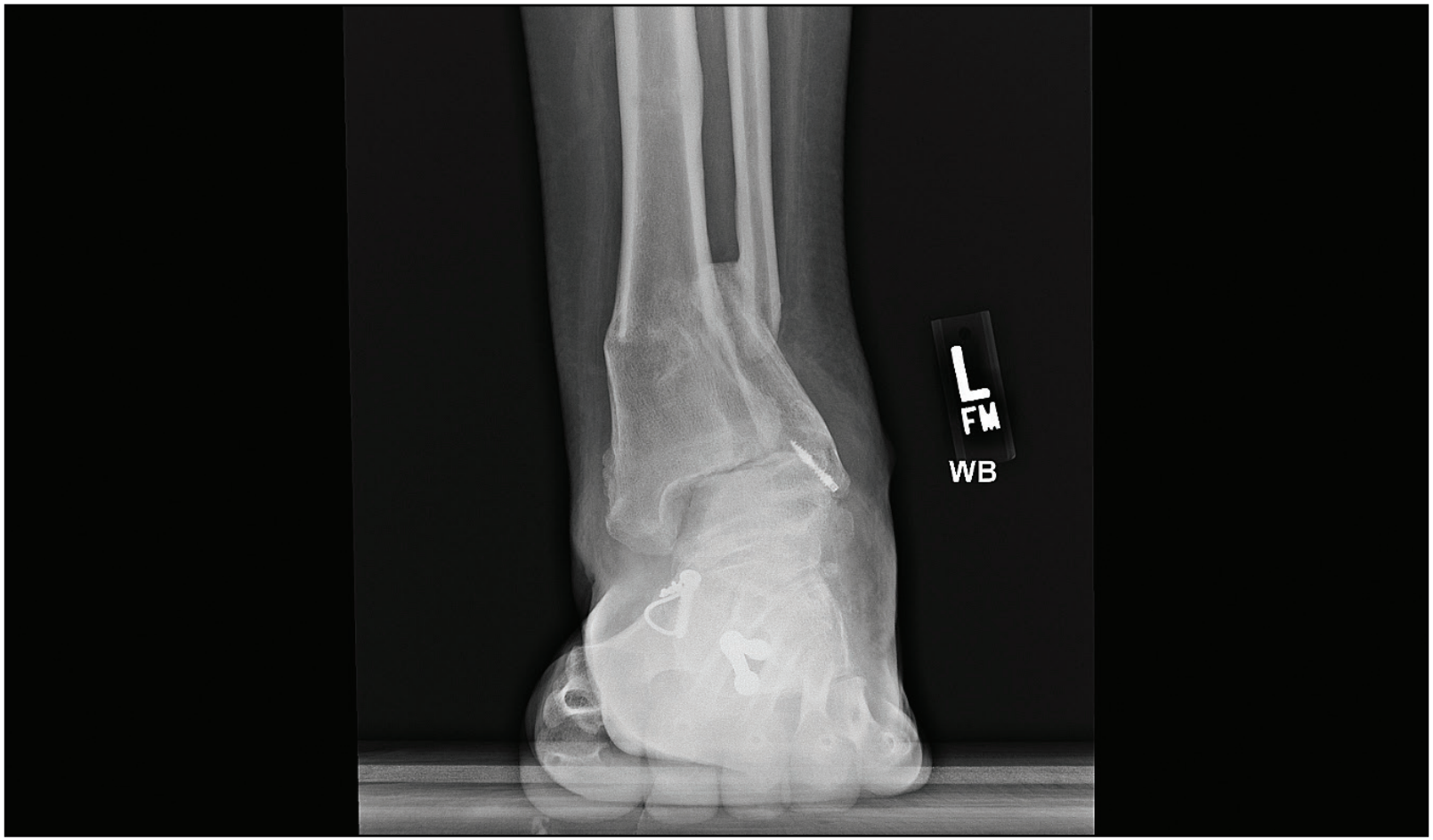

Figure 4: AP standing radiograph demonstrating correction of the varus deformity of the ankle, improved medial joint space and a plantigrade foot.

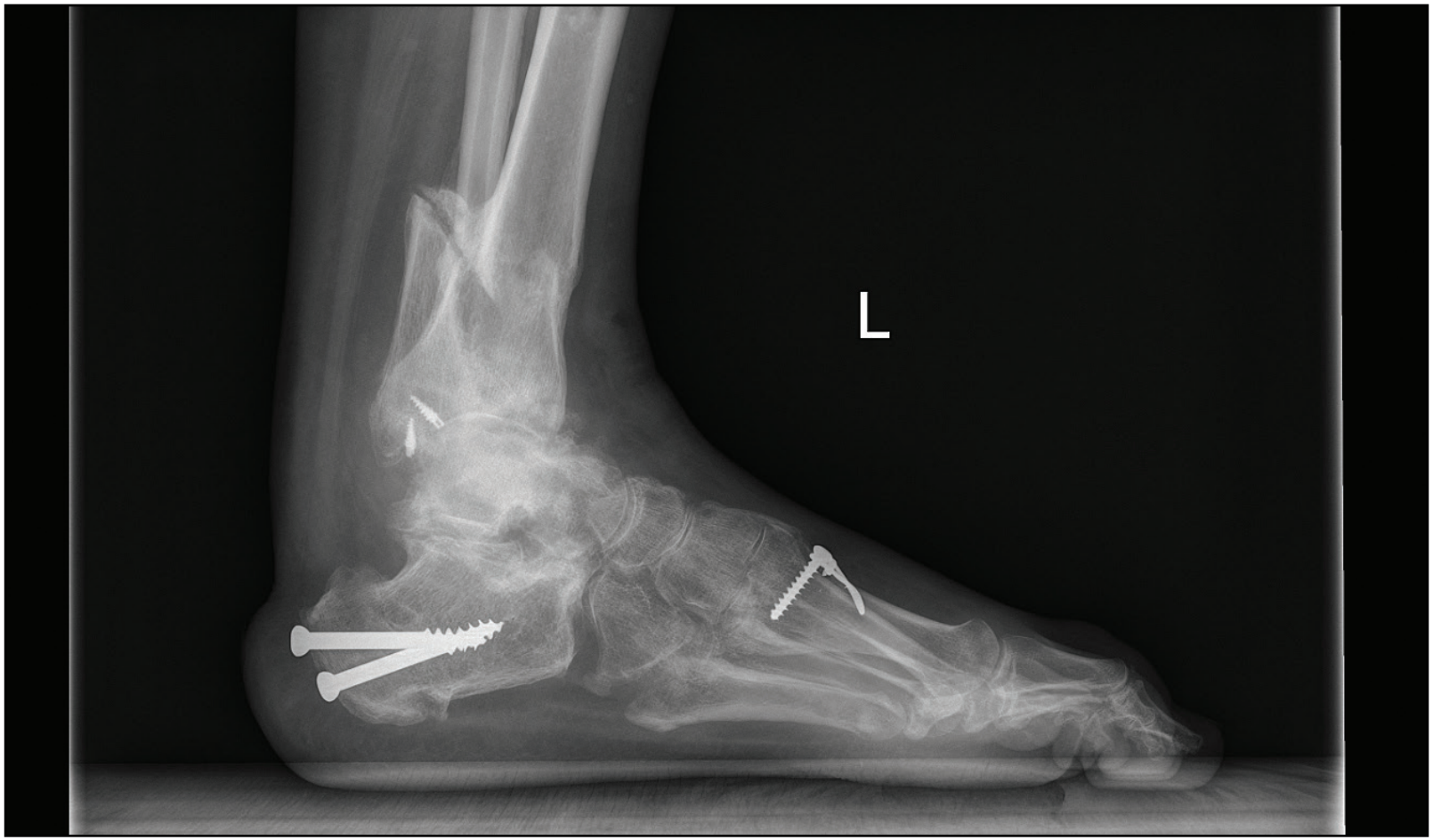

Figure 5: Lateral standing radiograph demonstrating reduction of the calcaneal pitch, elimination of anterior osteophytes and plantigrade alignment.