

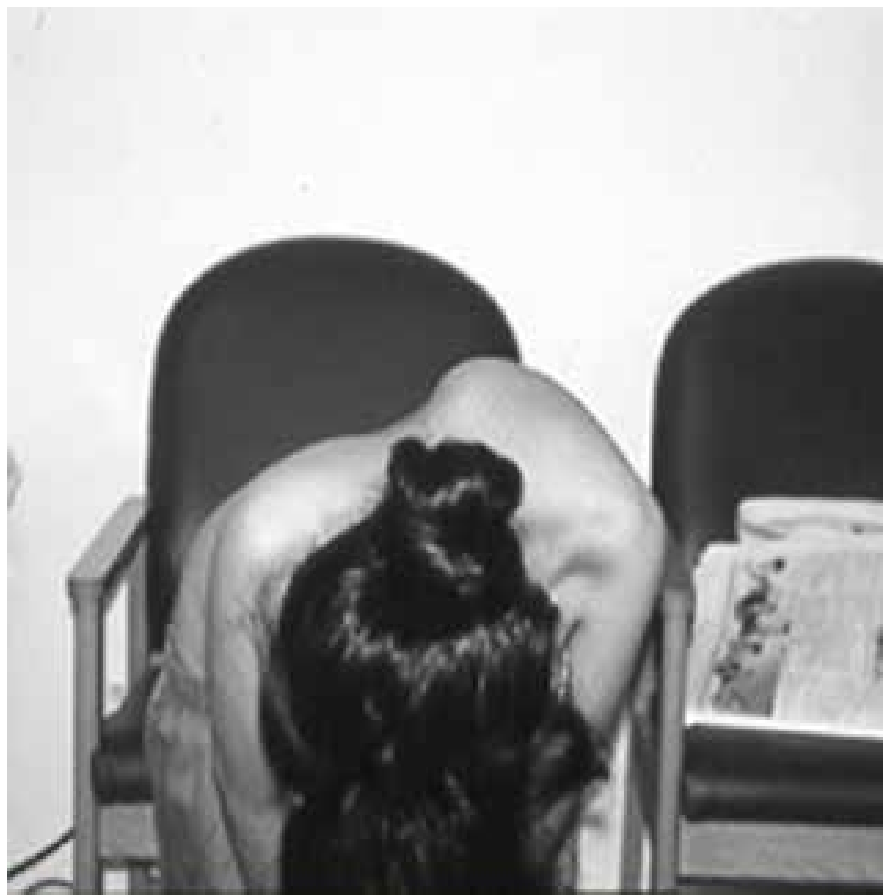
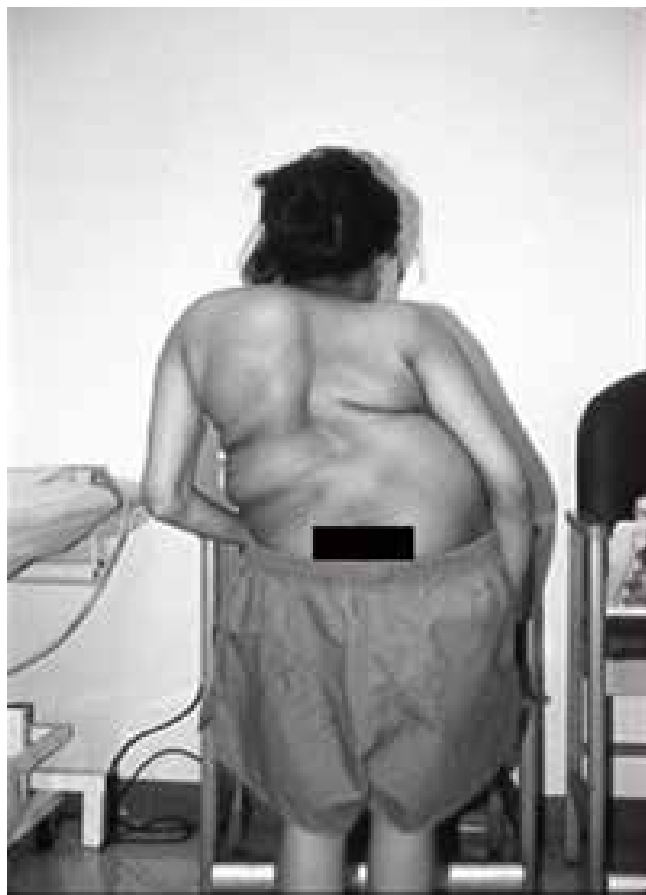
Figure 1 – Pre-operative photographs of the patient showing the severity of the scoliosis and kyphosis.

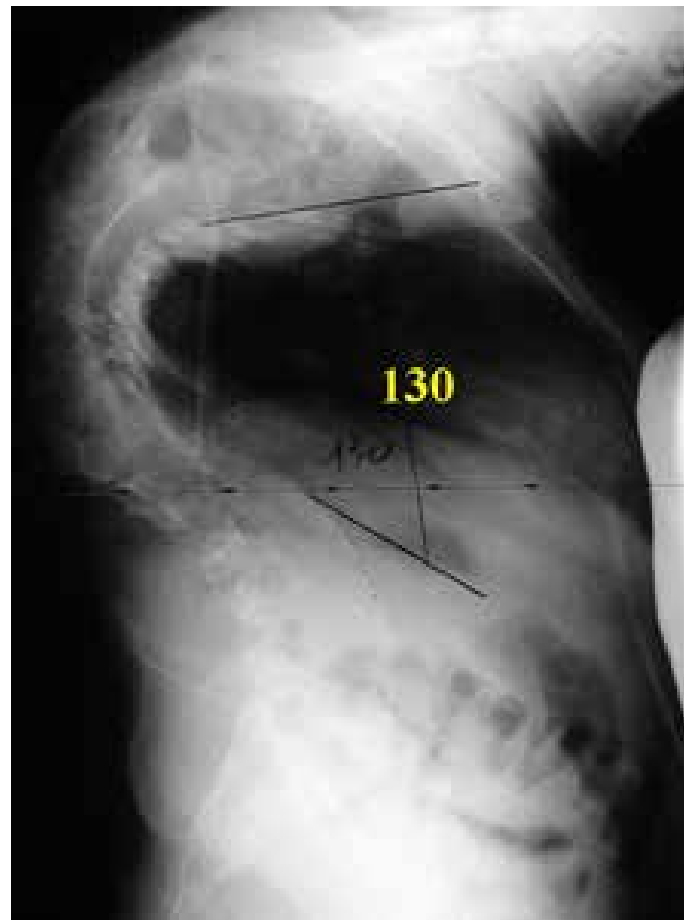
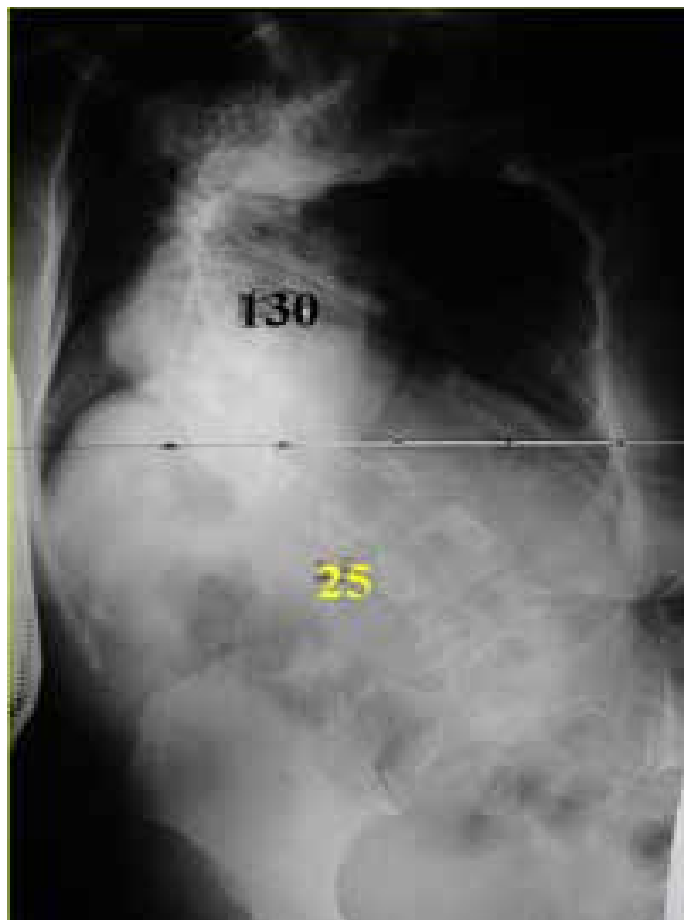


Figure 2. Preoperative AP and Lateral X-rays show a severe and rigid scoliosis (130 degrees) and hyperkyphosis (130 degrees).

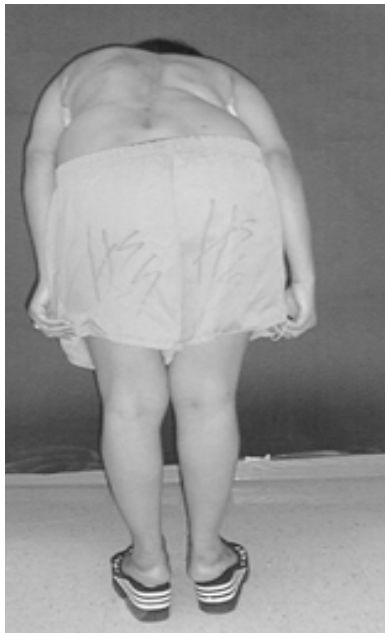
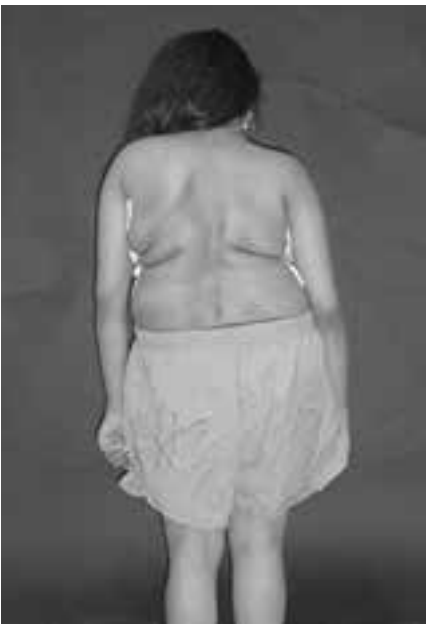
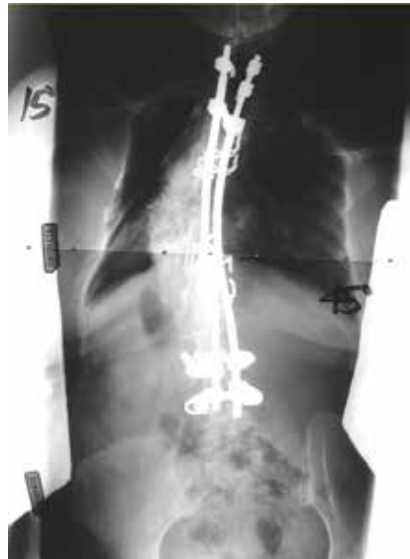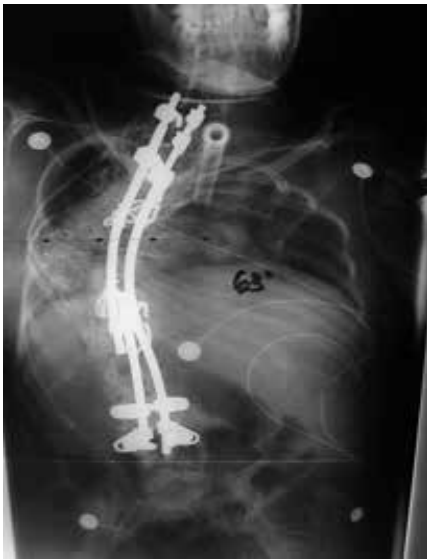Figure 3. Postoperative photograph shows the balance correction achieved in the frontal and sagittal planes.