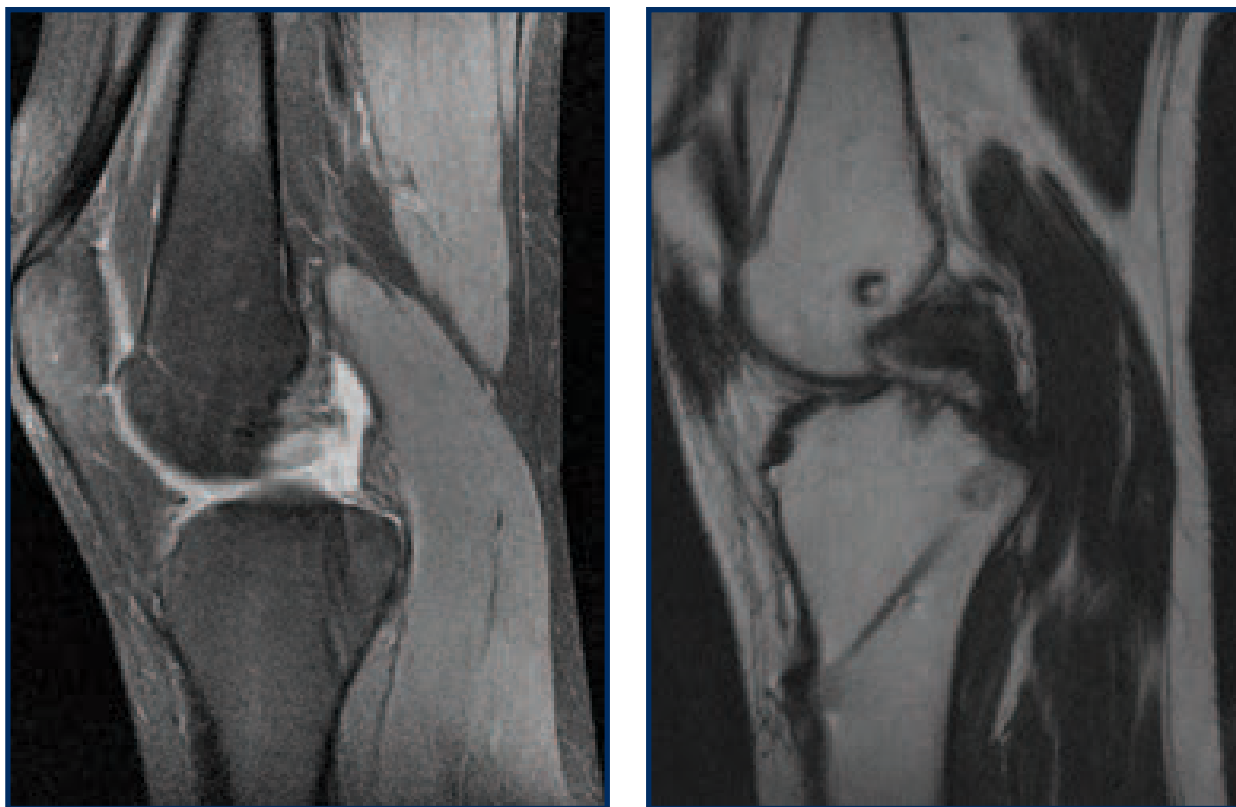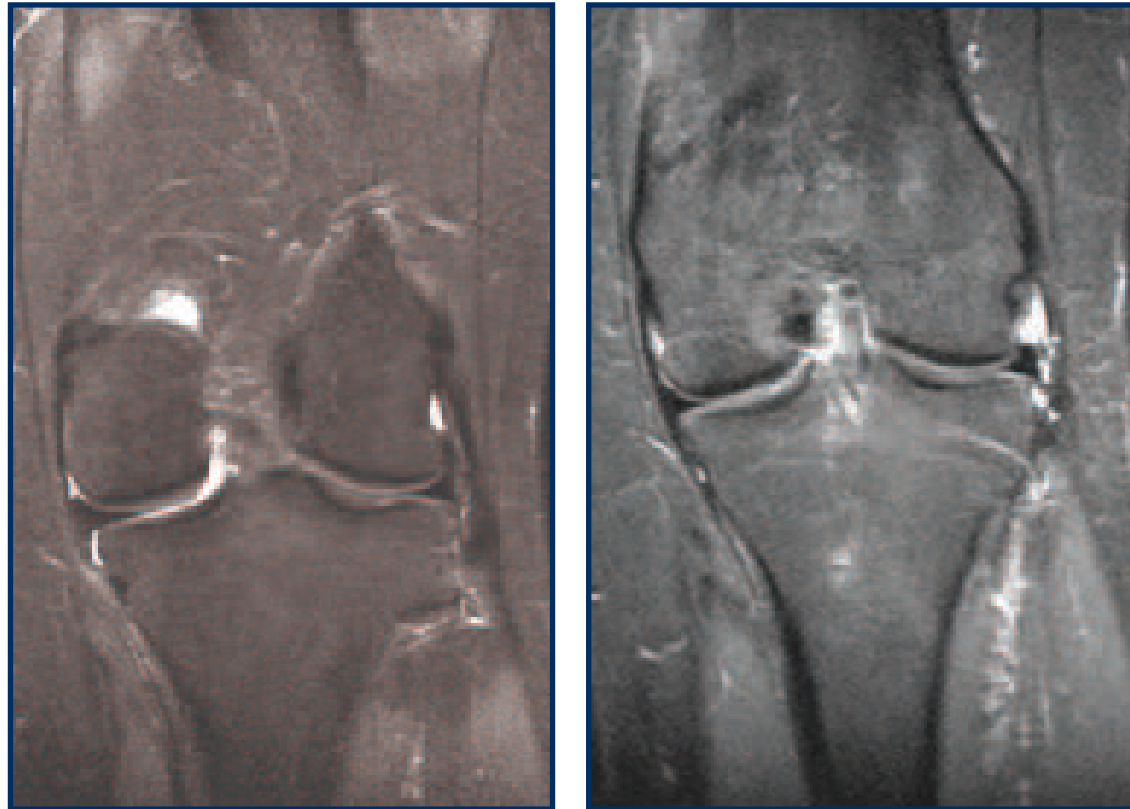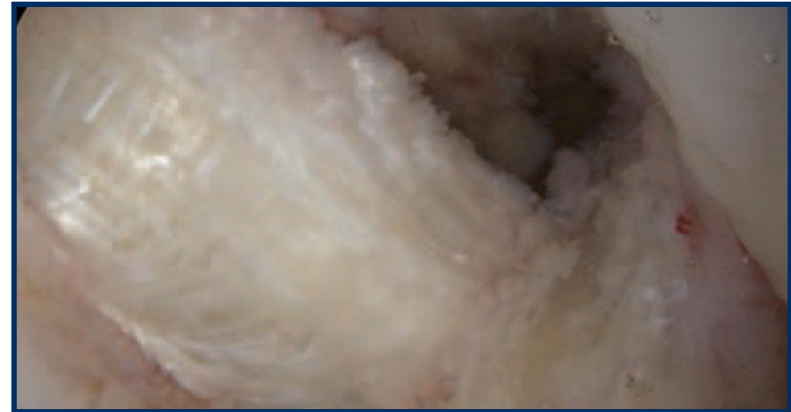


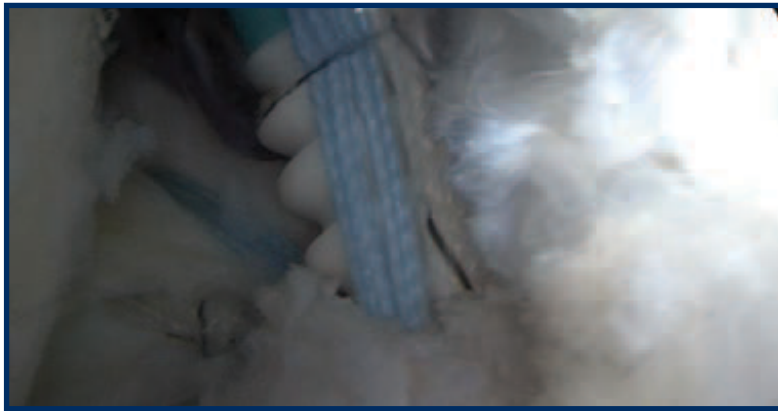**Figure 1** – Pre-operative (left) and post-operative (right) sagittal MRI images. On the left, the proton density MRI image shows a high-grade chronic tear of the PCL. The post-operative T1-weighted MRI shows the PCL allograft anchored with a well-placed tightrope through the tibia and interference screw into the femur.



**Figure 2** – Pre-operative (left) and post-operative (right) coronal STIR MRI images. The injury MRI shows extrusion of the medial meniscus consistent with root detachment. The post-repair image on the right shows no evidence of meniscal extrusion.



**Figure 3** – Intraoperative images showing the suture anchor fixation of the medial meniscal root (top) and the well-placed PCL allograft (bottom).