

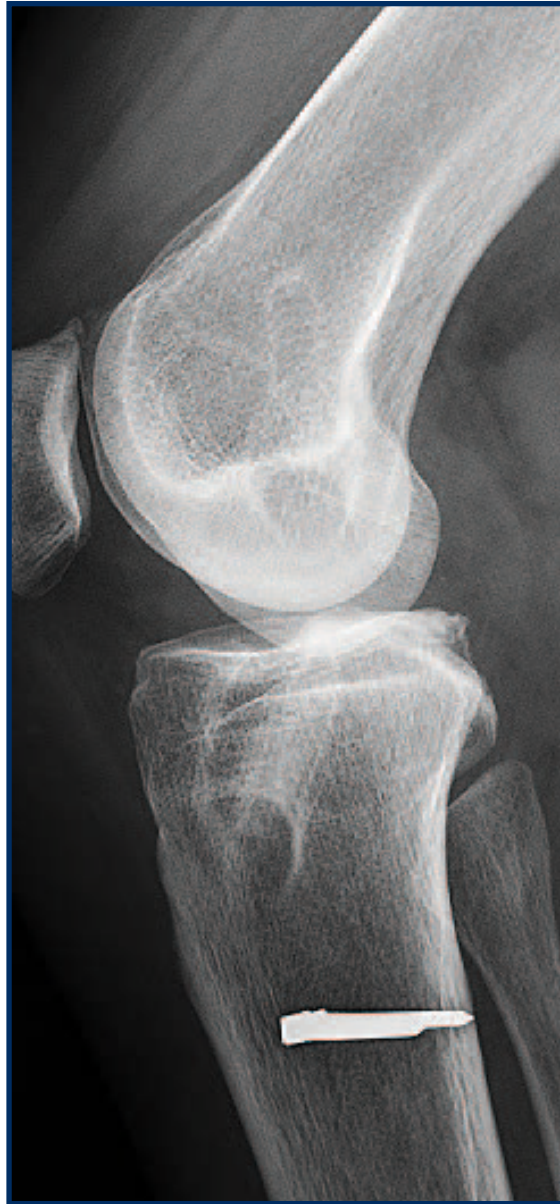
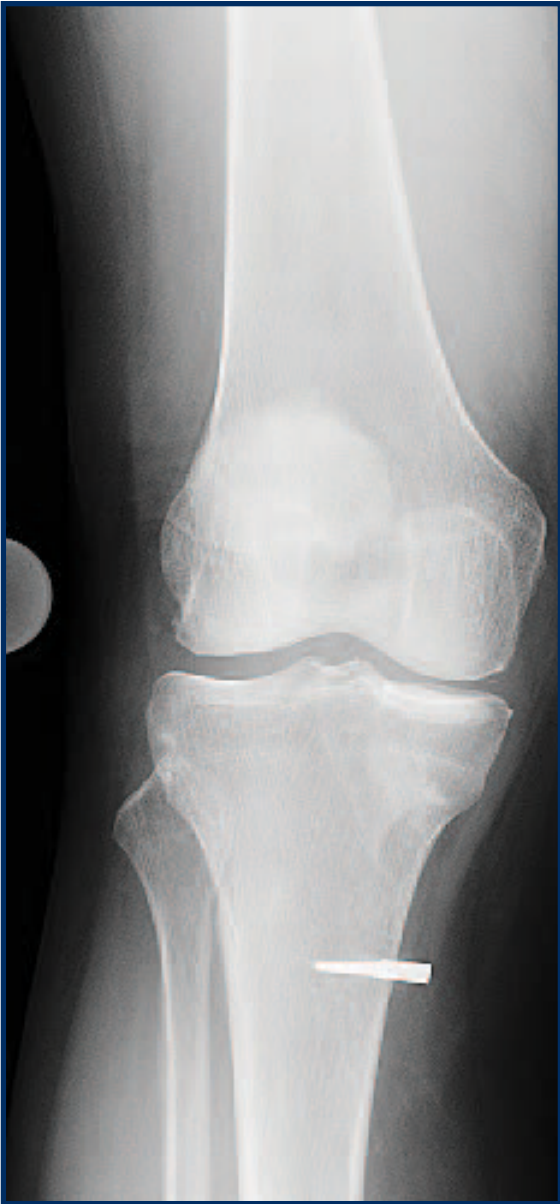
Figure 1 -
Pre-operative
radiograph
demonstrating
ACL tunnel
enlargement.

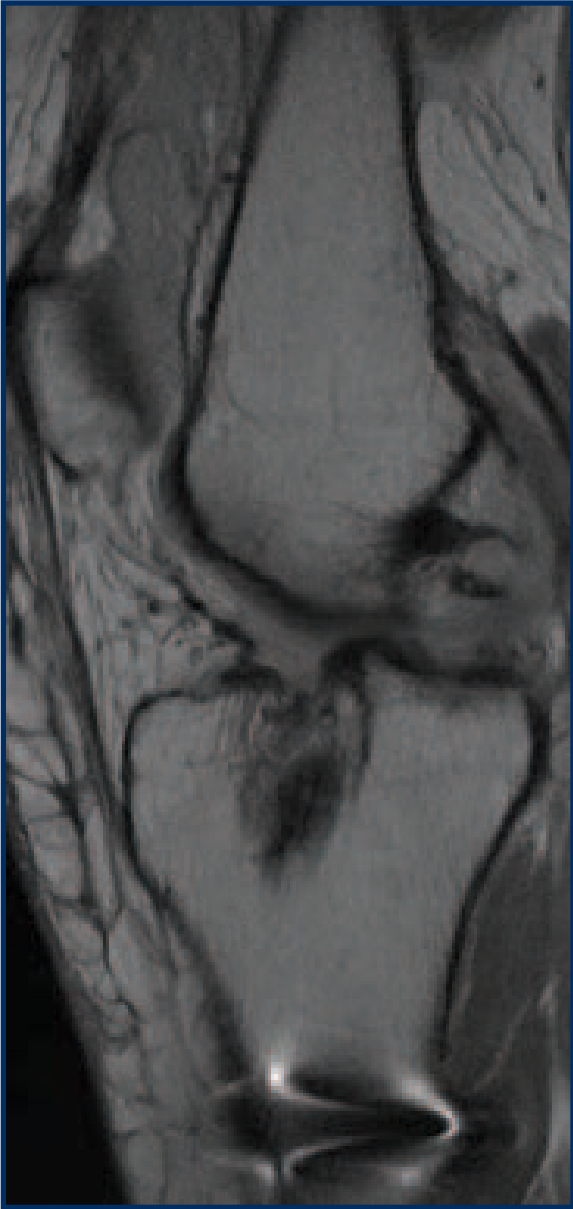


Figure 2 – Pre-operative MRI showing failed ACL reconstruction, anterior tibial subluxation, and synovitis.

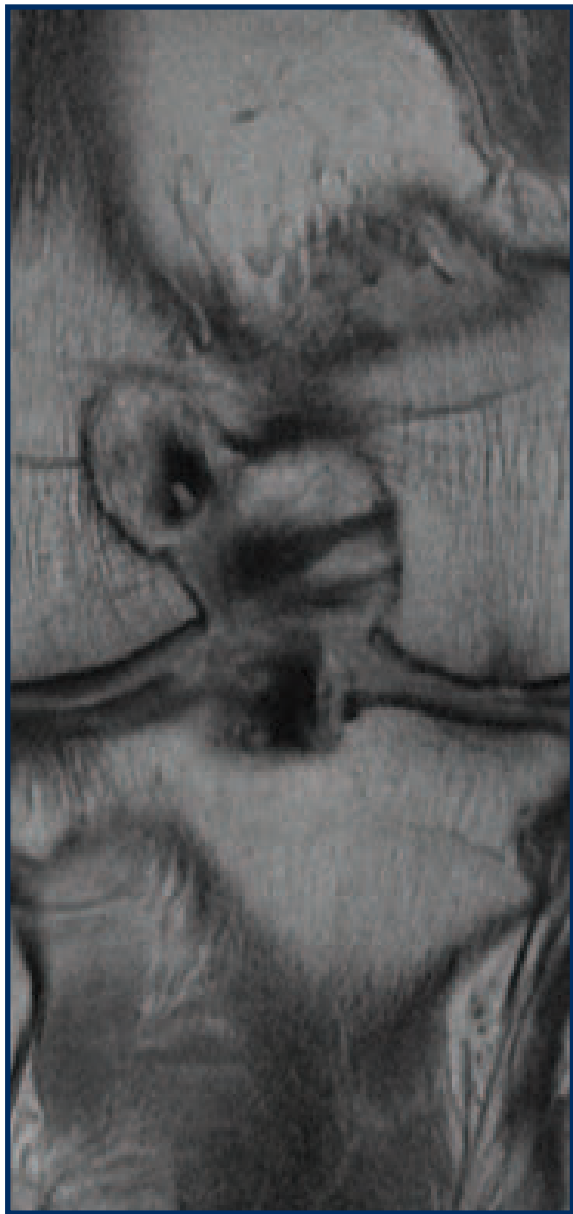

Figure 3 – Pre-operative MRI showing femoral ACL tunnel widening.

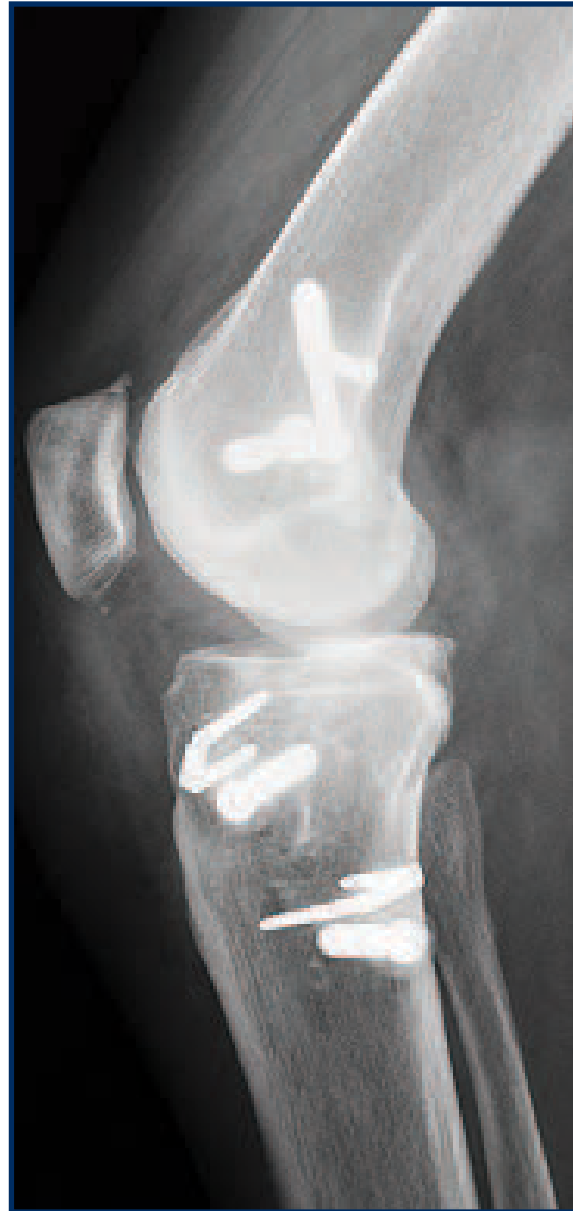
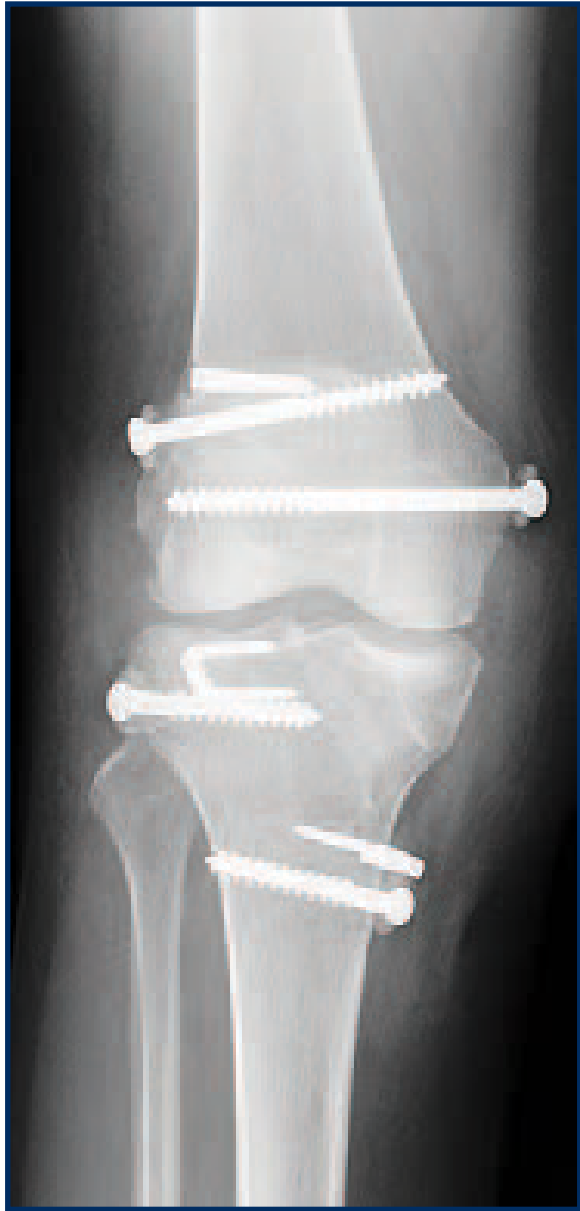
Figure 4 –
Pre-operative
radiograph
demonstrating
ACL tunnel
enlargement.