

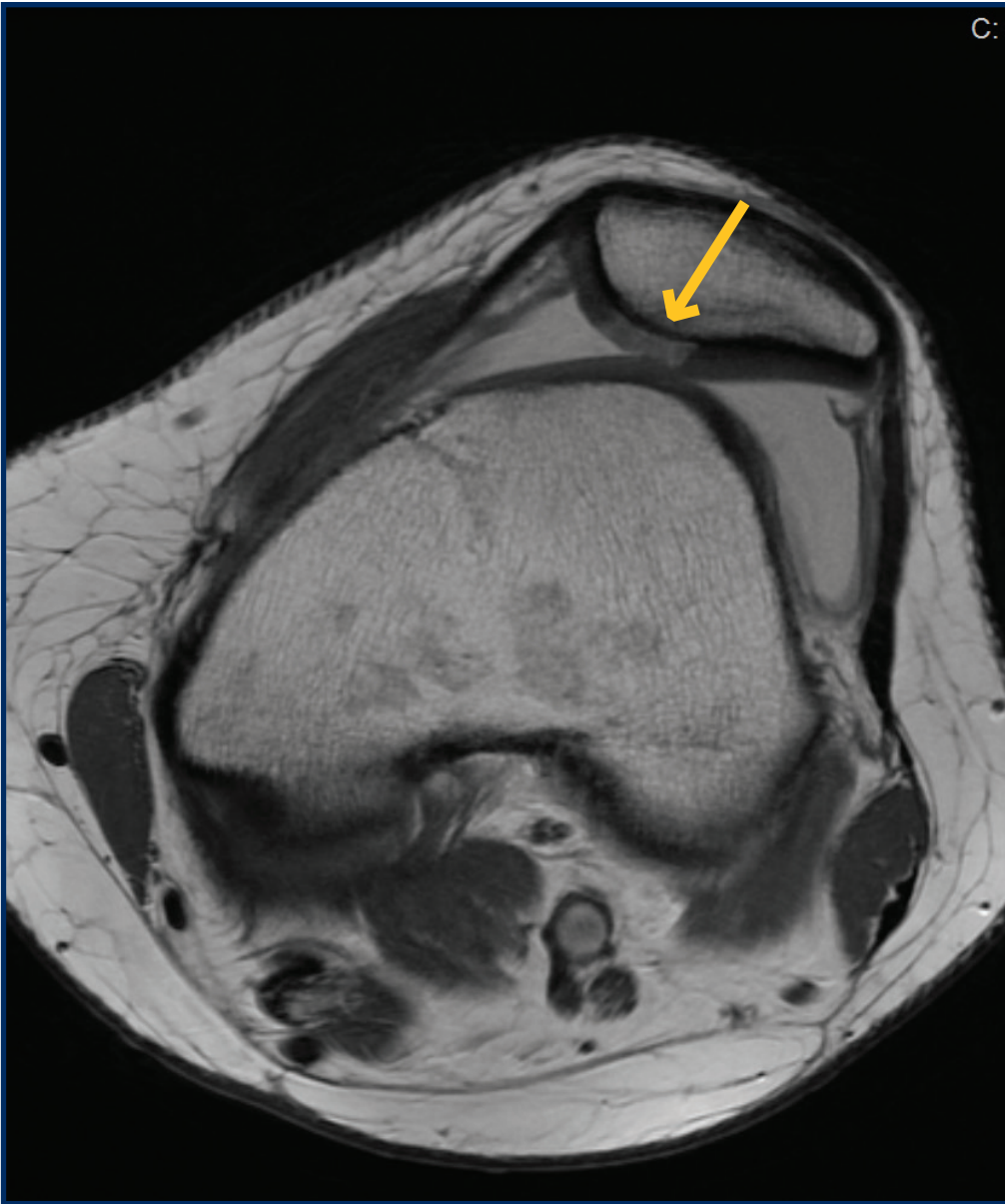Figure 1 – Axial MRI depicting trochlear hypoplasia, lateral patellar subluxation, and central patellar cartilage lesion (arrow).

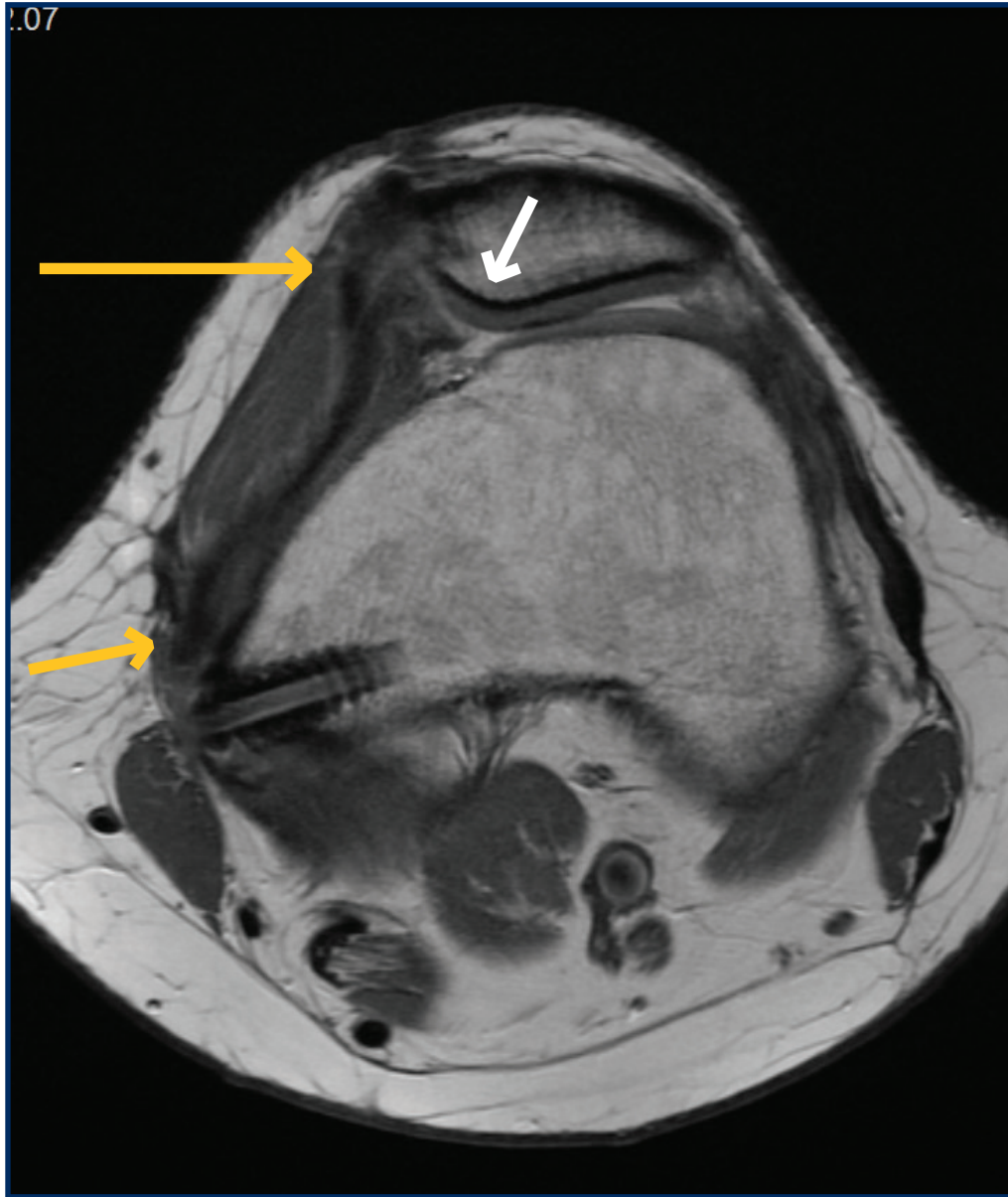


Figure 2 – Postoperative MRI depicting reconstructed MPFL (yellow arrows) with improved patellar alignment and excellent fill of cartilage defect (white arrow).