

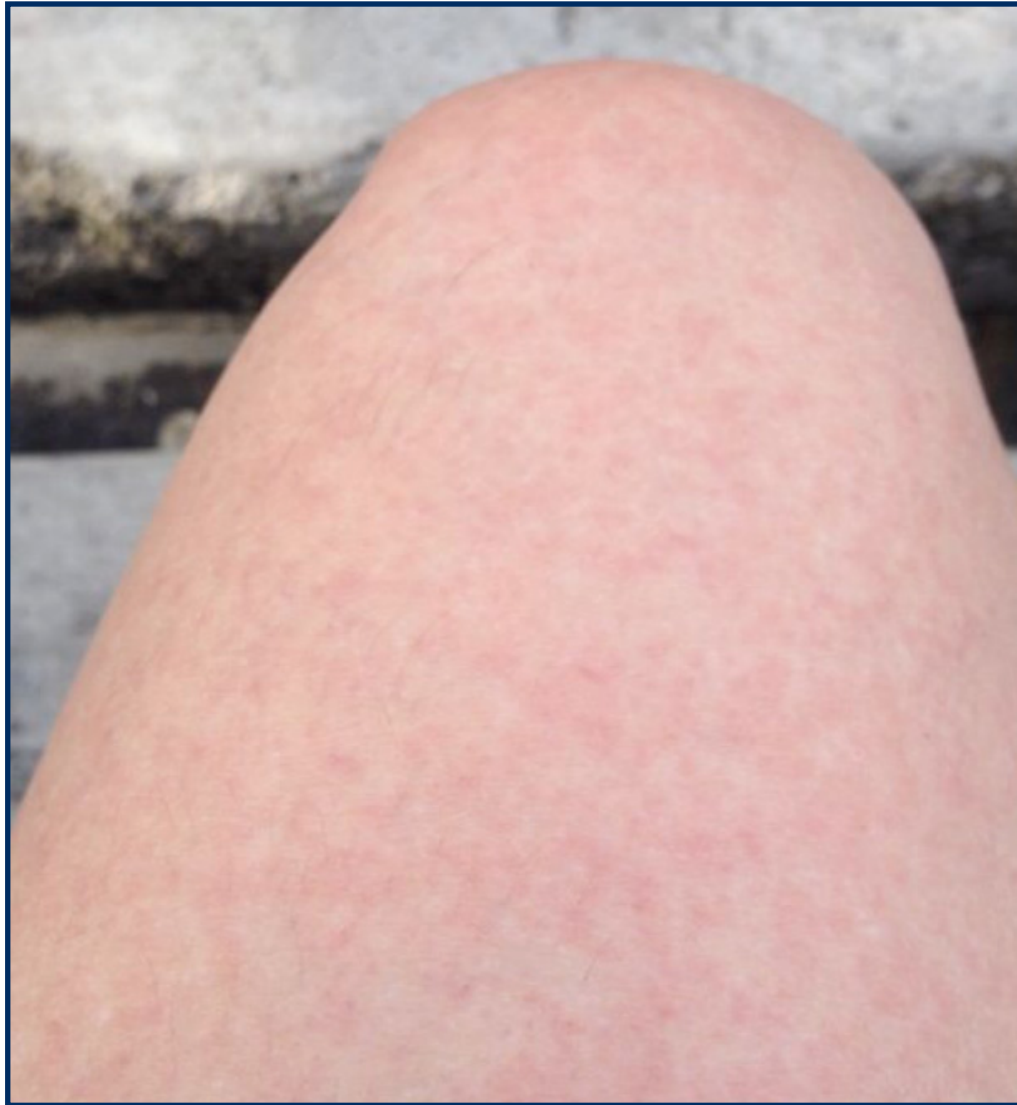

Figure 1 – Erythematous maculopapular rash on thigh.

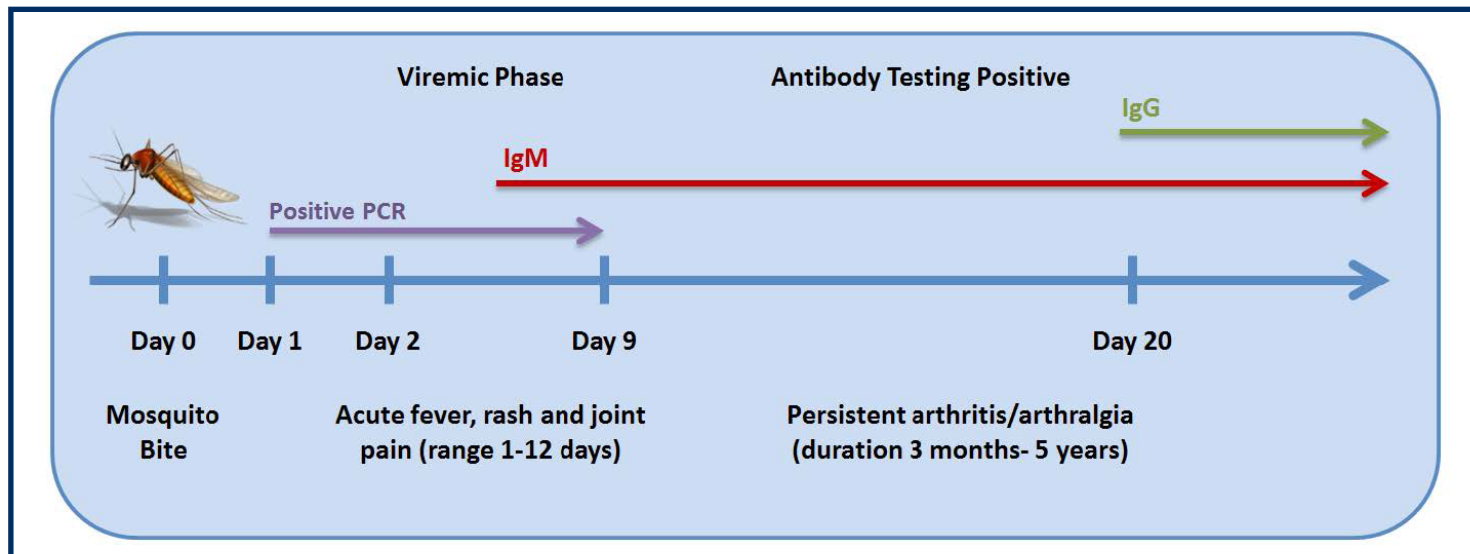


Figure 2 – Clinical course of Chikungunya.

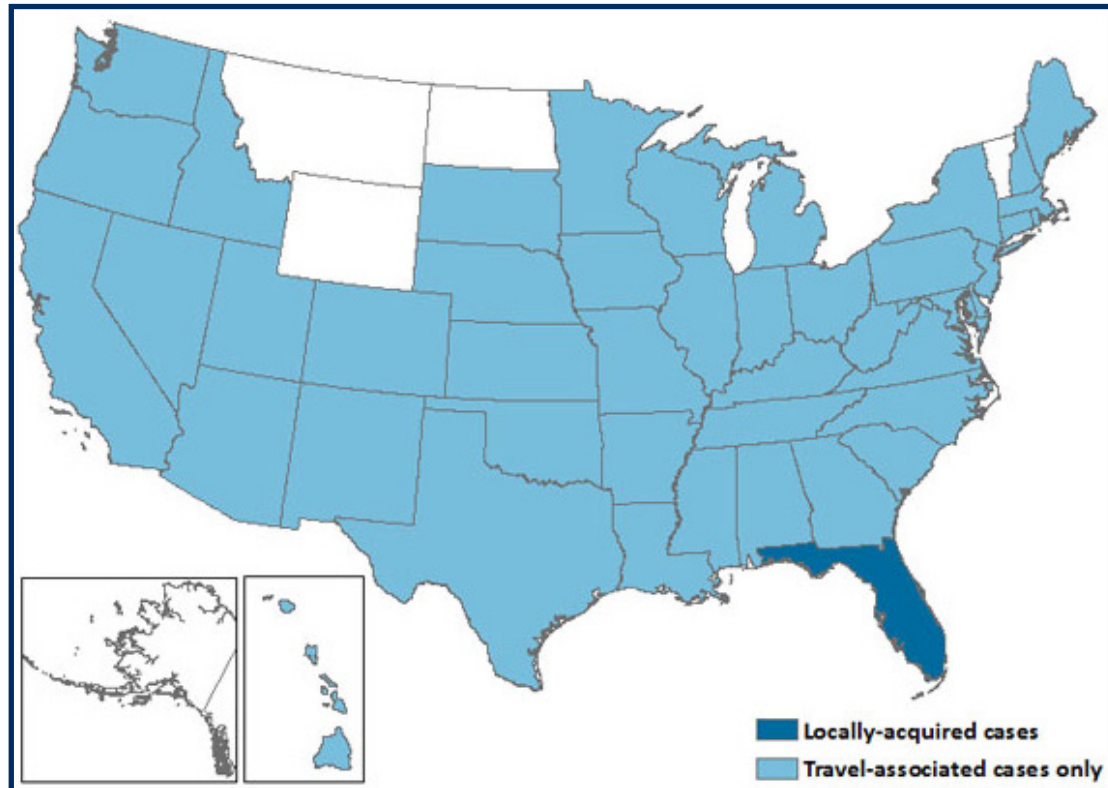


Figure 3 – Chikungunya reported by the CDC (3).