

APPENDIX:

NEUROVASCULAR ANATOMY OF THE LOWER EXTREMITY

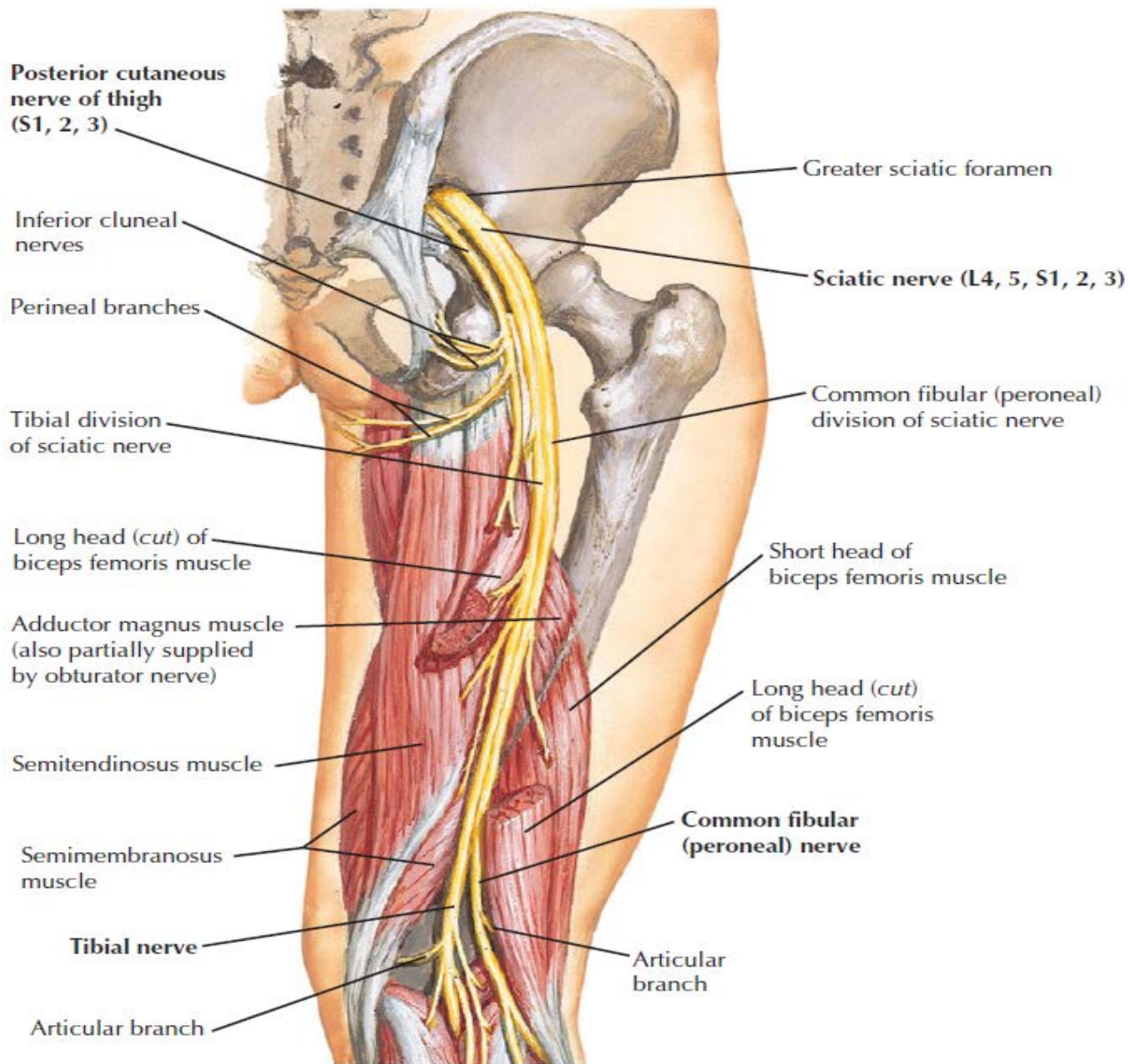
QICE Learning Module #1

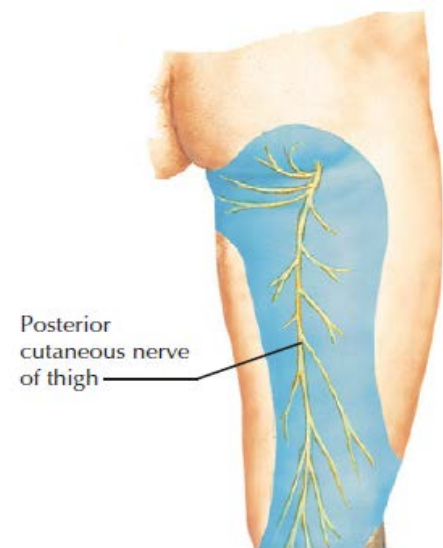
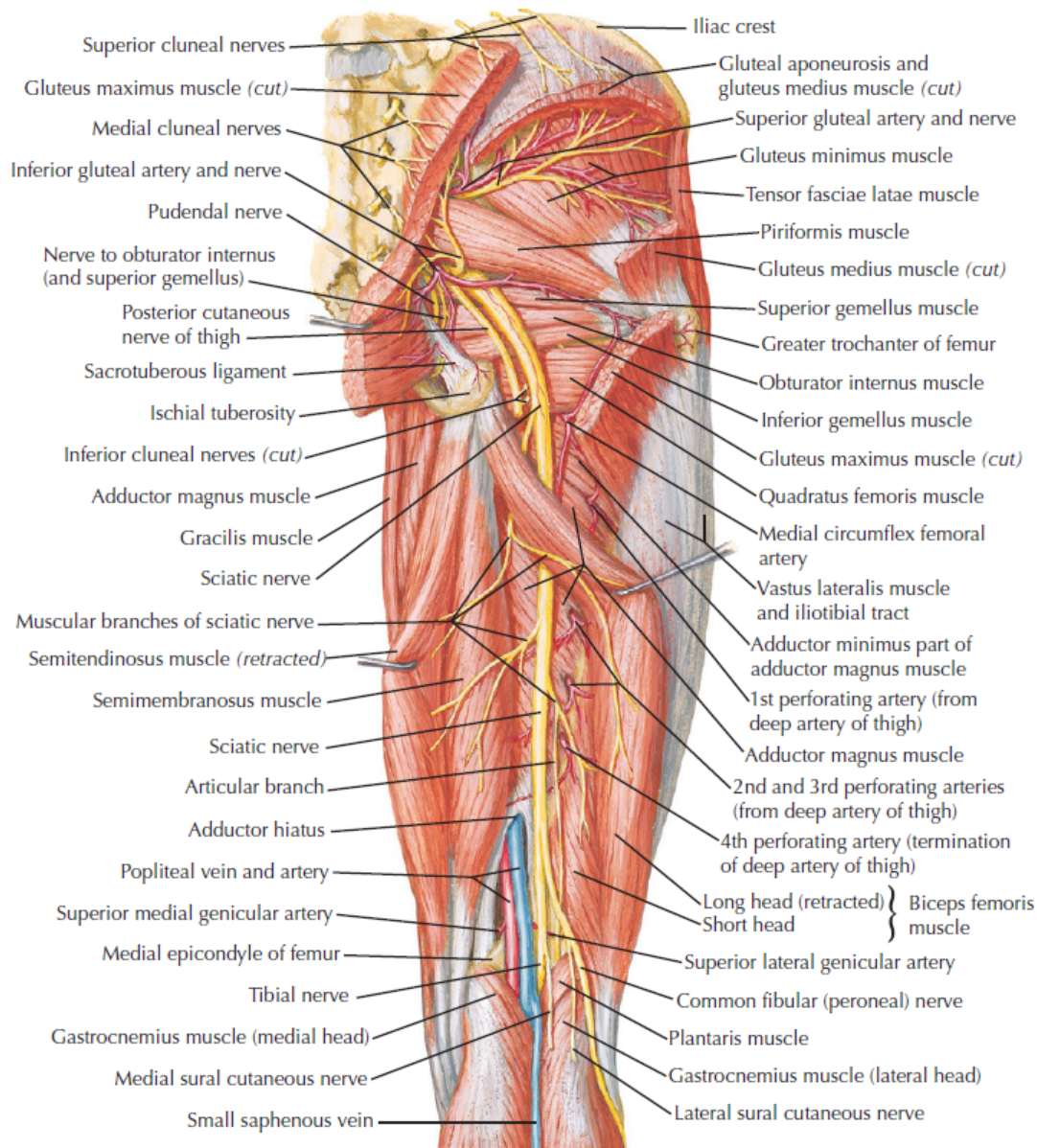
Peter Derman, MD, MBA

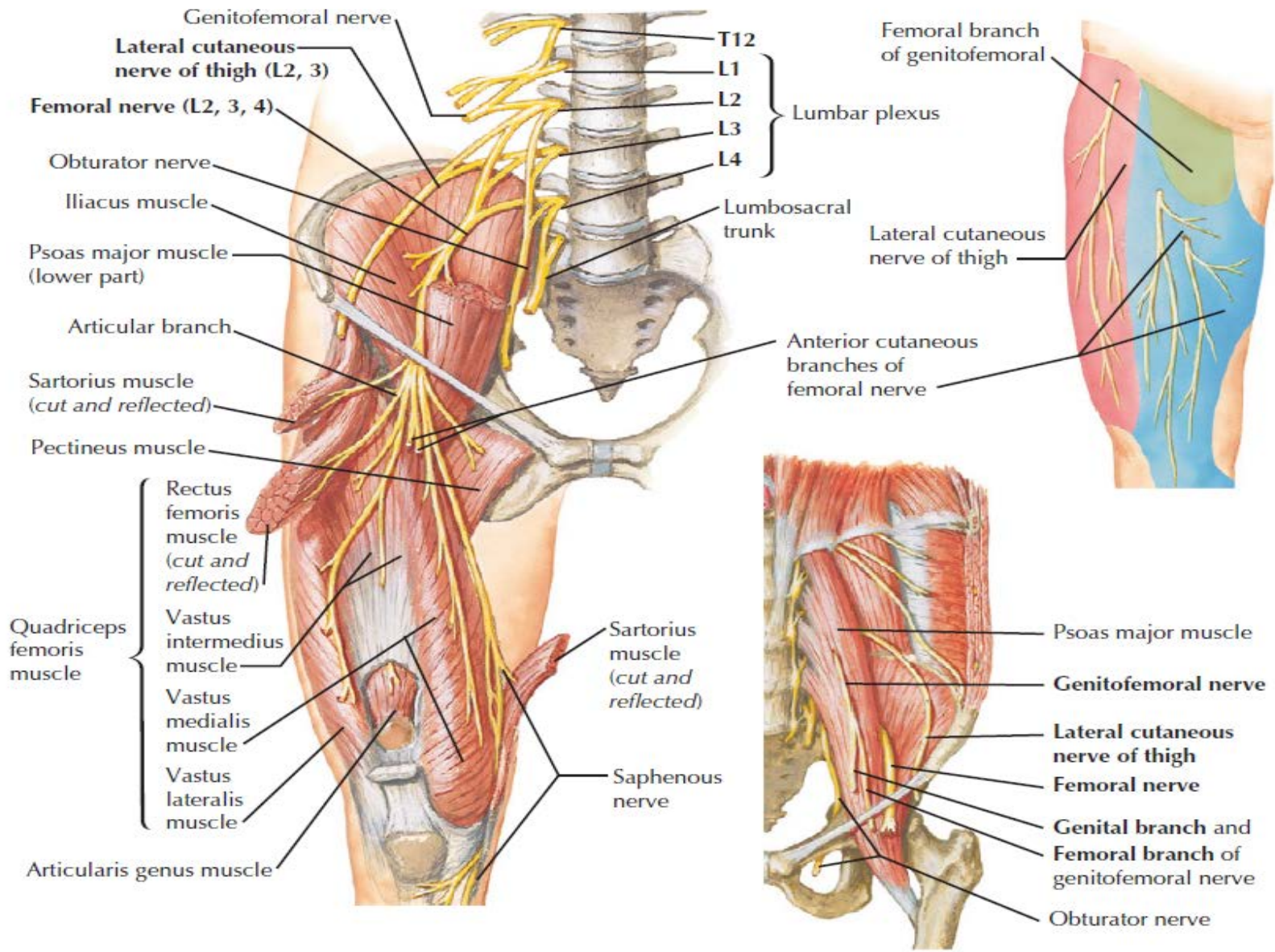
Orthopaedic Resident

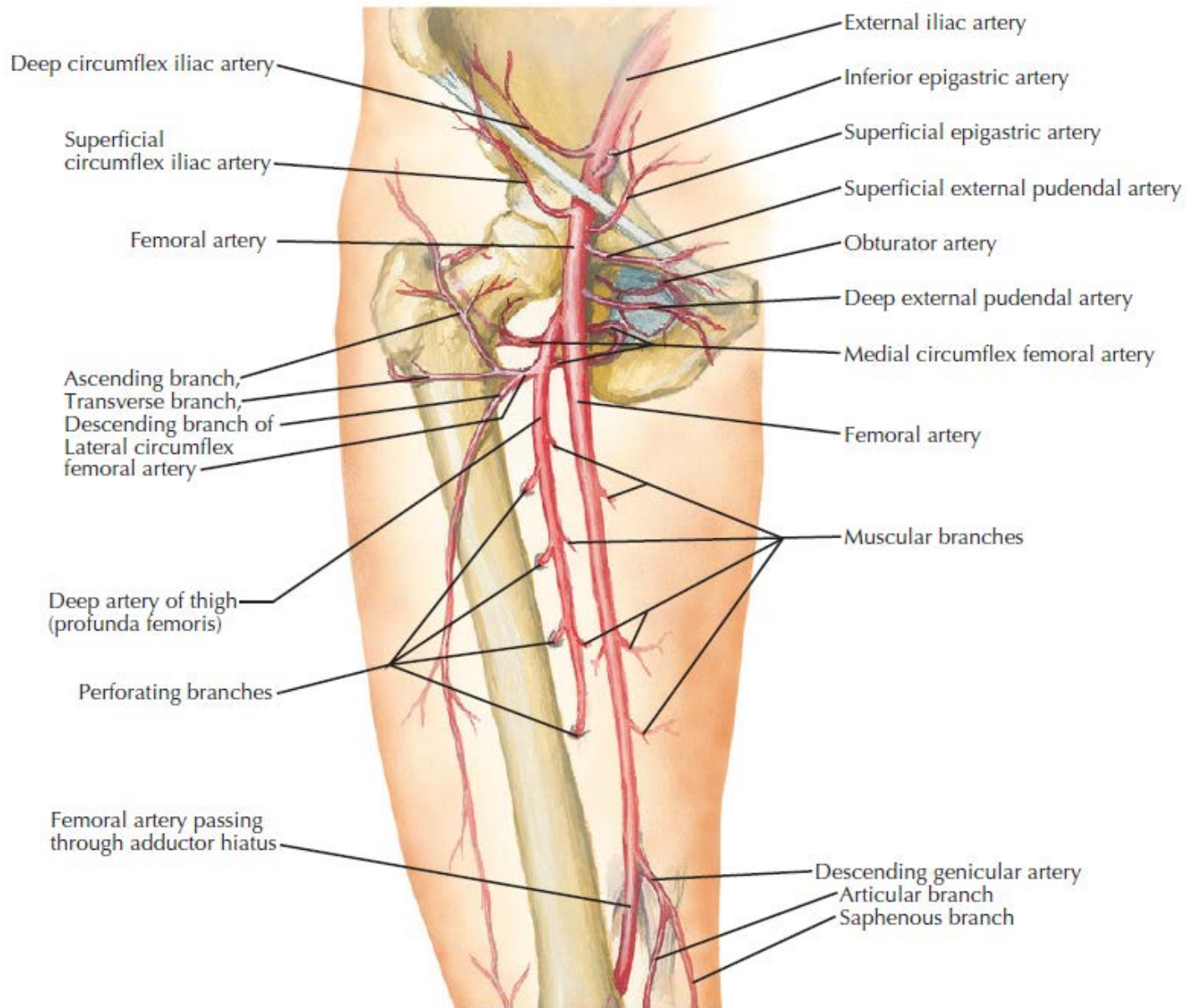
All illustrations courtesy of:

Netter's Concise Orthopaedic Anatomy, 2nd Edition

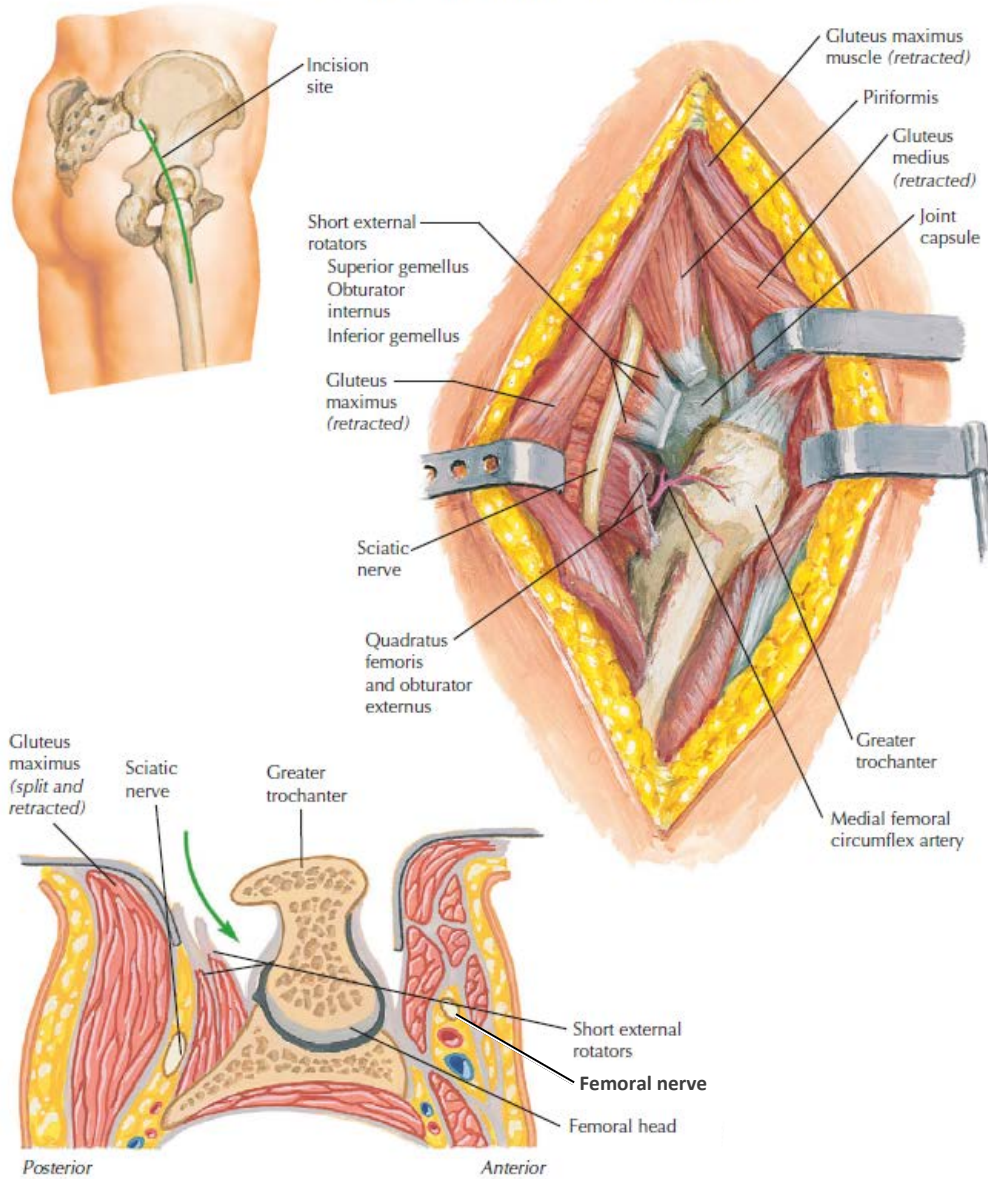






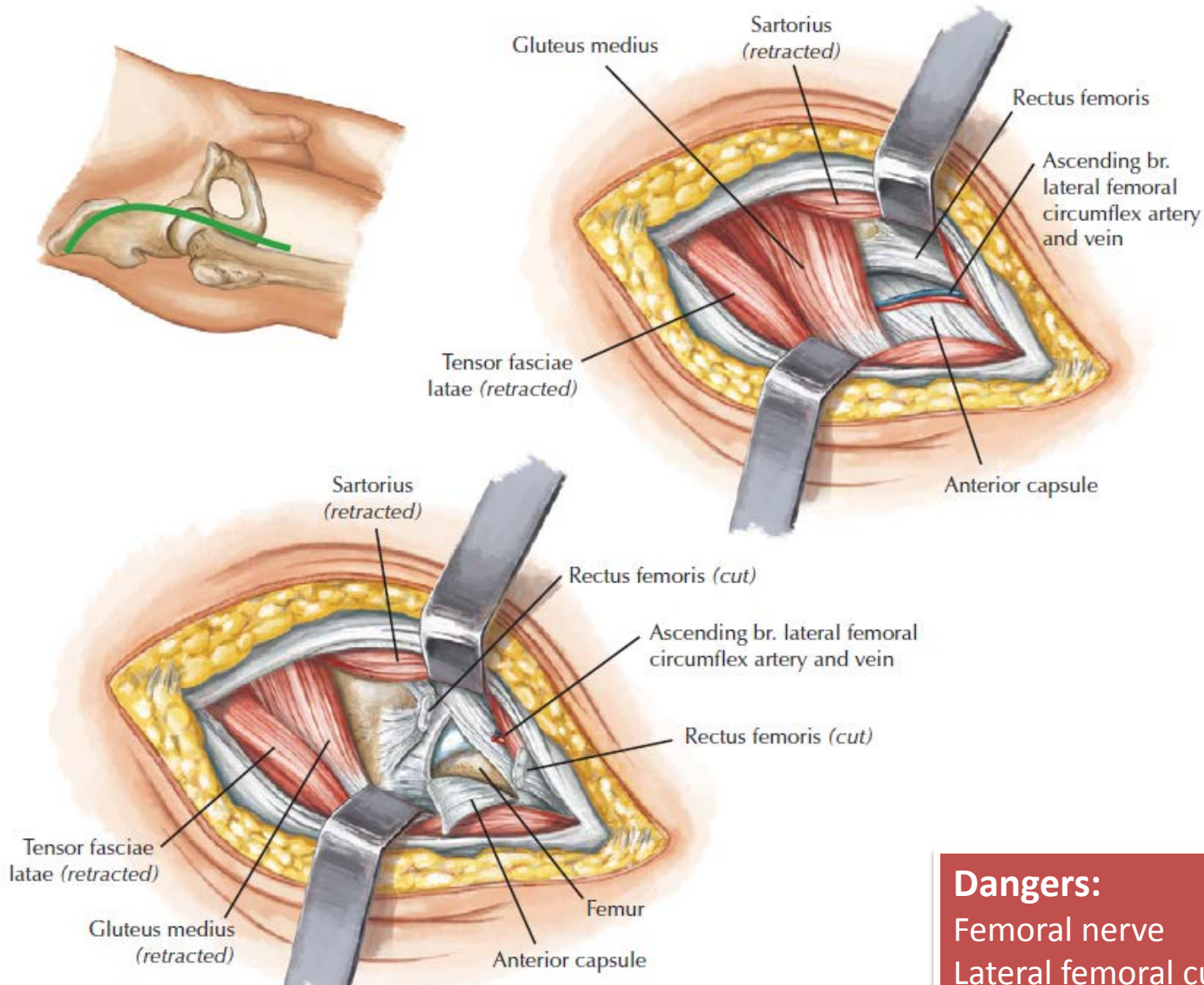


Posterior (Southern) Approach to Hip Joint



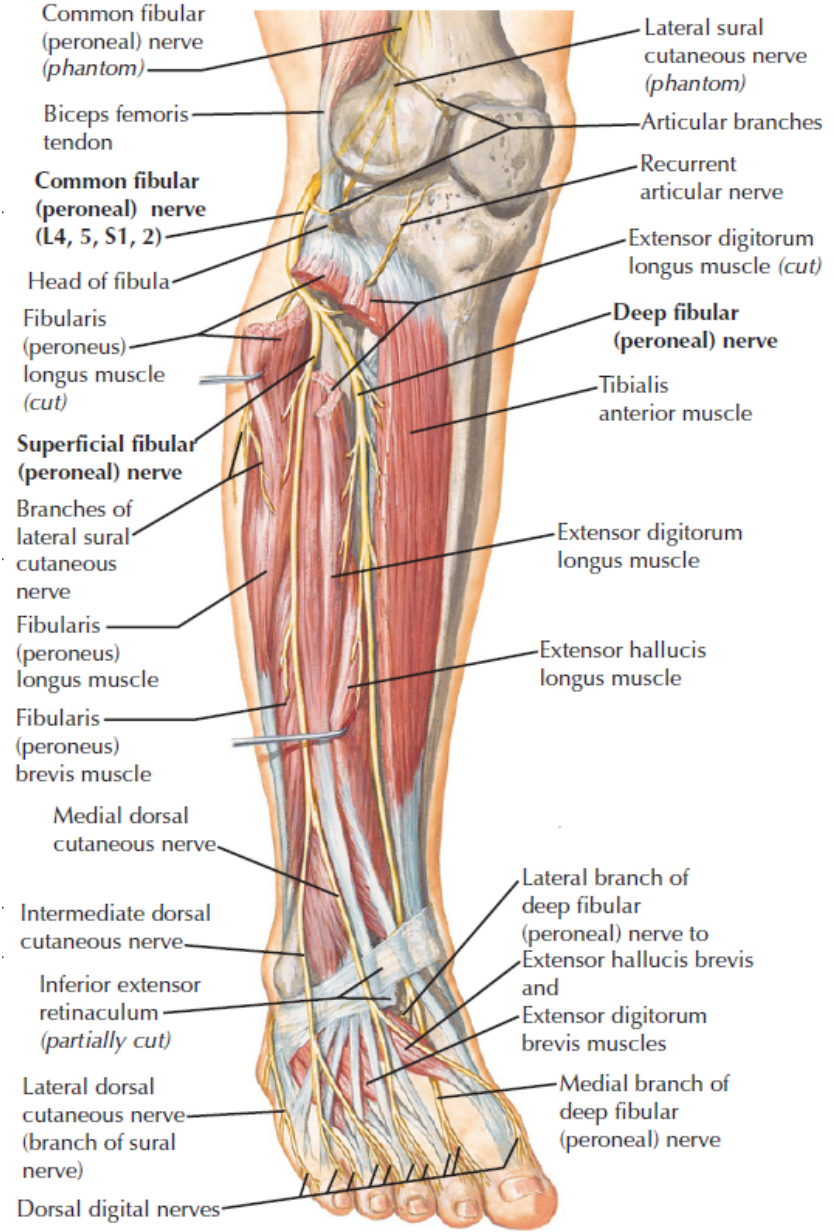
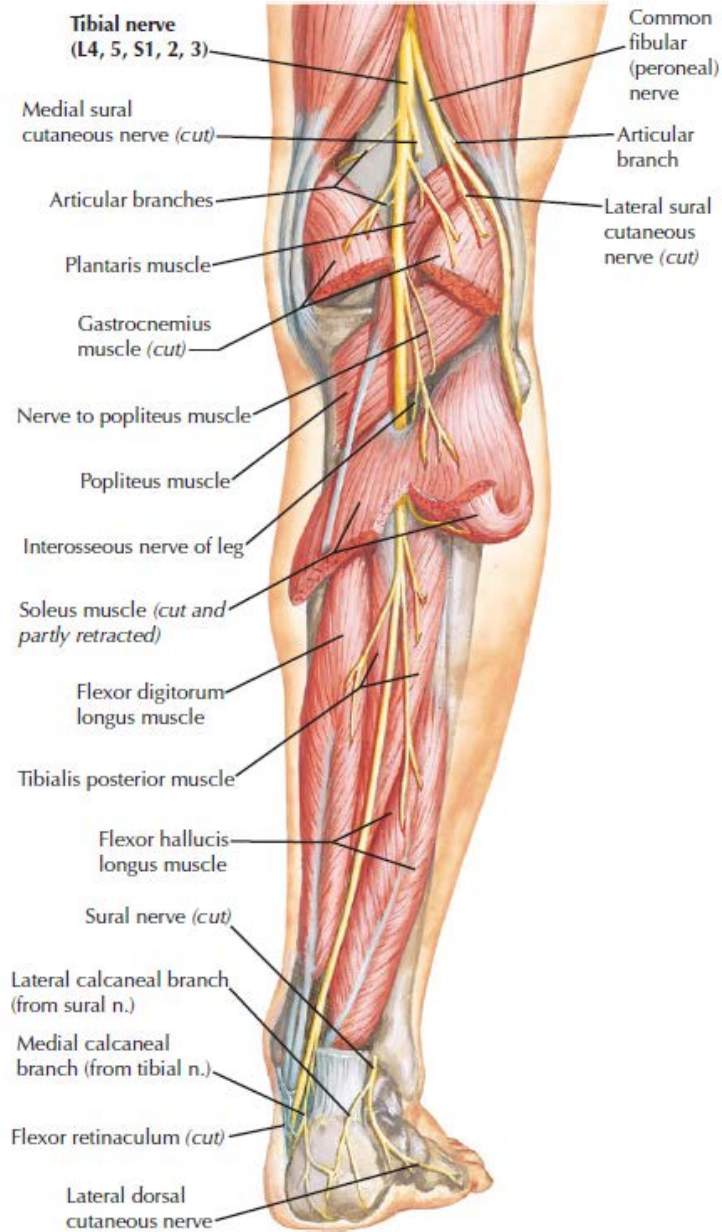
Dangers:
 Sciatic nerve
 Femoral nerve

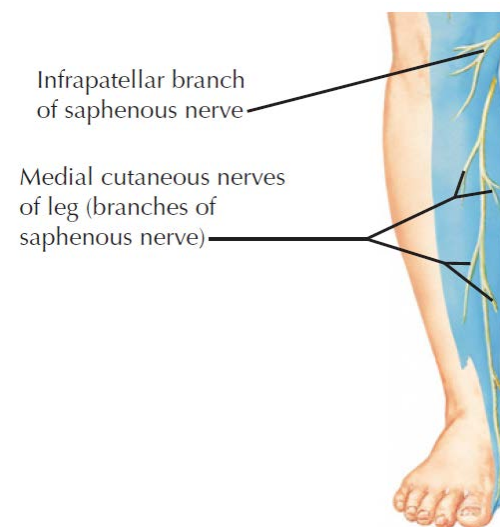
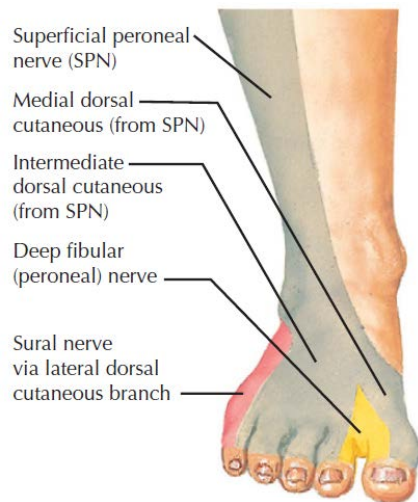
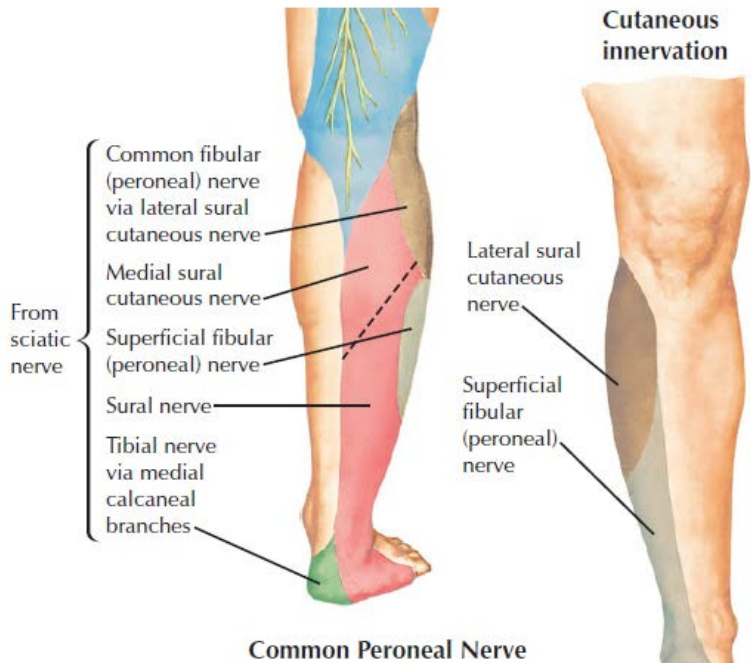
Anterior Approach to Hip

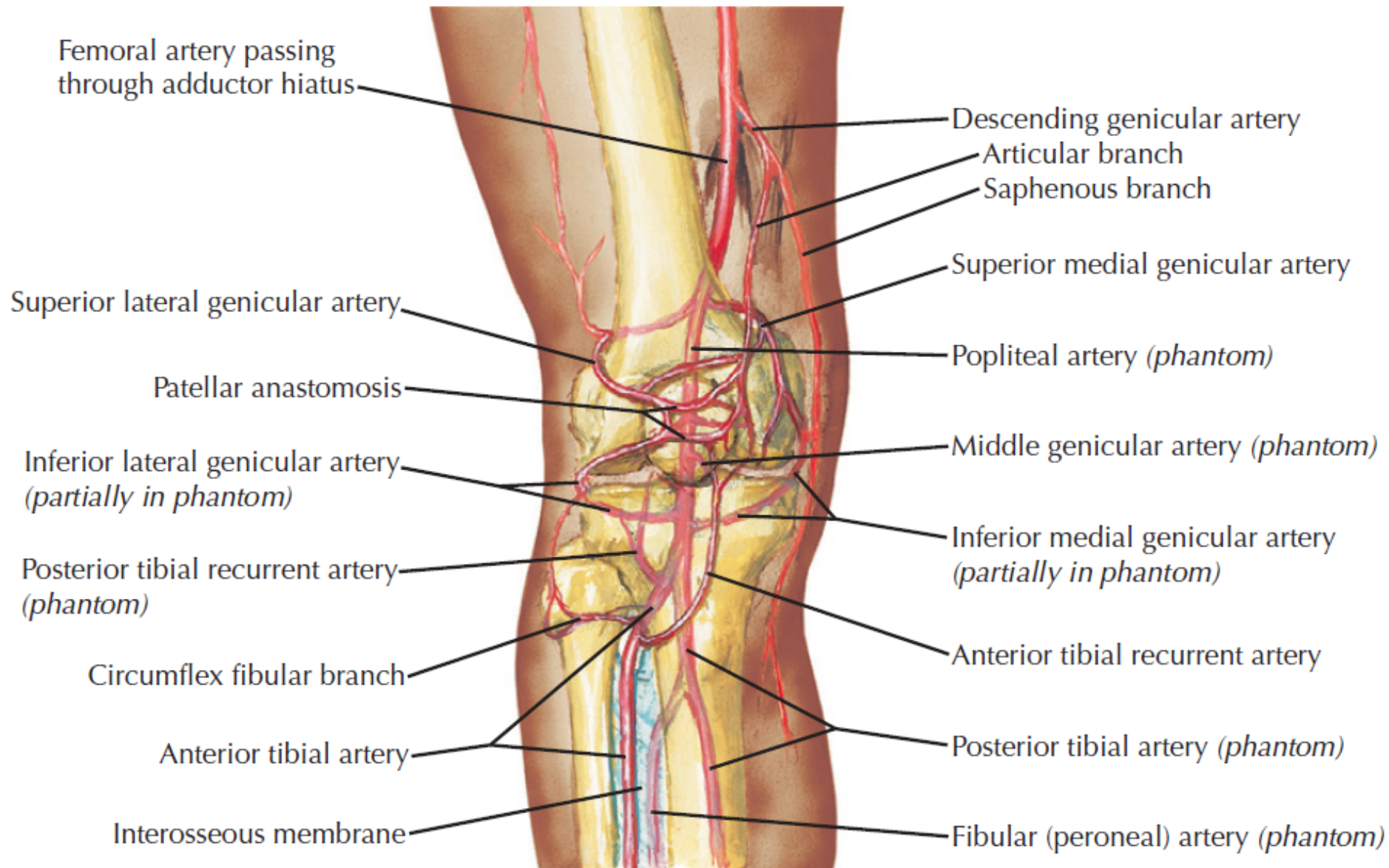


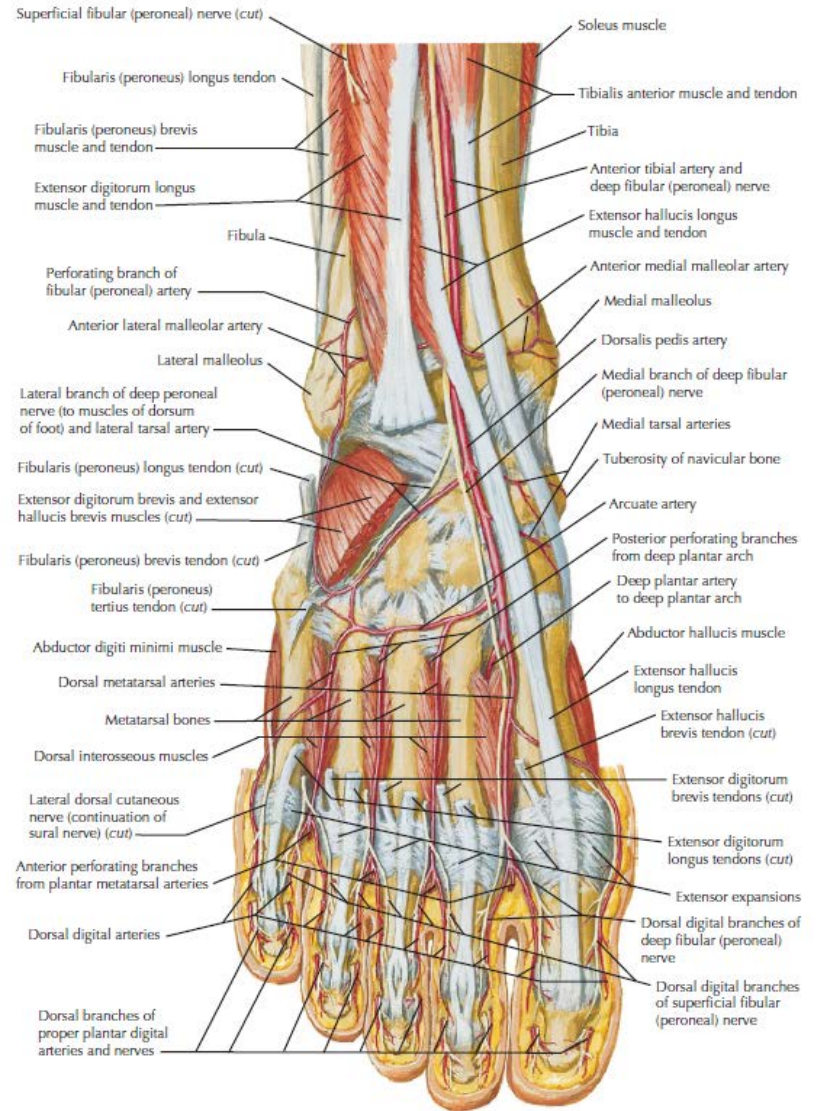
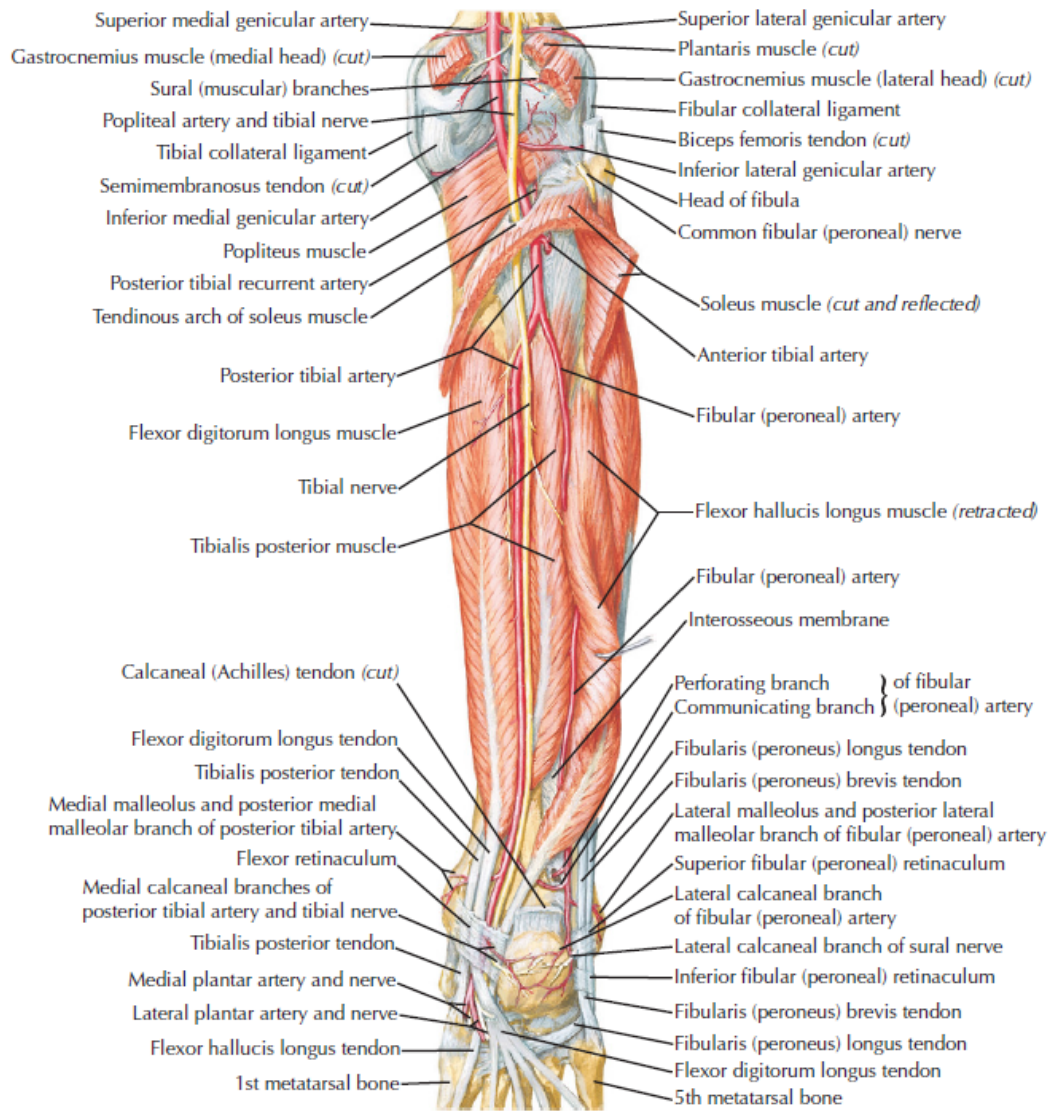
Dangers:

Femoral nerve
Lateral femoral cutaneous nerve

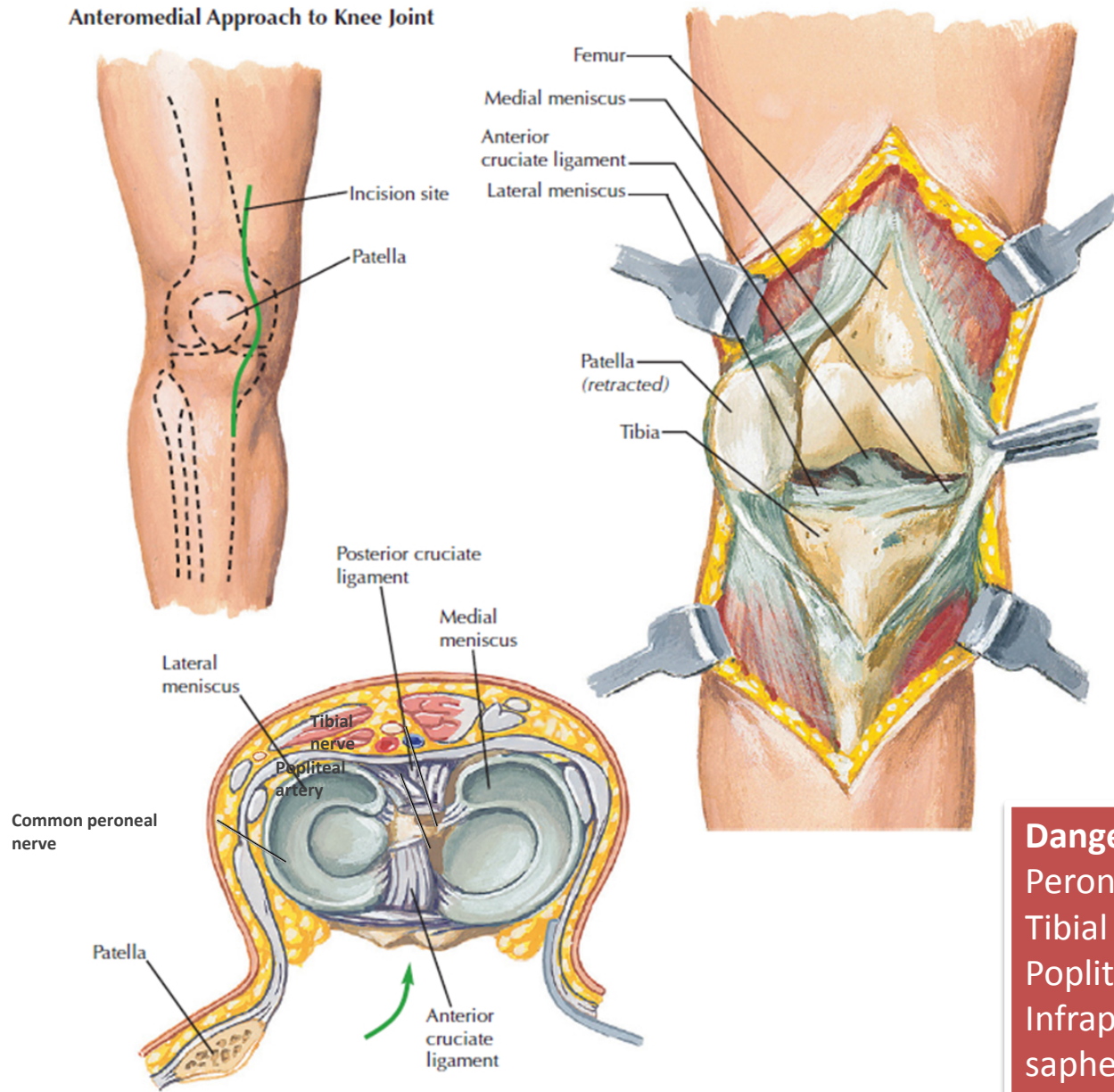








Anteromedial Approach to Knee Joint



Dangers:
 Peroneal nerve
 Tibial nerve
 Popliteal artery
 Infrapatellar branch of saphenous nerve