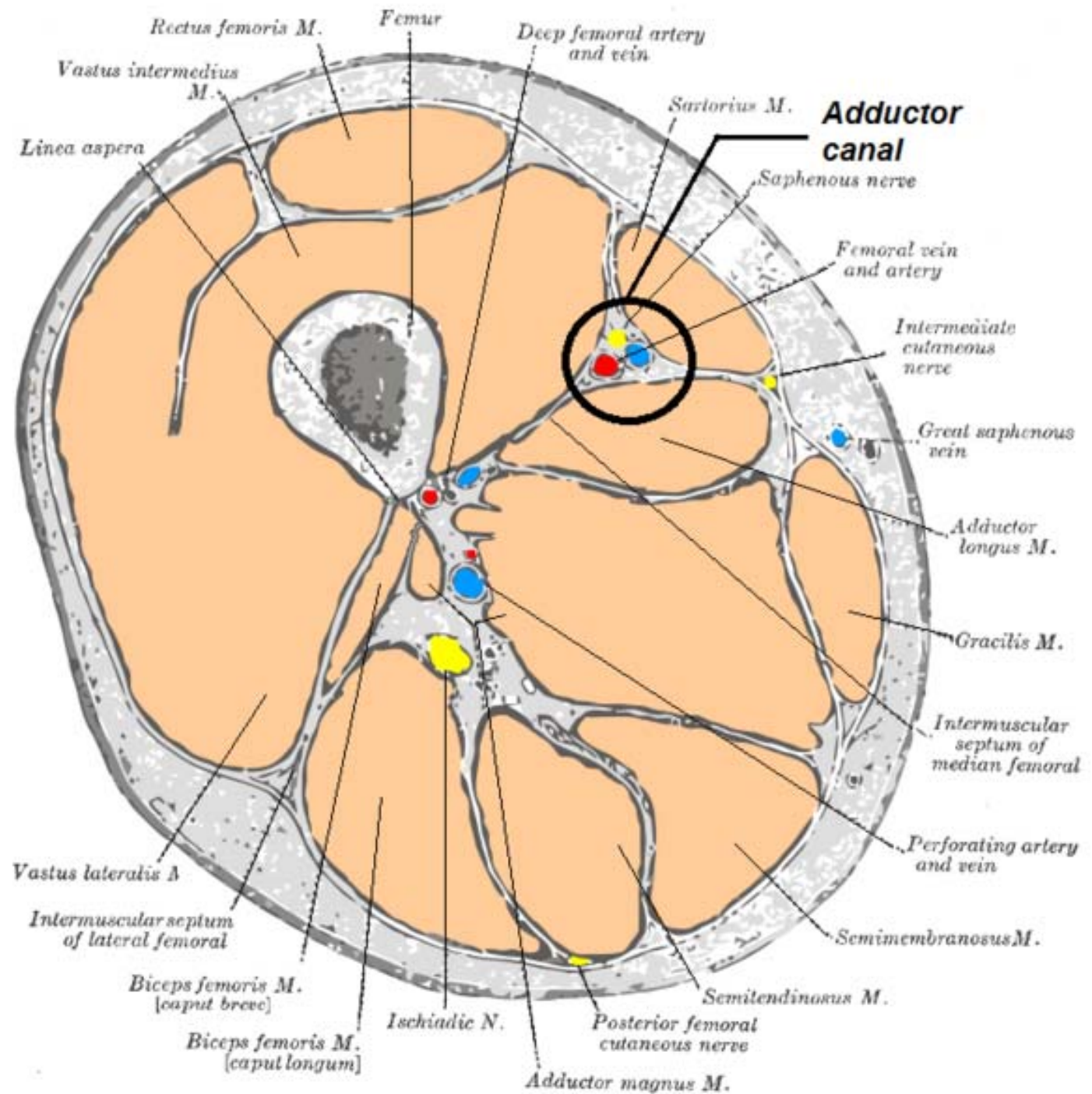


Adductor Canal Dissection

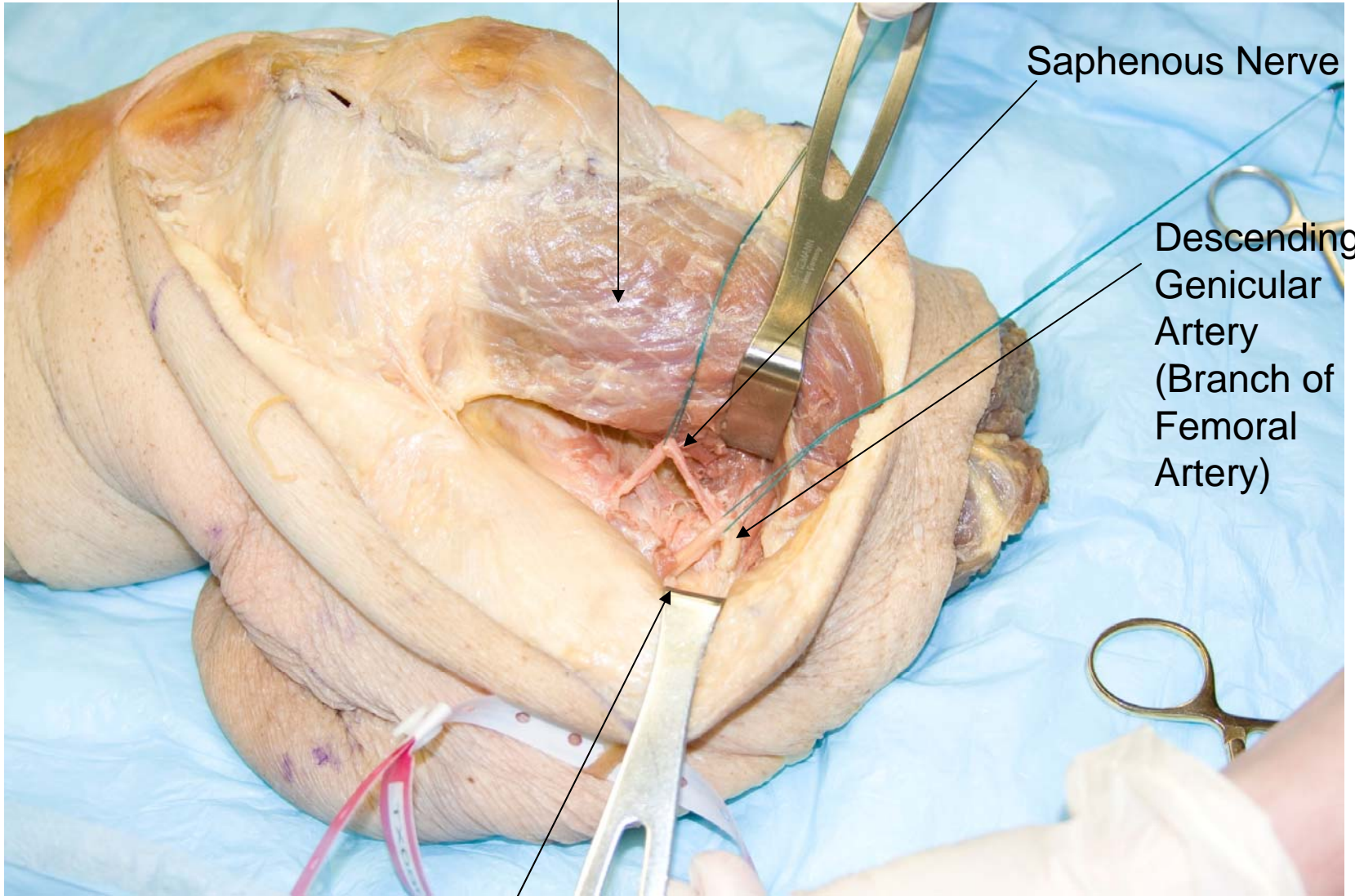


Vastus Medialis

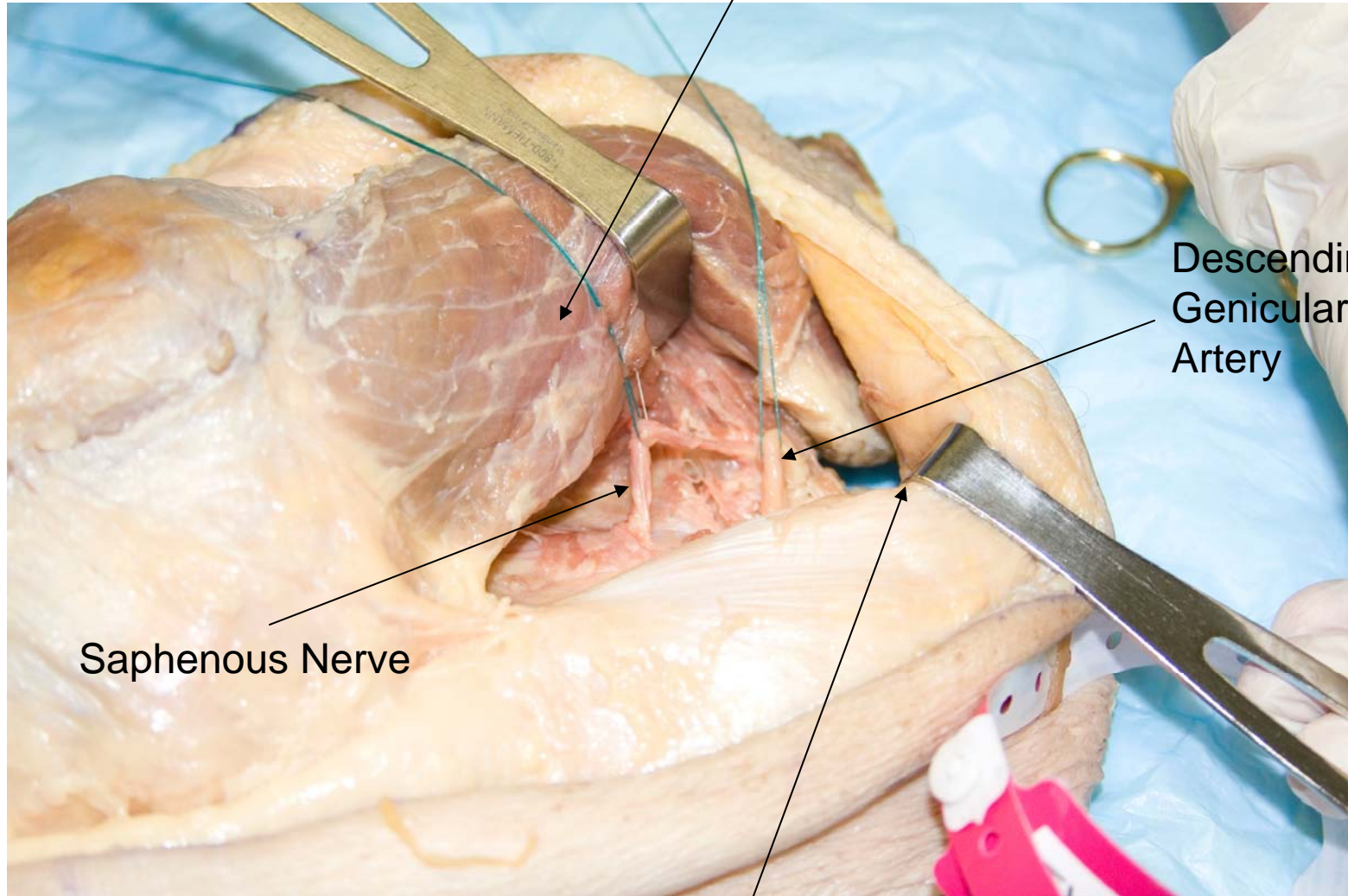
Saphenous Nerve

Descending
Genicular
Artery
(Branch of
Femoral
Artery)

Retracted Sartorius



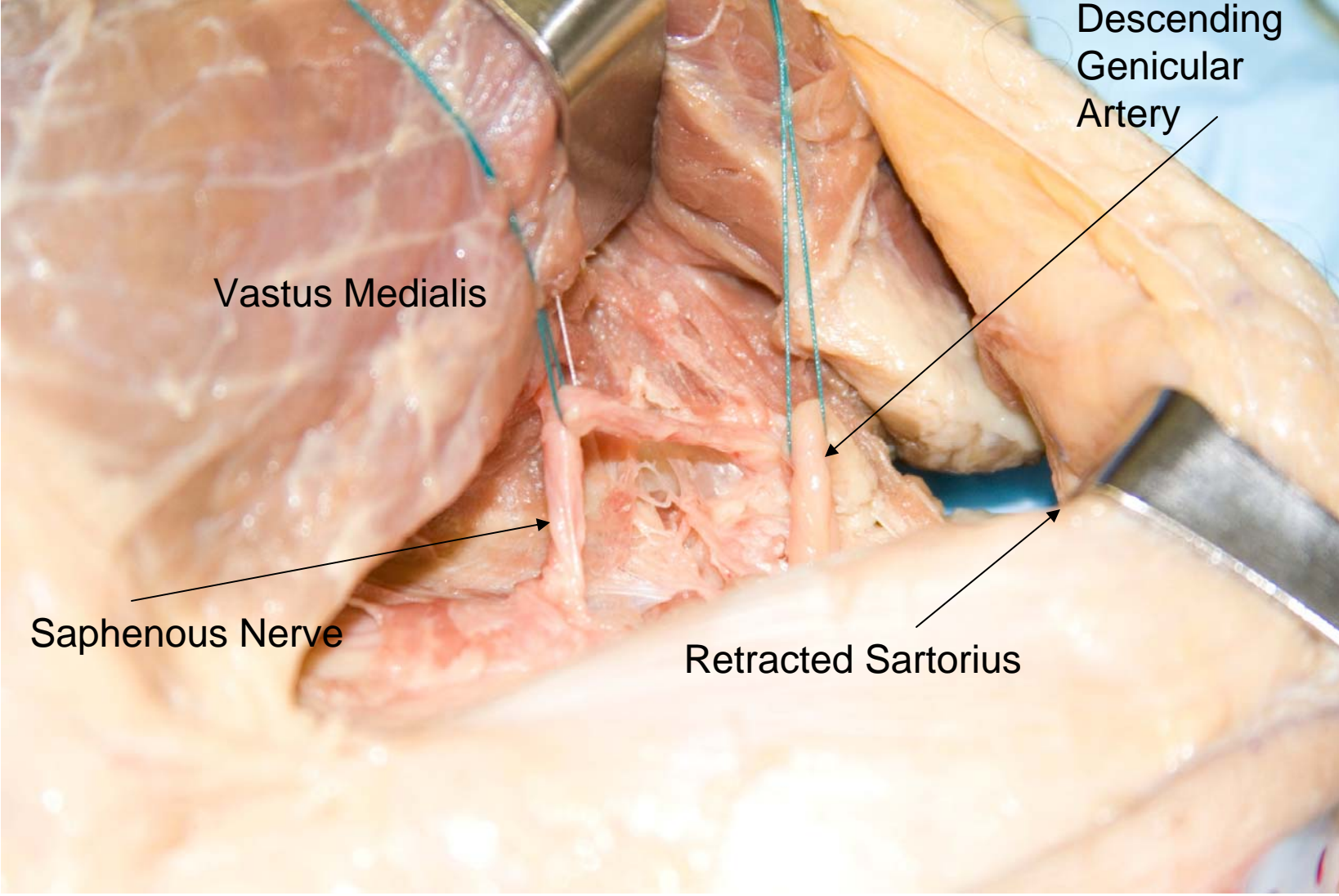
Vastus Medialis



Descending
Genicular
Artery

Saphenous Nerve

Retracted Sartorius



Vastus Medialis

Descending Genicular Artery

Saphenous Nerve

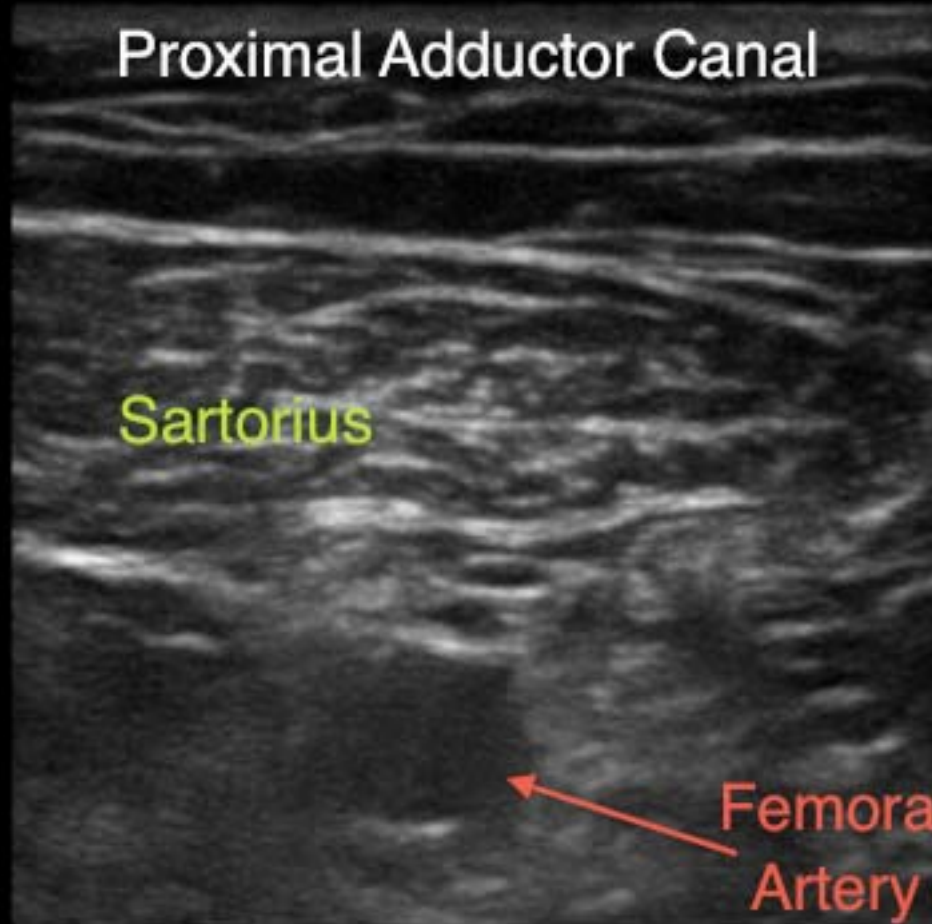
Retracted Sartorius



Gen
S

MB

Proximal Adductor Canal



Nrv
L38
55%
MI
1.3
TIS
0.2

A

B

3.8



Gen



0



Guide



MB On



Dual

Page 1/2

Distal Adductor Canal

Vastus Medialis

Sartorius

Femur

Femoral Artery

Femoral Vein



98%

MI

0.8

TIS

0.2



4.7