

Assessment of Bone Healing During Antegrade Intramedullary Rod Femur Lengthening Using Radiographic Pixel Density

Ettore Vulcano, MD
Jonathan S. Markowitz, BS
Shabaz Ali
Joseph Nguyen, MPH
Austin T. Fragomen, MD
S. Robert Rozbruch, MD

Abstract

Introduction: Premature full weight bearing after femur lengthening can lead to implant failure, telescopic nail shortening, and regenerate fracture. This study aimed at performing a retrospective analysis of the correlation between pixel density ratio (PDR) calculations and clinical readiness for weight bearing in patients undergoing intramedullary nail-mediated femoral distraction osteogenesis.

Methods: Thirty-two patients who underwent antegrade femur lengthening were included in this study. The PDR was calculated on femur radiographs in a picture archiving and communication system for each cortex (ie, medial, lateral, anterior, and posterior) at each postoperative visit. These values were then correlated with subjective evaluation of bone healing by the treating physician with expertise in bone lengthening.

Results: Bone regenerate healing was clinically declared by the treating surgeons (S.R.R. and A.T.F.) at a mean of 8.5 weeks (range, 4 to 18 weeks). No implant failure, nail shortening, or regenerate fracture was observed. The overall mean PDR corresponding to clinical bone healing was 0.90, which was significantly ($P < 0.001$) greater than the mean value at the previous visit (0.82), when the bone was not clinically declared to be healed. The PDR increased in all cortices at all postoperative visits.

Conclusions: The findings of the present study suggest that there may be a correlation between the PDR and clinical bone healing. This observational pilot study should be followed by additional studies to understand the relationship between the PDR and bony union.

From the Icahn School of Medicine at Mount Sinai, New York, NY (Dr. Vulcano), and Hospital for Special Surgery, New York, NY (Mr. Markowitz, Mr. Ali, Mr. Nguyen, Dr. Fragomen, Dr. Rozbruch).

Correspondence to Dr. Vulcano: ettorevulcano@hotmail.com

J Am Acad Orthop Surg 2018;26:e388-e394

DOI: 10.5435/JAAOS-D-16-00949

Copyright 2018 by the American Academy of Orthopaedic Surgeons.

The use of telescopic intramedullary (IM) rods for femur lengthening is quickly gaining in popularity. IM rods decrease the high complication rates of pin track infections, joint stiffness contractures due to tethering of the muscles by the pins, and large pin track scars that occur with external fixators.^{1,2} Weight bearing must be limited during distraction as per the device's biomechanical testing and the man-

ufacturer's recommendations. One of the challenges that orthopaedic surgeons face is the decision as to when a bone has sufficiently healed to allow a patient to begin bearing weight fully. The main tool used to assess bone healing in clinical practice today is standard radiography in two planes, which is commonly chosen because it is widely available and inexpensive. The presence of three of four continuous cortices at

least 2 mm thick on AP and lateral radiographs is a commonly cited criterion for the removal of the external fixator.³ This method of identifying three of four cortices is most applicable to lengthening with external fixation and not necessarily applicable to the use of a lengthening nail. Furthermore, identification of cortices on radiographs is subjective and surgeon dependent, and the variation in the assessment of the number of cortices present is slightly better than chance.^{4,5}

Various indirect quantitative methods, including dual-energy x-ray absorptiometry (DEXA) and quantitative CT (QCT), have been explored and evaluated as feasible options for assessing bone healing after distraction osteogenesis. Although they expose patients to less radiation, these methods have various pitfalls, including inability to assess for bone alignment and implant integrity, high cost, and less accessibility.

There is a need for a quick, inexpensive, reproducible, and simple quantitative method to help orthopaedic surgeons determine when it is appropriate to allow patients to bear weight after distraction osteogenesis using an IM rod. The pixel density ratio (PDR) method may provide a more accurate means for assessing the regenerate bone healing after distraction osteogenesis than the subjective evaluation of the cortical bridging method. Authors who have assessed the PDR method have evaluated only the method for bone healing of the tibia after application of an external fixator.^{6,7} Studies have shown that the PDR method has low interobserver variability and high

intraobserver reproducibility and that this method is a useful way to indicate callus stiffness to judge bone healing.^{6,7} Some authors have shown that pixel density (PD) is an effective method in determining when to remove an external fixator after distraction osteogenesis of the tibia, but little is known on its efficacy in determining bone healing after distraction osteogenesis of the femur using an IM rod.^{6,7} The goal of the present study was to correlate PDR values and clinical readiness for weight bearing in patients undergoing femur lengthening with an antegrade motorized IM nail. The authors hypothesize that the PDR will correlate with progressive bone healing, and there will be a notable threshold above which patients will be allowed to safely bear full weight.

Methods

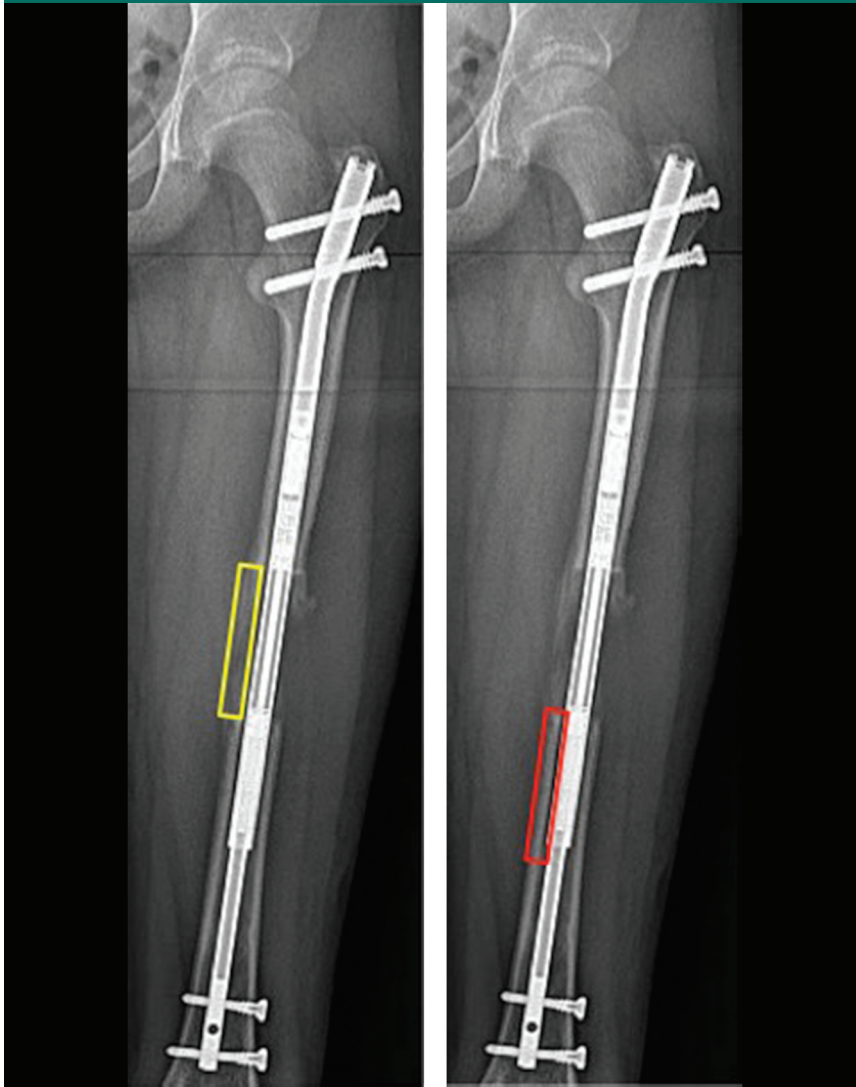
An institutional review board–approved retrospective study was conducted on 32 consecutive patients who underwent antegrade femur lengthening using a motorized IM rod from February 2012 to May 2015 at the Icahn School of Medicine at Mount Sinai. We excluded all patients who did not meet the minimum requirement of 1-year follow-up. Indications for limb lengthening included congenital in 26 patients (81%) (short stature in 6 patients, hence 12 femurs) and posttraumatic leg-length discrepancy in 6 patients (19%). Twenty-two (69%) were men, and 10 (31%) were women. The mean age was 26 years (range, 12 to 52 years). The mean amount of

lengthening was 41.7 mm (range, 20 to 70 mm). The mean bony union time was 8.5 weeks (range, 4 to 18 weeks) and was based on the surgeon's experience. Serial, non-weight bearing, two-view 36-inch radiographs of the femur (performed at 3 feet from the patient and with the use of a 1-inch magnification marker) were assessed by a single operator starting at the completion of lengthening (week 0). The pixel densities of the lateral and medial cortices were measured on AP radiographs, and the anterior and posterior cortices were measured on lateral radiographs. All four cortices were measured for each patient at every postoperative visit. These values were then compared with the adjacent 2 cm of original bone just distal to the regenerate site (Figure 1).

Any picture archiving and communication system provides a tool to measure the PD on the radiographs. Typically, this tool is labeled as "ROI" (region of interest). Once the tool has been selected, the operator will need to delineate the regenerate bone being studied (ie, medial, lateral, anterior, and posterior) with multiple mouse clicks. To avoid compromising the ultimate PD value, it is crucial not to incorporate any part of the metal rod in the region of interest. The same applies to the adjacent bone and to the area outside the regenerate site. The use of multiple mouse clicks will allow one to accurately select the area of interest. The delineation of the bone regenerate will ultimately provide a PD value. The next step is to perform the same measurement on the adjacent distal 2 cm of bone (not including the regenerate). The reason to use the

Dr. Fragomen or an immediate family member has received royalties from Stryker; serves as a paid consultant to NuVasive, Smith & Nephew, and Synthes; and serves as a board member, owner, officer, or committee member of the Limb Lengthening Research Society. Dr. Rozbruch or an immediate family member has received royalties from Stryker; is a member of a speakers' bureau or has made paid presentations on behalf of NuVasive, Smith & Nephew, and Stryker; serves as a paid consultant to NuVasive, Smith & Nephew, and Stryker; and serves as a board member, owner, officer, or committee member of the Limb Lengthening Reconstruction Society. None of the following authors or any immediate family member has received anything of value from or has stock or stock options held in a commercial company or institution related directly or indirectly to the subject of this article: Dr. Vulcano, Mr. Markowitz, Mr. Ali, and Mr. Nguyen.

Figure 1



Radiographs showing pixel density value measurement at the regenerate site (left) and original bone (right).

distal bone as opposed to the proximal bone is that, at the beginning of the data collection, the authors noticed that in several cases, the shadow of the buttocks or the genitals would overlap in the said area, affecting PD. The ratio of the bone regenerate PD to the adjacent bone PD was then calculated on an Excel spreadsheet. This calculation was made for each of the four regenerate bone sides.

The PD in picture archiving and communication system was auto-

matically calculated by the software by the following formula:

$$PD = Q0 + 1024 / (L \times [\mu1 \cdot T1 + \mu2 \cdot T2])$$

where PD = pixel density of the region of interest; Q0 = pixel value of background; L = latitude value of imaging plate; $\mu1$ = linear attenuation coefficient of bony tissue (per centimeter); T1 = thickness of bony tissue (in centimeters); $\mu2$ = linear attenuation

coefficient of soft tissue (per centimeter); and T2 = thickness of soft tissue.^{8,9}

The PDR was calculated using the following formula:

$$PDR = \frac{\text{pixel density regenerate site}}{\text{pixel density adjacent distal cortex}}$$

and subsequently correlated with the subjective assessment of bone healing by one of the senior authors.

Postoperatively, the patients were allowed partial weight bearing based on the IM rod manufacturer's recommendations. This depends on the size of the nail implanted: 8.5, 10.7, and 12.5 mm nails can bear a maximum of 30, 50, and 70 lbs, respectively. Only when sufficient bone healing was subjectively observed by the treating physician was the patient allowed to progress to full weight bearing.

Descriptive analysis of the study population included mean values and ranges to characterize continuous variables and frequencies and percentages for discrete variables. Paired *t*-tests were used to compare the average PDR value at the time of diagnosed healing versus the average PDR value at the immediate time point prior. Independent sample Student *t*-tests were used to evaluate any differences in patient or clinical factors in PDR at the time of bone healing. General linear modeling techniques were used to describe the change in the PDR over time from the end of the distraction period and to determine whether any patient or clinical characteristics may have affected that change over time. All analyses were done using SPSS version 22.0 (IBM).

Results

The mean distraction was 41.7 mm (range, 20 to 70 mm). Bone regenerate healing was clinically declared by

Table 1**Mean PDR of Lateral, Medial, Anterior, and Posterior Cortices at 8.5 Weeks**

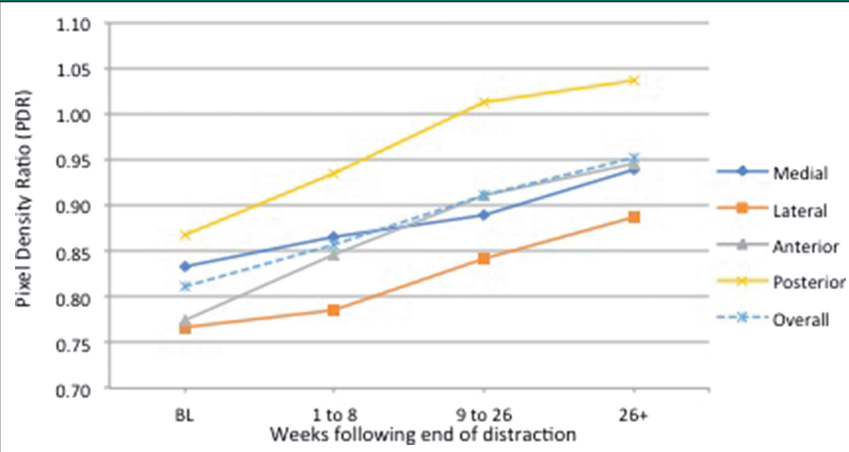
Cortex	PDR
Lateral	0.84
Medial	0.89
Anterior	0.92
Posterior	0.98

PDR = pixel density ratio

the treating surgeon at mean 8.5 weeks (range, 4 to 18 weeks). The mean PDR at bone healing was 0.84 at the lateral cortex (range, 0.81 to 0.84), 0.89 at the medial cortex (range, 0.84 to 0.93), 0.92 at the anterior cortex (range, 0.89 to 0.96), and 0.98 at the posterior cortex (range, 0.94 to 1.02) (Table 1). The overall mean PDR corresponding to clinical bone healing was 0.90 (range, 0.88 to 0.92), which was significantly ($P < 0.001$) greater than the mean value at the previous clinic visit (mean, 0.82; range, 0.77 to 0.84), when the bone was not clinically declared to be healed (Figure 2). The PDR at bone healing was not associated with patient sex, age, laterality, or distraction length (Table 2).

Discussion

Until recently, external fixation for limb lengthening represented the most effective means of lengthening bone. Over the past two decades, however, the introduction of internal lengthening rods has signified an extraordinary innovation in the field of limb lengthening. IM rods decrease the high complication rates of pin track infections, joint stiffness, contractures due to tethering of the muscles by the pins, and large pin track scars, which can occur with external fixators.^{1,2}

Figure 2

Graph showing changes in the PDR of the regenerate bone after the end of the distraction period. PDR = pixel density ratio

Distraction osteogenesis accomplished with an external fixator allows a patient to fully weight bear, whereas distraction osteogenesis using an IM rod limits weight bearing until sufficient bone healing is observed. However, of cautionary note for the latter treatment method, a premature declaration of bone healing may lead to failure of the implants (Figure 3).

The main tool to assess bone healing in clinical practice today is standard radiography in two planes because it is widely available, inexpensive, and allows a surgeon to monitor bone alignment and implant integrity. The presence of three of four continuous cortices that are at least 2 mm thick on AP and lateral radiographs is a commonly cited criterion for the removal of the external fixator after distraction osteogenesis.^{3,10} Anand et al⁴ found interobserver rate agreement to be less than half between all involved orthopaedic surgeons, supporting the observation that assessment of bone healing by this radiographic method is subjective.^{4,11} Starr et al⁵ investigated the reliability of using radiographs as

Table 2**Association Between the PDR at Bone Healing and Patient Characteristics**

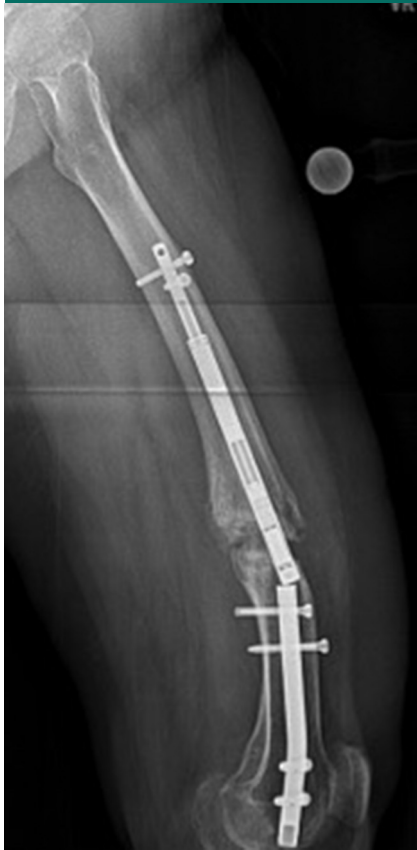Patient Characteristic	P value
PDR and sex	<0.001
PDR and age	<0.05
PDR and laterality	<0.001
PDR and distraction length	<0.05

PDR = pixel density ratio

a method to assess bone healing and determined that the variation in the assessment of the number of cortices was slightly better than chance. The authors concluded that low refracture rates after removal of an external fixator may be more an indicator of clinical judgment by experienced practitioners than the accuracy of using radiographic evaluation.^{5,11} It is not clear whether the traditional method of analyzing the presence of three of four cortices is applicable to the internal lengthening nail.

Various indirect quantitative methods, including ultrasonography (US), DEXA, and QCT, have been explored as potential options for

Figure 3



Radiograph showing failure of the implant after premature declaration of bone healing.

assessing bone healing after distraction osteogenesis. Studies have shown that US cannot differentiate changes in bone stiffness and strength after a certain point during healing.^{11,12} In addition, because most of the energy of US is transmitted through soft tissue, variable amounts of soft tissue overlying the bone may lead to fluctuations in measurements.^{11,13} DEXA is expensive and does not allow for assessment of alignment and implant integrity. Although US and DEXA provide valuable information about the distribution and quantity of new bone formed during limb lengthening, Eyres et al¹² found that the high-resolution images of radiography were useful in the detection of small cortical defects, which were not

identified by the other imaging techniques. QCT may have the unique advantage of providing high-resolution images of the healing bone while providing quantitative analysis. Babatunde et al¹¹ report that the major disadvantages of QCT are its limited availability, high cost, and relatively higher radiation exposure to patients.

Radiographic pixel values expressed as PDR indicate ossification or calcification of bone. Although the pixel value is not absolute, the relative pixel value of the distraction site compared with the pixel value of the original bone may provide information regarding biological steps of bone gap healing⁸ (Figure 4). The PDR at each of the four cortices essentially monitors the maturation of the regenerate by comparing its density—in pixels—to that of the adjacent native bone.

The relative pixel value ratios at the declared time of clinical bone healing were >0.89 in three of the four cortices. The average PDR of 0.90 may represent the circumferential bone density after distraction osteogenesis. Treating surgeons may use this value as a method to monitor regenerate maturation and as a guide to decide for full weight bearing. The PDR can be used alone or as an adjunct to the subjective method of deciding whether the bone is healed based on multiple bridging cortices. In addition, we found that the PDR associated with clinical bone healing was not affected by patient sex, age, laterality, or distraction length. A value of 0.90 may be used as a guide for bone healing for a broad range of patients irrespective of age, sex, and amount of lengthening.

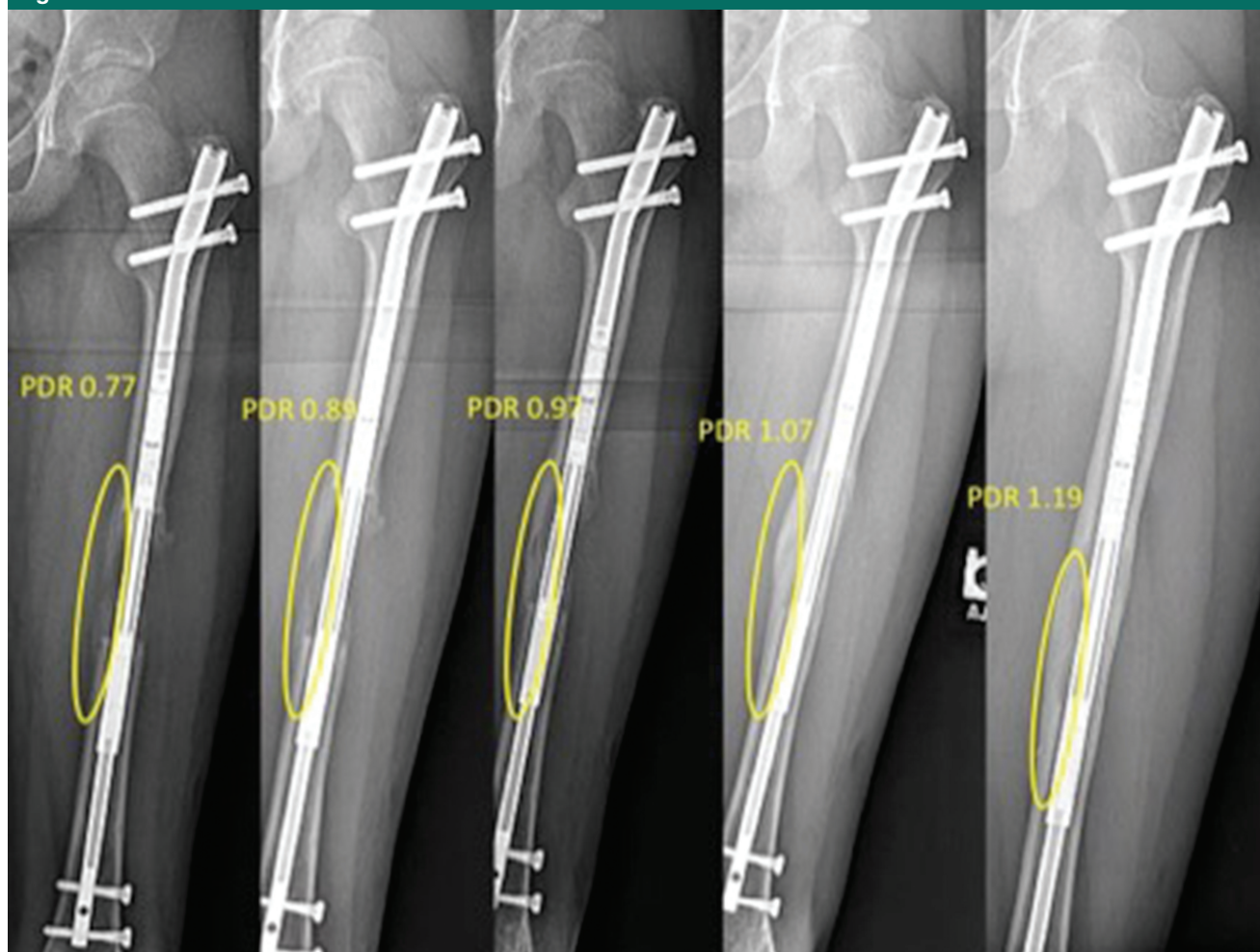
We recognize that our study has several limitations. This study relies on visualization and it is potentially misleading. The authors did not measure or test the mechanical environment suitable for weight bearing.

Other limitations include the retrospective nature of the study, the lack of a control group, and the relatively small cohort size. The use of the adjacent healthy bone whose PD was calculated may have potentially affected the results as it may have been affected by disuse osteopenia. Perhaps the contralateral femur should have been measured, but this would have led to higher costs and exposure to radiation. However, it is not clear whether creating a ratio with contralateral bone would be superior. The radiographic technique may differ from side to side, and contralateral radiographs were not routinely done. This may be an idea for a future study. Another limitation is that the surgeons may have been too conservative with respect to allowing full weight bearing. Consequently, even lower PDR may correspond to safe full weight bearing. Another limitation is the fact that despite E.V.'s recommendation to partially or to fully bear weight, there were no means to identify how much weight each patient effectively put on the surgical extremity. A weight-bearing monitoring device would be ideal to account for this.

There is no doubt that stronger nails may become available that may allow earlier weight bearing with different risks of implant failure. For the time being, the only titanium telescopic nail available in the United States is the one discussed in this article. The findings in the present study should assist, not replace, clinical judgment. When a stronger nail is developed, the mechanics and timing of bone healing and full weight bearing will likely change. It will be an opportunity to study the PDR in the new setting and see if and how it changes.

The findings of this pilot observational study introduce the PDR as a possible objective aid that may be used to monitor bone healing. The PDR is a rapid, objective, inexpensive, and

Figure 4



Radiographs showing progression of bone healing of the medial cortex from week 3 to 12 months from the end of distraction. PDR = pixel density ratio

simple method for the detection of bone density changes in distraction osteogenesis of the femur using a specific antegrade IM rod. This method may assist less experienced surgeons and serve as a valuable aid to senior orthopaedic surgeons in unclear cases. Furthermore, the PDR may be used as an objective measurement in clinical research, increasing measurement uniformity. Future studies should focus on assessing the intra- and inter-reliability of the method, in addition to more rigorous methodology to establish a threshold value for bone healing. Multicenter studies will help achieve

more scientifically sound conclusions as to the objective assessment of bone healing and its correlation with weight-bearing status in the setting of internal bone lengthening. Furthermore, the introduction to the market of newer and stronger nails will present an opportunity to test the validity of the PDR method with different implants. The PDR may be implant-specific or perhaps universal. This remains to be seen. The methodology may be used as a standardized measurement of bone regenerate healing, which may help limb-lengthening surgeons to report results and communicate more effectively.

References

References printed in **bold type** are those published within the past 5 years.

1. Kirane Y, Fragomen AT, Rozbruch SR: **Precision of the precise internal lengthening nail. *Clin Orthop Relat Res* 2014;472: 3869-3878.**
2. Rozbruch SR, Birch JG, Dahl MT, Herzenberg JE: **Motorized intramedullary nail for treatment of limb length discrepancy and deformity. *J Am Acad Orthop Surg* 2014;22: 403-409.**
3. Skaggs DL, Leet AI, Money MD, Shaw BA, Hale JM, Tolo VT: **Secondary fractures associated with external fixation in pediatric femur fractures. *J Pediatr Orthop* 1999;19:582-586.**

4. Anand A, Feldman DS, Patel RJ, et al: Interobserver and intraobserver reliability of radiographic evidence of bone healing at osteotomy sites. *J Pediatr Orthop* 2006;15: 271-272.
5. Starr KA, Fillman R, Raney EM: Reliability of radiographic assessment of distraction osteogenesis site. *J Pediatr Orthop* 2004; 24:26-29.
6. Hazra S, Song HR, Biswal S, et al: Quantitative assessment of mineralization in distraction osteogenesis. *Skeletal Radiol* 2008;37:843-847.
7. Song SH, Sinha S, Kim TY, Park YE, Kim SJ, Song HR: Analysis of corticalization using the pixel value ratio for fixator removal in tibial lengthening. *J Orthop Sci* 2011;16:177-183.
8. Shim JS, Chung KH, Ahn JM: Value of measuring bone density serial changes on a picture archiving and communication systems (PACS) monitor in distraction osteogenesis. *Orthopedics* 2002;25: 1269-1272.
9. Swaton N: Learn from experience: Insights of 200+ PACS customers. *Radiol Manage* 2002;24:22-27.
10. Fischgrund J, Paley D, Suter C: Variables affecting time to bone healing during limb lengthening. *Clin Orthop Relat Res* 1994; 301:31-37.
11. Babatunde OM, Fragomen AT, Rozbruch SR: Noninvasive quantitative assessment of bone healing after distraction osteogenesis. *HSS J* 2010;6:71-78.
12. Eyres KS, Bell MJ, Kanis JA: Methods of assessing new bone formation during limb lengthening: Ultrasonography, dual energy x-ray absorptiometry and radiography compared. *J Bone Joint Surg Br* 1993;75: 358-364.
13. Markel MD, Chao EY: Noninvasive monitoring techniques for quantitative description of callus mineral content and mechanical properties. *Clin Orthop Relat Res* 1993;293:37-45.