

Ankle Distraction: patient education

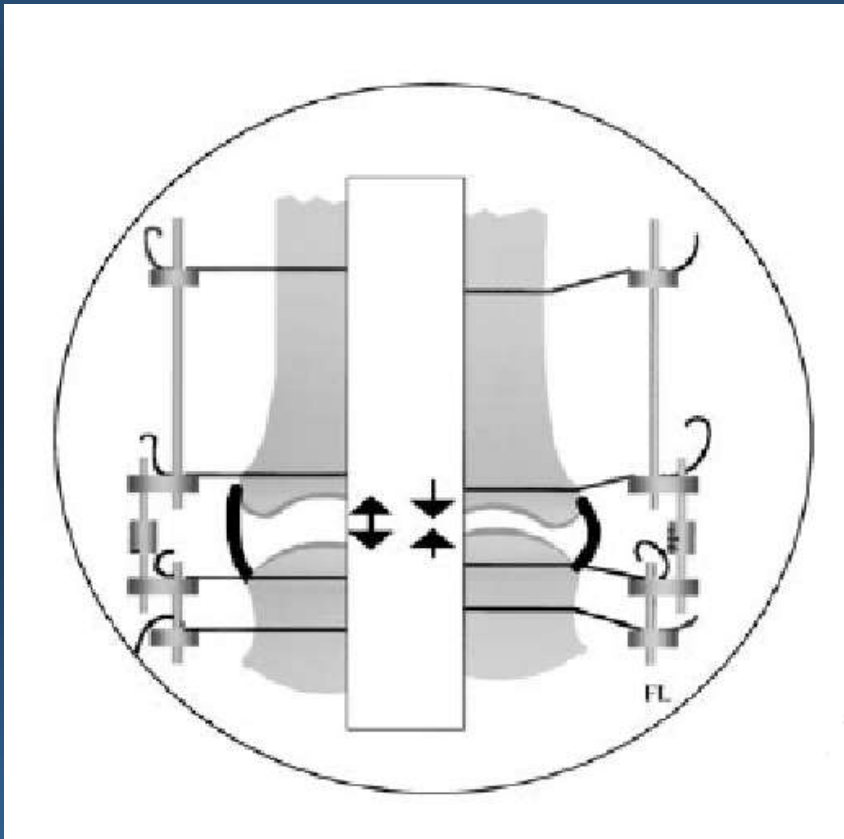
S. Robert Rozbruch, MD

LIMB .COM

HOSPITAL
FOR
SPECIAL
SURGERY



Ankle Distraction



Mechanical unloading
of the joint

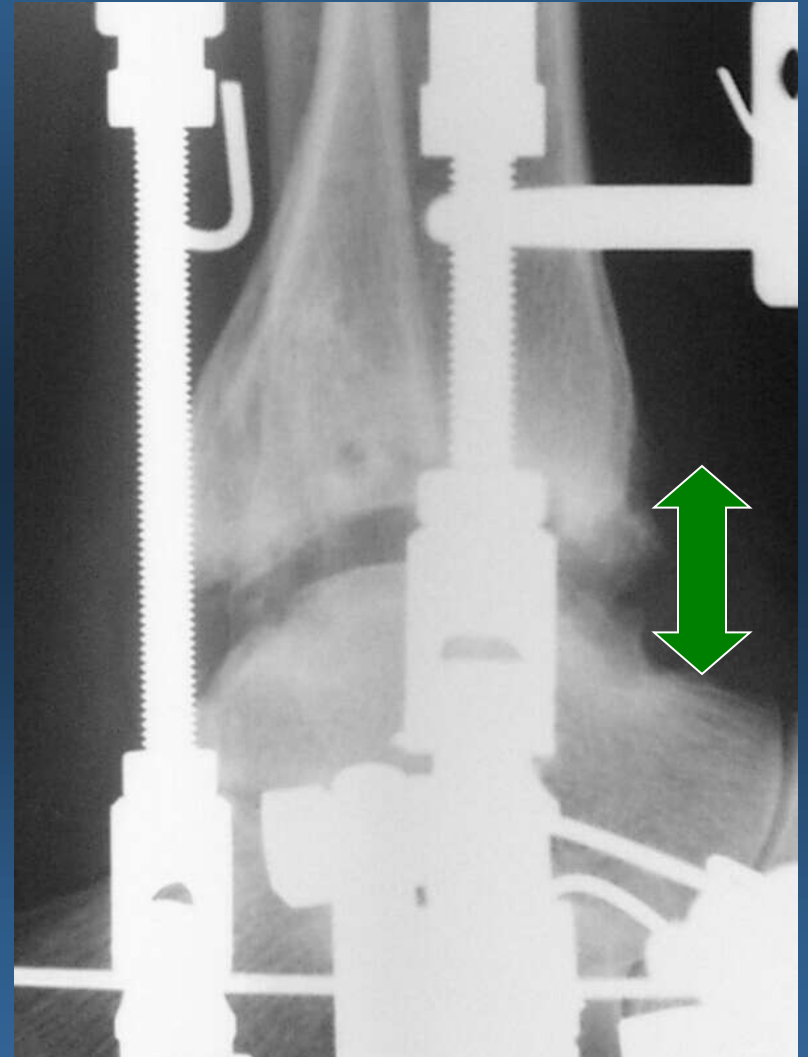
- Cartilage reparative process

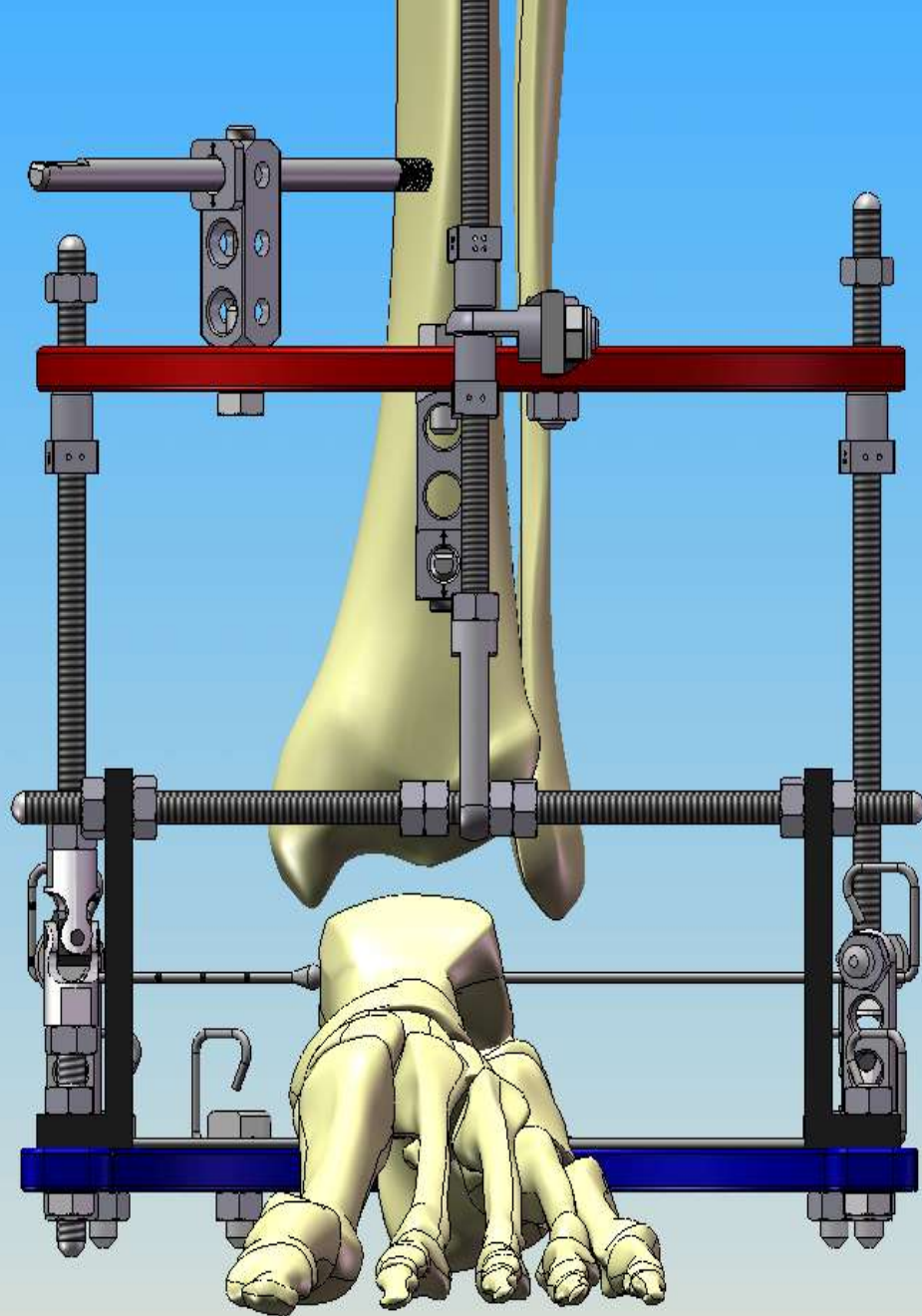
Intermittent flow of
joint fluid and changes
in hydrostatic pressure

- Weight bearing and ankle
movement in frame

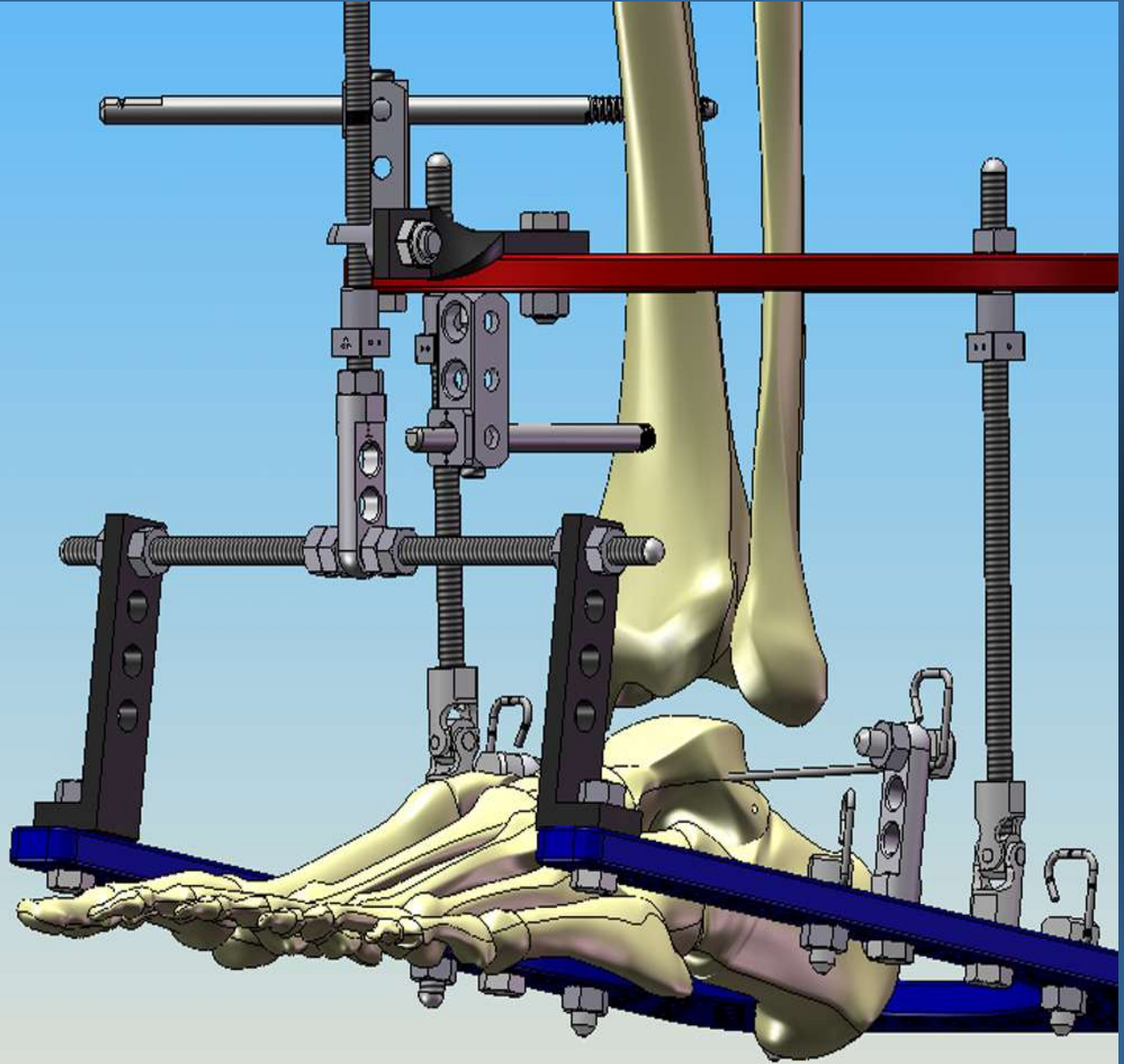
Mechanism

- Ilizarov external fixation for Distraction
- Combined w/ resection of anterior osteophyte & chondral stimulation

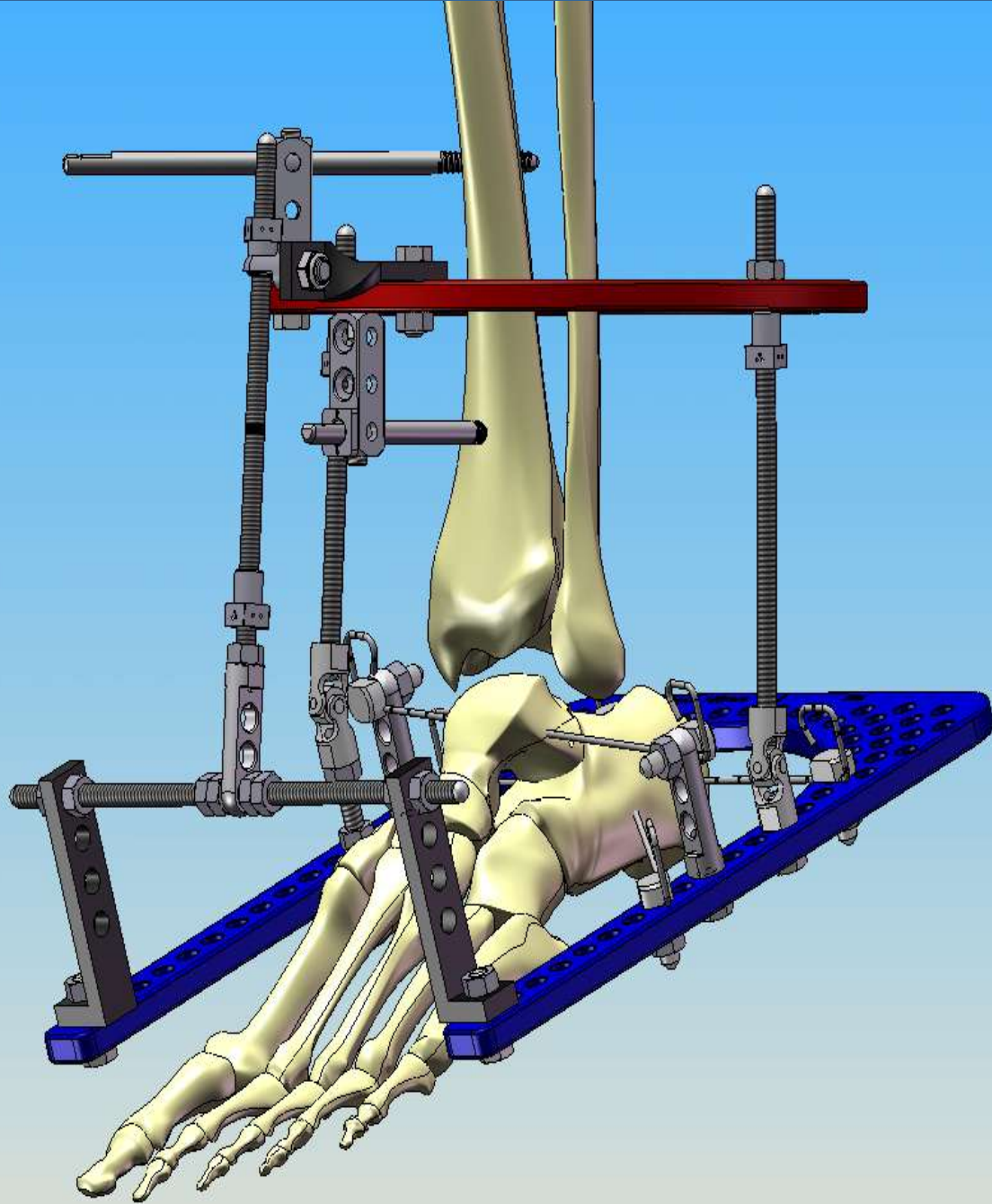




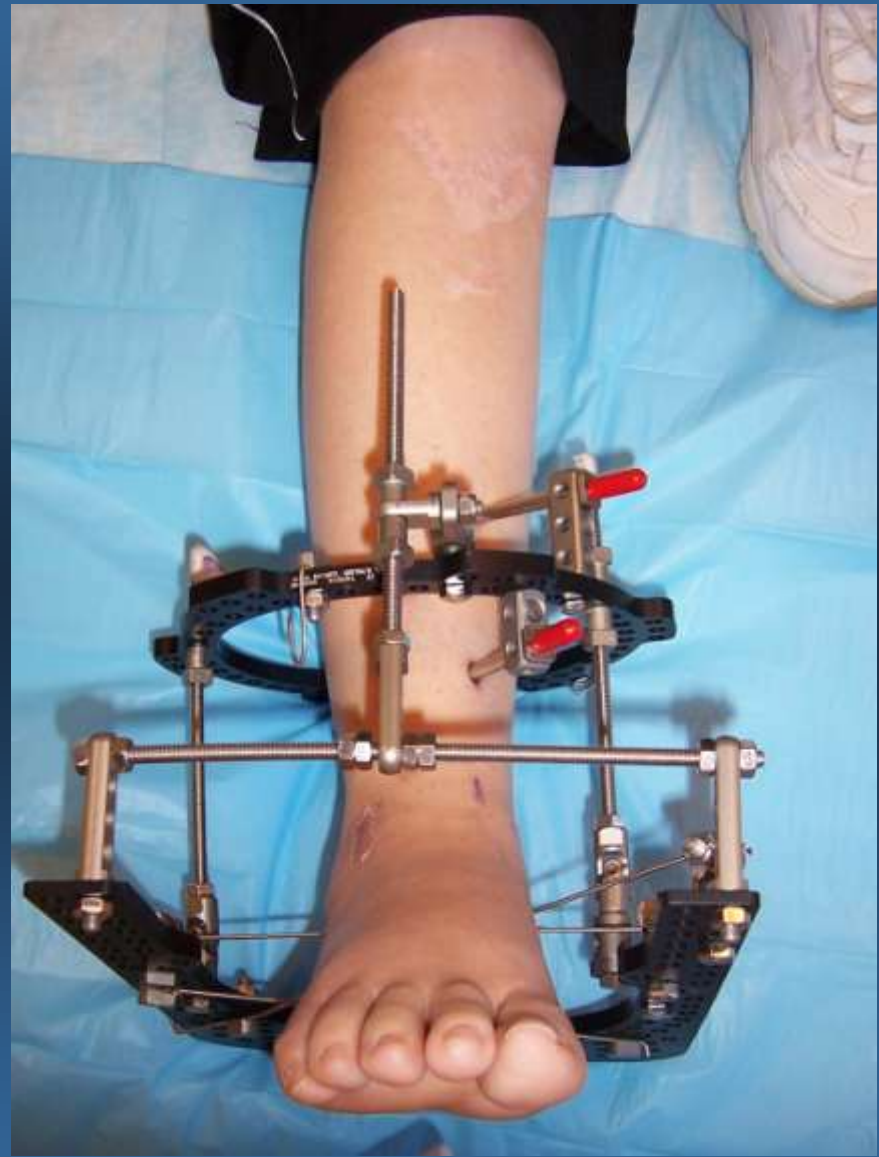RingFIX[™] **RAD**
ROZBRUCH ANKLE DISTRACTION



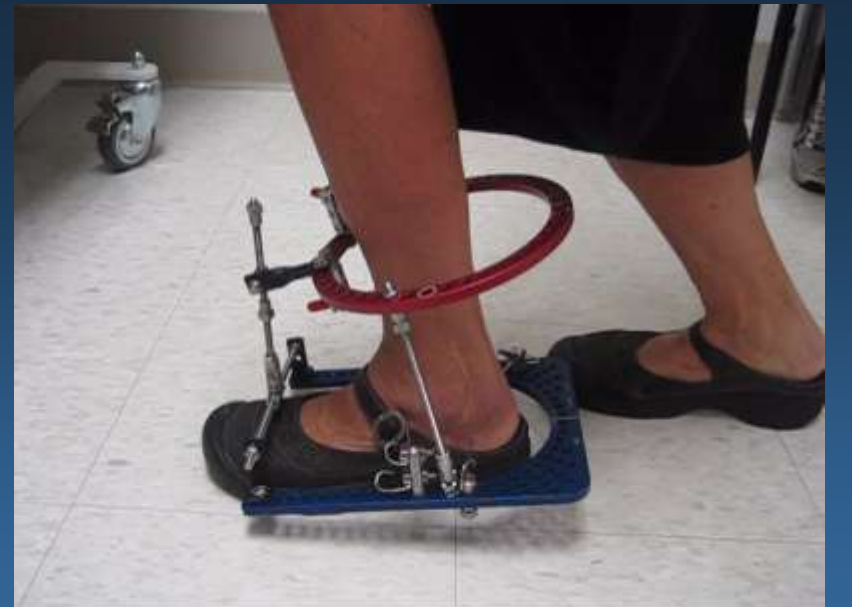
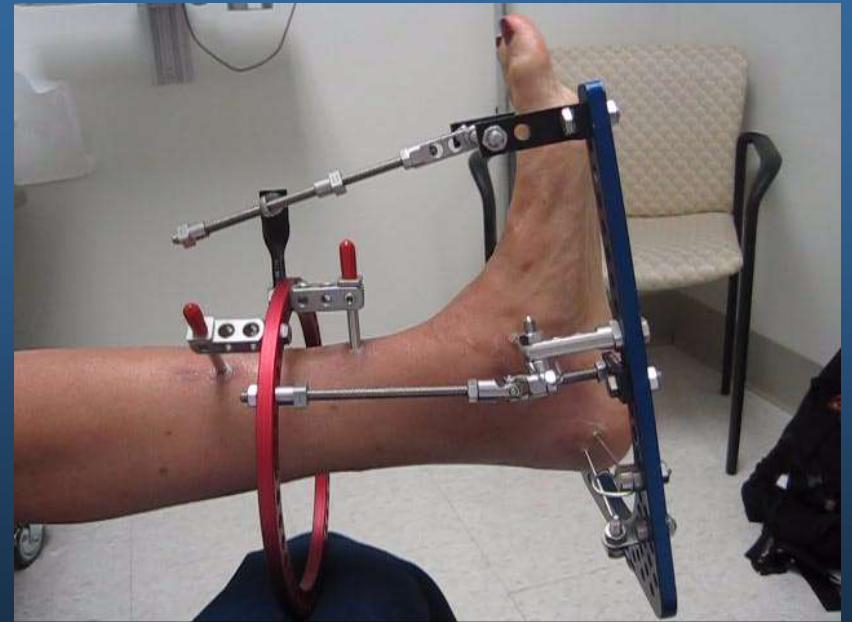
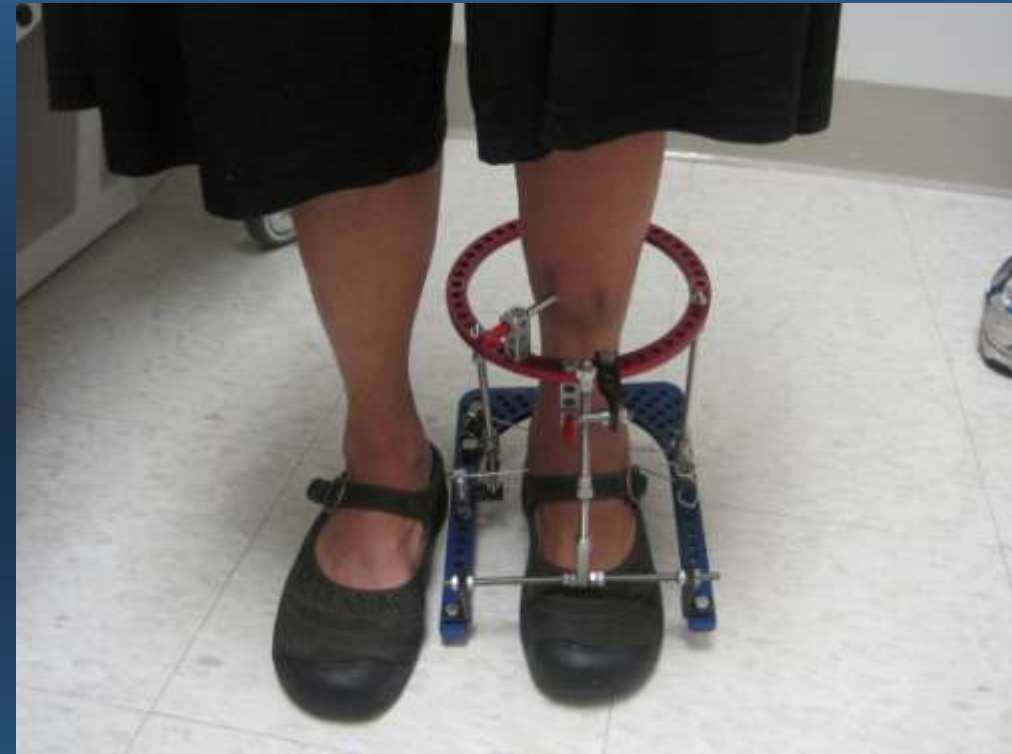RAD
RingFIX™
ROZBRUCH ANKLE DISTRACTION



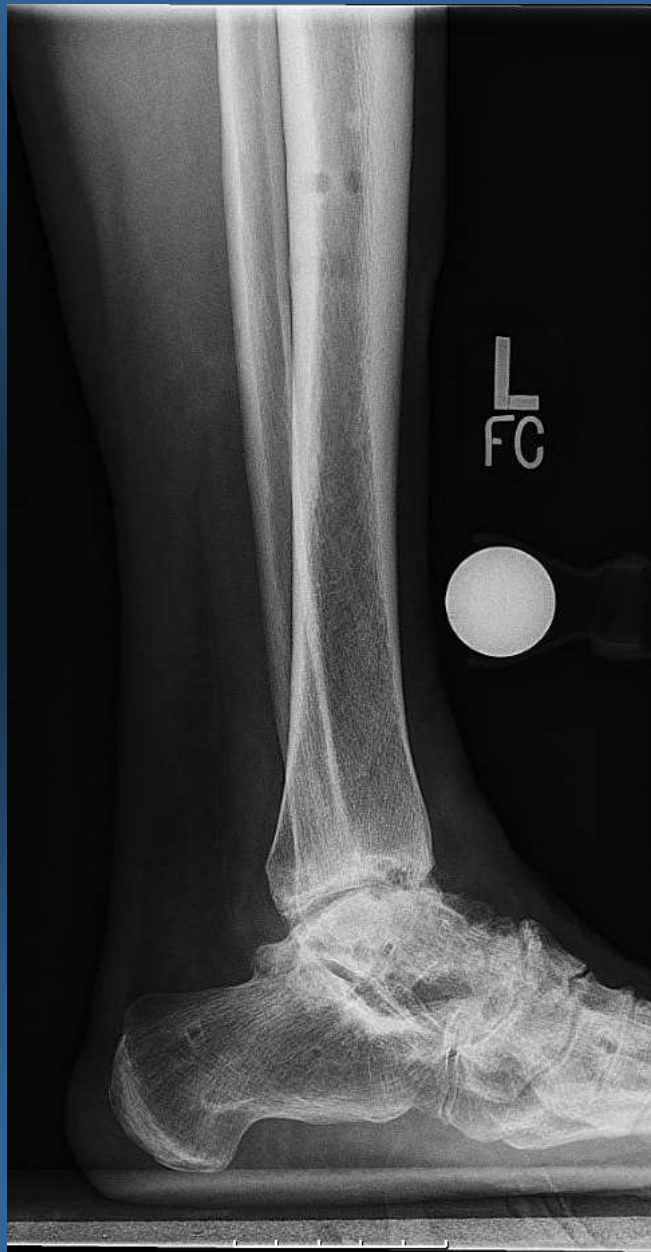RingFIX[™] **RAD**
ROZBRUCH ANKLE DISTRACTION



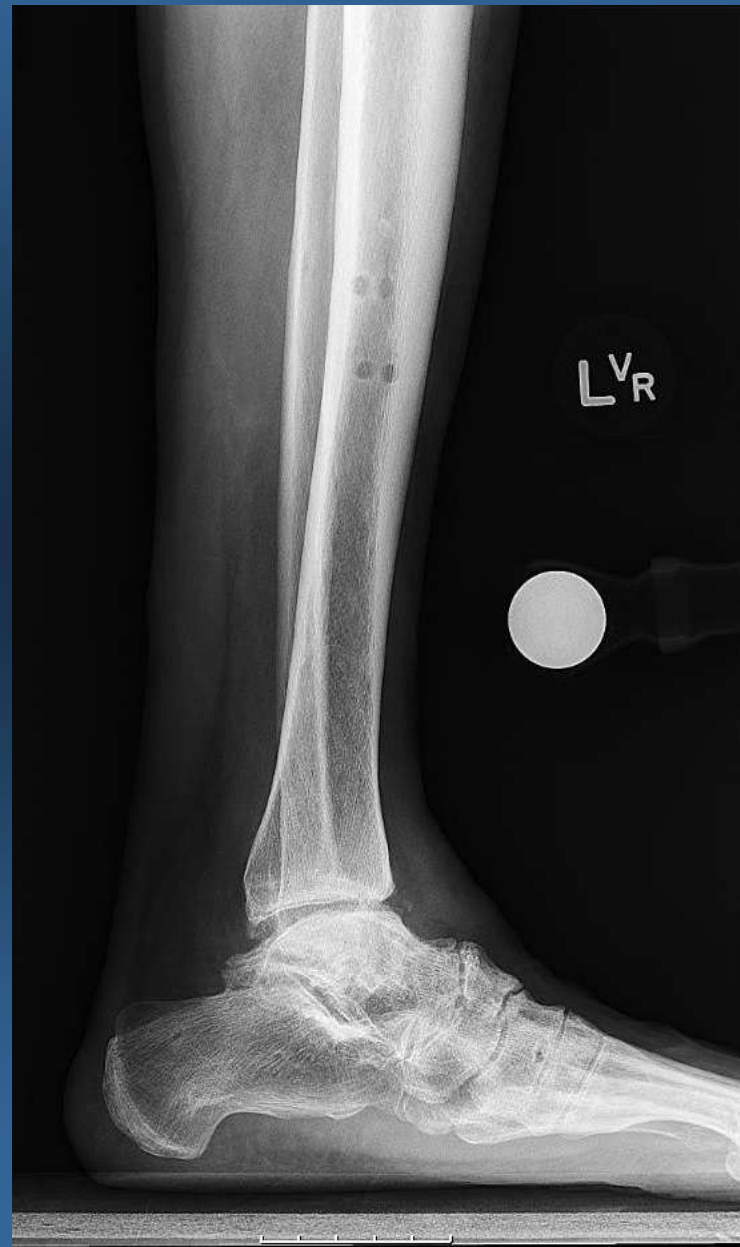


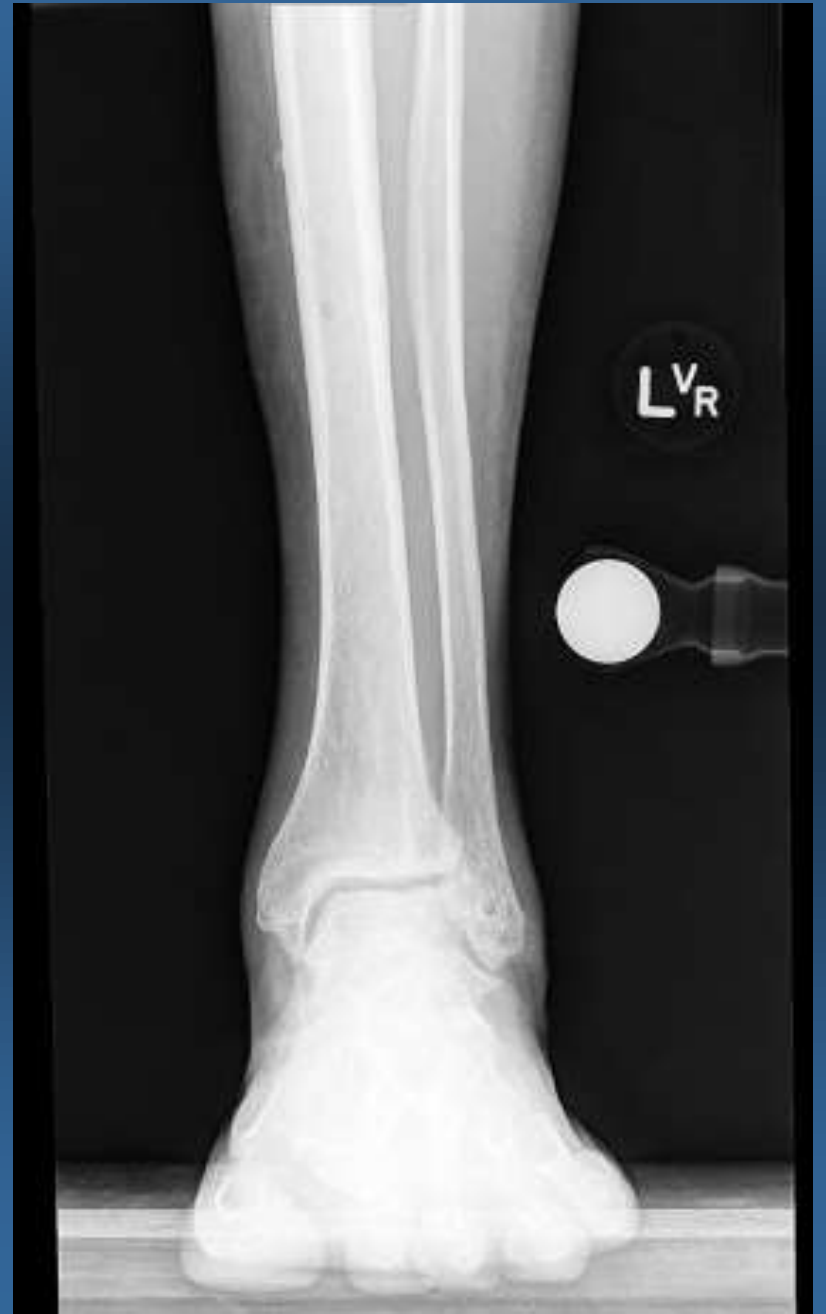
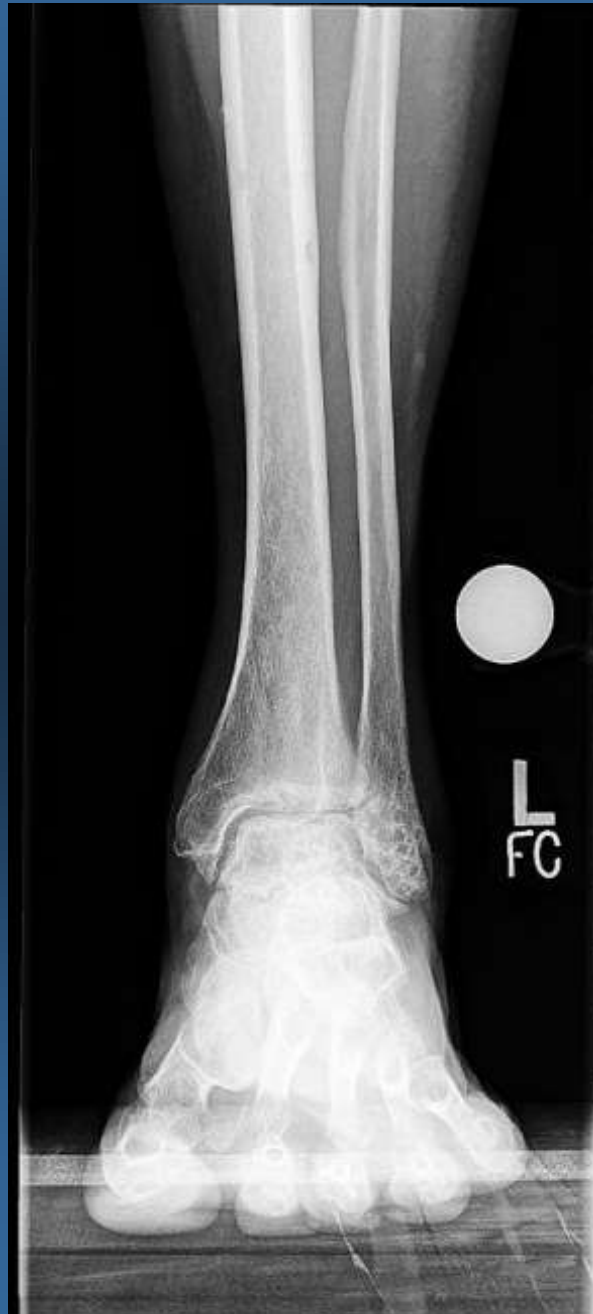Before

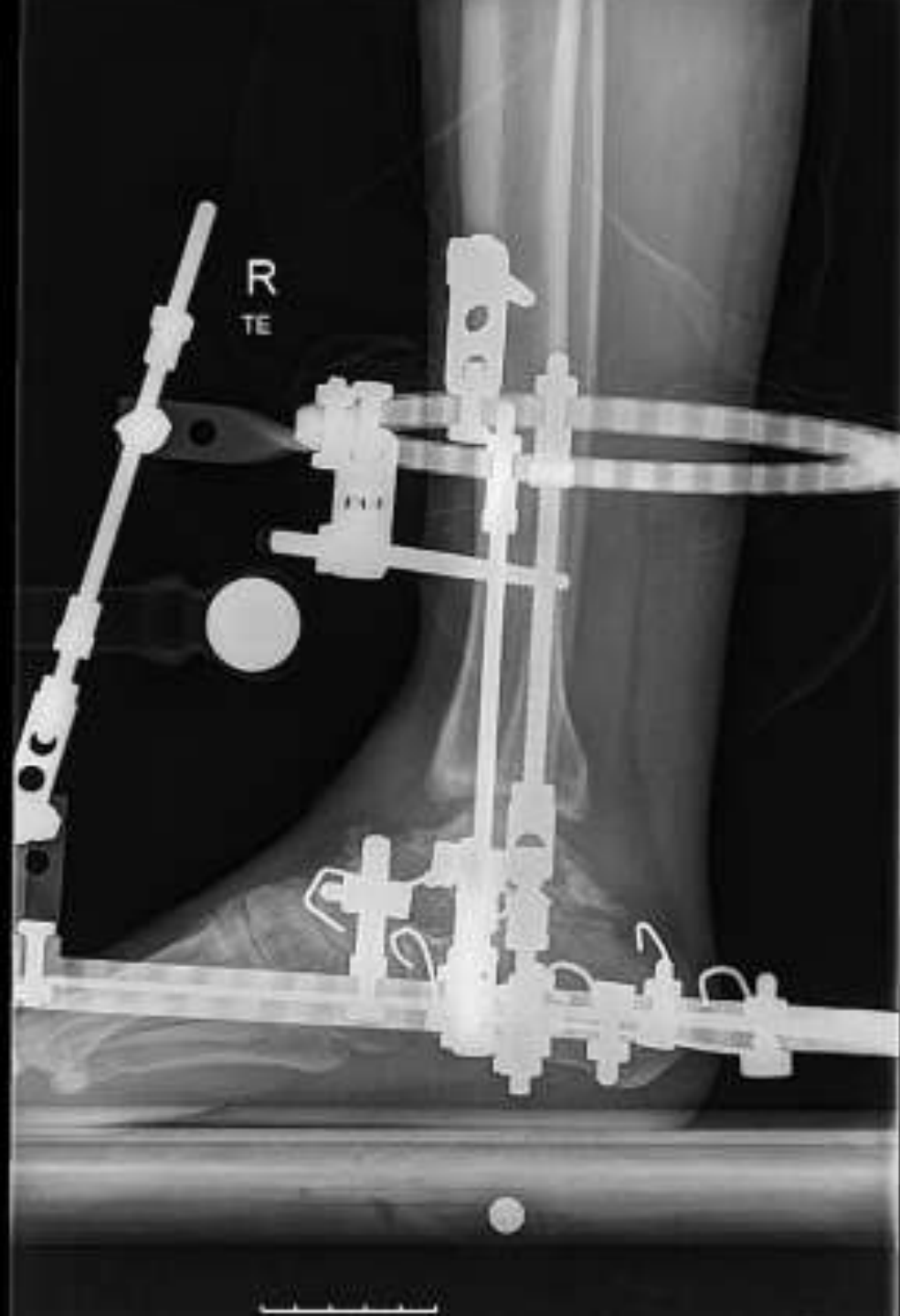


2 years

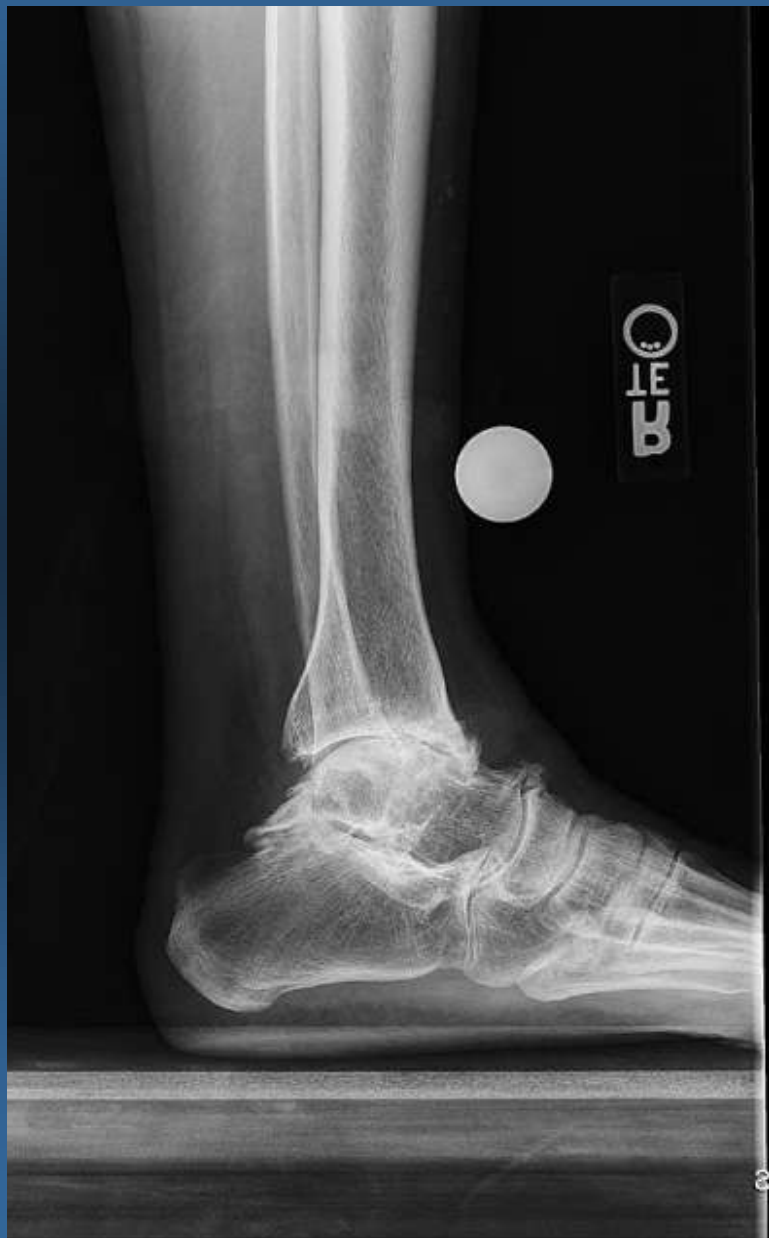




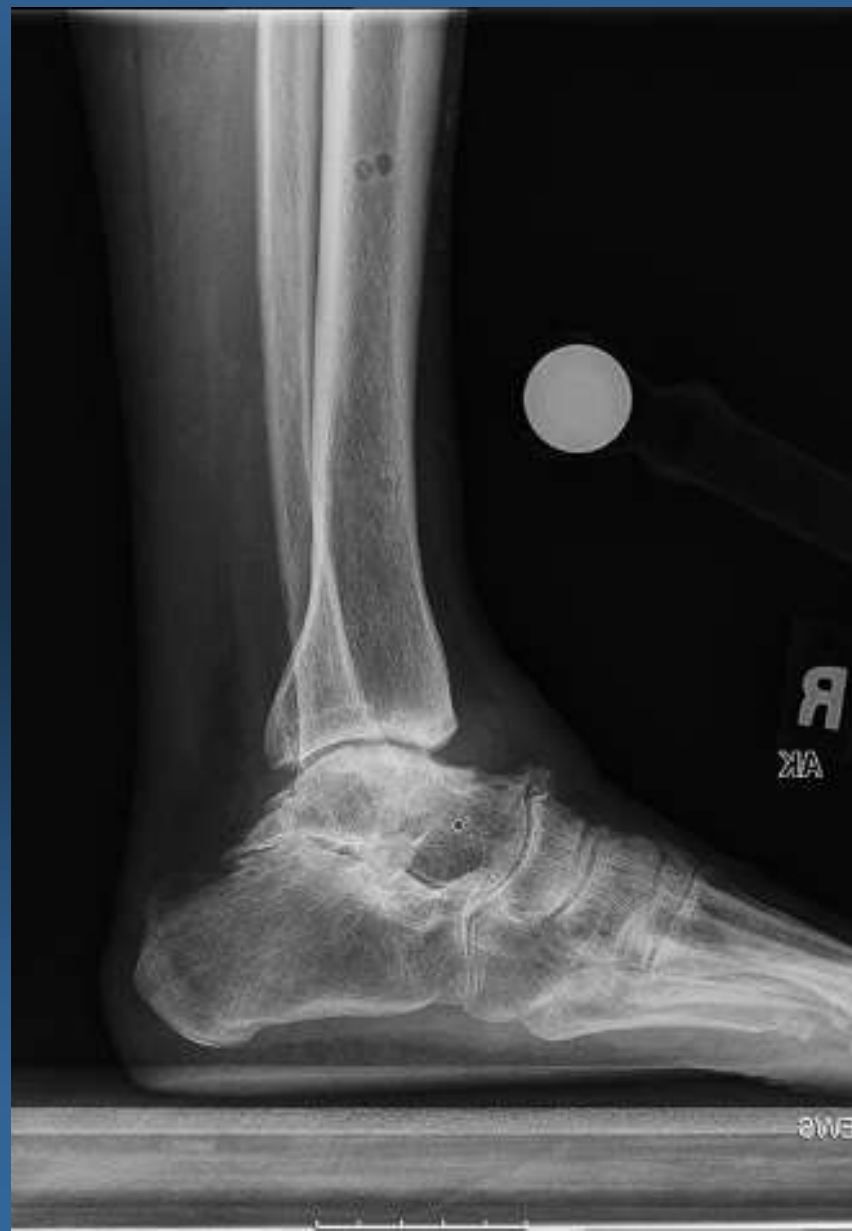


Before

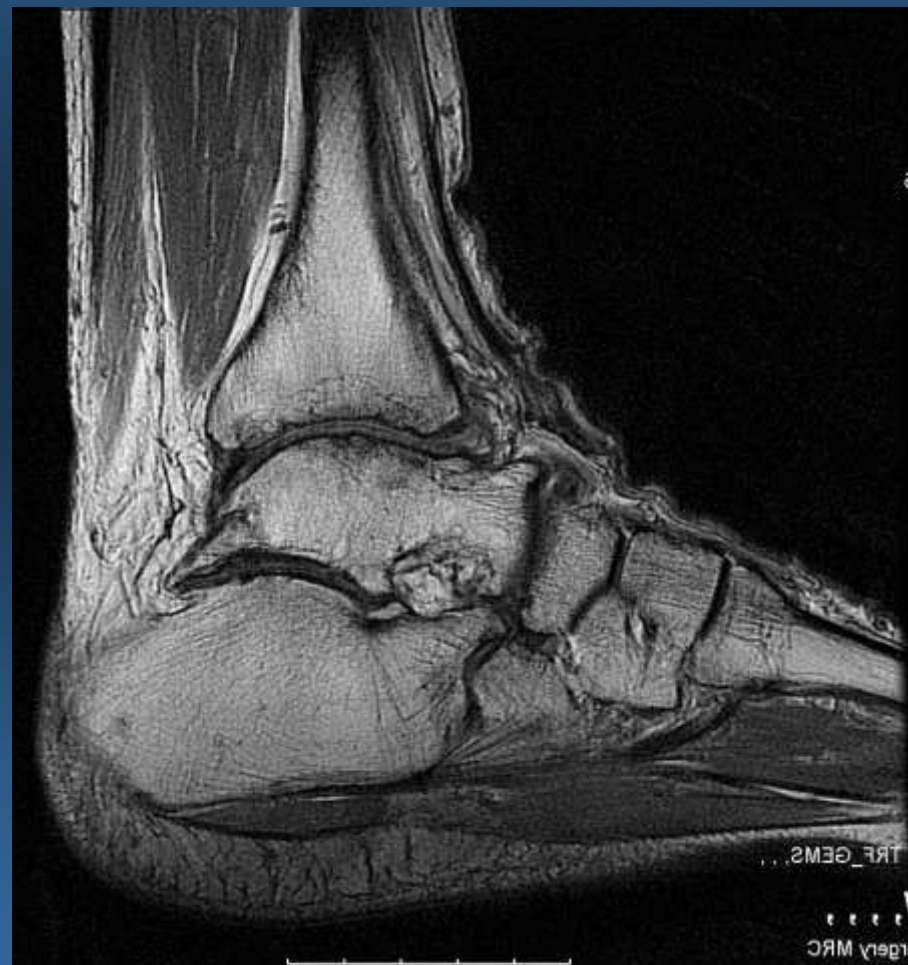
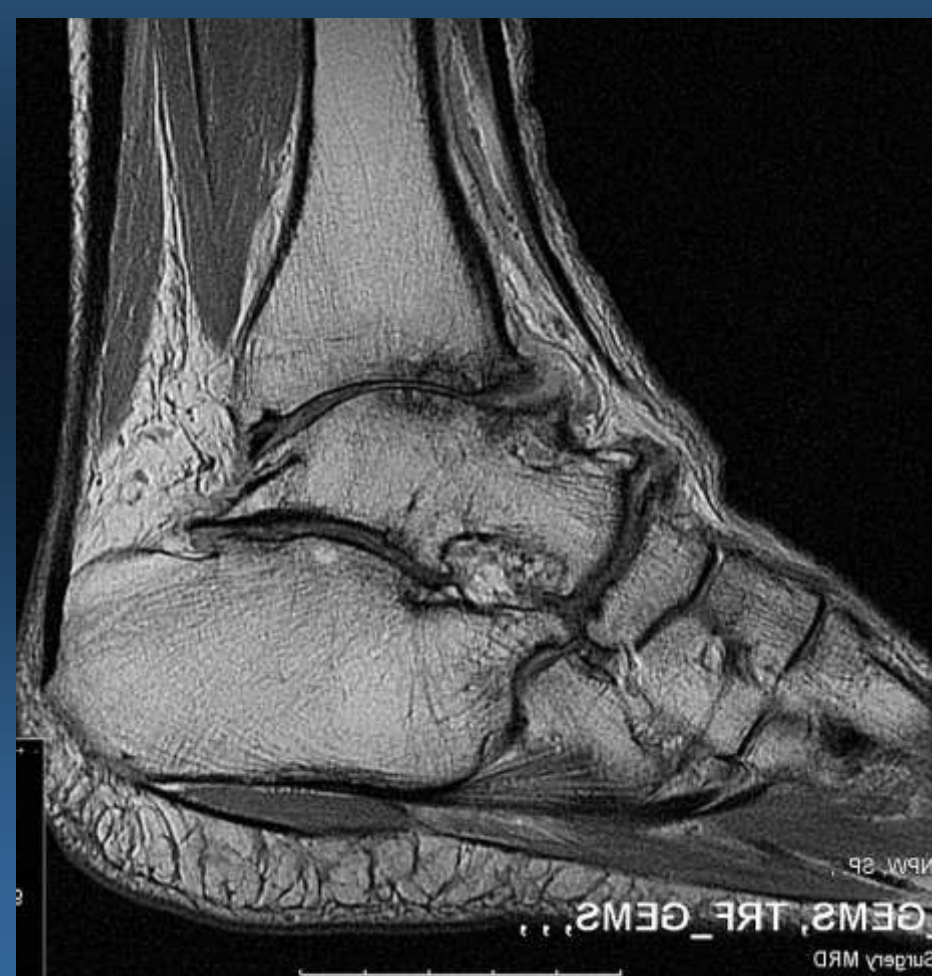
2 years

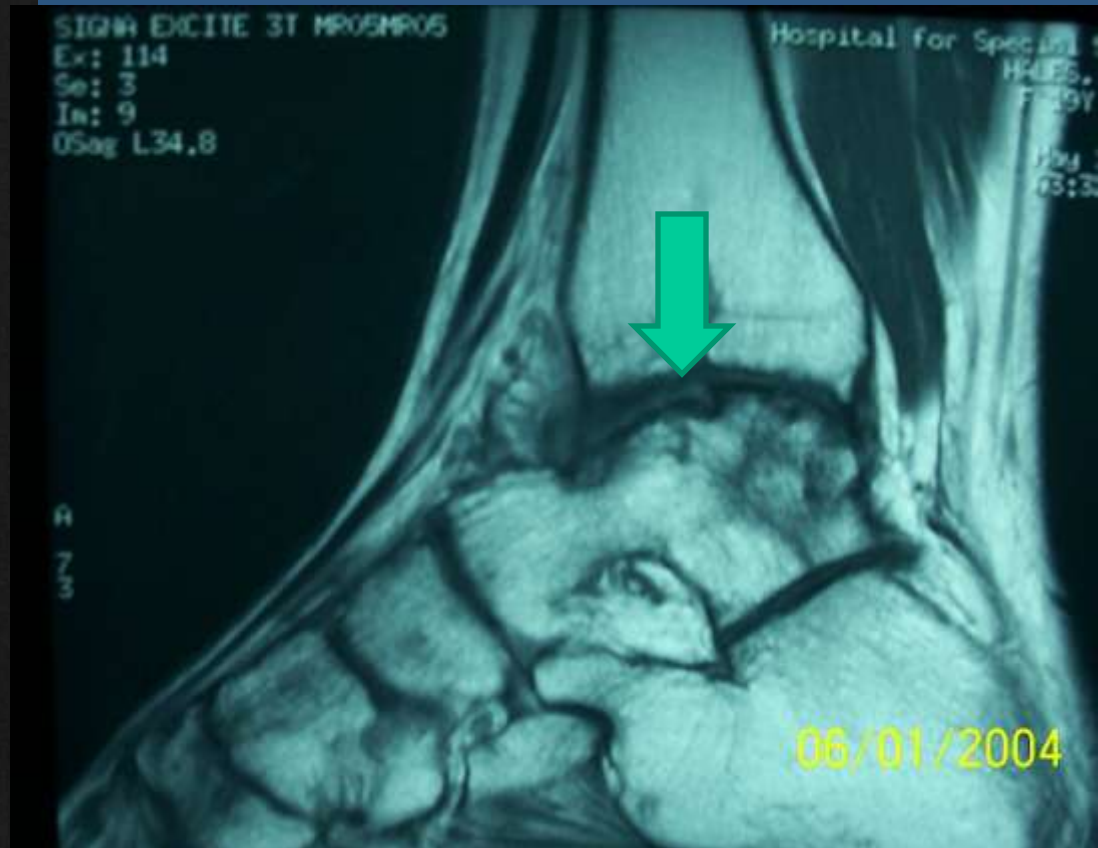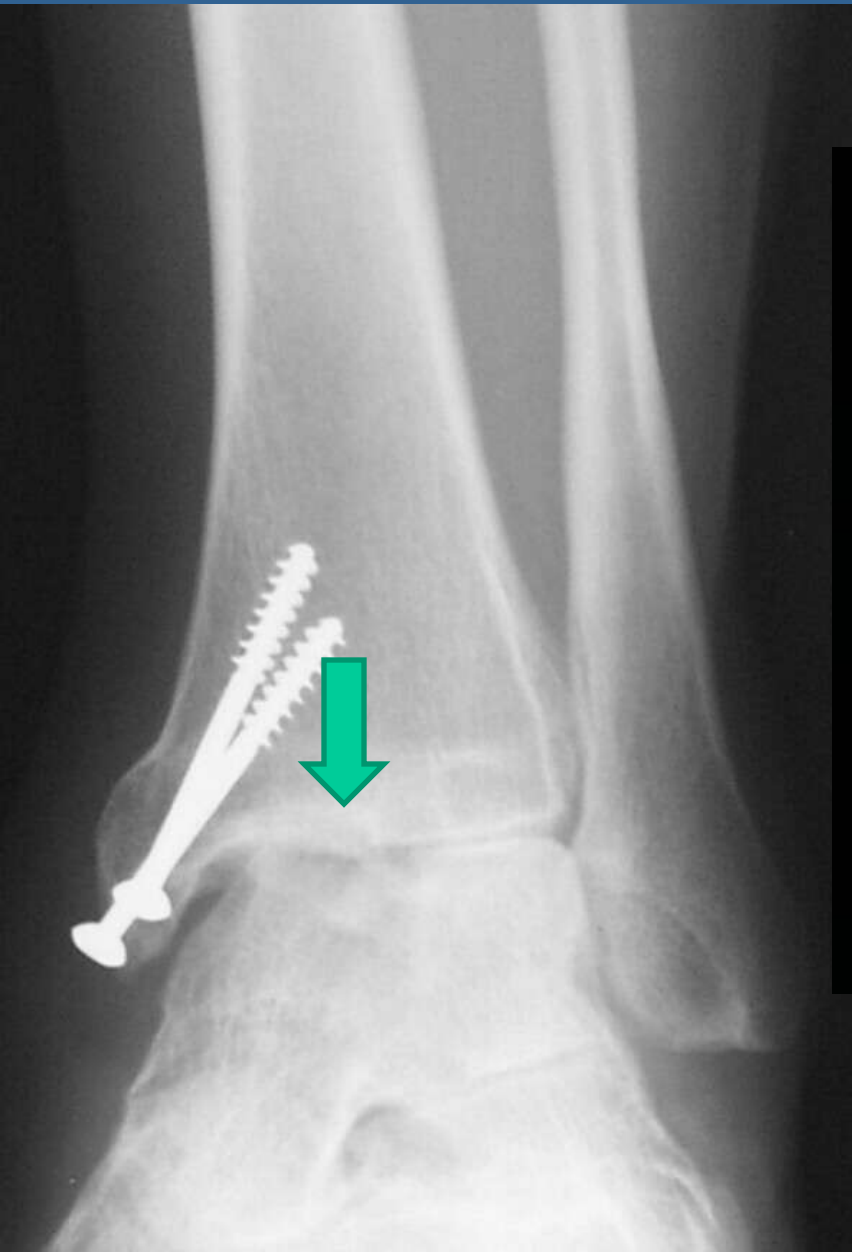


Before

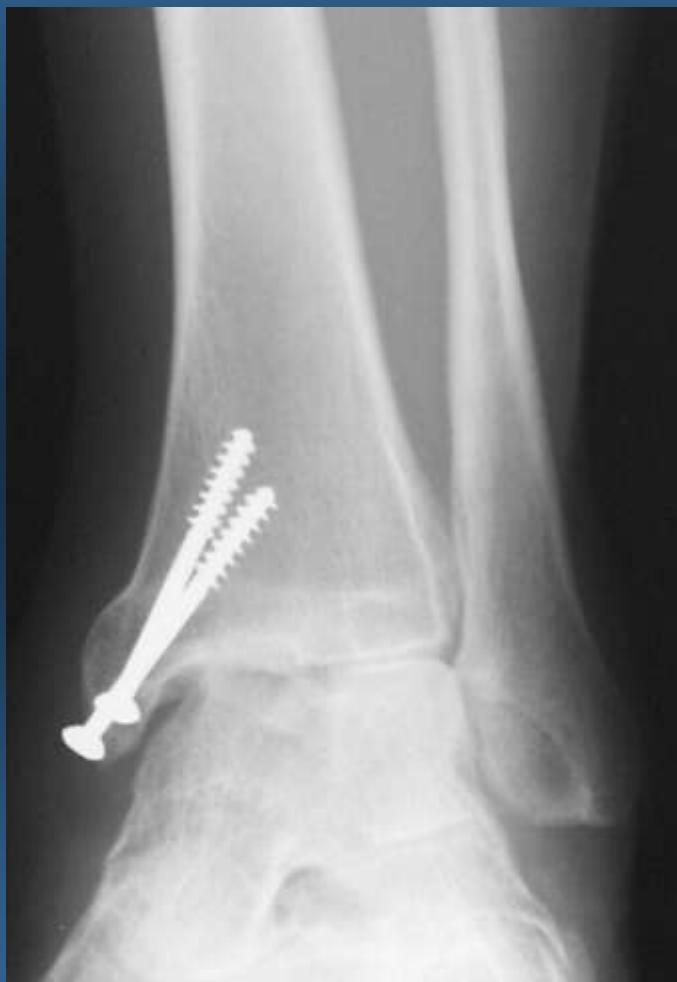2 years later



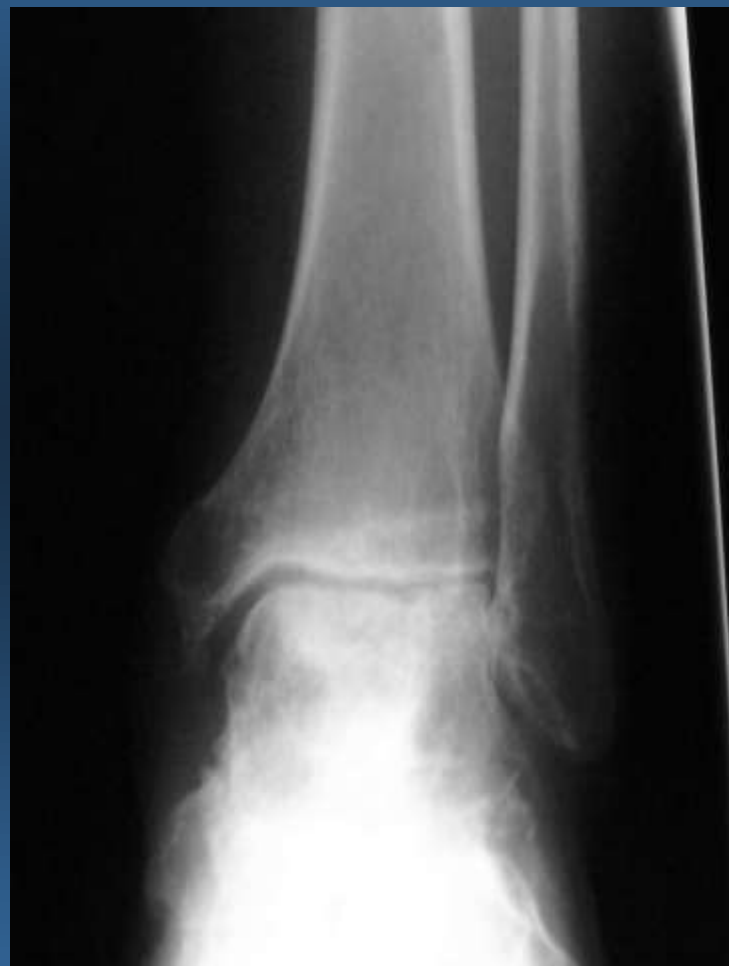Talar osteonecrosis

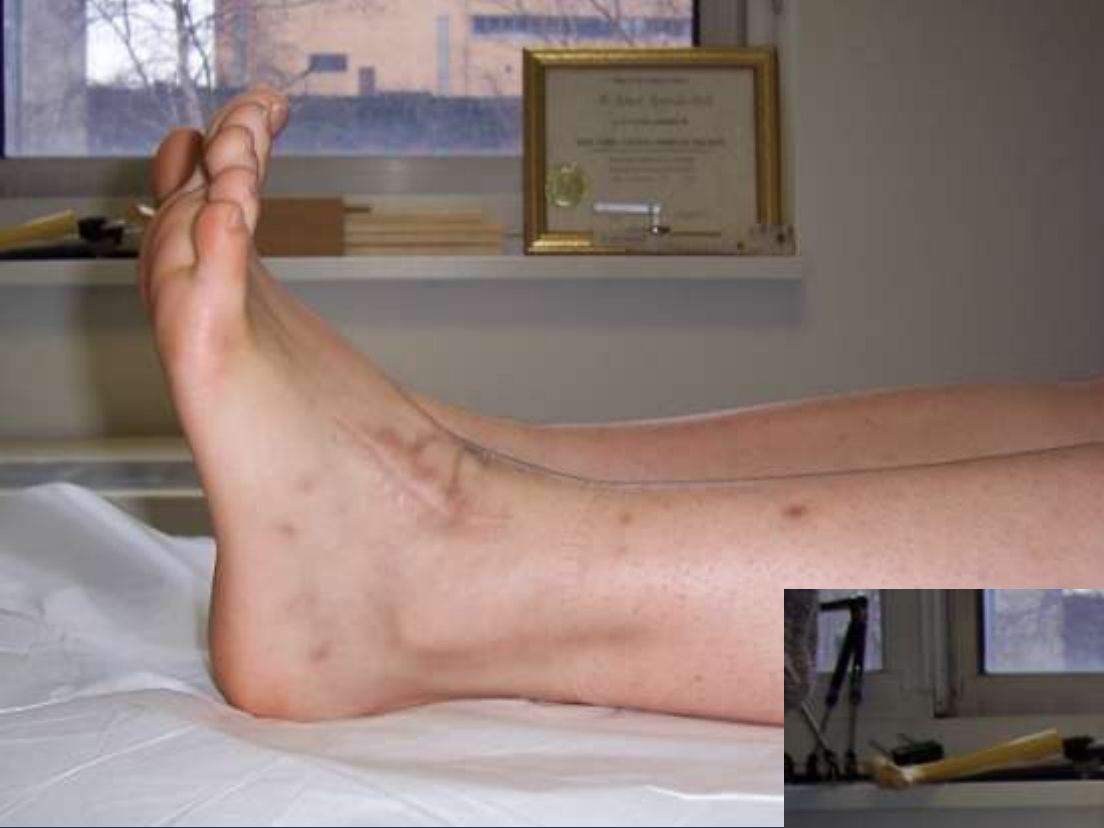

Before

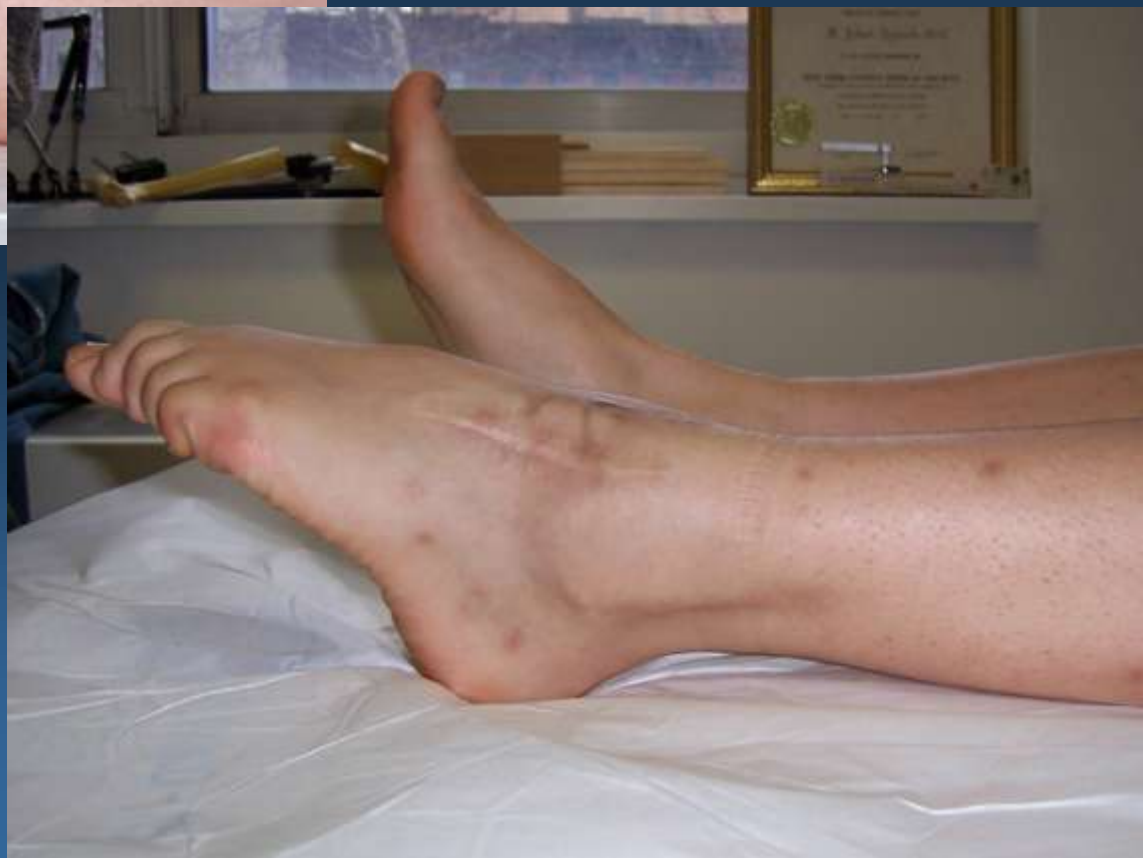

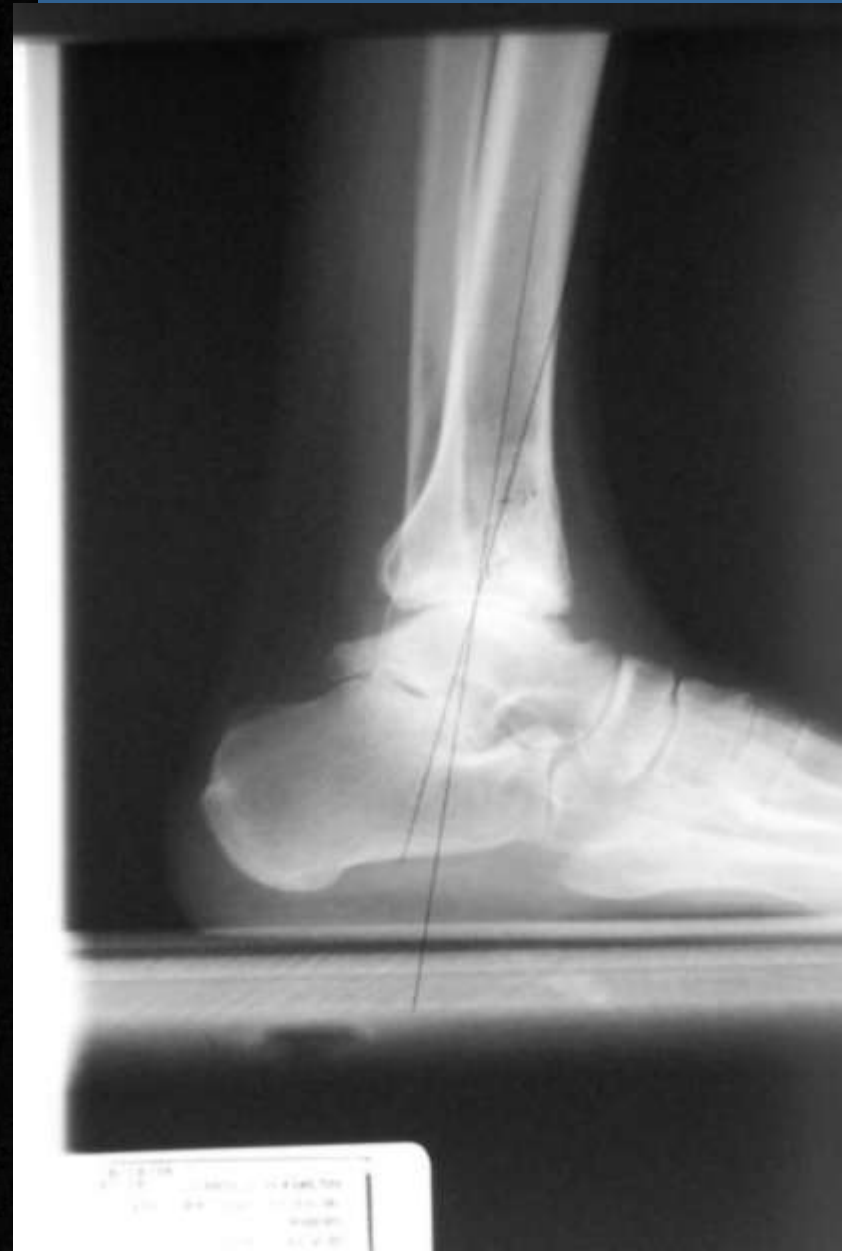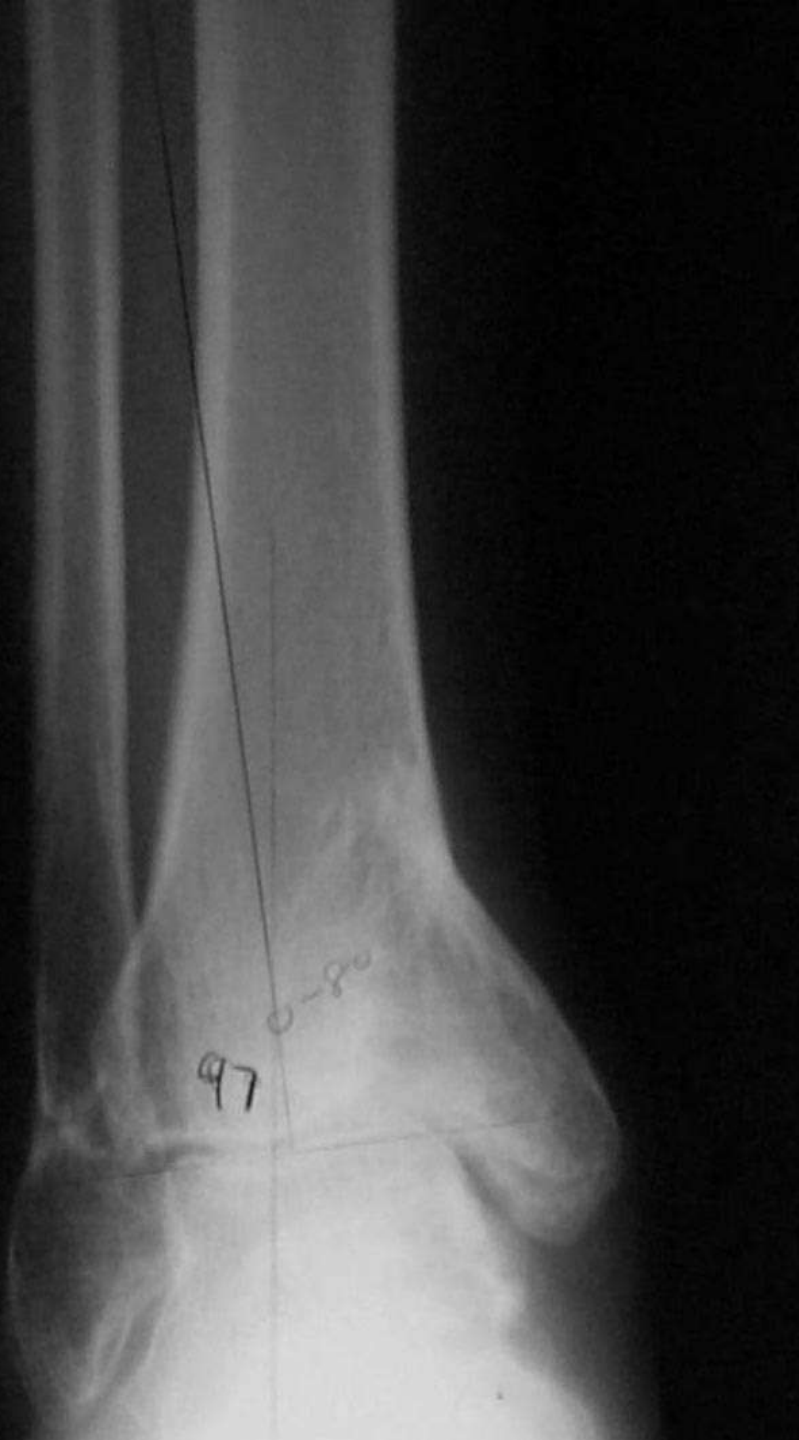2 years

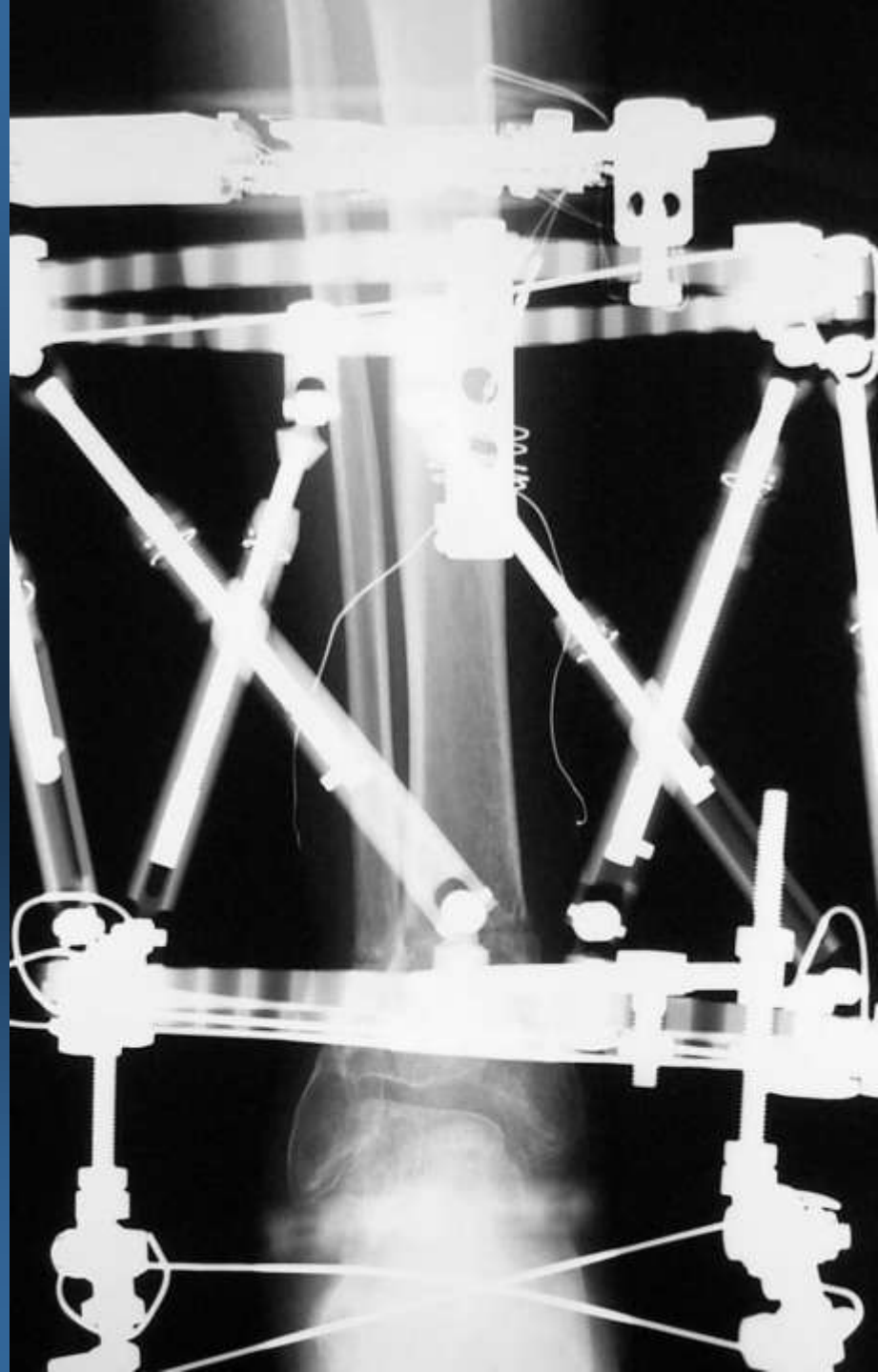
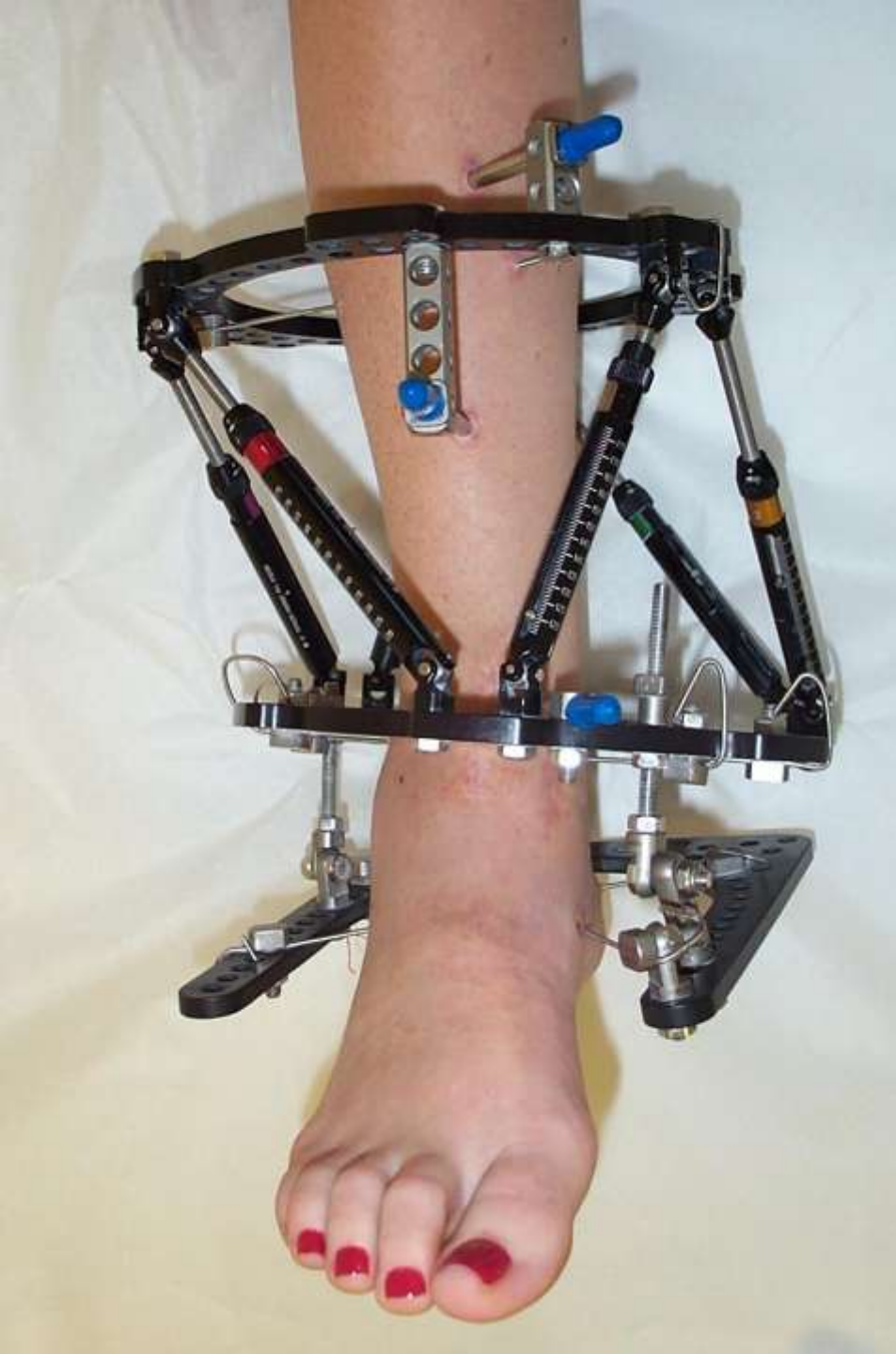




S



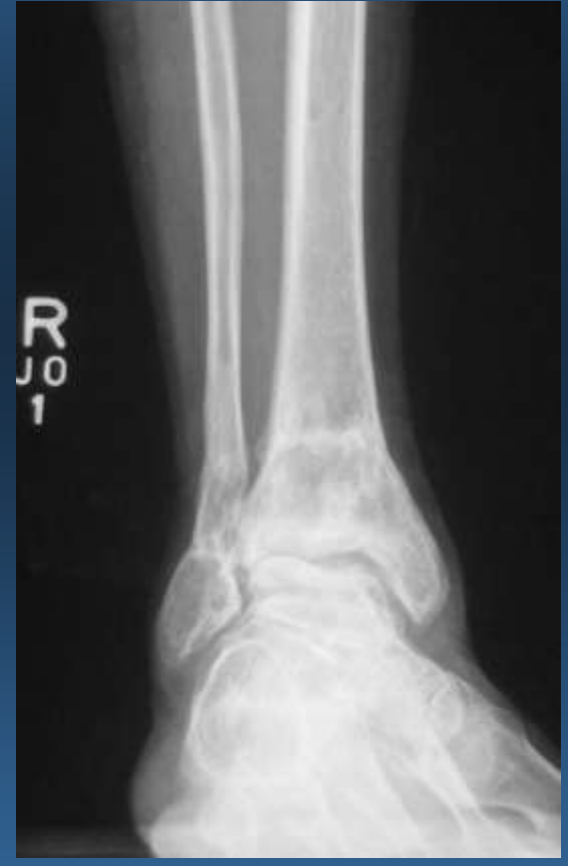
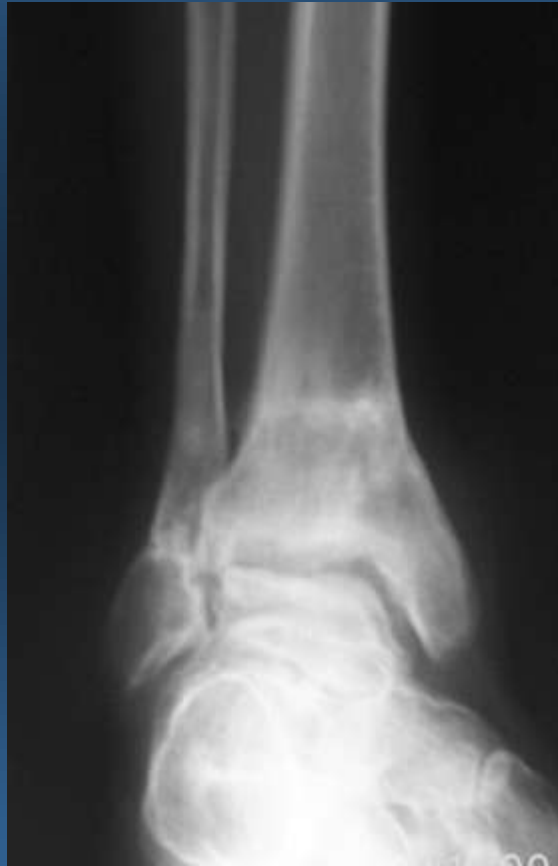
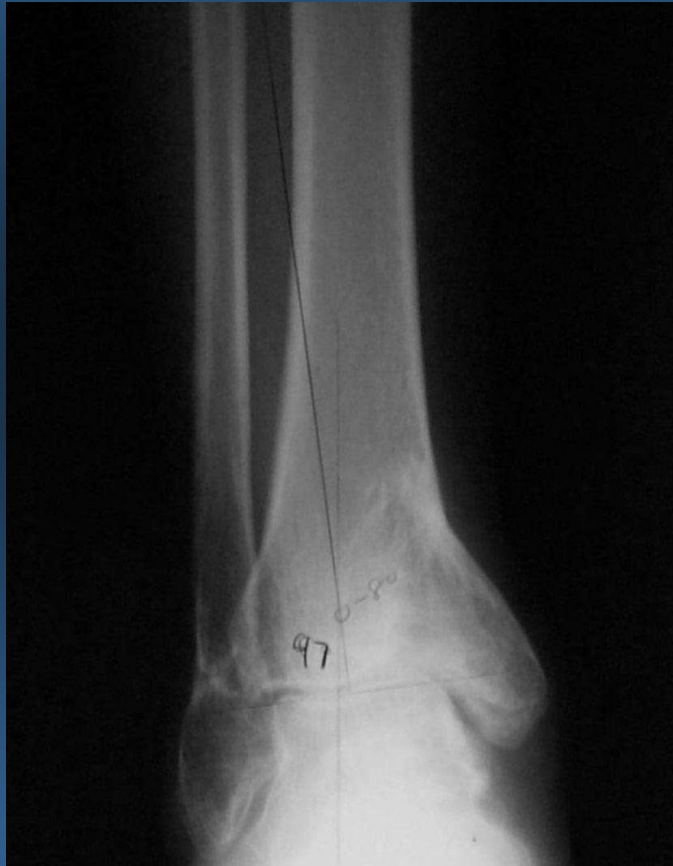

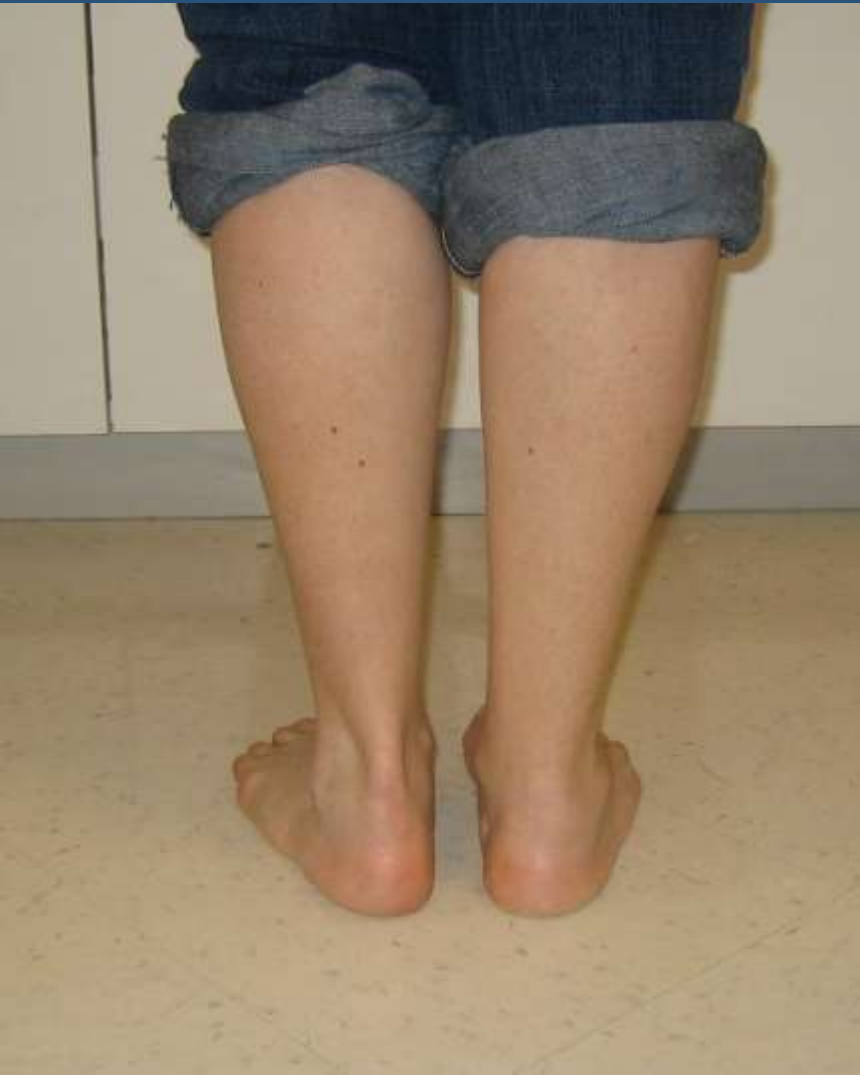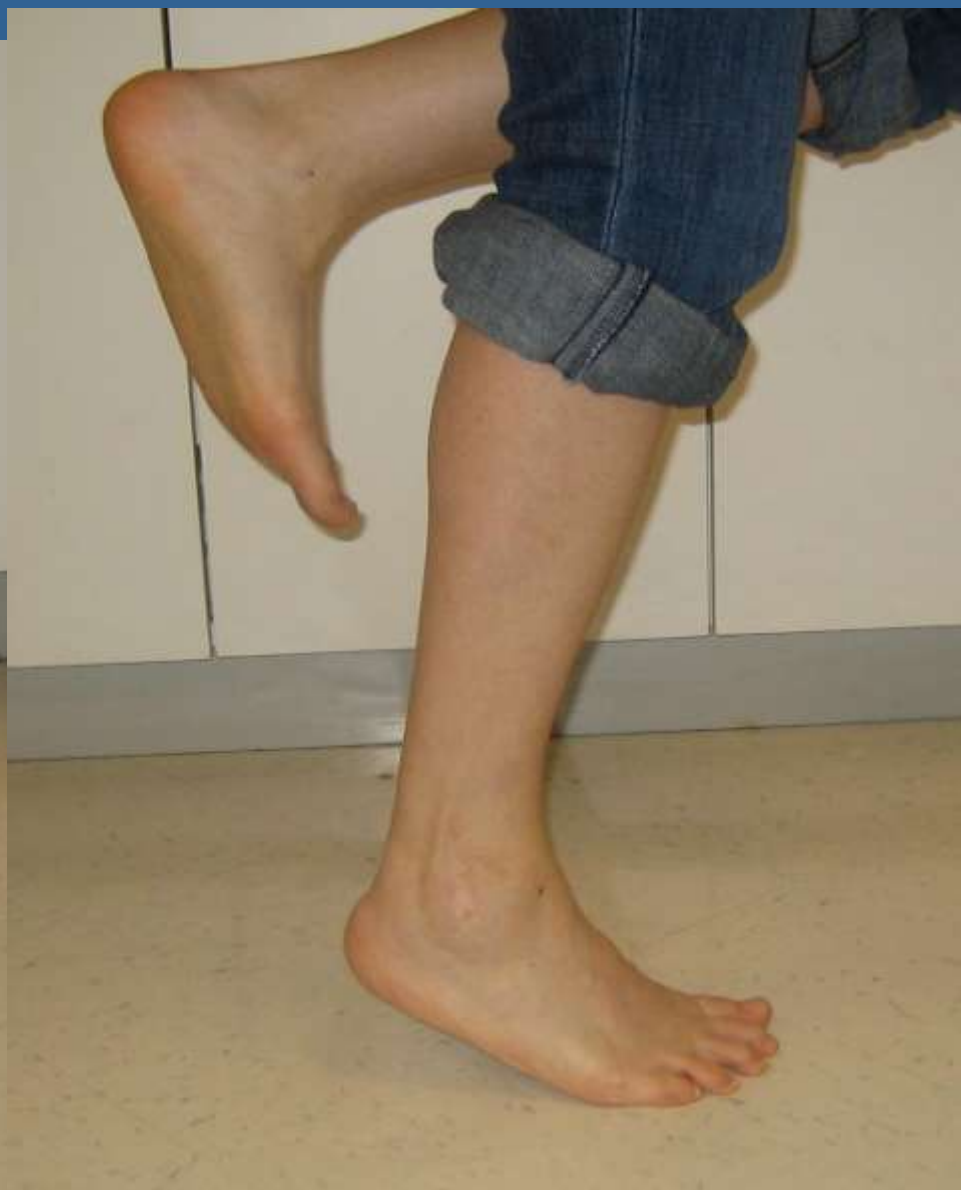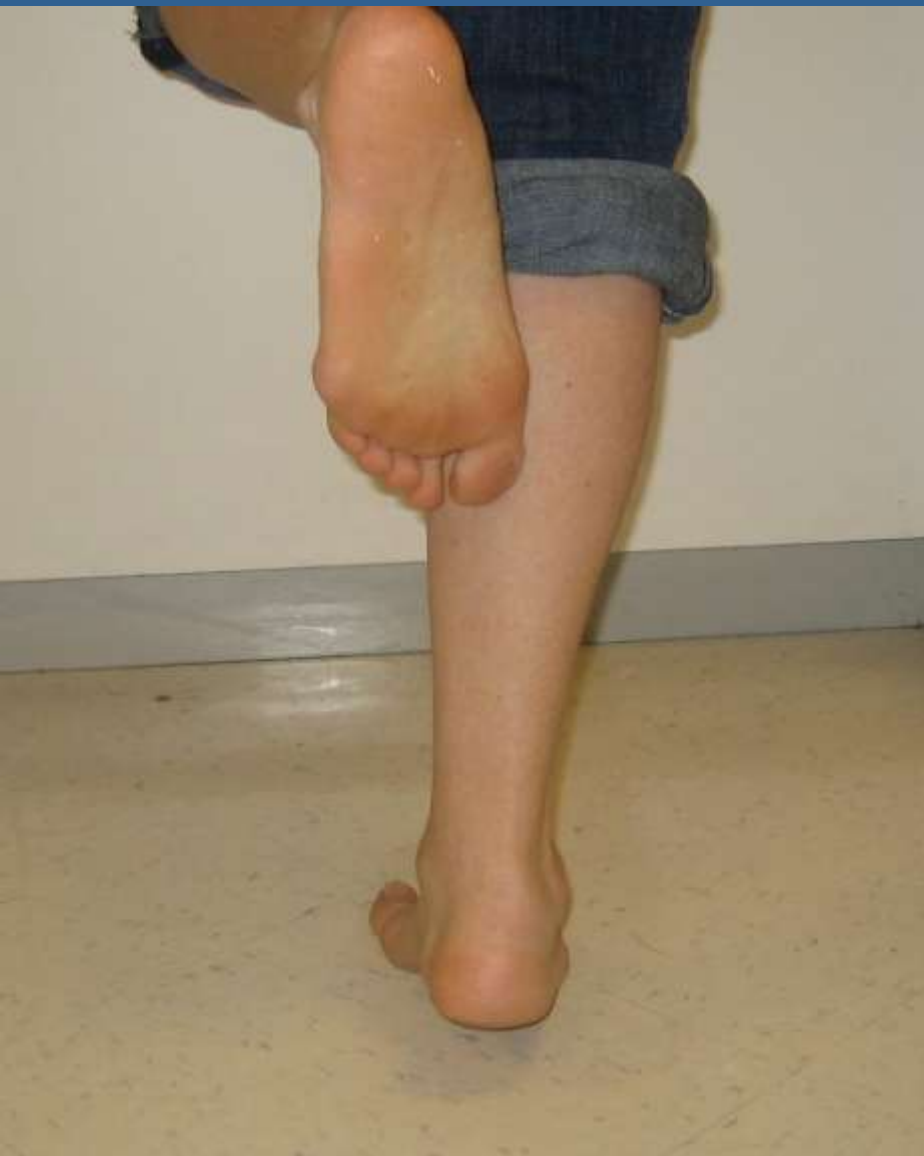Preop

2.5 years

5 years

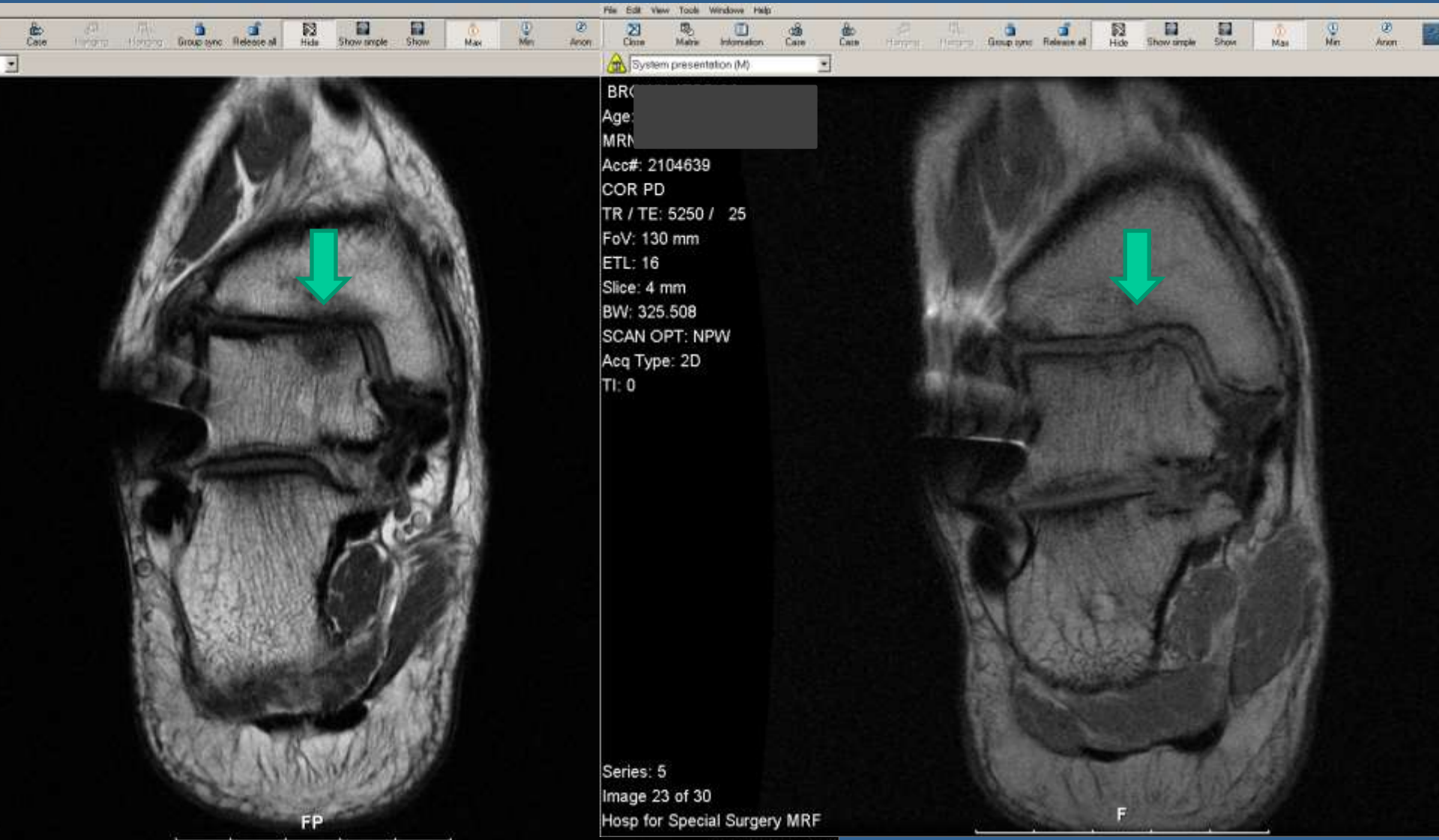




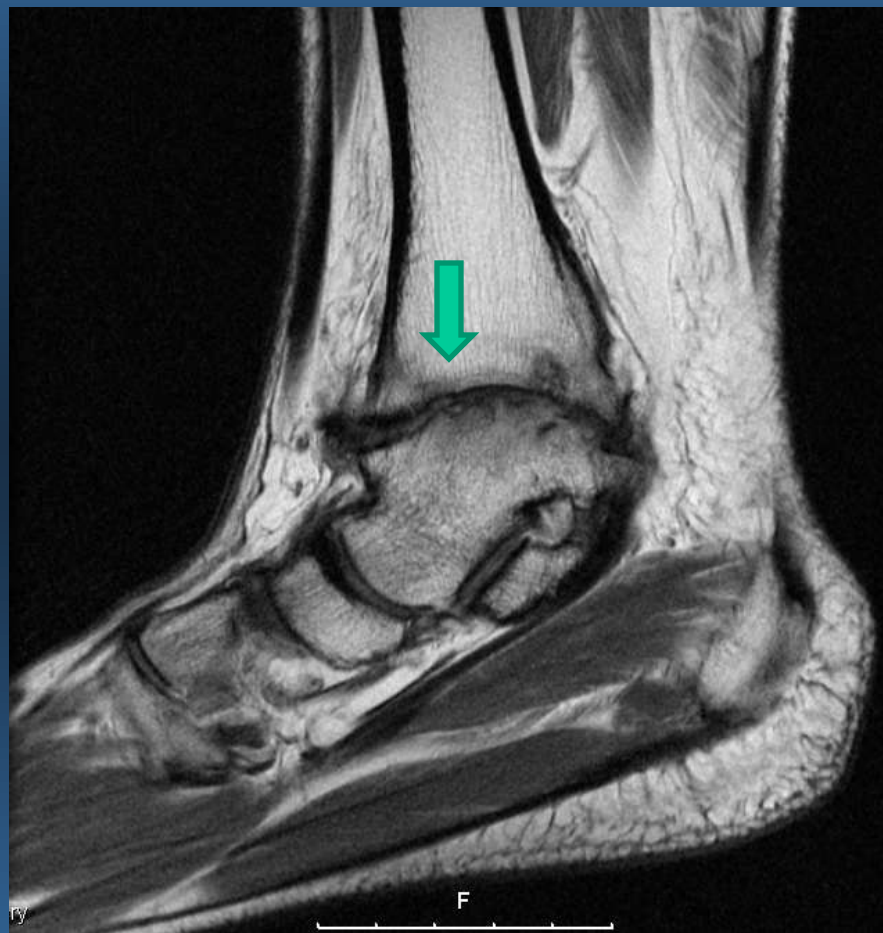

Before

After



Before



After

