

Femoral Deformity Planning: Intentional Placement of the Apex of Deformity

PETER D. FABRICANT, MD, MPH; JAMES M. CAMARA, PHD; S. ROBERT ROZBRUCH, MD

abstract

Full article available online at [Healio.com/Orthopedics](https://www.healio.com/Orthopedics). Search: 20130426-11

Traditionally, correction of femoral deformity has been performed with osteotomies through the center of rotation of angulation (CORA), but the CORA location is not always practical. If the osteotomy is created at a site adjacent to the CORA, an additional translation must be performed to accurately correct the deformity. However, at times, the ideal osteotomy site may require an unfeasible amount of translation. Multiple osteotomies may also be problematic, and when overcorrection of the mechanical axis is planned, the CORA method is not practical.

This article describes a novel method by which the surgeon may choose the location of the osteotomy regardless of the location of the CORA and may consolidate a multiapical deformity into a single corrective osteotomy. Furthermore, intentional mechanical axis overcorrection may be performed to unload knee joint arthritis. Simple, complex, and multiapical deformities may now be corrected via a single familiar surgical procedure, such as a distal femoral osteotomy, and the need for translation is eliminated.

The authors are from the Department of Orthopaedic Surgery (PDF), and the Limb Lengthening and Complex Reconstruction Service (SRR), Hospital for Special Surgery; and the Department of Chemistry (JMC), Yeshiva University, New York, New York.

Drs Fabricant and Camara have no relevant financial relationships to disclose. Dr Rozbruch is a consultant for and earns royalties from Small Bone Innovations and is a consultant for and on the speakers bureau of Smith & Nephew.

This study was approved by the Hospital for Special Surgery Institutional Review Board Protocol #23097.

Correspondence should be addressed to: Peter D. Fabricant, MD, MPH, Department of Orthopaedic Surgery, Hospital for Special Surgery, 535 E 70th St, New York, NY 10021 (fabricantp@hss.edu).

doi: 10.3928/01477447-20130426-11

Acute correction of femoral deformity is commonly performed to restore the mechanical axis of the lower extremity. Currently, acute corrections are used by a variety of orthopedic surgeons. Proximal tibial and distal femoral osteotomies are performed to improve load transmission across an arthritic joint. These osteotomies are typically of low magnitude (5° - 10°), yet have a powerful corrective effect because they are directly adjacent to the joint. Poor or inaccurate preoperative planning may lead to residual or iatrogenic malalignment¹; a meticulous yet simple preoperative planning technique would add to the predictability of successful outcomes after these procedures.

Alternatively, larger and more complex deformities are more difficult to treat. Congenital and posttraumatic lower-extremity deformities may require the use of gradual correction with an external fixator; however, it is occasionally feasible to perform an acute correction for these patients. Traditionally, correction has been performed with osteotomies through the center of rotation of angulation (CORA),² but in some circumstances the CORA location is not practical for performing an osteotomy due to its location in the bone (eg, diaphysis), the bone quality (eg, posttraumatic, previously devitalized), or soft tissue coverage (eg, flap, skin graft). In these instances, if the osteotomy is planned at a site adjacent to the CORA, an additional translation must be performed to accurately correct the deformity.³ However, the ideal osteotomy site could require an unfeasible amount of translation (eg, more than 50% of the bone width). Multiple osteotomies may also be problematic with regard to biologic bone healing and technical difficulty.⁴ Furthermore, when overcorrection of the mechanical axis is planned to provide additional joint unloading, the CORA method is not practical.

This technique allows for the planning and correction of a lower-extremity deformity at any level to be corrected in

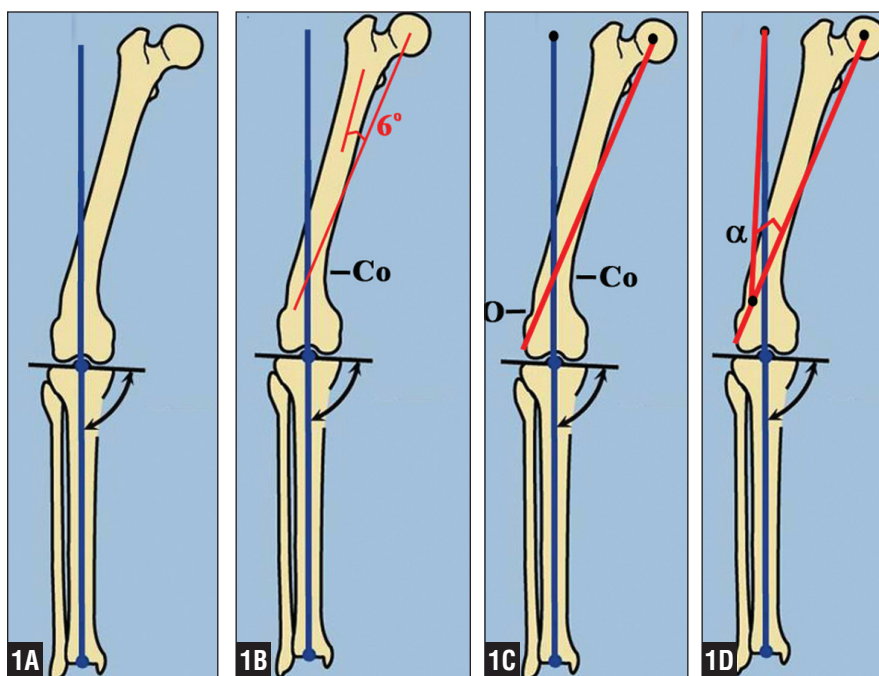


Figure 1: Illustrations showing the preoperative planning technique. First, a straight line is drawn from the center of the tibial plafond through the medial tibial spine to the level of the femoral head. This defines the final neutral mechanical axis (blue line) (A). The current mechanical axis of the femur is drawn 6° from the anatomic axis (using normal anatomic relationships) (B). The intersection of these 2 lines is the center of rotation of angulation (Co). The surgeon may choose an osteotomy level (O); in this case, distal to the CORA at the supracondylar region of the distal femur (C). The angle (α) of osteotomy at the chosen level is measured as the angle between lines drawn from the center of the femoral head along the current mechanical axis to the selected level and from that point to the target femoral head center (D).

an ideal location with commonly available planning tools and a surgical method familiar to a broad range of orthopedic surgeons. Surgeons are able to choose the location of the osteotomy regardless of the location of the CORA and perform acute correction without a simultaneous translation maneuver or multiple osteotomies.

MATERIALS AND METHODS

Institutional review board approval was obtained for this study, although patient treatment was not altered. This technique represents a novel planning method for patients with femoral deformities that can be used in conjunction with several well-established surgical techniques. A mathematical proof was performed using the law of cosines and indicates that the single osteotomy (angle= α) may be made at any point along the femoral mechanical

axis (Figure 1) for the correction of simple, complex, and multiapical deformities.

Surgical Technique

As part of an initial diagnostic work-up, which included a detailed history and physical examination, all patients were evaluated using standing (weight-bearing) 51-inch hip-to-ankle radiographs, which have proven to be ideally suited for evaluating angular and length discrepancies in the lower extremity while minimizing radiation exposure.⁵ A lower extremity that is properly aligned has a neutral mechanical axis of 180° , which is formed by a 3-point line that traverses the center of the femoral head, the center of the knee, and the center of the tibial plafond. Ideally, any surgical correction for abnormal limb alignment will restore this mechanical relationship.

Using this understanding during surgical planning, surgeons can draw a line on the standing radiograph between 2 of these points and define a target for the third. For patients with a femoral deformity with lateral compartment arthritis, some overcorrection of the mechanical axis medially is planned to unload the lateral compartment. A straight line is drawn from the center of the tibial plafond through the medial tibial spine to the level of the center of the femoral head (Figures 1A, 3A); this point represents the target to which the femoral head should be at the final correction. Then, the mechanical axis of the femur is drawn using known anatomical relationships.^{2,3} In patients with a distal deformity, the proximal femur is used and a mechanical axis line is drawn from the center of the femoral head 6° from the anatomic axis (Figures 1B, 3B). Conversely, for patients with a concomitant tibial deformity, the femoral head target point may be drawn by anchoring the femoral mechanical axis distally based on the normal anatomic 2° valgus of the mechanical lateral distal femoral angle. This alternative method may also be performed for patients with a tibial deformity or amputation to recreate the normal anatomic relationships of the femur independently of the tibia.

Because of the graphic nature of this templating method, surgeons can also choose to build in slight additional varus or valgus to customize mechanical load at the tibia. By drawing the mechanical axis slightly lateral to the center of the tibial plateau, surgeons can offload the medial compartment of the knee if concomitant medial compartment osteoarthritis exists. At this point, once the femoral head target is chosen, surgeons can choose the location of the osteotomy. Two lines are then drawn to form an angle: 1 from the current location of the femoral head down the mechanical axis line to the level of the desired osteotomy, and another from that point up to the femoral head target. The correction angle at that level of osteotomy

is the angle formed by these 2 lines (Figures 1C, 1D, 3C, 3D).

RESULTS

Using this technique, surgeons can choose the osteotomy locations regardless of the location of the CORA and can consolidate a multiapical deformity into a single corrective osteotomy. By templating the aforementioned points and lines, a triangle is formed between 3 points: the CORA, the current center of the femoral head, and the target for the femoral head. The equivalence of mechanical axis correction between an osteotomy at the CORA and an osteotomy at a level determined by the surgeon using this technique was proven mathematically using the law of cosines (Figure 2). This proof indicates that the single osteotomy (angle=alpha) can be made at any point along the femoral mechanical axis for correction of simple, complex, and multiapical deformities. This resulted in the derivation of the following formula (parameters defined in the Figure 2 caption):

$$\alpha = \arccos\left(\frac{l^2 + m^2 - d^2}{2lm}\right)$$

Illustrative case examples using this technique are shown in Figures 3 and 4.

DISCUSSION

Previous authors have reported mathematically modeled techniques for complex deformity correction that are successful but have several limitations. Sangeorzan et al^{6,7} developed a mathematical method of correcting multiplanar long bone deformities through a single osteotomy without a translation event; however, the osteotomy was performed through the deformity site, which has similar disadvantages to the CORA technique in that the osteotomy site may be in a site of decreased vascularity (eg, diaphyseal, posttraumatic) or under complex soft tissue coverage (eg, musculocutaneous flap). Furthermore, it requires computer assistance to calculate the correct plane of osteotomy, which may

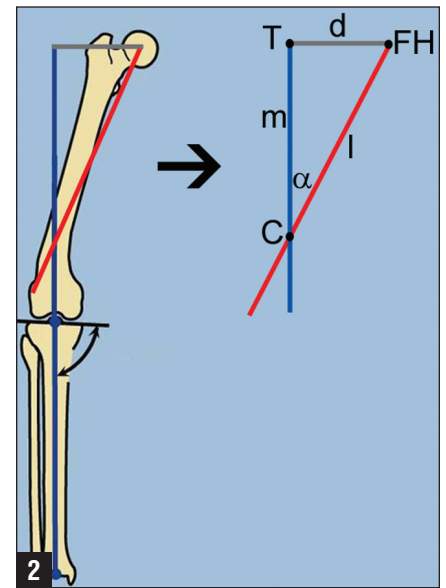


Figure 2: Mathematical proof of the preoperative planning technique. Let (T) be the target position of the femoral head (FH). The distance that the FH must be moved to achieve proper mechanical alignment is given by (d). If the red line denotes the mechanical axis of the femur (as measured 6° off of the proximal femoral anatomic axis), a correction may be made at any point (C) lying a distance (l) from the femoral head along the femoral mechanical axis. The angle of correction (α) at such a point (C) can be derived from the distances (l) and (m) and (d). Because the line segments (TFH), (TC), and (CFH) form a scalene triangle, the angle (α) can be derived from the law of cosines: $d^2 = l^2 + m^2 - 2lm \cos(\alpha)$, and $\alpha = \arccos\left[\frac{l^2 + m^2 - d^2}{2lm}\right]$.

not be available to all orthopedic surgeons. Russell et al^{8,9} reported the clamshell osteotomy for complex diaphyseal deformity, which is advantageous in its use of a single osteotomy to correct length, alignment, and rotation of the proximal and distal joints modeled on the contralateral limb. This technique also requires an osteotomy at the deformity site and a normally aligned contralateral limb, which may not be present in cases of polytrauma or bilateral deformity. Furthermore, computer modeling is required and may not be available to all orthopedic surgeons. Neither the mathematical method described by Sangeorzan et al^{6,7} nor the clamshell osteotomy technique easily allow for intentional axis overcorrection

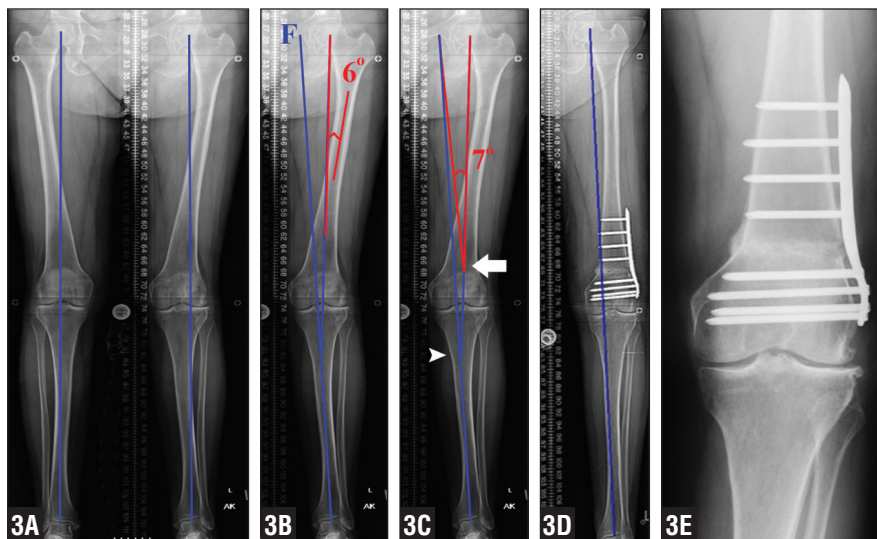


Figure 3: Illustrative case 1. Standing 51-inch anteroposterior hip-to-ankle radiograph showing left genu valgum of a 64-year-old woman with lateral knee pain and early lateral compartment arthrosis (A). The mechanical axis of the left lower extremity passes through the lateral compartment of the knee. A line is drawn from the center of the tibial plafond through the medial tibial spine to create a new mechanical axis line and a target for the femoral head (F) (B). In addition, the current mechanical axis of the femur is drawn from the center of the femoral head 6° from the anatomic axis of the proximal femur (red line). This line intersects the center of rotation of angulation in the proximal tibial diaphysis (arrowhead). An osteotomy site is chosen at the supracondylar region of the distal femur (arrow), and an angle is measured at this level between 2 lines: 1 drawn from the femoral head down the mechanical axis to this level, and another from this point up to the femoral head target (C). Postoperative standing radiograph showing anatomic alignment with the mechanical axis passing medial to the medial tibial spine (D). At final follow-up, the osteotomy site healed with maintenance of correction.

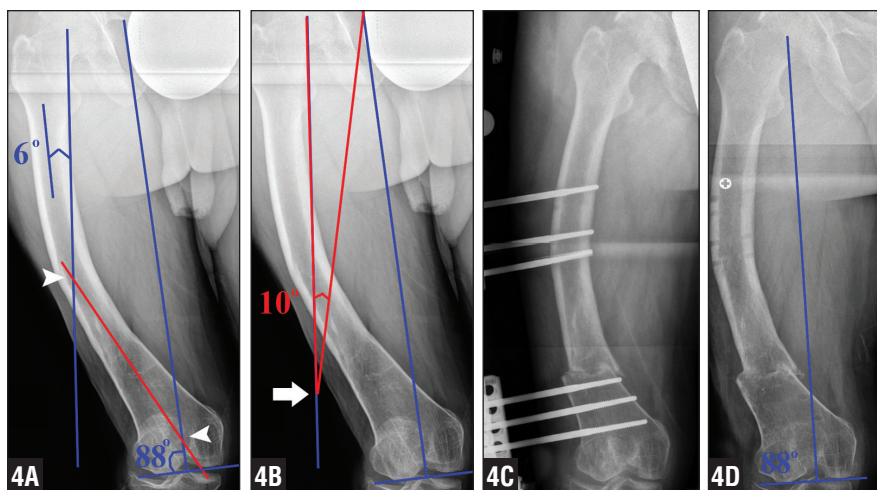


Figure 4: Illustrative case 2. Correction of bowed femoral deformity in a 48-year-old man with a history of childhood rickets. Drawing both proximal (6° from the anatomic axis) and distal (88° from femoral condyles) femoral mechanical axes reveals a complex 2-apex deformity (arrowheads) (A). An angle is formed by 2 lines: 1 from the current femoral head center down the mechanical axis to the level of the chosen osteotomy site (arrow) (B) and from that point to the femoral head target measuring 10°. A distal femoral osteotomy is transfixed with a unilateral external fixator (C). After osseous healing and frame removal, a corrected mechanical axis exists between the distal femur and the center of the femoral head (D).

in order to provide additional unloading of an arthritic knee joint.

It is important to note that this is a novel preoperative planning technique. Although it allows surgeons to choose the level of osteotomy regardless of location of the CORAs and graphically determine the degree of correction, it is only an alternative method to presurgical planning. Surgical technique, osteotomy technique (eg, opening wedge, closing wedge, and neutral wedge), and postoperative protocols remain at the discretion of the treating surgeon.

CONCLUSION

This novel planning technique allows surgeons to choose the osteotomy site regardless of the location of the CORA, and easily allows surgeons to perform intentional mechanical axis overcorrection to alleviate symptoms of medial or lateral knee compartment arthritis. Simple, complex, and multiapical deformities may now be corrected via a single familiar surgical procedure, such as a distal femoral osteotomy, and the need for translation is eliminated. This preoperative planning technique may be done using plain radiographs without comparison to the contralateral limb and eliminates the requirement of computer assistance or modeling. □

REFERENCES

1. Koyonos L, Slenker N, Cohen S. Complications in brief: osteotomy for lower extremity malalignment. *Clin Orthop Relat Res.* 2012; 470(12):3630-3636.
2. Paley D, Herzenberg JE, Tetsworth K, McKie J, Bhav A. Deformity planning for frontal and sagittal plane corrective osteotomies. *Orthop Clin North Am.* 1994; 25(3):425-465.
3. Paley D, Tetsworth K. Mechanical axis deviation of the lower limbs. Preoperative planning of uniapical angular deformities of the tibia or femur. *Clin Orthop Relat Res.* 1992; (280):48-64.
4. Paley D, Tetsworth K. Mechanical axis deviation of the lower limbs. Preoperative planning of multiapical frontal plane angular and bowing deformities of the femur and tibia. *Clin Orthop Relat Res.* 1992; (280):65-71.

5. Sabharwal S, Zhao C, McKeon J, Melaghari T, Blacksin M, Wenekor C. Reliability analysis for radiographic measurement of limb length discrepancy: full-length standing anteroposterior radiograph versus scanogram. *J Pediatr Orthop*. 2007; 27(1):46-50.
6. Sangeorzan BJ, Sangeorzan BP, Hansen ST Jr, Judd RP. Mathematically directed single-cut osteotomy for correction of tibial malunion. *J Orthop Trauma*. 1989; 3(4):267-275.
7. Sangeorzan BP, Judd RP, Sangeorzan BJ. Mathematical analysis of single-cut osteotomy for complex long bone deformity. *J Biomech*. 1989; 22(11-12):1271-1278.
8. Russell GV, Graves ML, Archdeacon MT, Barei DP, Brien GA Jr, Porter SE. The clamshell osteotomy: a new technique to correct complex diaphyseal malunions: surgical technique. *J Bone Joint Surg Am*. 2010; 92 (suppl 1 pt 2):158-175.
9. Russell GV, Graves ML, Archdeacon MT, Barei DP, Brien GA Jr, Porter SE. The clamshell osteotomy: a new technique to correct complex diaphyseal malunions. *J Bone Joint Surg Am*. 2009; 91(2):314-324.