

# Antibiotic-Coated Nail for Fusion of Infected Charcot Ankles

Abhijit Pawar, MD<sup>1</sup>, Goksel Dikmen, MD<sup>1</sup>, Austin Fragomen, MD<sup>1</sup>, and S. Robert Rozbruch, MD<sup>1</sup>

## Abstract

**Background:** Treating infected ankles in patients with neuropathy is difficult, and complications are frequently encountered. Eradication of infection and effective arthrodesis are required for a successful outcome. The purpose of this study was to evaluate the outcomes of patients with Charcot neuropathy whose infected ankles were treated with a retrograde, antibiotic-coated, locked intramedullary nail.

**Methods:** We analyzed 5 patients with infected neuroarthropathy of the ankle joint. Three patients had failed treatment with the circular external fixator for infected neuroarthropathy of the ankle. The other 2 were treated primarily by this technique. All patients were treated with surgical nonunion repair, arthrodesis, and insertion of an antibiotic-coated, locked intramedullary nail. The average age was 59 years (range, 46 to 82 years). The average follow up period was 18 months (range, 12-24 months).

**Results:** The average time taken for radiological healing was 4.1 months (range, 4-4.5 months). In all patients, bony union was achieved and infection was eradicated. There were no cases of hardware failure.

**Conclusion:** Antibiotic-coated nails were used to treat infected ankle nonunions and infected distal tibial fractures in Charcot patients with successful bony union, fusion, and eradication of infection.

**Level of Evidence:** Level IV, therapeutic study.

**Keywords:** arthrodesis, fusion, ankle, infection, osteomyelitis, antibiotic cement, intramedullary nail

Charcot neuroarthropathy is common in patients with diabetes mellitus, peripheral nerve injuries, and spinal abnormalities.<sup>18,21</sup> The combination of osteopenia, bone hyperemia, joint instability, and sensorimotor deficits predisposes patients to the changes seen with Charcot arthropathy. The incidence of neuropathic fractures is estimated at 0.1% to 2.5% in the diabetic population.<sup>8,18,21,27</sup> Ankle neuroarthropathy is a challenging condition to treat because of the instability, deformity, and high incidence of ulceration and osteomyelitis.<sup>20,21,27</sup> The ankle is a common site of involvement, comprising 3% to 10% of all cases.<sup>1,13,21</sup> In addition, Charcot neuroarthropathy is a chronic and progressive process of joint and bone destruction associated with a high incidence of amputation.<sup>18,27</sup> Achieving a stable plantigrade foot remains the ultimate goal in this patient group. Many neuropathic fractures and dislocations of the ankle are treated nonoperatively with the use of total-contact casting, followed by appropriate bracing. However, these conservative treatment options can be complicated by progressive joint collapse, ulceration, and osteomyelitis.<sup>6,20,21</sup>

Operative fixation of the neuropathic ankle joint has been well described.<sup>5,6,10,28</sup> The use of internal fixation including lag screws and plates in Charcot patients carries a risk of failure because of the osteopenic bone's inability to support screw threads. The use of intramedullary nails for

fixation of tibiocalcaneal fusions has become popular for treatment of Charcot arthropathy.<sup>7,14,16,26</sup> However, reconstruction of a failed ankle fusion is challenging as bone quality is often poor, and infection is presumed present until ruled out. Removal of internal or external fixation and debridement of all necrotic bone, prolonged systemic antibiotic administration, and temporary fixation are necessary.<sup>3,4,21</sup> A second-stage surgery would then be needed for definitive fusion and fixation. External fixation is often used for revision arthrodesis and can achieve good results in Charcot patients.<sup>6,10,21,22,28</sup> However, most patients find the frame uncomfortable. After frame removal, there can be refracture at the fusion site or a stress fracture through a previous pin site. When an attempted ankle fusion goes into nonunion after using an external frame, revision options are limited. Contaminated pin sites increase the risk of infection, and osteopenia is often present. The use of a second course of prolonged external fixation is often unacceptable to the patient, and amputation is often discussed.<sup>6,13,28</sup>

<sup>1</sup>Hospital for Special Surgery, New York, NY, USA

## Corresponding Author:

S. Robert Rozbruch, Hospital for Special Surgery, 535 E. 70th St, New York, NY 10021

Email: [rozbruchsr@hss.edu](mailto:rozbruchsr@hss.edu)

**Table 1.** Patient Information

Patient No.	Age	Sex	Diagnosis	Cause of Peripheral Neuropathy	Previous Surgical Procedures	Type of Fusion
1	82	F	Nonunion bimalleolar Fx + OM	Spinal stenosis	ORIF of bimalleolar fracture	Tibiototalcalcaneal fusion
2	61	M	Rt ankle fusion nonunion + OM	DM type 2	CEF + ORIF	Tibiototalcalcaneal fusion
3	50	M	Lt ankle fusion nonunion + OM	DM type 2	CEF	Tibiototalcalcaneal fusion
4	55	M	Rt ankle Charcot arthropathy + OM	Bilateral peripheral neuropathy idiopathic	0	Tibiocalcaneal fusion
5	46	M	Rt ankle septic arthritis, ankle fusion nonunion	DM type 2	CEF	Tibiototalcalcaneal fusion

Abbreviations: Fx, fracture; Rt, right; Lt, left; CEF, circular external fixator; DM, diabetes mellitus; OM, osteomyelitis; ORIF, open reduction internal fixation.

Thonse and Conway<sup>24</sup> showed that the use of a locked intramedullary nail (IMN) with antibiotic cement coating could successfully provide stability and eradicate infection in tibial nonunions and knee fusion. The aim of this study was to assess the treatment of infected Charcot ankles using an antibiotic-coated locked IMN. Outcome was measured by the ability to obtain fusion and eradicate infection.

## Materials and Methods

We retrospectively analyzed a consecutive case series of 5 patients (4 males and 1 female) with infected neuropathic ankles at a tertiary care facility between 2008 and 2010. Patients were identified for inclusion using the service's internal review board–approved database. Relevant demographic and clinical features, including age, sex, history, and radiographic features, were analyzed from the clinical records (Table 1). We used the Sanders and Frykberg<sup>13,21</sup> anatomic classification to describe the location and the Eichenholtz<sup>9,19,20</sup> radiographic staging to describe the stage of Charcot arthropathy (Table 2). All surgeries were performed by the senior author (S.R.R.). The average follow-up period was 18 months (range, 12–24 months).

## Surgical Technique

Preoperative radiographs, including anteroposterior and lateral views of the ankle, and full-length standing anteroposterior views of both lower extremities made with a 130-cm cassette were evaluated. All patients were treated by the Phoenix retrograde ankle arthrodesis nail (Biomet, Warsaw, IN) coated with antibiotic-impregnated polymethyl methacrylate bone cement. An adequate nail length was calculated with the same standard method as is used to determine the length of an interlocking nail (ie, from the plantar aspect of the calcaneus to the desired level in the tibia). In general, a 15-cm nail provided sufficient support for the ankle fusion. A long intramedullary nail was used in the current series if a potential stress riser point was present at

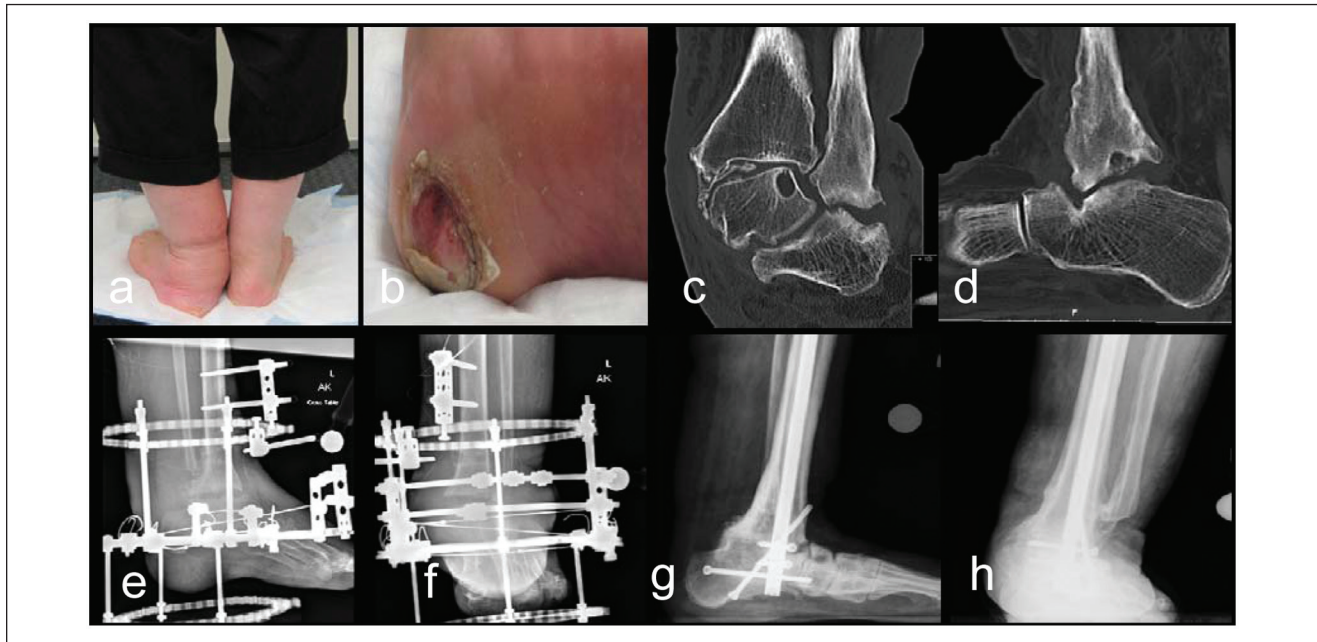
the proximal tip of the nail. We used a sterilized silicone rubber tube of 12.5-mm inner diameter for preparation of the antibiotic-coated locked IMN. One 40-g bag of cement was mixed with 2 g of vancomycin and 3.4 g of tobramycin. The cement was inserted into the silicone tube with the cement gun. The IMN was then inserted into the tubing. After the cement had cured, the tubing was cut off the IMN. This technique gave a uniform covering of cement over the nail and took about 10 to 15 minutes in the operating room.<sup>24</sup> We used a 10-mm-diameter IMN and achieved 1.25 mm of cement coating on the outer surface of the rod.

The supine position was used because it gave good exposure to both the medial and the lateral sides of the ankle. The transfibular approach was used, and the distal fibula was resected proximal to the tibiotalar joint. A flat cut resection technique was used for preparation of the joint surfaces.<sup>14</sup> Deformity was corrected by making the distal tibial cut perpendicular to the tibial axis and the talus or calcaneus cut parallel to the weightbearing surface of the foot. All necrotic and infected tissue was removed. The talus was removed if it did not appear viable. Five tissue specimens were sent to the microbiology service for culture and sensitivity, and a specimen was sent to the pathology service to analyze for infection. Intravenous antibiotics were given after the tissue cultures were taken. The surfaces were reduced and pinned in place. Flexible reamers were used to increase the medullary canal to 1 mm above the diameter of the nail (13.5 mm). An intramedullary canal brush was used to debride the canal, and several liters of pulsatile lavage was done. The IMN was then inserted. Two proximal interlocking screws were inserted using the free hand technique. Compression across the ankle arthrodesis was achieved with the outboard compression device since the cement mantle blocks the internal IMN compression mechanism. An outrigger was used to place 2 lateral to medial locking screws (1 in the calcaneus, 1 in the talus if present) and 1 posterior to anterior calcaneus screw. An additional screw was inserted outside the IMN in an oblique fashion across the calcaneus, subtalar, and ankle arthrodesis site (Figure 1).

**Table 2.** Patient Information Continued

Charcot Eichenholtz Stage/ Sanders Anatomical Classification	Bone Resection	Organism	Surgical Technique	Postoperative ABX	Bone Healing Time, mo	Follow-up, mo
3/IV	3 cm	MSSA	Biomet AFN antibiotic coated (10 mm × 17 cm)	6 wk IV oxacillin + oral doxycycline 100 × 2 mo	4	24
None	None	MRSE	Biomet AFN (1 g vancomycin, 2.5 g tobramycin) coated retrograde IMN (10 mm × 15 cm)	6 wk IV vancomycin + rifampin + oral doxycycline 100 × 2 mo	4	12
3/IV	None	MRSA	Biomet AFN antibiotic coated (10 mm × 27 cm)	6 wk IV daptomycin 800 mg + oral doxycycline 100 × 2 mo	4	24
1/IV	1 cm	MRSA	Biomet AFN antibiotic coated (10 mm × 30 cm)	6 wk IV daptomycin 800 mg + rifampin + oral doxycycline 100 × 2 mo	4.5	16
3/IV	None	Negative	Biomet AFN antibiotic coated (10 mm × 18 cm)	Did not require postoperative antibiotic therapy.	4	14

Abbreviations: ABX, antibiotics; AFN, ankle fusion nail; IMN, intramedullary nail; MRSA, methicillin-resistant *Staphylococcus aureus*; MRSE, methicillin-resistant *Staphylococcus epidermidis*; MSSA, methicillin-sensitive *Staphylococcus aureus*.



**Figure 1.** (a and b) Patient with heel valgus and ulcer (c and d) with advanced Charcot arthropathy Eichenholtz/Sanders III/IV (e and f) failed treatment with Ilizarov frame. (g and h) Follow-up radiographs.

The patients were put in a postoperative plaster splint followed by a series of short leg casts for 4 months and were nonweightbearing during this period. This was followed by a walking cast for 1 month and then a Cam walker boot for 1 month. This was followed by custom-made footwear.

### Case Example

Case 3 (Figure 1) was a 50-year-old male with a 15-year history of peripheral neuropathy who presented with large heel ulcer, valgus deformity, and Charcot neuroarthropathy

of the left ankle (Eichenholtz/Sanders type 3/IV). His cultures were positive for infection with methicillin-resistant *Staphylococcus aureus*. His erythrocyte sedimentation rate (ESR) was 126 mm/h and his C-reactive protein (CRP) was 21.1 mg/dL. We treated him initially with a circular frame. Postoperatively, he received 6 weeks of intravenous daptomycin for antibiotic prophylaxis followed by oral doxycycline for 2 months. His wound healed well; however, he developed cellulitis around the foot and ankle, pin tract infections, and severe pain during the first 3 months while he was in the Ilizarov frame. He was intolerant to the frame; thus, we treated this ankle fusion nonunion with the antibiotic-coated IMN.

## Results

The ESR and the CRP were abnormal in 4 patients (1, 2, 3, and 4) and they returned to normal after treatment. Two patients (1 and 4) had a valgus deformity of the ankle preoperatively as assessed by the malalignment test and the Saltzman view, which was completely corrected at follow-up. The other 3 patients did not have large deformity as it had been corrected during previous fusion attempts with circular external fixation (CEF). The bony union was assessed by bridging bone seen on radiographs and computed tomography scan. Infection control was assessed by normal values of ESR and CRP and healing of wounds. The goal of infection control and bony union was achieved in all the patients. The average time taken to see complete radiological healing was 4.1 months (range, 4-4.5 months)

## Discussion

Ankle arthrodesis with a retrograde intramedullary nail has been used successfully in patients with Charcot arthropathy.<sup>2,7,16,23,25,26</sup> A nail inserted through the plantar aspect of the foot can afford excellent stability, position, and alignment.<sup>7,25,26</sup> The level of the tibia fixed by the retrograde ankle intramedullary nail is determined by the nail length. In patients with neuropathy, a long intramedullary nail can be used to provide protection against tibia fracture at a potential stress riser point at the proximal tip of the nail. The 2 goals of treatment of infected neuropathic ankles are eradication of infection and achievement of a stable ankle through bony fusion.<sup>3,4</sup> Patients with previous failed ankle fusions, infection, and instability may be candidates for limb salvage surgery.<sup>6,21,28</sup> These salvage procedures are a last resort to eradicate infection, achieve union, relieve pain, and prevent recurrent ulceration.

Good results have been achieved using CEF in patients with infection, instability, deformity, and nonunion.<sup>6,10,22,28</sup> The amputation rate after salvage ankle fusions with the Ilizarov frame has been reported from 7% to 14%.<sup>10,28</sup> The

circular frame is bulky and can injure the opposite leg. Infection of the pin sites is very common and can evolve into osteomyelitis. Breakage of the pins and wires is also common and requires surgical intervention. In addition to all these factors, duration of treatment is long. These patients treated with external fixation who did not tolerate the frame or failed to unite with the frame may be less likely to agree to an amputation.<sup>6,22,28</sup> The described technique may be used for those patients who have failed ankle fusion with CEF. Patient 2 in the current study failed to unite despite being in a frame for 11 months. Similarly, patients 3 and 5 in the study developed intolerance to the frame because of repeated pin infections, breaking of wires, and cellulitis around the foot and ankle. Patient 4 in the current study refused treatment with a frame because of its cumbersome nature and the duration of treatment. However, all these patients did well with the antibiotic-coated nail and showed complete healing after about 4 months. Autograft, allograft, or bone graft substitutes including bone morphogenetic proteins were not used to enhance the fusion in any of these cases. The implants did not require removal, and long-term antibiotic suppression was not needed in any of the patients. A limitation of the technique was that we could use a silicon tube of only 12.5-mm diameter and a nail of 10-mm diameter in all the cases. We also believe that the diameter of the silicon tube may change slightly after insertion of bone cement due to its exothermic reaction. The silicon tube with variable diameters would be ideal. It would also give the surgeon flexibility to choose the diameter of the nail.

Antibiotic-impregnated cement beads and spacer blocks have been used successfully in the treatment of open fractures, infected nonunions, and infected joint arthroplasty.<sup>10,15,22</sup> Treatment with the antibiotic-coated nail leads to local antibiotic delivery as well as stable internal fixation.<sup>11,12,15,17,24,25</sup> Since the IMN is locked, it can be used as definitive fixation rather than as an intermediate stage. Another advantage of the IMN is that it helps avoid complications associated with external fixation while providing a comparable result. One limitation is that this series is small and uncontrolled. A larger study with longer follow-up and assessment of functional outcome would provide more substantial information. A comparison to other methods such as use of CEF or 2-stage treatment with internal fixation would be good material for future study. In summary, this case series demonstrated the successful use of an antibiotic-coated IMN for limb salvage of infected ankle arthrosis and ankle fusion nonunions in patients with neuropathy.

## Declaration of Conflicting Interests

The author(s) declared no potential conflicts of interest with respect to the research, authorship, and/or publication of this article.

## Funding

The author(s) received no financial support for the research, authorship, and/or publication of this article.

## References

1. Ayoub MA. Ankle fractures in diabetic neuropathic arthropathy: can tibiotalar arthrodesis salvage the limb? *J Bone Joint Surg Br.* 2008;7:906-914.
2. Caravaggi C, Cimmino M, Caruso S, Dalla Noce S. Intramedullary compressive nail fixation for the treatment of severe Charcot deformity of the ankle and rear foot. *J Foot Ankle Surg.* 2006;1:20-24.
3. Cierny G III, Cook WG, Mader JT. Ankle arthrodesis in the presence of ongoing sepsis: indications, methods, and results. *Orthop Clin North Am.* 1989;4:709-721.
4. Cierny G III, Cook WG, Mader JT. Ankle arthrodesis in the presence of continuous sepsis: indications, methods, and results. *Clin Podiatr Med Surg.* 1990;7:545-563.
5. Cinar M, Derincek A, Akpinar S. Tibiocalcaneal arthrodesis with posterior blade plate in diabetic neuroarthropathy. *Foot Ankle Int.* 2010;6:511-516.
6. Dalla Paola L, Brocco E, Ceccacci T, et al. Limb salvage in Charcot foot and ankle osteomyelitis: combined use single stage/double stage of arthrodesis and external fixation. *Foot Ankle Int.* 2009;11:1065-1070.
7. Dalla Paola L, Volpe A, Varotto D, et al. Use of a retrograde nail for ankle arthrodesis in Charcot neuroarthropathy: a limb salvage procedure. *Foot Ankle Int.* 2007;9:967-970.
8. de Souza LJ. Charcot arthropathy and immobilization in a weight-bearing total contact cast. *J Bone Joint Surg Am.* 2008;4:754-759.
9. Eichenholtz S, ed. *Charcot Joint.* Springfield, IL: Charles C. Thomas; 1966.
10. El-Gafary KA, Mostafa KM, Al-Adly WY. The management of Charcot joint disease affecting the ankle and foot by arthrodesis controlled by an Ilizarov frame: early results. *J Bone Joint Surg Br.* 2009;10:1322-1325.
11. Hanssen AD. Local antibiotic delivery vehicles in the treatment of musculoskeletal infection. *Clin Orthop Relat Res.* 2005;437:91-96.
12. Madanagopal SG, Seligson D, Roberts CS. The antibiotic cement nail for infection after tibial nailing. *Orthopedics.* 2004;7:709-712.
13. Myers TG, Lowery NJ, Frykberg RG, Wukich DK. Ankle and hindfoot fusions: comparison of outcomes in patients with and without diabetes. *Foot Ankle Int.* 2012;1:20-28.
14. Myerson MS, Alvarez RG, Lam PW. Tibiocalcaneal arthrodesis for the management of severe ankle and hindfoot deformities. *Foot Ankle Int.* 2000;8:643-650.
15. Nizegorodcew T, Palmieri G, Marzetti E. Antibiotic-coated nails in orthopedic and trauma surgery: state of the art. *Int J Immunopathol Pharmacol.* 2011;1(suppl 2):125-128.
16. Noonan T, Pinzur M, Paxinos O, Havey R, Patwardhin A. Tibiotalocalcaneal arthrodesis with a retrograde intramedullary nail: a biomechanical analysis of the effect of nail length. *Foot Ankle Int.* 2005;4:304-308.
17. Paley D, Herzenberg JE. Intramedullary infections treated with antibiotic cement rods: preliminary results in nine cases. *J Orthop Trauma.* 2002;10:723-729.
18. Pinzur MS. Diabetic peripheral neuropathy. *Foot Ankle Clin.* 2011;2:345-349.
19. Pinzur MS, Lio T, Posner M. Treatment of Eichenholtz stage I Charcot foot arthropathy with a weightbearing total contact cast. *Foot Ankle Int.* 2006;5:324-329.
20. Pinzur MS, Shields N, Trepman E, Dawson P, Evans A. Current practice patterns in the treatment of Charcot foot. *Foot Ankle Int.* 2000;11:916-920.
21. Rogers LC, Frykberg RG, Armstrong DG, et al. The Charcot foot in diabetes. *Diabetes Care.* 2011;9:2123-2129.
22. Tellisi N, Fragomen AT, Ilizarov S, Rozbruch SR. Limb salvage reconstruction of the ankle with fusion and simultaneous tibial lengthening using the Ilizarov/Taylor spatial frame. *HSS J.* 2008;1:32-42.
23. Thomas RL, Sathe V, Habib SI. The use of intramedullary nails in tibiotalocalcaneal arthrodesis. *J Am Acad Orthop Surg.* 2012;1:1-7.
24. Thonse R, Conway JD. Antibiotic cement-coated nails for the treatment of infected nonunions and segmental bone defects. *J Bone Joint Surg Am.* 2008;90(suppl 4):163-174.
25. Woods JB, Lowery NJ, Burns PR. Permanent antibiotic impregnated intramedullary nail in diabetic limb salvage: a case report and literature review [published online February 1, 2012]. *Diabet Foot Ankle.*
26. Wukich DK, Shen JY, Ramirez CP, Irrgang JJ. Retrograde ankle arthrodesis using an intramedullary nail: a comparison of patients with and without diabetes mellitus. *J Foot Ankle Surg.* 2011;3:299-306.
27. Young MJ, Marshall A, Adams JE, Selby PL, Boulton AJ. Osteopenia, neurological dysfunction, and the development of Charcot neuroarthropathy. *Diabetes Care.* 1995;1:34-38.
28. Zarutsky E, Rush SM, Schuberth JM. The use of circular wire external fixation in the treatment of salvage ankle arthrodesis. *J Foot Ankle Surg.* 2005;1:22-31.