HOSPITAL FOR SPECIAL SURGERY

SUMMER 2010 | VOLUME 1 | ISSUE 2

Grand Rounds from HSS

MANAGEMENT OF COMPLEX CASES

Authors

Edward V. Craig, MD, MPH
Attending Orthopaedic Surgeon
Hospital for Special Surgery
Professor of Orthopaedic Surgery
Weill Cornell Medical College

Austin T. Fragomen, MD
Assistant Attending Orthopaedic Surgeon
Hospital for Special Surgery
Assistant Professor of Orthopaedic Surgery
Weill Cornell Medical College

David L. Helfet, MD
Attending Orthopaedic Surgeon
Hospital for Special Surgery
Professor of Orthopaedic Surgery
Weill Cornell Medical College

Thomas P. Sculco, MD
Surgeon-in-Chief and Medical Director
Korein-Wilson Professor of Orthopaedic Surgery
Hospital for Special Surgery
Professor of Orthopaedic Surgery
Weill Cornell Medical College

Co-authors

Danilo Bruni, MD
Teaching Assistant in Orthopaedics and Traumatology
Bologna University
Specialist in Orthopaedics and Traumatology
Istituto Ortopedico Rizzoli
Bologna, Italy

Lawrence V. Gulotta, MD
Orthopaedic Surgery Fellow
Sports Medicine and Shoulder Service
Hospital for Special Surgery

Devon M. Jeffcoat, MD
Orthopaedic Trauma Fellow
Orthopaedic Trauma Service
Hospital for Special Surgery

Each author certifies that Hospital for Special Surgery has approved the reporting of this case and that all investigations were conducted in conformity with ethical principles of research.

A MESSAGE FROM THE SURGEON-IN-CHIEF

Welcome to the second issue of *Grand Rounds* from Hospital for Special Surgery. Edward C. Jones, MD, MA, will serve as editor of this publication, assisted by an advisory board of specialists with diverse expertise in surgical subspecialties and musculoskeletal imaging. At HSS we believe in using the cases in our Grand Rounds to illustrate solutions to complex cases and emphasize basic principles which are applicable to all patients.

— Thomas P. Sculco, MD, Surgeon-in-Chief

FROM THE EDITOR

I am honored to serve as the editor of *Grand Rounds from HSS/Management of Complex Cases* and look forward to presenting a variety of cases that demonstrate the management of difficult issues that challenge orthopaedic surgeons and their colleagues across the wide spectrum of musculoskeletal conditions.

The cases presented in this volume highlight the challenging consequences of trauma. David Helfet demonstrates the importance of surgical exposure and well-planned osteosynthesis in treating a posterior hip dislocation with femoral head and posterior wall acetabular fractures. The principles of the Ilizarov method are applied by Austin Fragomen to achieve limb lengthening, deformity correction and union in a hypertrophic non-union of the femur. Edward Craig uses the evolving technology of reverse shoulder arthroplasty to treat a four-part proximal humerus fracture with a pre-existing large rotator cuff tear. And leading off, a case dealing with the devastating consequence of periarticular insensitivity to repeated microtrauma in a neuropathic knee. With careful soft tissue dissection and a rotating hinge prosthesis, Tom Sculco is able to restore alignment and stability to the knee with excellent return of function.

We hope you find these special cases to be interesting and the principles presented informative. We welcome comment at complexcases@hss.edu.

— Edward C. Jones, MD, MA, Assistant Attending Orthopaedic Surgeon

in this issue

CASE 1

Neuropathic Joint, Total Knee Replacement

Case presented by Thomas P. Sculco, MD, and Danilo Bruni, MD

Figure 1: Antero-posterior radiograph of the neuropathic knee joint, secondary to diabetes mellitus

Figure 2: Lateral radiograph of the neuropathic knee joint

Figure 3: Antero-posterior radiograph after knee arthroplasty using a rotating hinge prosthesis

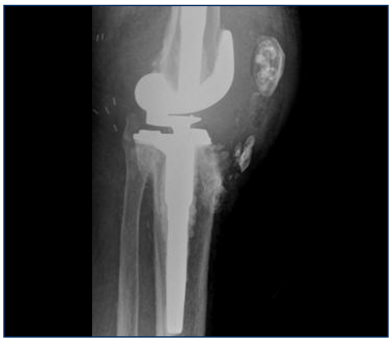

Figure 4: Lateral radiograph after knee arthroplasty using a rotating hinge prosthesis

AUTHOR DISCLOSURES:
Dr. Sculco does have a financial interest or relationship with the manufacturers of products or services.
- Research support, Exactech

Dr. Bruni does not have a financial interest or relationship with the manufacturers of products or services.

CASE REPORT: A 53-year-old male presented with severe knee deformity and an inability to walk. The patient stated that he had been confined to a wheelchair for the previous six months and had become completely dependent on his family for activities of daily living. His medical history revealed that he had Type I Diabetes Mellitus requiring daily insulin.

On physical examination the patient was overweight with a BMI of 35. He was able to transfer to the examining table but could not stand without assistance. He was unable to ambulate. There was swelling noted in both pretibial and ankle areas but no areas of skin breakdown. Examination of the knee demonstrated a posterior knee dislocation with a flexion contracture of 60 degrees with further flexion possible to 75 degrees. There was marked varus deformity of the knee with crepitus on knee motion and significant medial/lateral instability. The patient reported mild discomfort on knee flexion and extension. Peripheral pulses were diminished. Radiographs demonstrated complete posterior dislocation of the knee with marked bone loss on the upper tibia, particularly on the medial side. There was evidence of bone fragmentation and complete obliteration of the joint space (Figure 1, 2).

DISCUSSION: A neuropathic joint was diagnosed and total knee replacement was recommended to the patient because of his marked disability, severe deformity and instability. After medical and vascular clearance, the patient was taken to the operating room. Exposure of the knee was difficult, particularly the posterior aspect of the joint. Utilizing sharp dissection, the posterior capsule was released to allow the tibia to be translated anteriorly. There was marked destruction of the proximal tibia and bone was resected to achieve planar surfaces of the distal femur and proximal tibia. Radical soft tissue release was necessary to mobilize the knee joint into extension. A rotating hinge prosthesis was used to restore bone loss and provide knee joint stability. The extensor mechanism was imbricated to reduce redundancy from the persistent flexion contracture.

Postoperatively the patient was placed in a Bledsoe brace for four weeks to support the knee during ambulation, and flexion was gradually allowed to 90 degrees. The wound healed without complication. At three months postoperative, the patient demonstrated a range of motion of 10-100 degrees and had a 10 degree extensor lag. The patient was ambulatory around the house with a cane and outdoors with a walker. The knee was stable and without pain. (Figure 3, 4)

In 1868, Jean Marie Charcot (1) first described a severely destroyed knee joint in a patient with tabes dorsalis. The neuropathic joint is a severely destructive process associated with nerve damage and periarticular insensitivity. The diminution or absence of proprioception and nociception results in poor joint protection and undetected microtrauma, progressively producing bone destruction and attenuation of ligaments (2). The exact pathomechanism for the disease is unknown and "neurotraumatic" and "neurovascular" theories are still debated as a basis for neurogenic arthropathy (3). Diabetes mellitus is the most prevalent cause of neuropathic joints with the ankle, tarsometatarsal and tarsal joints most commonly affected. When the knee joint is involved, marked disorganization of the joint with gross instability and bone fragmentation as in this case is usually present. Conservative treatment with bracing of the knee joint is usually not successful. Historically the surgical treatment of choice has been arthrodesis of the knee. Although stability is provided by knee fusion, functional disability is significant. In an attempt to maintain better function and mobility, knee arthroplasty is an option (4-8). The use of condylar or constrained condylar knee implants does not provide adequate stability and dislocation, and early loosening may occur. The rotating hinge-type prosthesis is necessary to correct the severe bone deficiency with local or segmental augmentation and provide optimal knee joint stability. The disadvantage of a rotating hinge is the increased load to the interfaces, which may result in loosening of the prosthesis.

In patients with severe fixed knee joint dislocation as presented in this patient, neurovascular injury may occur during posterior dissection, and exposure must be performed carefully. Mobilization of the tibia must be possible to relocate the joint, and this requires skeletalization of the soft tissues from the distal femur and proximal tibia.

Excellent return of function is possible as in this patient when joint relocation, stability and bone restoration is effected.

References located on back page.

CASE 2

Open Reduction of Pipkin IV Fracture through Trochanteric Flip Osteotomy

Case presented by David L. Helfet, MD, and Devon M. Jeffcoat, MD

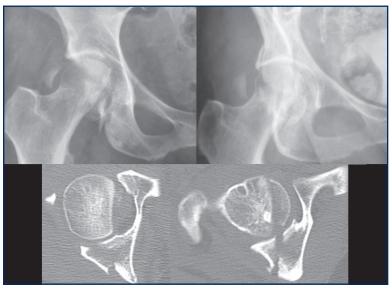

Figure 1A-C: Anteroposterior (AP) and Obturator Oblique radiographic pelvic views and axial CT images through the hip joint (clockwise from top-left) illustrating a comminuted femoral head and posterior acetabular wall fracture.

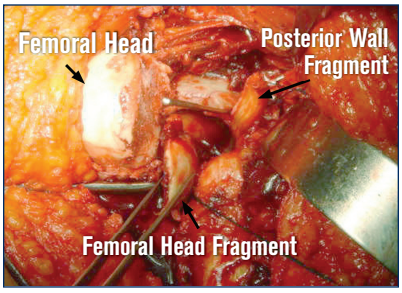

Figure 2: Intra-operative photograph demonstrating trochanteric flip osteotomy performed through a Kocher-Langenbeck approach and reduction of the femoral head and posterior wall acetabular fractures.

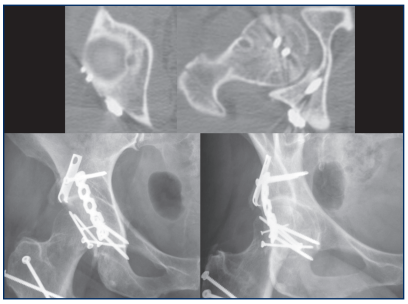

Figure 3 A-C: Postoperative axial CT images through the roof of the acetabulum and hip illustrating anatomical reduction and acceptable positioning of the hardware, and AP and Obturator Oblique radiographic pelvic views (counterclockwise from top) at six months following surgery reveal maintenance of fixation and joint space.

AUTHOR DISCLOSURES:

Dr. Helfet does have a financial interest or relationship with the manufacturers of products or services.

- Member, Board of Directors, Synthes

Dr. Jeffcoat does not have a financial interest or relationship with the manufacturers of products or services.

CASE REPORT: A 64-year-old female was on vacation in Nicaragua and was involved in a high-speed motor vehicle accident in a remote jungle. She and her husband were badly injured and taken by truck to a local hospital. Her injuries included a right posterior hip dislocation, femoral head fracture and posterior wall acetabular fracture (Figure 1 A-C). Fortuitously her husband had an international satellite phone and dialed the local 911 emergency response service, which then contacted the U.S. Embassy in Nicaragua who helped to locate and coordinate both triage and emergency medical evacuation to New York. She and her husband were transferred via medical flight to the care of Dr. David L. Helfet at Hospital for Special Surgery. Her hip dislocation was carefully reduced with a traction pin placed while in Nicaragua. Upon arrival at HSS, she received an Inferior Vena Cava (IVC) filter to protect her from pulmonary embolism. Open Reduction and Internal Fixation (ORIF) was later performed through a Kocher-Langenbeck approach with a trochanteric flip osteotomy and a surgical hip dislocation (Figure 2). The posterior wall acetabular fracture was reduced and fixed with two countersunk headless screws. The posterior wall fracture was reduced and fixed with a spring plate and a 5-hole pelvic reconstruction plate. The fractures and osteotomy site healed uneventfully. At her most recent follow-up six months following surgery, she has resolution of hip pain, full range of motion, and has resumed her pre-injury activities (Figure 3 A-C).

DISCUSSION: Fracture-dislocations of the hip that involve the femoral head and acetabulum (Pipkin IV fractures) are a rare injury that pose technical challenges to surgeons (1-3). The goal is anatomic reduction and rigid fixation of both fractures to allow for early motion. Traditional approaches to the fixation of posterior wall acetabular fractures do not allow adequate visualization of the femoral head. Conversely, femoral head fractures are best treated through an anterior approach. This dilemma formerly led to dual incisions or accepting suboptimal exposure. With the development of the trochanteric flip osteotomy and surgical dislocation, the femoral head is very well-visualized and proper screw trajectory is easier to achieve. Through this approach, one can also place allografts when significant impaction injuries are present in the femoral head (1). Since it is a variation of the traditional Kocher-Langenbeck approach, it also allows for fixation of posterior acetabular fractures.

Preservation of the blood supply to the femoral head is critical. To assure this, a "Z"-shaped capsulotomy is performed, and the short external rotators of the hip are preserved during the work on the femoral head (4). These protect the medial femoral circumflex artery from direct damage as well as avulsion during surgical dislocation. Following fixation of the femoral head fracture, the posterior wall can be reduced and plated as needed. As the trochanteric fragment retains its attachments to the abductors and vastus lateralis, it is less likely to displace and only requires fixation with two cortical screws. Patients are kept toe-touch weight-bearing for eight weeks and are able to begin immediate range of motion exercises. Though there is a relative paucity of outcome data for these rare injuries, multiple case series have demonstrated the utility of the surgical dislocation for their treatment.

This case demonstrates the importance of preparedness for both patient and surgeon. If the patient had not brought a satellite phone and had travel insurance, they would not have the means to arrange transport for definitive management of this complex injury. It also underscores the need for the surgeon treating these rare combination injuries to be familiar with "trochanteric flip" hip dislocation approaches and techniques of ORIF of complex fractures to allow for restoration of anatomy and function of the hip. The patient and her husband acquired a satellite phone and medical travel insurance prior to their trip; both proved to be "life savers."

REFERENCES:

1. Nousiainen MT, Sen MK, Mintz DN, Lorich D, Paul O, Buly RL, Helfet DL. The use of osteochondral allograft in the treatment of a severe femoral head fracture. *J. Orthop Trauma* 2010; 24:120-124.
2. Solberg BD, Moon CN, Franco DP. Use of a trochanteric flip osteotomy improves outcomes in Pipkin IV fractures. *Clin. Orthop* 2009; 467:929-933.
3. Gardner MJ, Suk M, Pearle A, Buly RL, Helfet DL, Lorich.D.G. Surgical dislocation of the hip for fractures of the femoral head. *J. Orthop Trauma* 2005; 19:334-342.
4. Ganz R, Gill TJ, Gautier E, Ganz K, Krugel N, Berlemann U. Surgical dislocation of the adult hip a technique with full access to the femoral head and acetabulum without the risk of avascular necrosis. *J Bone Joint Surg* Br 2001; 83:1119-1124.

CASE 3

Complex Limb Reconstruction Techniques

Case presented by Austin T. Fragomen, MD

Figure 1: A standing AP radiograph of both lower extremities shows a hypertrophic nonunion of the left femur with varus (16 degrees) and shortening (8.2 cm).

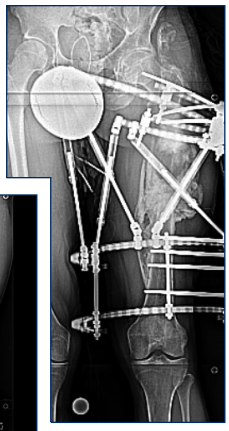

FIGURE 2

FIGURE 3

Figure 2: A later standing AP radiograph of both lower extremities showing the Ilizarov/Taylor spatial frame on the left femur. Most of the length is restored and the varus is corrected to a satisfactory position. Note the double rings on the proximal femur used to prevent ring deflection. Also note the bending of the proximal half pins.

Figure 3: A final standing AP radiograph of both lower extremities demonstrates equalization of limb length and full healing of the both the femur and tibia. The tibial nail was later removed.

CASE REPORT: A 38-year-old man was injured in a motor vehicle accident, sustaining a closed left femur fracture. This proximal third diaphyseal fracture was initially treated with an intramedullary (IM) nail in Nigeria. He went on to nonunion, the implant fractured, and it was removed. Without fixation, he developed a hypertrophic nonunion (Figure 1). After examination, the assessment was the following: left femur stiff, hypertrophic nonunion with varus alignment and shortening of 8 cm. There was no history of infection and preoperative lab work up was negative.

Complex management was needed to resolve the shortening, deformity and un-united bone: stiff, hypertrophic nonunions will undergo osteogenesis when placed under tension (1,2).

At surgery, a circular external fixator, the Taylor Spatial Frame (Smith and Nephew, Memphis, TN), was mounted to the left femur with a combination of 6 mm HA coated half pins and tensioned wires. No separate osteotomy was created and no bone graft was used. The patient adjusted the external fixator at 1mm per day to correct varus and lengthen through the nonunion site directly. The femur was lengthened 6 cm and the varus deformity corrected from 18 to 5 degrees. However, as the correction progressed, further adjustments became problematic. The patient's thick thigh muscles and stiff nonunion generated tremendous tension. As the struts pushed the rings apart, the proximal femoral ring bent considerably and crept into the patient's perineum where it began to cause pressure necrosis of the skin overlying the pubic symphysis.

Four months after placement of the circular fixator, the patient was taken back to the operating room for a fixator-assisted IM nailing. The half pins from the circular fixator that were in the path of the IM nail were removed. A temporary spanning external fixator was placed in two planes, and the circular frame was removed. The new half pins were inserted outside of the path of the IM canal to allow passage of the nail (3).

Over the next three months the femur went on to heal without any signs of infection. The patient still had a 2 cm leg length discrepancy, and a tibial lengthening was ultimately performed using the lengthening-over-nail technique(3).

One year after the final surgery, the patient is walking well without pain or a limp. He has no limb length inequality and no deformity (Figure 3). He has full knee and ankle motion and hopes to return to playing soccer.

DISCUSSION: The Ilizarov method is a set of principles that are particularly well-utilized for the treatment of nonunions, limb shortening and deformity correction. Gradual traction through an osteotomy or hypertrophic nonunion will stimulate osteogenesis (1). IM nailing after prolonged external fixation carries a high risk of infection in the tibia (4), but less is known about the femur. Lengthening Over a Nail (LON) and Lengthening and Then Nailing (LATN) techniques have been used to safely insert an IM implant into both the femur and tibia after extended time in an external fixator. This case illustrates insertion of an IM nail into the femur through previous pin sites that had been in place for 4 months without a latency period and without development of infection. Reasons for this success are thought to include the use of 6 mm HA coated half pins (which are less likely to loosen and get infected) and the placement of the fixator in a non-trauma, reconstructive setting where the patient's body was not going through a systemic inflammatory response. Additionally, the thick soft tissue envelope of the femur is presumed to help make deep infection less likely. We advocate the removal of the IM implant once the bone has healed in the event that there has been some subclinical contamination of the nail. Using combined internal and external fixation techniques most deformities can be corrected and limb length discrepancies equalized with a minimum amount of external fixation time. Ideally the external fixation should be placed with the intent of future internal fixation. This would require that pins and wires be placed away from the future site of the nail or plate. However, in some cases conversion to internal fixation can still be attempted when not part of the original plan.

REFERENCES:

1. Ilizarov GA. Transosseus osteosynthesis. Theoretical and clinical aspects of the regeneration and growth of tissue. (Ed) Green S. Springer-Verlag Berlin Heidelberg 1992:63-136
2. Rozbruch SR, Fragomen A, Ilizarov S. "Correction of tibial deformity with use of the Ilizarov/Taylor Spatial Frame". *JBJS-Am* 88-A 2006, Suppl. 4:156-174
3. Paley D, Herzenberg JE, Paremain G, Bhave A. Femoral lengthening over an intramedullary nail. A matched-case comparison with Ilizarov femoral lengthening. *J Bone Joint Surg* Am. 1997 Oct;79(10):1464-80
4. Bhandari M, Zlowodzki M, Tornetta P 3rd, Schmidt A, Templeman DC. Intramedullary nailing following external fixation in femoral and tibial shaft fractures. *J Orthop Trauma*. 2005 Feb;19(2):140-4.

AUTHOR DISCLOSURE:

Austin T. Fragomen, MD does have a financial interest or relationship with the manufacturers of products or services.

- Salary, royalty, or honoraria: SBI, Smith & Nephew, Biomet
- Consulting fees: SBI
- Institutional Education Support: SBI, Smith & Nephew, Biomet

CASE 4

Reverse Total Shoulder Prosthesis for the Treatment of a Four-part Proximal Humerus Fracture

Case presented by Edward V. Craig, MD, MPH, and Lawrence V. Gulotta, MD

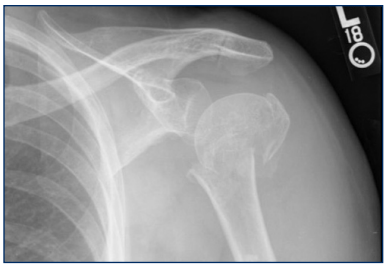

Figure 1: Radiograph at presentation showing a comminuted proximal humerus fracture with displaced humeral shaft.

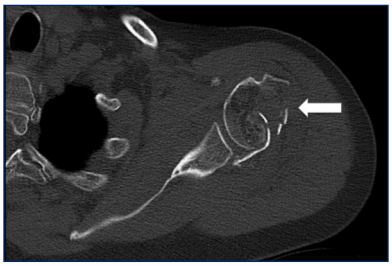

Figure 2: CT showing significant comminution of the greater tuberosity (arrow).

Figure 3: Modified Grashey AP radiograph at most recent follow-up.

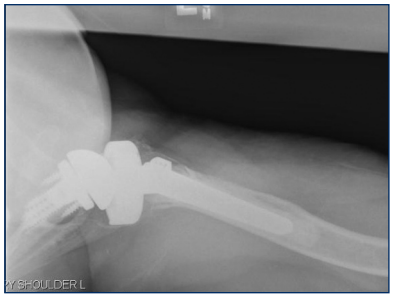

Figure 4: Axillary radiograph at most recent follow-up.

AUTHOR DISCLOSURES:
Dr. Craig is a co-developer of the reverse total shoulder prosthesis used in this case. He receives royalties for his intellectual property.
Dr. Gulotta does not have a financial interest or relationship with the manufacturers of products or services.

CASE REPORT: The patient is a 76-year-old, right hand dominant female who fell and sustained a left proximal humerus fracture. She presented to Hospital for Special Surgery where she reported a history of intermittant pain and weakness in the left shoulder prior to her injury. Her physical exam revealed acute pain, swelling and ecchymosis around the left shoulder with inability to elevate the arm. She was able to contract her deltoid muscle and had intact sensation in the axillary nerve distribution. Radiographs and CT scans revealed a four-part humerus fracture with significant comminution of the greater tuberosity.

The patient was offered and elected to proceed with prosthetic replacement of her shoulder. A standard deltopectoral approach was utilized and the greater and lesser tuberosities were identified and tagged. The articular surface of the humeral head was removed. Comminution of the greater tuberosity was confirmed, as was a large pre-existing rotator cuff tear with retraction and atrophy of the supraspinatus and infraspinatus muscles. Adequate teres minor and subscapularis tendons were present. There was minimal arthritis of the glenoid. A decision was made to proceed with a reverse total shoulder replacement (R-TSR). This was based on the intra-operative findings of comminution of the greater tuberosity, and the presence of a rotator cuff tear, both of which were suspected pre-operatively, but were confirmed intra-operatively. The glenosphere was implanted with a 10-degree cephalad tilt such that the inferior portion of the implant was level with the inferior aspect of the glenoid to avoid notching. A fracture stem was then cemented into the prepared humerus in 20 degrees of retroversion after the proper height of the prosthesis was determined with a trial. A standard humeral bearing was then placed after trialing had revealed the appropriate size. The remaining tuberosities were then bone grafted and repaired with a combination of sutures through the fin on the humeral implant, and through drill holes in the humeral shaft that had been made previously. The wound was then closed in layers over a drain.

She was placed in a shoulder immobilizer for 14 days. She then began gentle passive range of motion with a limit of 90 degrees of forward flexion in the plane of the scapula and 30 degrees of external rotation to protect the tuberosity repair. At six weeks, she began progressive active range of motion and strengthening exercises. At three months, she was pain-free and was using her arm for all activities of daily living. She had passive elevation to 120 and active elevation to 100. Overall, she was very satisfied with her result.

DISCUSSION: Hemiarthroplasty has traditionally been the treatment of choice for most four-part and head-splitting fractures of the proximal humerus. While this procedure reliably alleviates pain, it has mixed results in terms of function (5). The functional results following hemiarthroplasty are directly related to the ability of the tuberosities to heal following repair (5). When the tuberosities fail to heal, as is common in the setting of extensive comminution, the patient's rotator cuff is rendered useless and they have difficulty elevating their arm as they would with a massive rotator cuff tear.

R-TSA is an attractive option for patients with these fractures since elevation is dependent on the deltoid and not on the rotator cuff. With this prosthesis, the deltoid lever arm is maximized by medializing the center of rotation of the shoulder and by distalizing the deltoid insertion. Recent studies have shown consistently good functional results with the use of the R-TSR for the treatment of acute proximal humerus fractures, with active elevation averaging approximately 100 degrees (1). However, there is also a higher complication rate when compared to hemiarthroplasty (3). Complications include dislocation, infection and loosening of the implant.

Due to the higher complication rate, we do not recommend R-TSR for all fractures that require a prosthesis. At this time, the indications for a R-TSR over a hemiarthroplasty for the treatment of an acute fracture include patients with a physiologic age greater than 70 with a sedentary lifestyle, extensive comminution of the tuberosities in which fixation and healing are deemed unlikely, the presence of an irreparable rotator cuff tear, and significant glenoid arthritis.

Several technical pearls exist for this surgery. First, function of the deltoid muscle and axillary nerve must be confirmed pre-operatively, which can be difficult in the setting of an acute fracture. We suggest asking the patient to push their elbow posterior in order to test posterior deltoid contraction. Second, the humeral height must be carefully determined to avoid post-operative instability. This can be difficult to assess due to proximal bone loss. A reliable anatomic landmark is that the top of the prosthesis should be 5.6 cm from the top of the pectoralis major tendon (4). Third, the tuberosities must be repaired if possible since an intact teres minor and subscapularis will improve post-operative external and internal rotation and aid in stability (2).

In select patients, R-TSA can be an effective treatment for proximal humerus fractures.

References located on back page.

HOSPITAL
FOR
**SPECIAL
SURGERY**

535 East 70th Street
New York, NY 10021

NON-PROFIT ORG.
U.S. POSTAGE
PAID
NEW YORK, N.Y.
PERMIT NO. XX

Grand Rounds from HSS

MANAGEMENT OF COMPLEX CASES

CASE 1 CONTINUED

REFERENCES:

1. Delano P. J.: The pathogenesis of Charcot's joint. *Am. J. Rheumat.* 56:189, 1946.
2. Troyer J, Levine BR. Proximal tibia reconstruction with a porous tantalum cone in a patient with Charcot arthropathy. *Orthopedics.* 2009 May; 32(5):358.
3. Marmor L. The Marmor knee replacement. *Orthop Clin North Am* 1982; 13:55.
4. Ranawat CS, Shine JJ. Duo-condylar total knee arthroplasty. *Clin Orthop* 1973; 94:185.
5. Yoshino S, Fujimori J, Kajino A, et al. Total knee arthroplasty in Charcot's joint. *J Arthroplasty* 1993;8:335.
6. Bae DK, Song SJ, Yoon KH, Noh JH. Long-term outcome of total knee arthroplasty in Charcot joint: a 10- to 22-year follow-up. *J Arthroplasty.* 2009 Dec;24(8):1152-6.
7. Parvizi J, Marrs J, Morrey BF. Total knee arthroplasty for neuropathic(Charcot) joints. *Clin Orthop* 2003;416:145.
8. Kim YH, Kim JS, Oh SW. Total knee arthroplasty in neuropathic arthropathy. *J Bone Joint Surg* Br 2002;84:216

CASE 4 CONTINUED

REFERENCES:

1. Bufquin T, Hersan A, Hubert L, et al: Reverse shoulder arthroplasty for the treatment of three- and four-part fractures of the proximal humerus in the elderly: a prospective review of 43 cases with a short-term follow-up. *J Bone Joint Surg* Br 89(4): 516-520, 2007.
2. Edwards TB, Williams MD, Labriola JE, et al: Subscapularis insufficiency and the risk of shoulder dislocation after reverse shoulder arthroplasty. *J Shoulder Elbow Surg* 18(6): 892-896, 2009.
3. Gallinet D, Clappaz P, Garbuio P, et al: Three or four parts complex proximal humerus fractures: hemiarthroplasty versus reverse prosthesis: a comparative study of 40 cases. *Orthop Traumatol Surg Res* 95(1): 48-55, 2009.
4. Murachovsky J, Ikemoto RY, Nascimento LG, et al: Pectoralis major tendon reference (PMT): a new method for accurate restoration of humeral length with hemiarthroplasty for fracture. *J Shoulder Elbow Surg* 15(6): 675-678, 2006.
5. Nijs S, Broos P: Outcome of shoulder hemiarthroplasty in acute proximal humeral fractures: a frustrating meta-analysis experience. *Acta Orthop Belg* 75(4): 445-451, 2009.

Issues of Grand Rounds from HSS/Management of Complex Cases are also available online at www.hss.edu/complexcases.

Here you will be able to take a look at the imagery from each case in greater detail and download archived issues.

We welcome your feedback and comments at complexcases@hss.edu.

DESIGN/PRODUCTION:
Marcia Ennis | Director, Education Publications & Communications

Grand Rounds from HSS Management of Complex Cases Editorial Board

EDITOR

Edward C. Jones, MD, MA
Assistant Attending Orthopaedic Surgeon
Hospital for Special Surgery
Assistant Professor of Orthopaedic Surgery
Weill Cornell Medical College

BOARD

Friedrich Boettner, MD
Assistant Attending Orthopaedic Surgeon
Hospital for Special Surgery
Assistant Professor of Orthopaedic Surgery
Weill Cornell Medical College

Alexander P. Hughes, MD
Assistant Attending Orthopaedic Surgeon
Hospital for Special Surgery
Assistant Professor of Orthopaedic Surgery
Weill Cornell Medical College

Robert G. Marx, MD, MSc, FRCSC
Attending Orthopaedic Surgeon
Hospital for Special Surgery
Professor of Orthopaedic Surgery
Weill Cornell Medical College

Helene Pavlov, MD, FACR
Radiologist-in-Chief, Radiology and Imaging
Attending Radiologist
Hospital for Special Surgery
Professor of Radiology
Weill Cornell Medical College

Laura Robbins, DSW
Senior Vice President, Education & Academic Affairs
Hospital for Special Surgery
Associate Professor, Graduate School of Medical Sciences, Clinical Epidemiology and Health Services Research
Weill Cornell Medical College

Thomas P. Sculco, MD
Surgeon-in-Chief and Medical Director
Korein-Wilson Professor of Orthopedic Surgery
Hospital for Special Surgery
Professor of Orthopaedic Surgery
Weill Cornell Medical College

All rights reserved. ©2010 Hospital for Special Surgery | Education Publications & Communications
Hospital for Special Surgery is an affiliate of NewYork-Presbyterian Healthcare System and Weill Cornell Medical College.