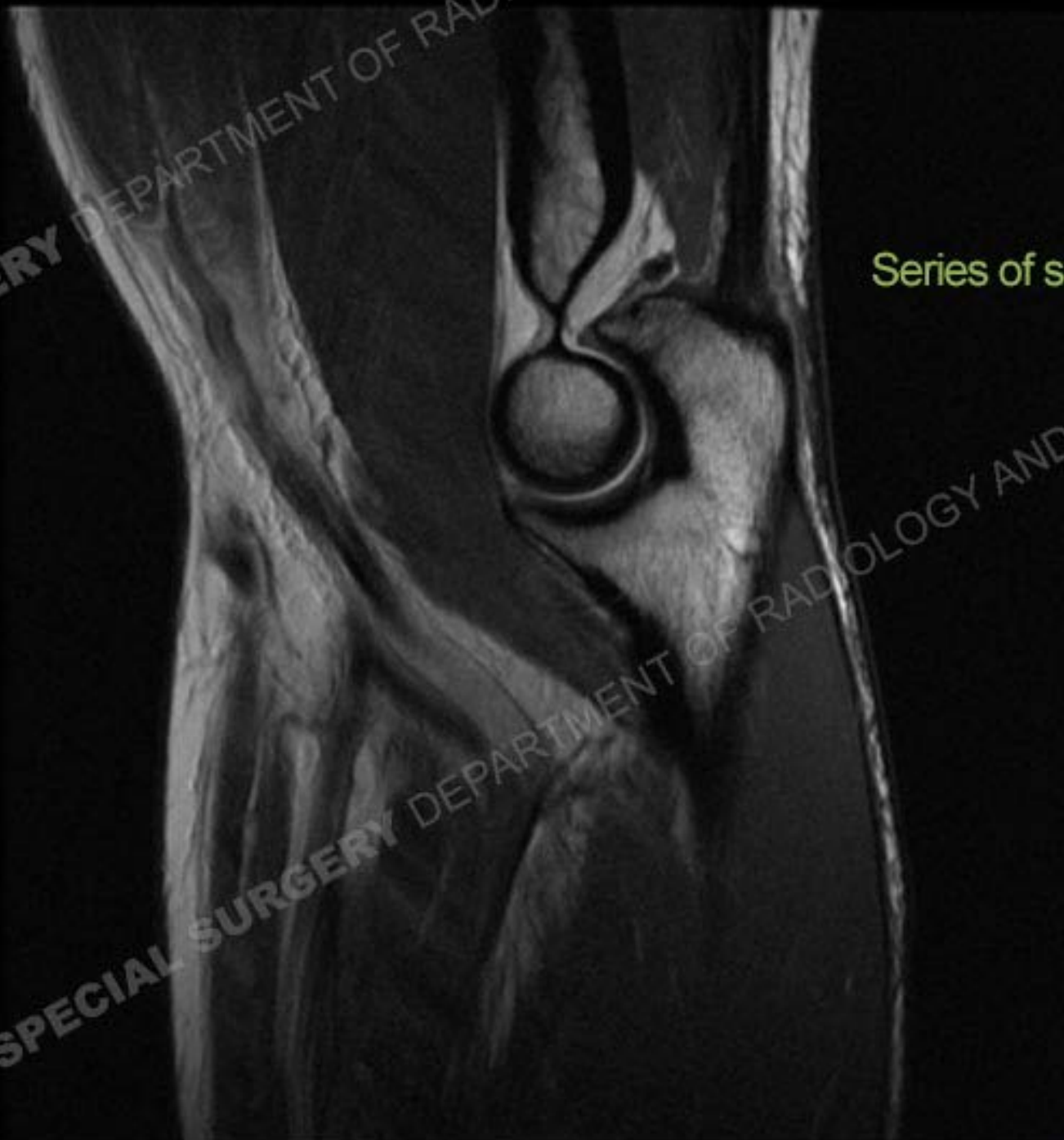
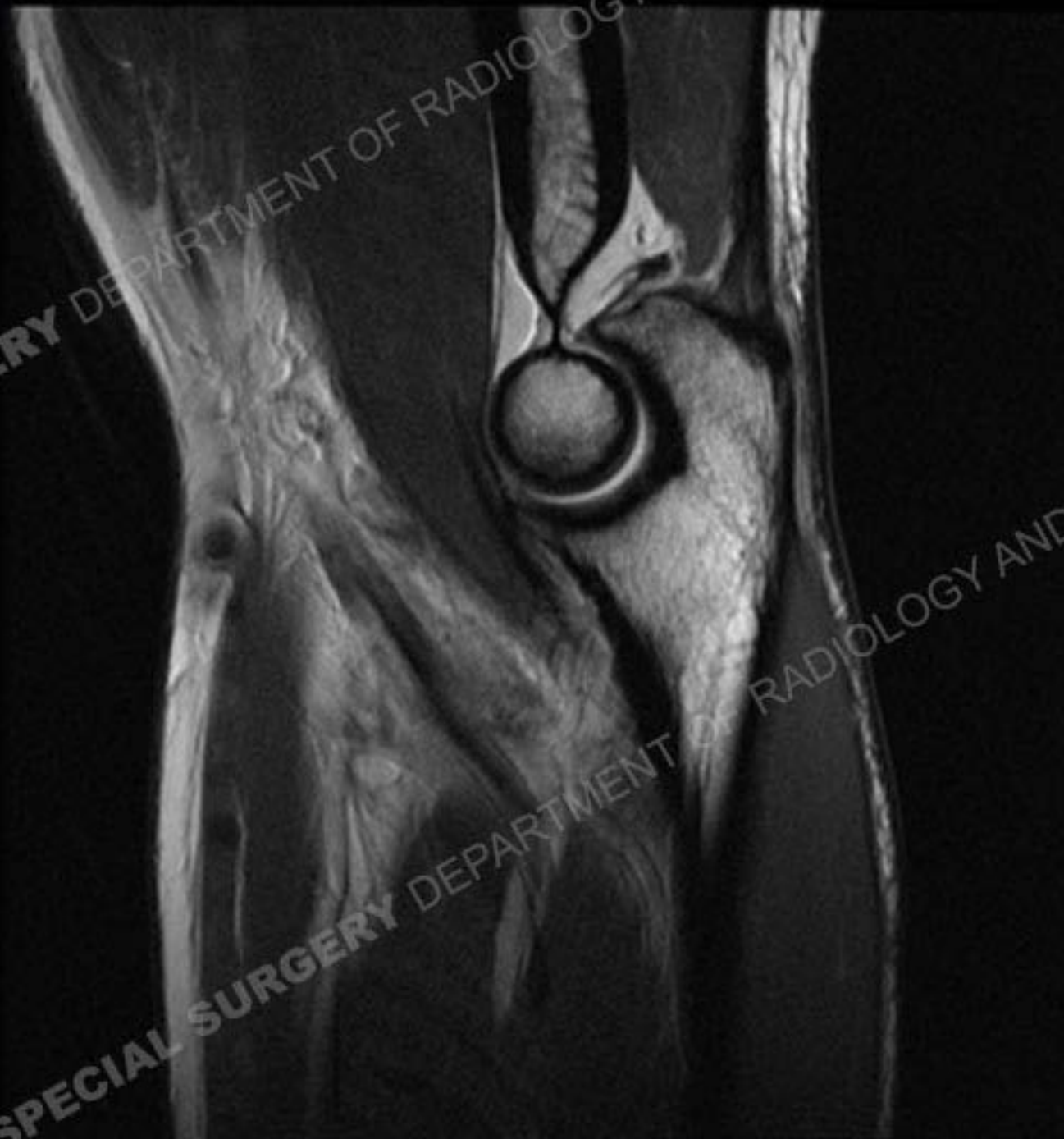


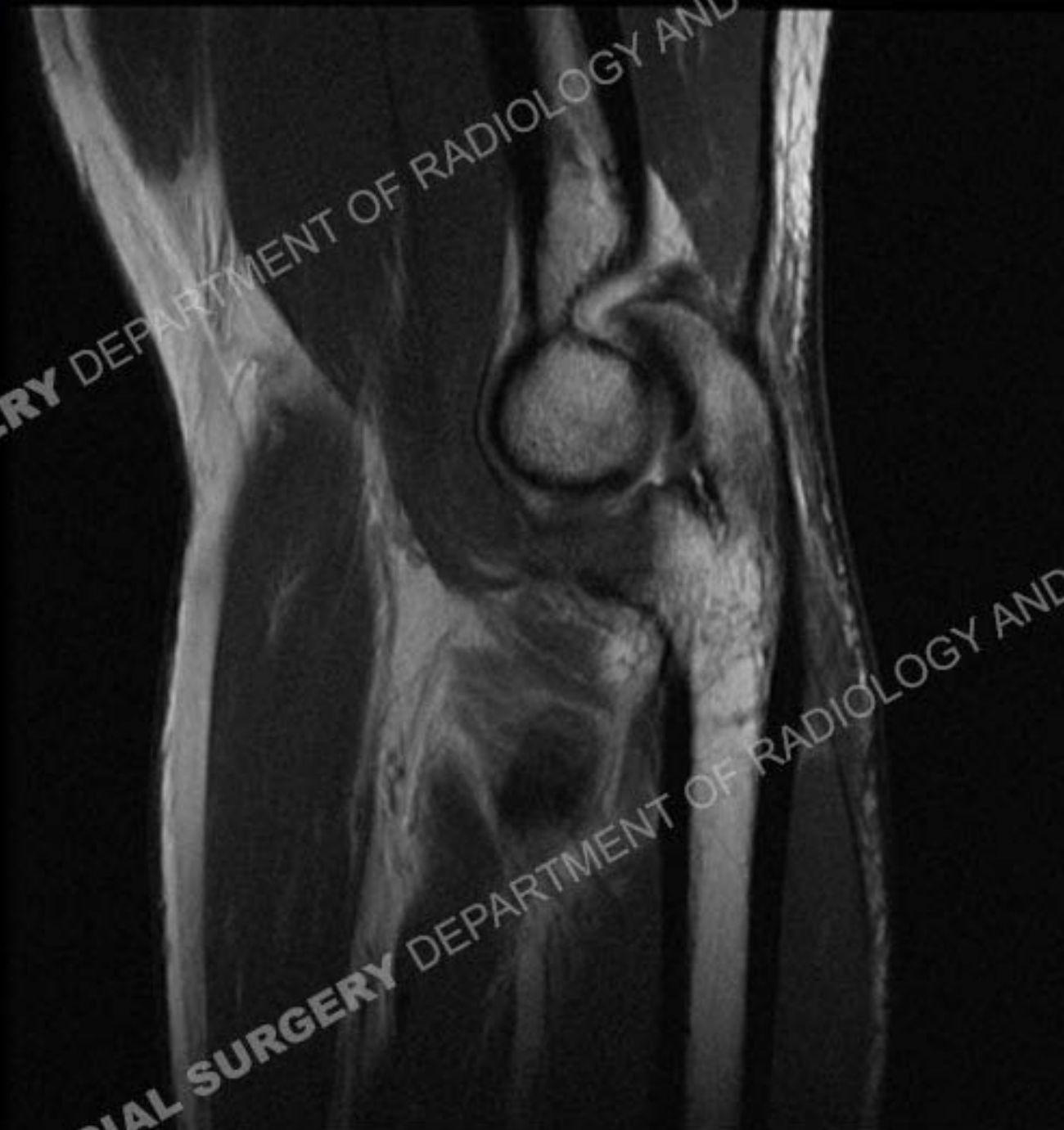Series of sagittal PD images

Series: 6  
Image no: 12  
Image 12 of 26

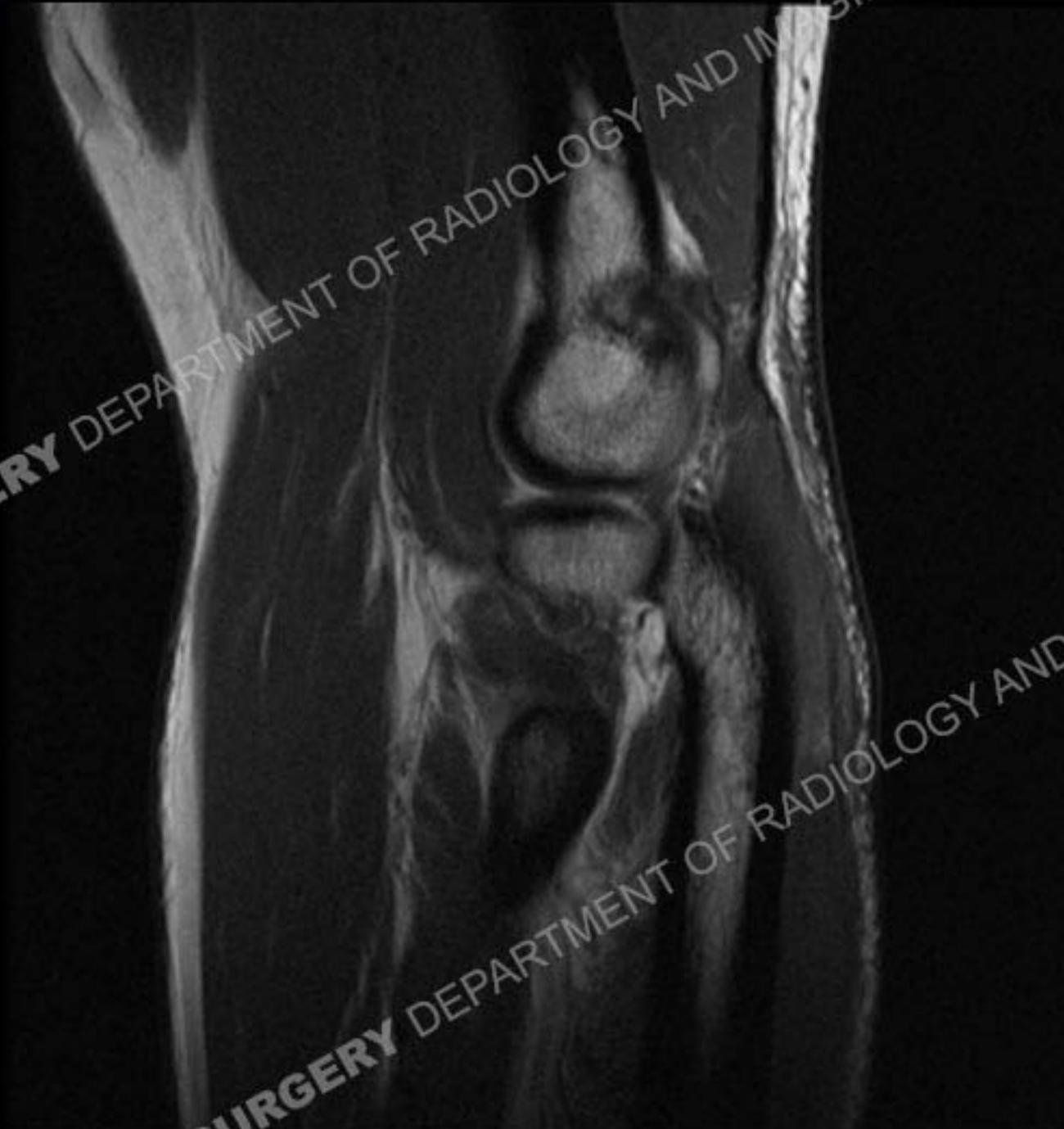**History:** 43 year old man with elbow pain after working out



Series: 6  
Image no: 13  
Image 13 of 26



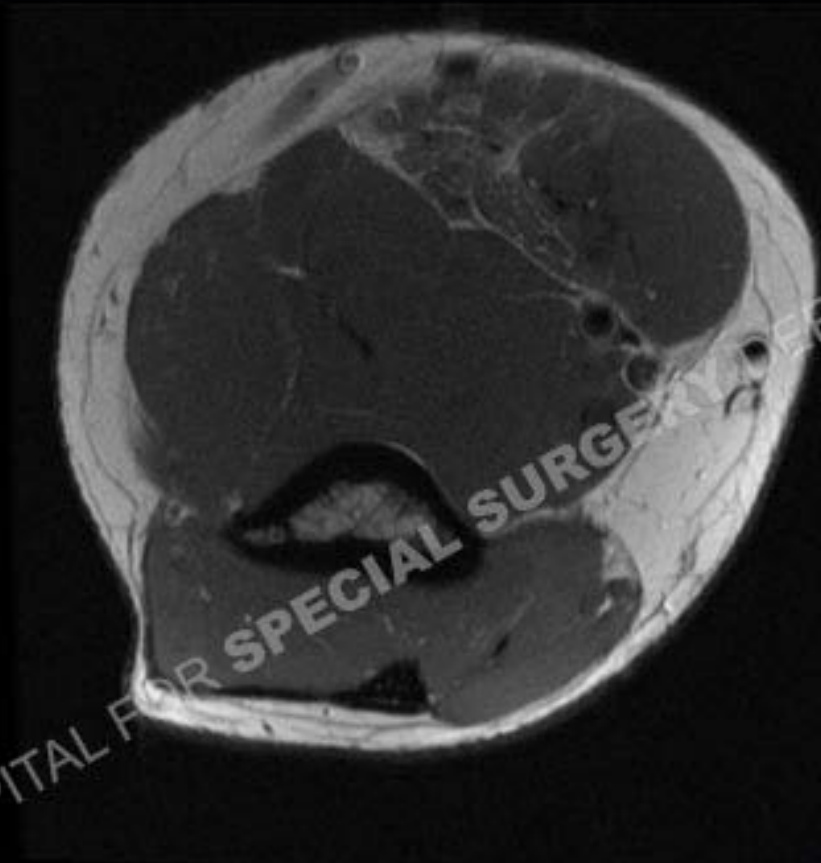
Series: 6  
Image no: 15  
Image 15 of 26



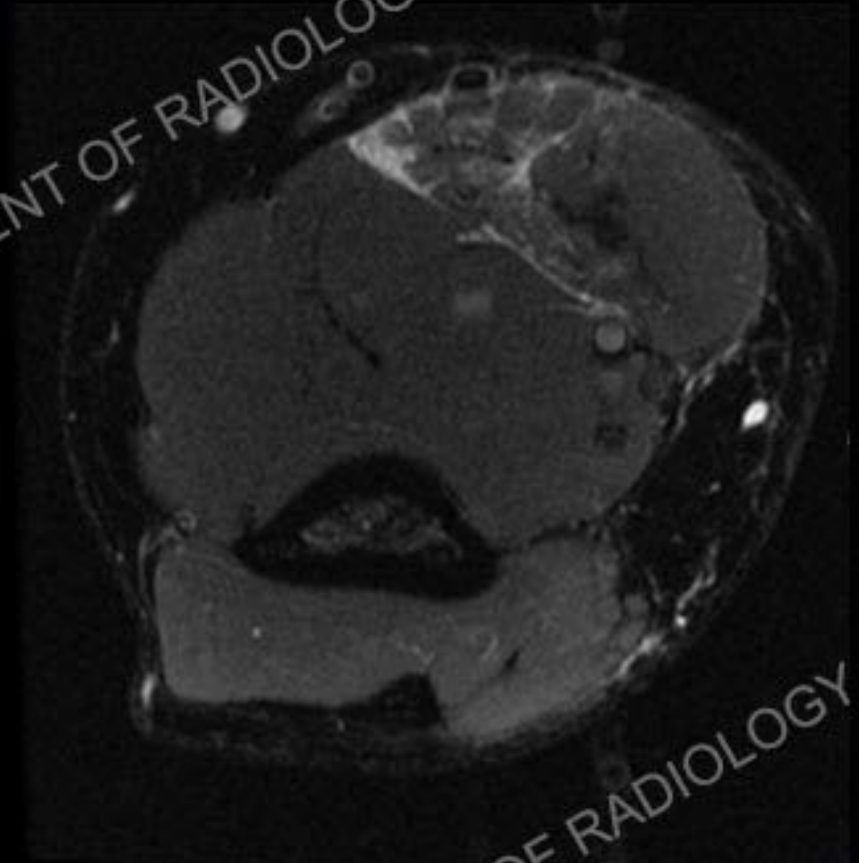
Series: 6  
Image no: 16  
Image 16 of 26



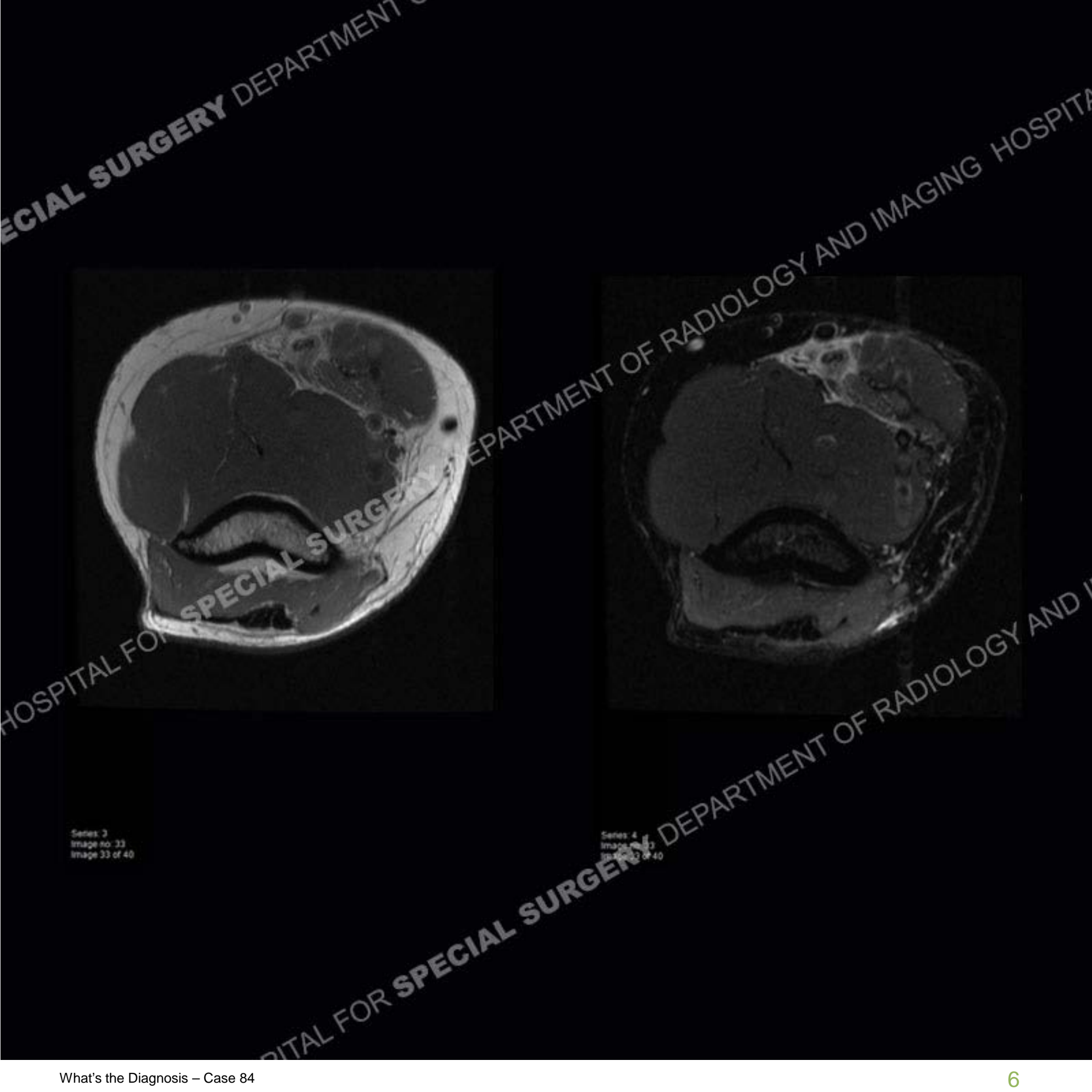
## Series of Axial PD and IR images



Series: 3  
Image no: 36  
Image 36 of 40

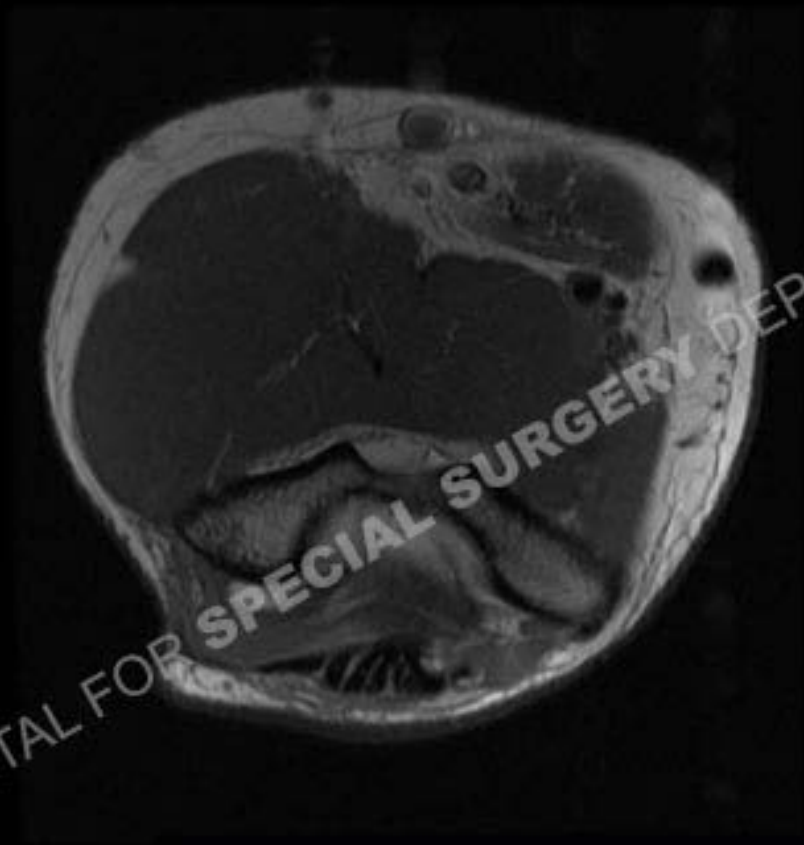


Series: 3  
Image no: 36  
Image 36 of 40

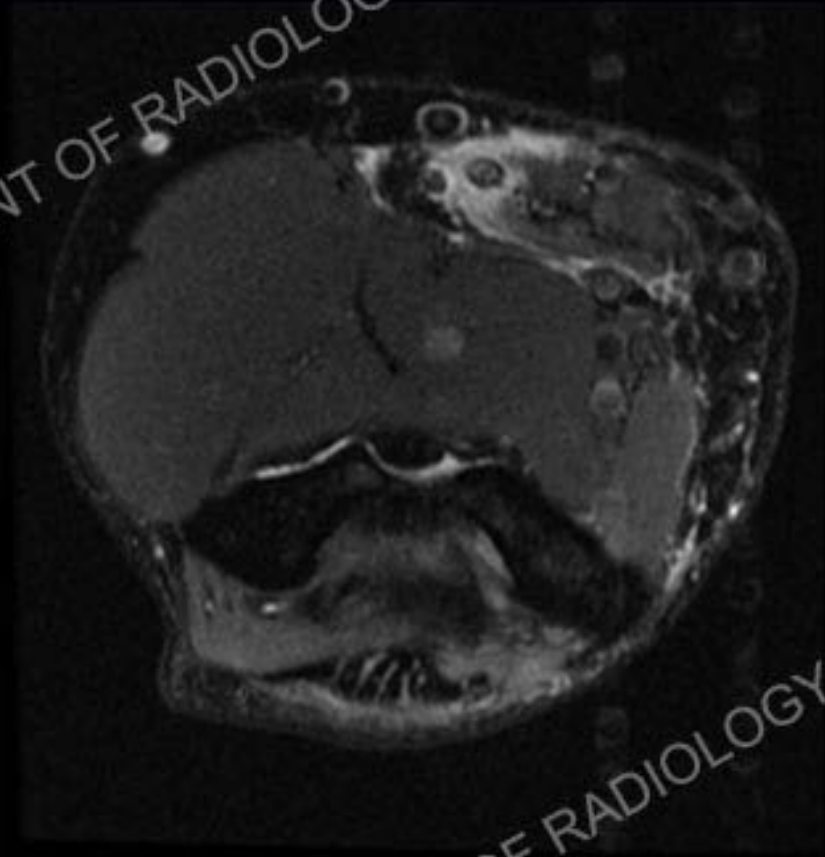


SPECIAL SURGERY DEPARTMENT

HOSPITAL FOR SPECIAL SURGERY DEPARTMENT OF RADIOLOGY AND IMAGING HOSPITAL

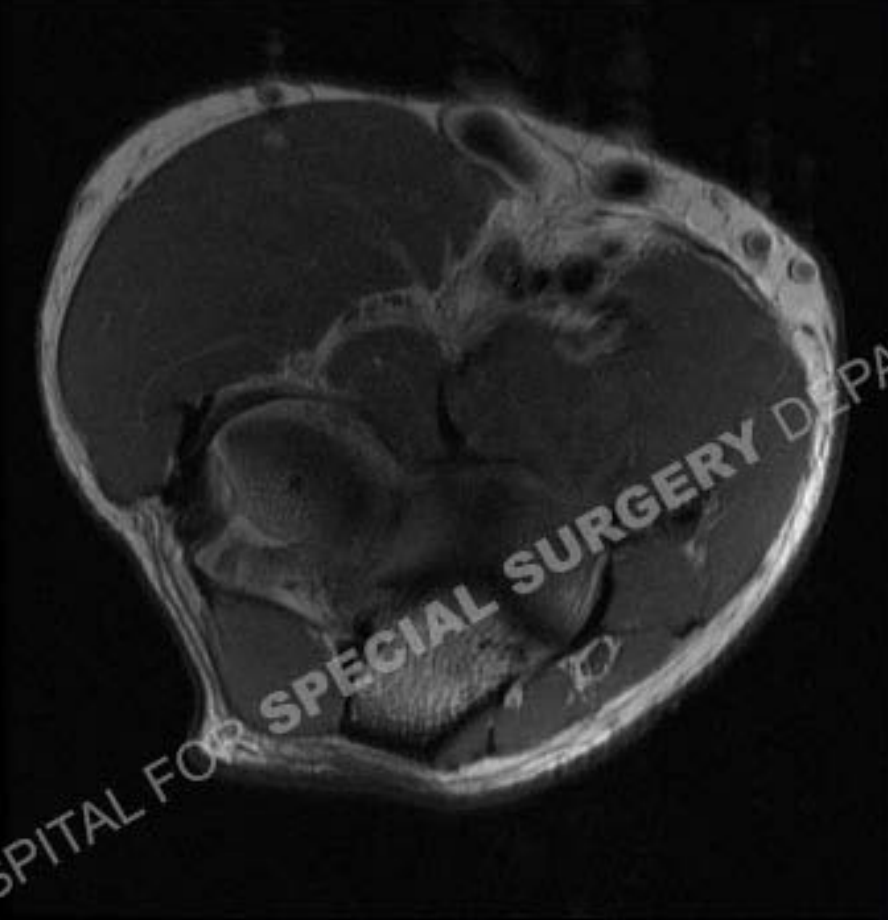

Series: 3  
Image no: 30  
Image 30 of 40

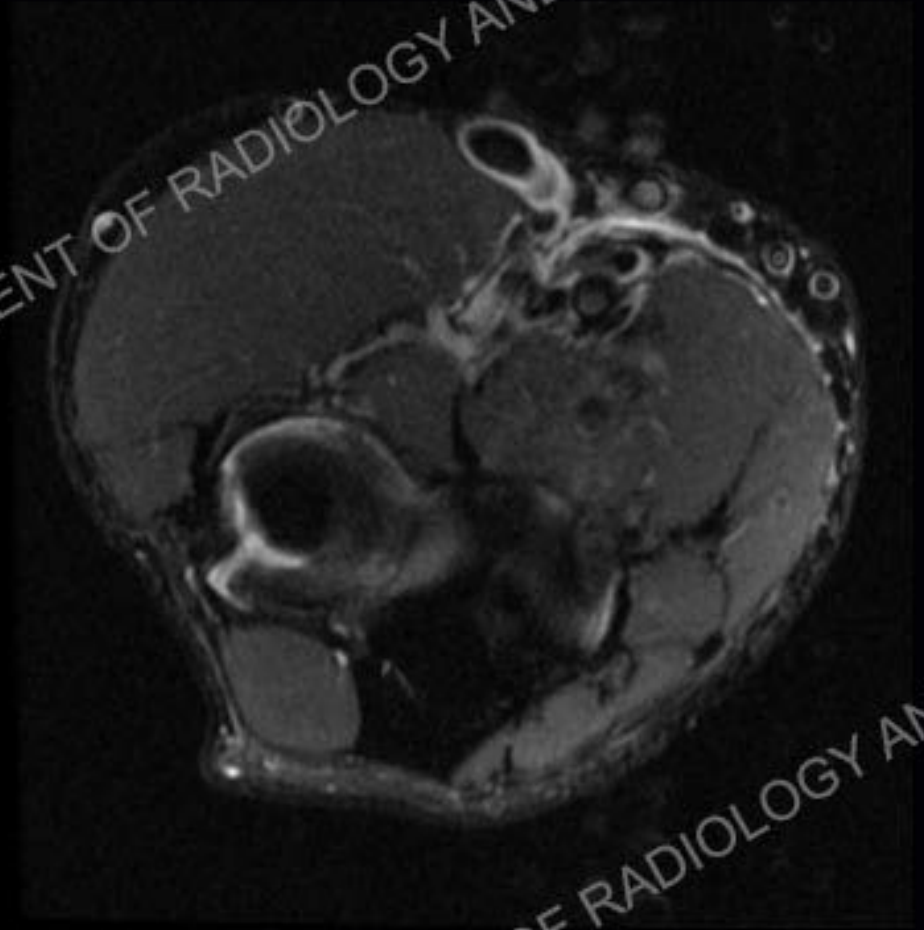


Series: 4  
Image no: 30  
Image 30 of 40

HOSPITAL FOR SPECIAL SURGERY DEPARTMENT OF RADIOLOGY AND IMAGING HOSPITAL



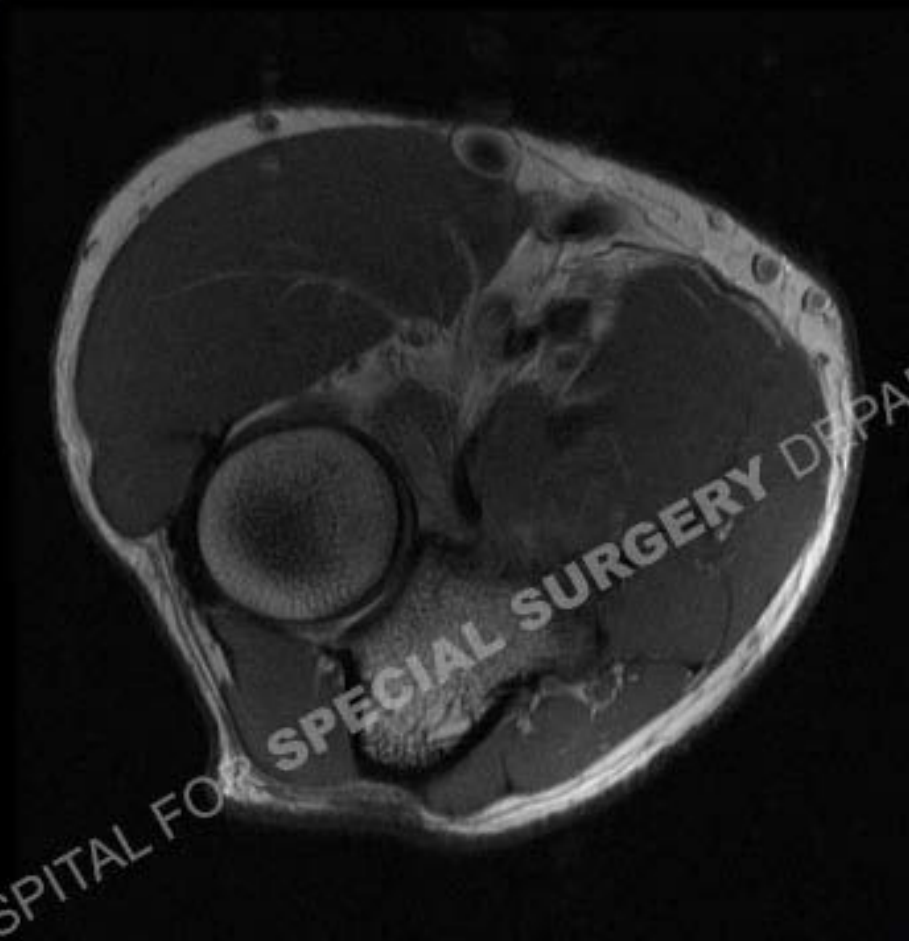Series: 3  
Image no: 22  
Image 22 of 40



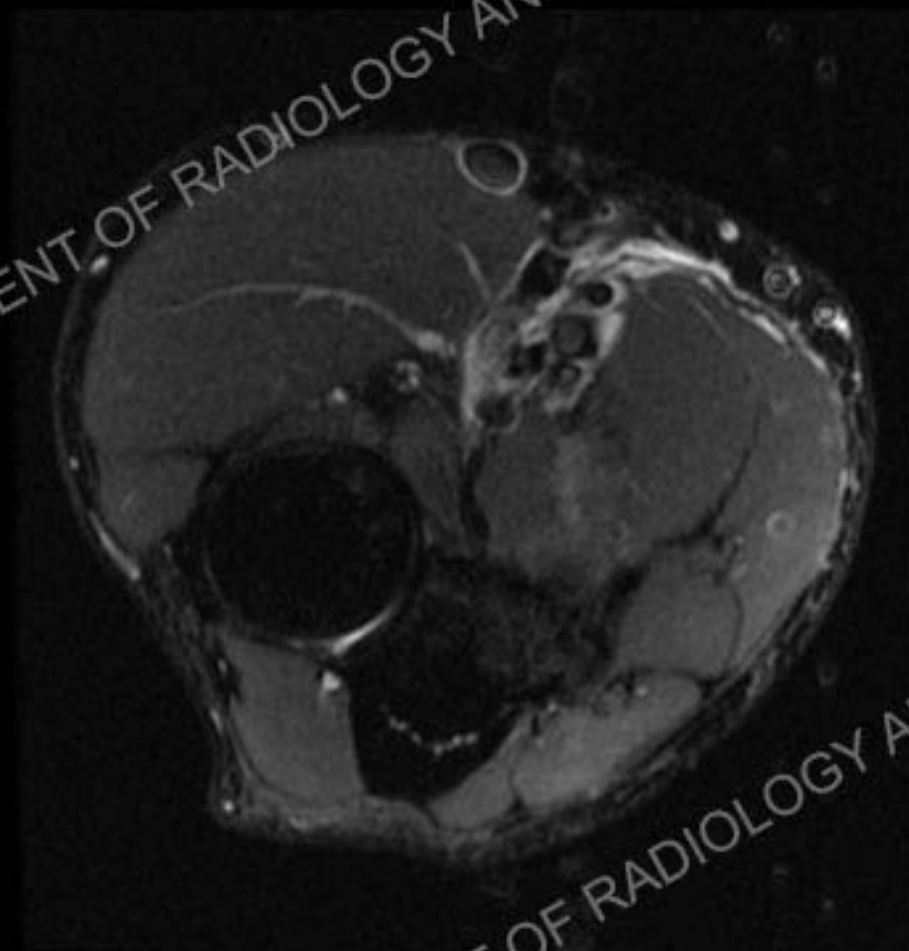
Series: 4  
Image no: 22  
Image 22 of 40



SPECIAL SURGERY DEPARTMENT



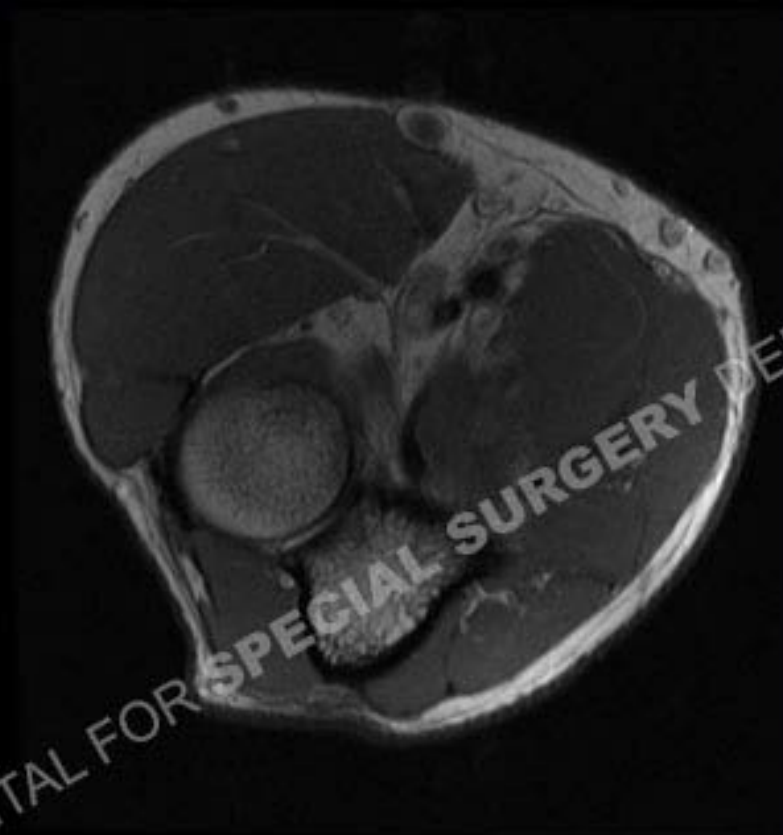Series: 3  
Image no: 20  
Image 20 of 40



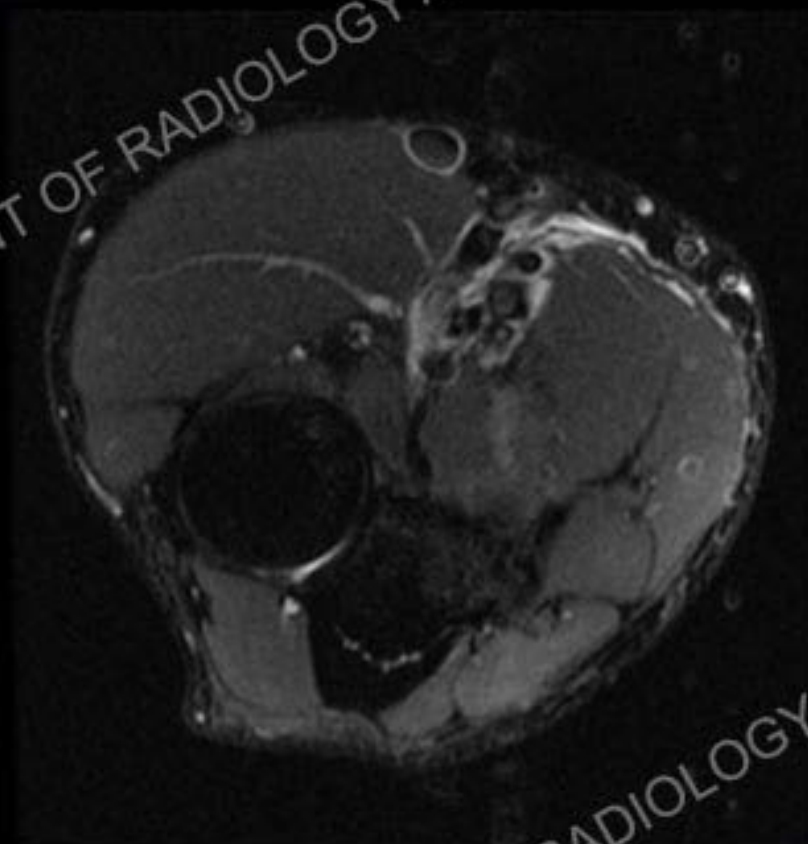
Series: 4  
Image no: 20  
Image 20 of 40

HOSPITAL FOR SPECIAL SURGERY DEPARTMENT OF RADIOLOGY AND IMAGING HOSPITAL

SPECIAL SURGERY DEPARTMENT



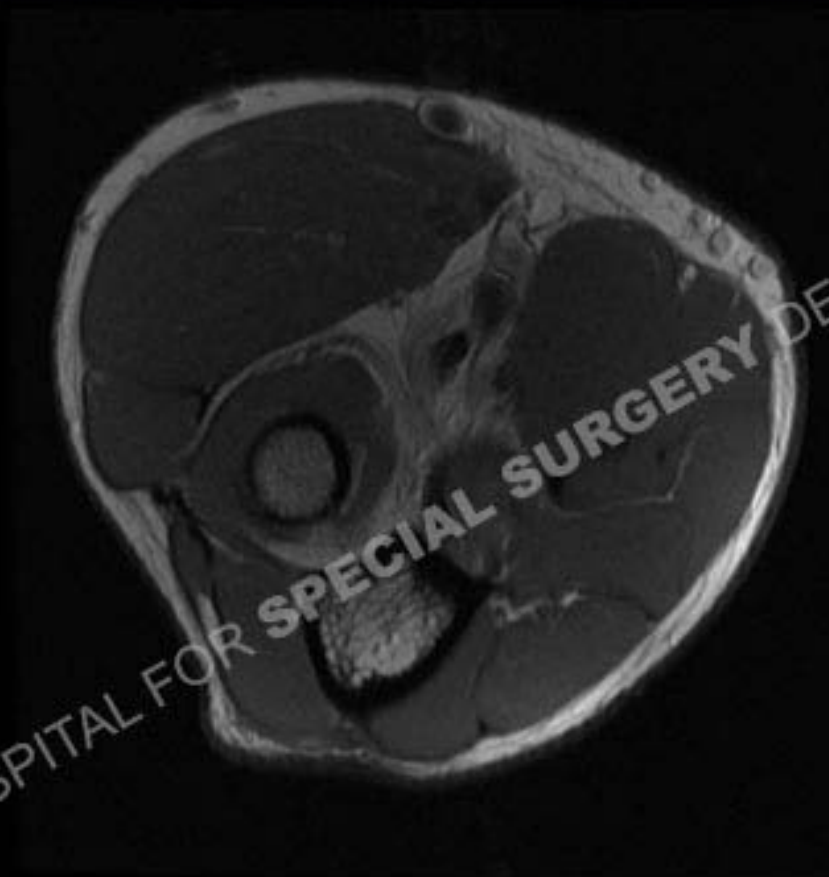
Series: 3  
Image no: 19  
Image 19 of 40



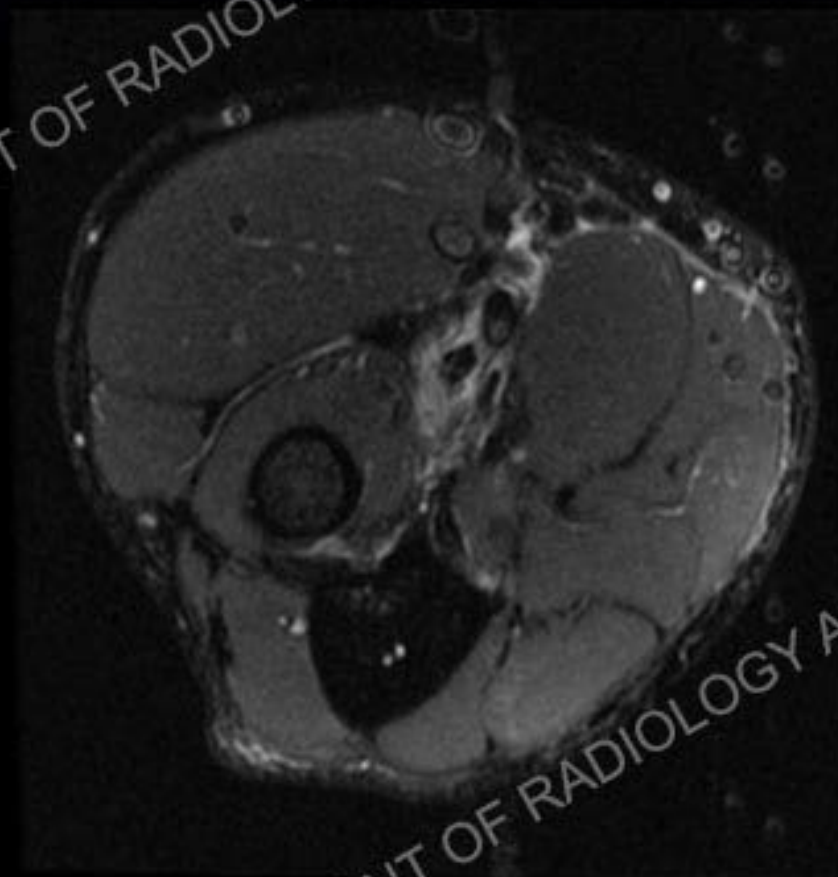
Series: 4  
Image no: 20  
Image 20 of 40

HOSPITAL FOR SPECIAL SURGERY DEPARTMENT OF RADIOLOGY AND IMAGING HOSPITAL

SPECIAL SURGERY DEPARTMENT OF RADIOLOGY AND IMAGING HOSPITAL FOR SPECIAL SURGERY

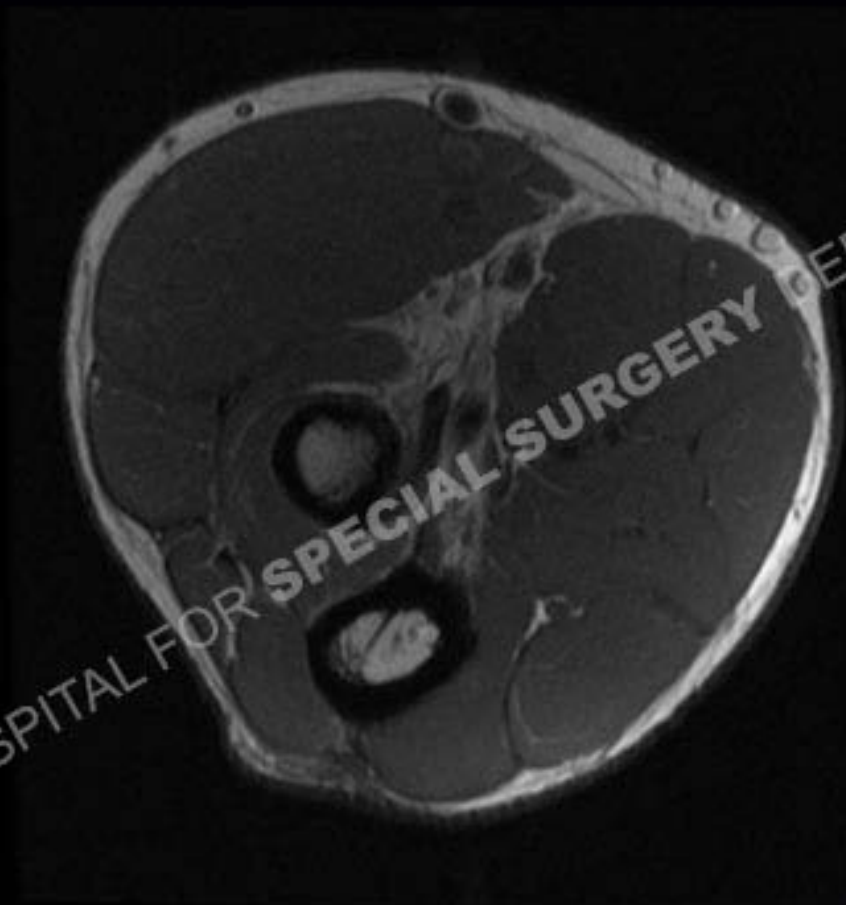

Series: 3  
Image no: 17  
Image 17 of 40

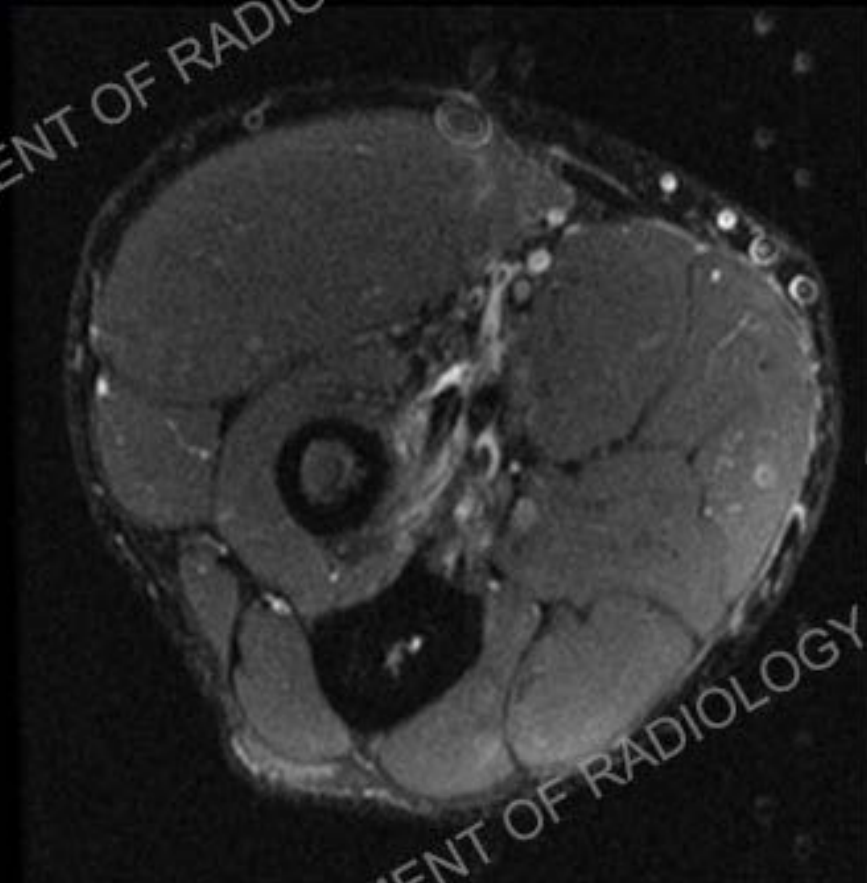


Series: 4  
Image no: 17  
Image 17 of 40

SPECIAL SURGERY DEPARTMENT OF RADIOLOGY AND IMAGING HOSPITAL FOR SPECIAL SURGERY



Series: 3  
Image no: 13  
Image 13 of 41



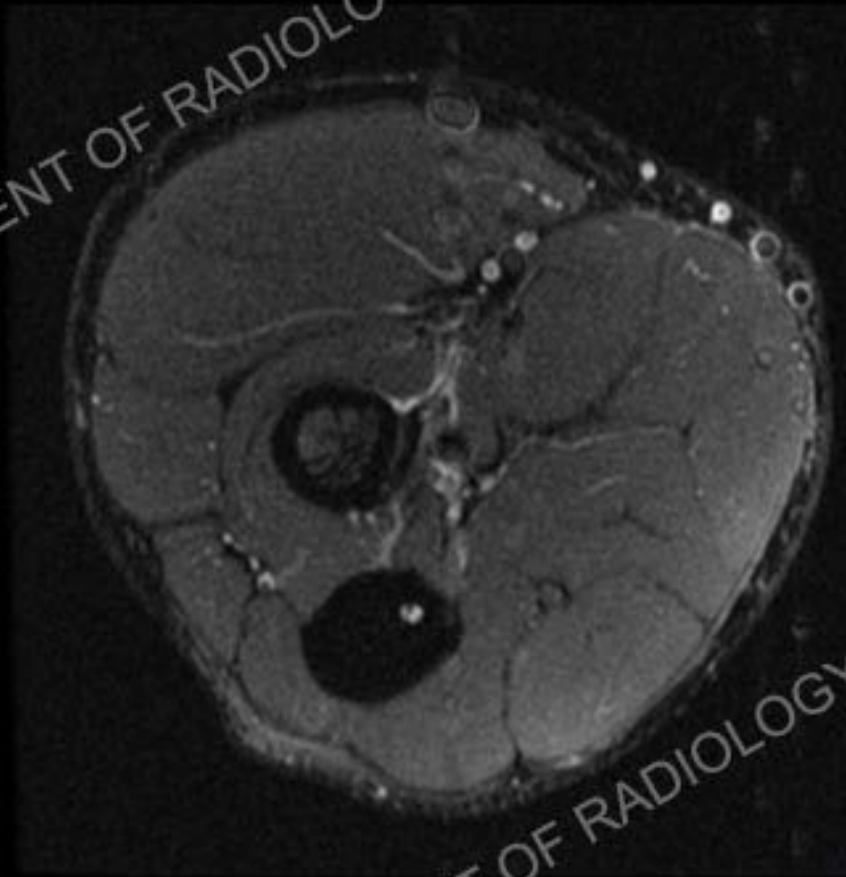
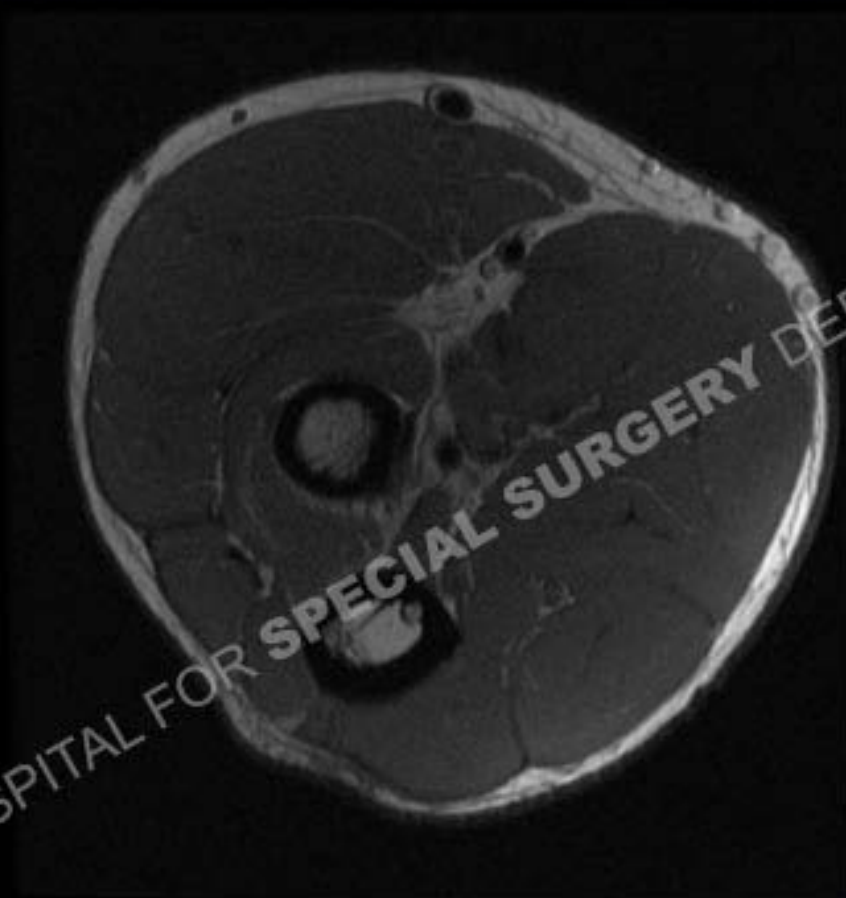Series: 4  
Image no: 14  
Image 14 of 40

HOSPITAL FOR SPECIAL SURGERY DEPARTMENT OF RADIOLOGY AND IMAGING HOSPITAL



SPECIAL SURGERY DEPARTMENT

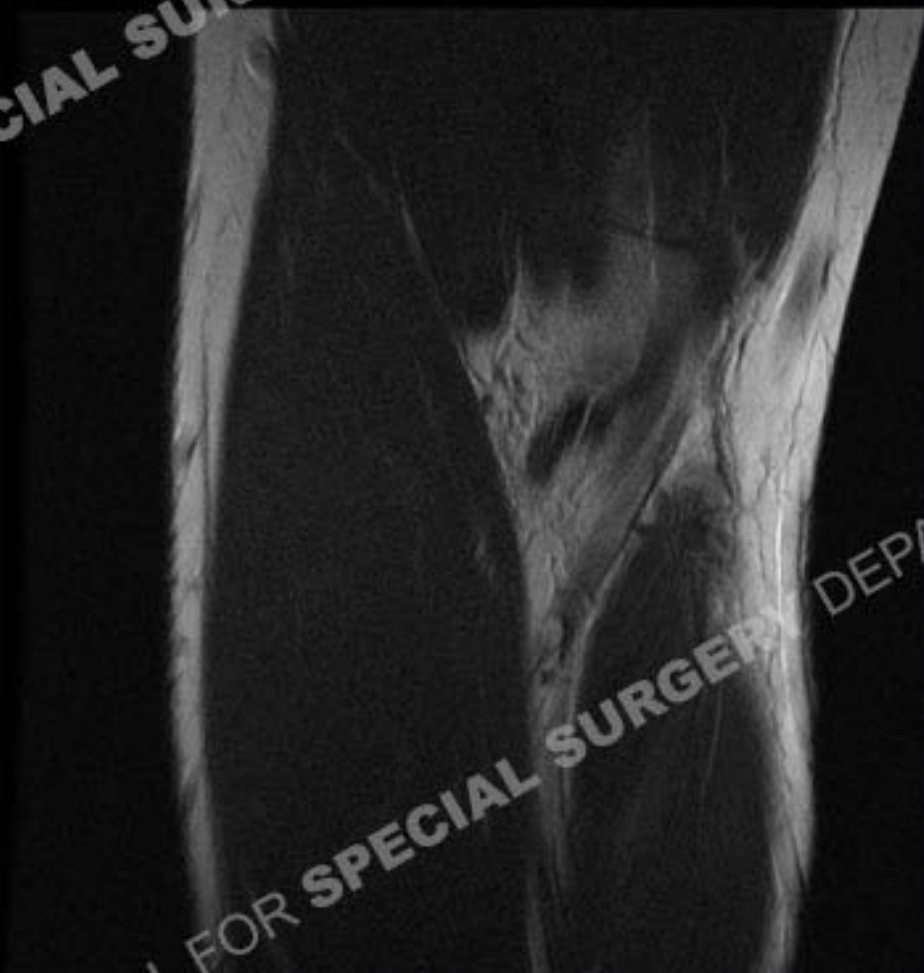DEPARTMENT OF RADIOLOGY AND IMAGING HOSPITAL



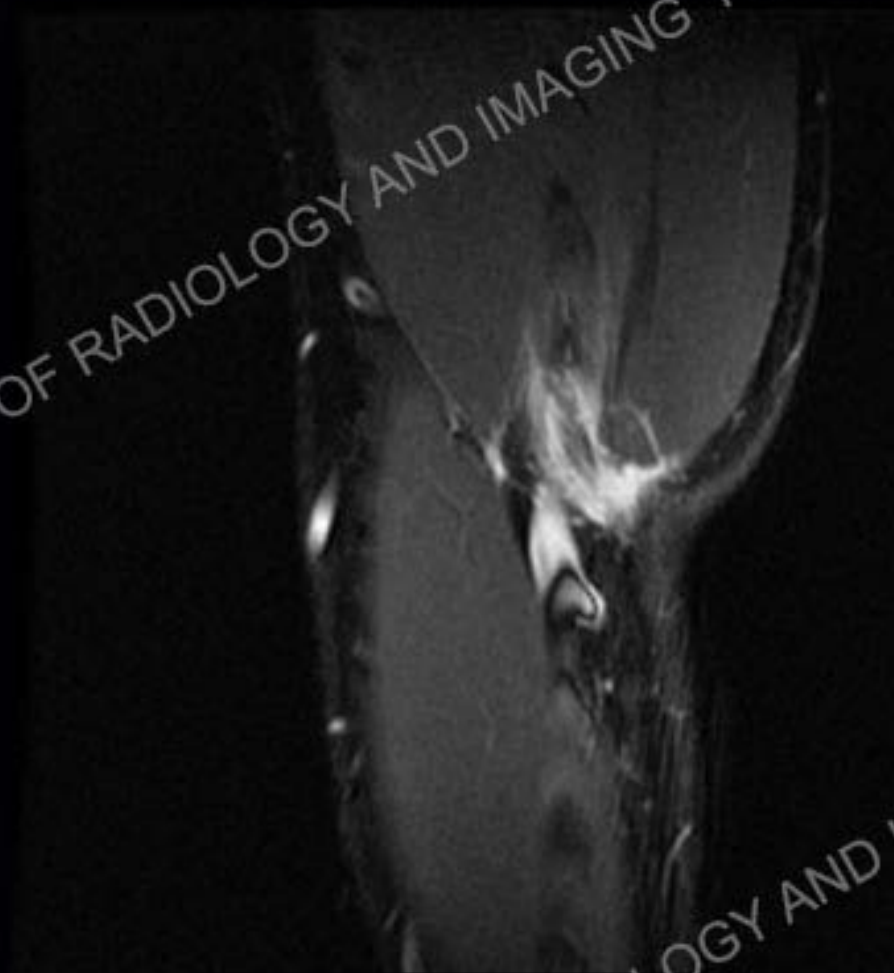
Series: 3  
Image no: 10  
Image 10 of 40

Series: 3  
Image no: 11  
Image 11 of 40

HOSPITAL FOR SPECIAL SURGERY DEPARTMENT OF RADIOLOGY AND IMAGING HOSPITAL

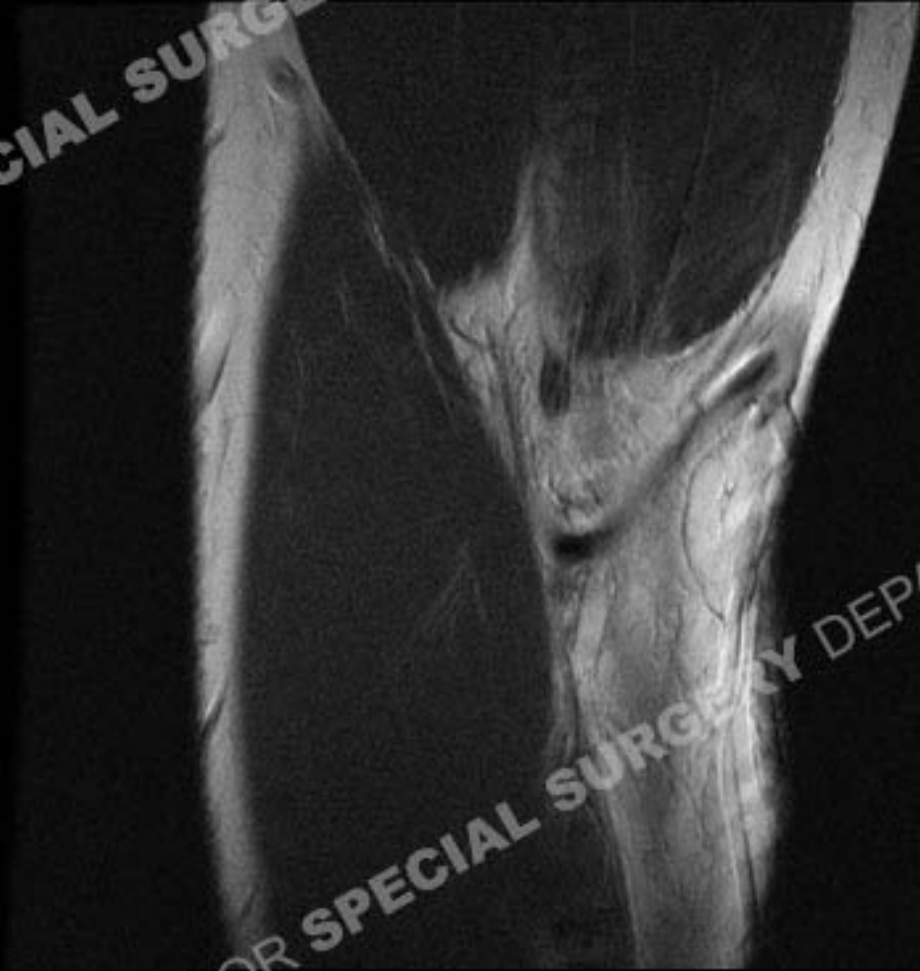

Series: 5  
Image no: 28  
Image 28 of 30

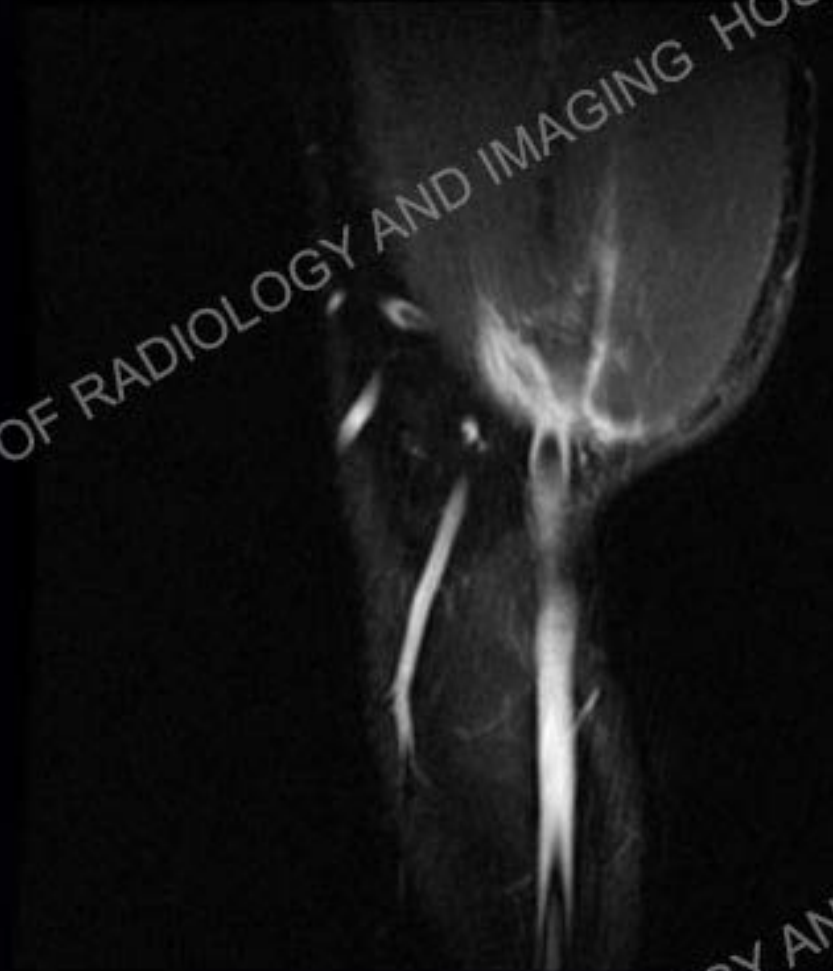


Series: 2  
Image no: 28  
Image 28 of 30

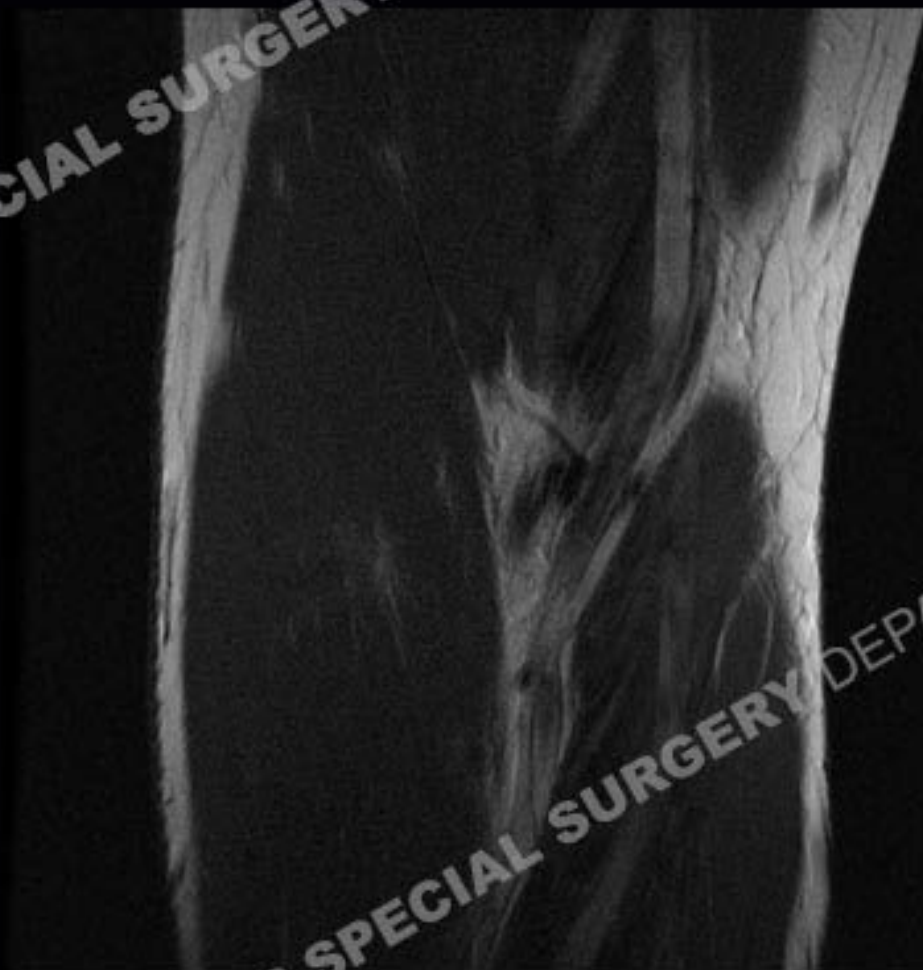## Coronal PD and IR images



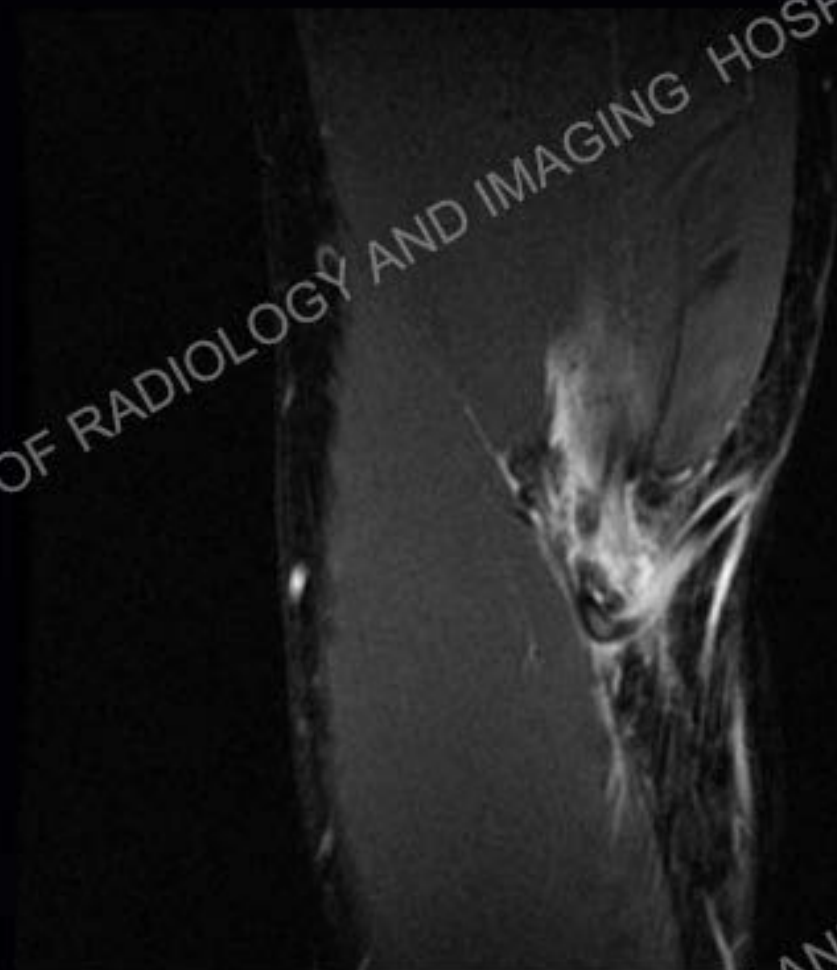
Series: 5  
Image no: 30  
Image 30 of 30



Series: 2  
Image no: 30  
Image 30 of 30

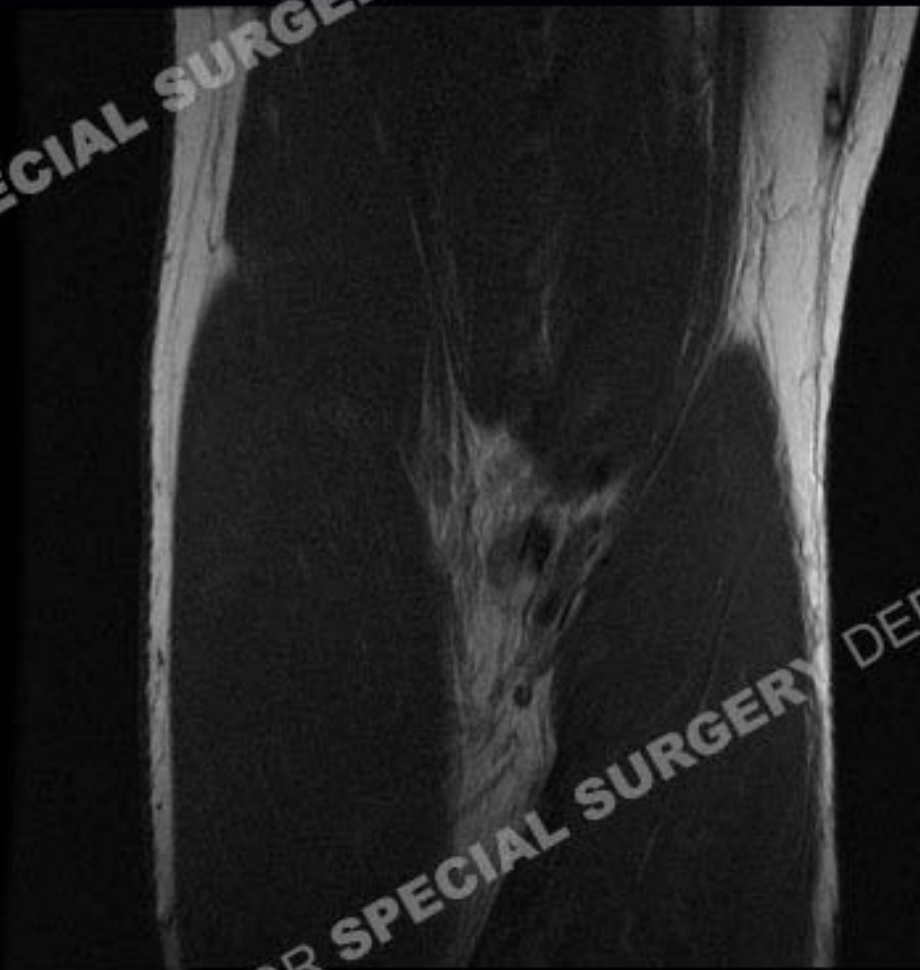

Series: 5  
Image no: 26  
Image 26 of 30

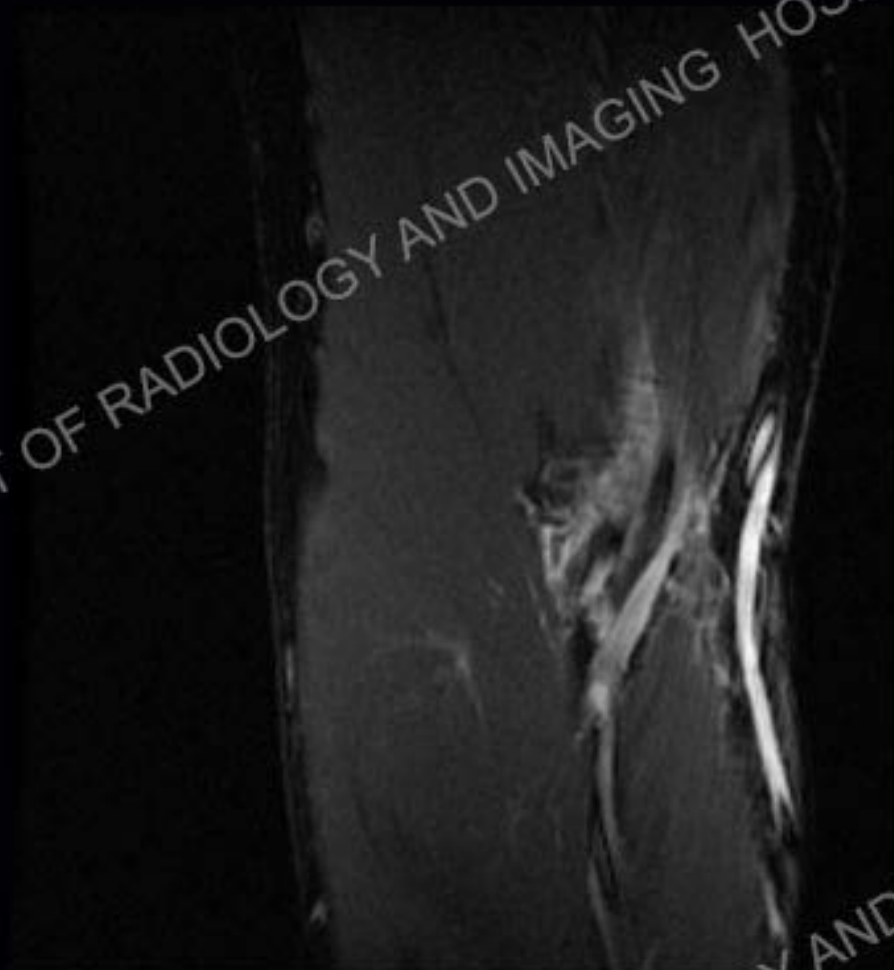


Series: 2  
Image no: 26  
Image 26 of 30

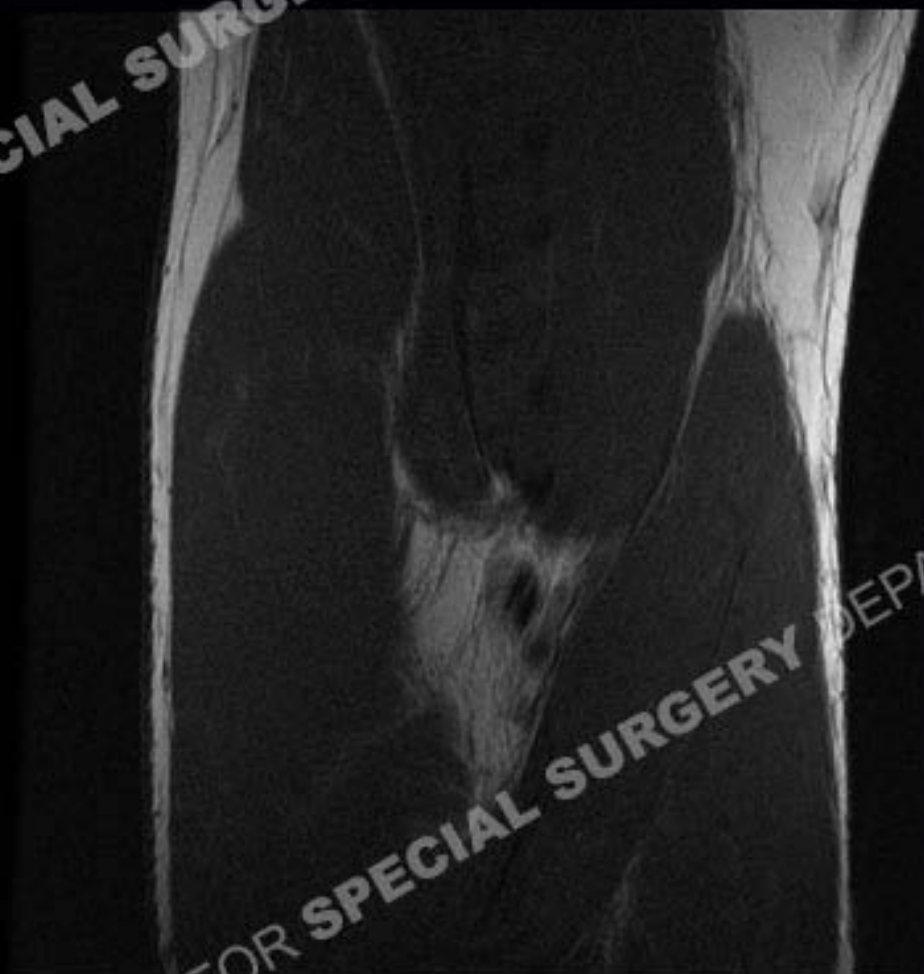



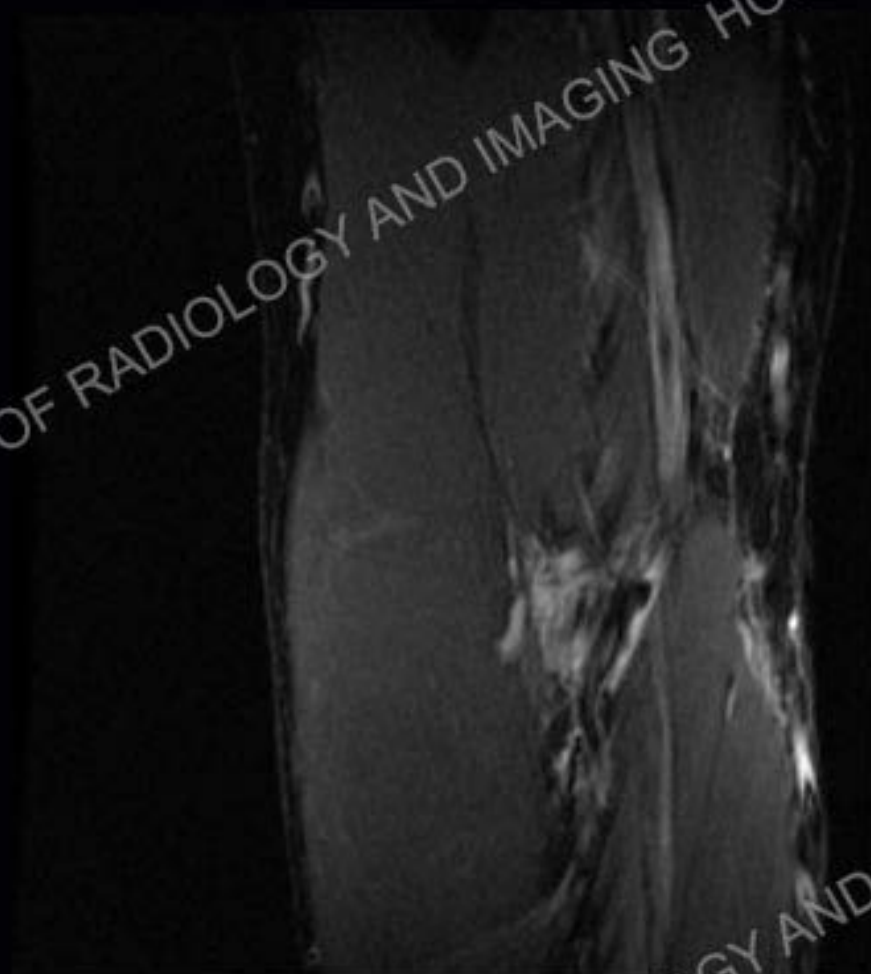
Series: 5  
Image no: 24  
Image 24 of 30



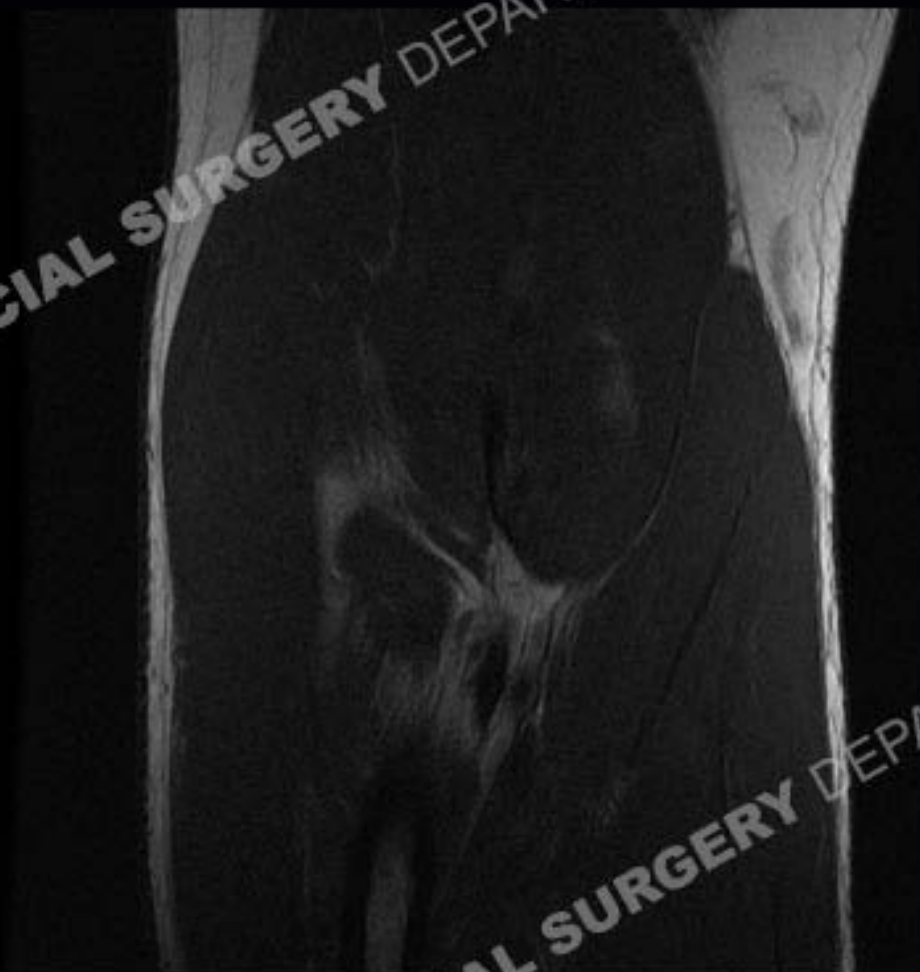Series: 2  
Image no: 24  
Image 24 of 30



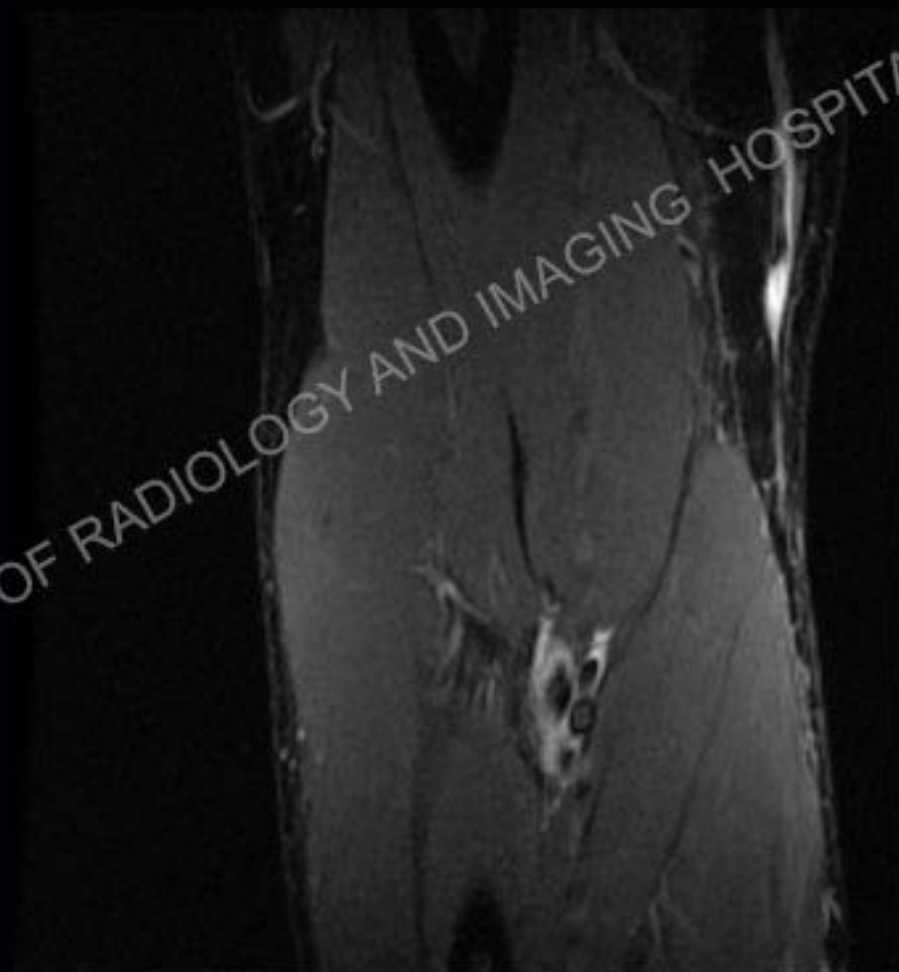
Series: 5  
Image no: 22  
Image 22 of 30



Series: 2  
Image no: 22  
Image 22 of 30

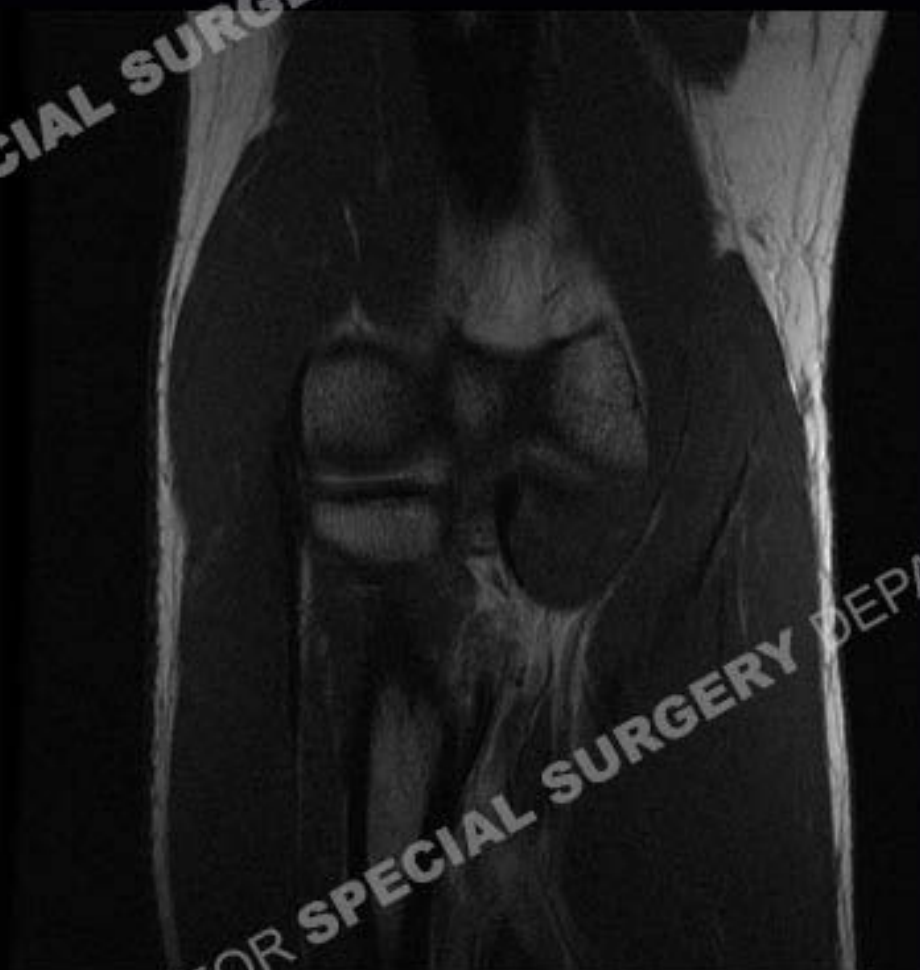

Series: 5  
Image no: 19  
Image 19 of 30

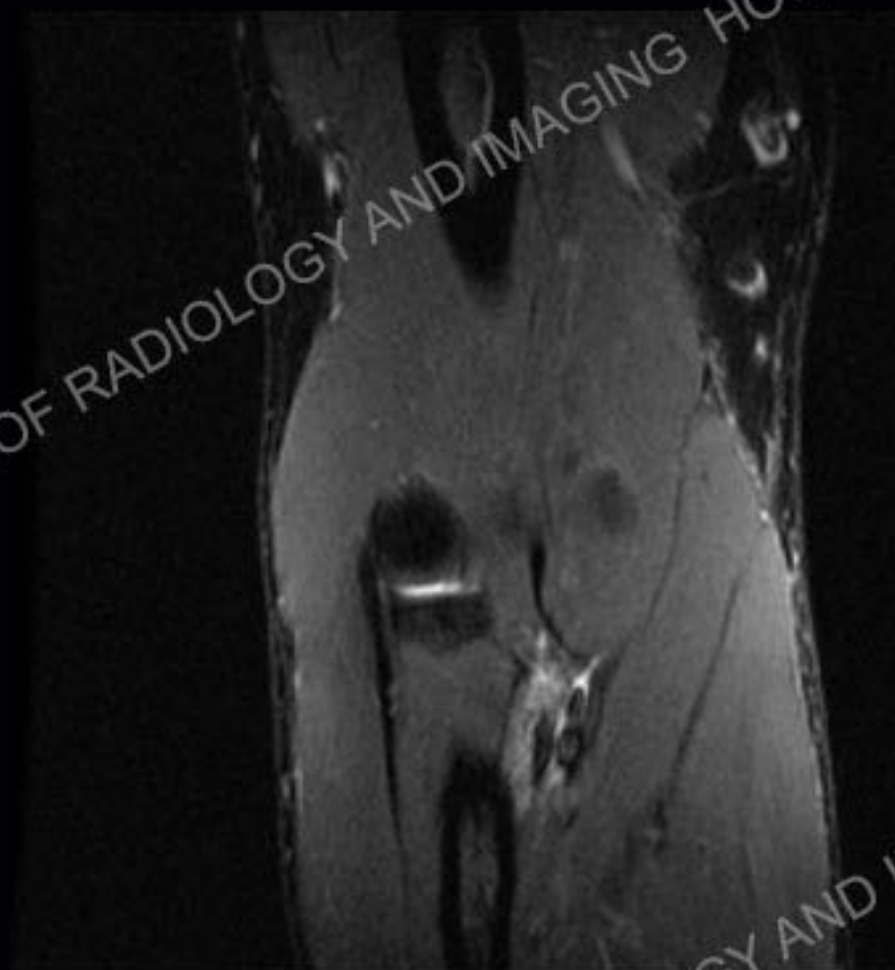


Series: 2  
Image no: 19  
Image 19 of 30

HOSPITAL FOR SPECIAL SURGERY DEPARTMENT OF RADIOLOGY



Series: 6  
Image no: 17  
Image 17 of 30

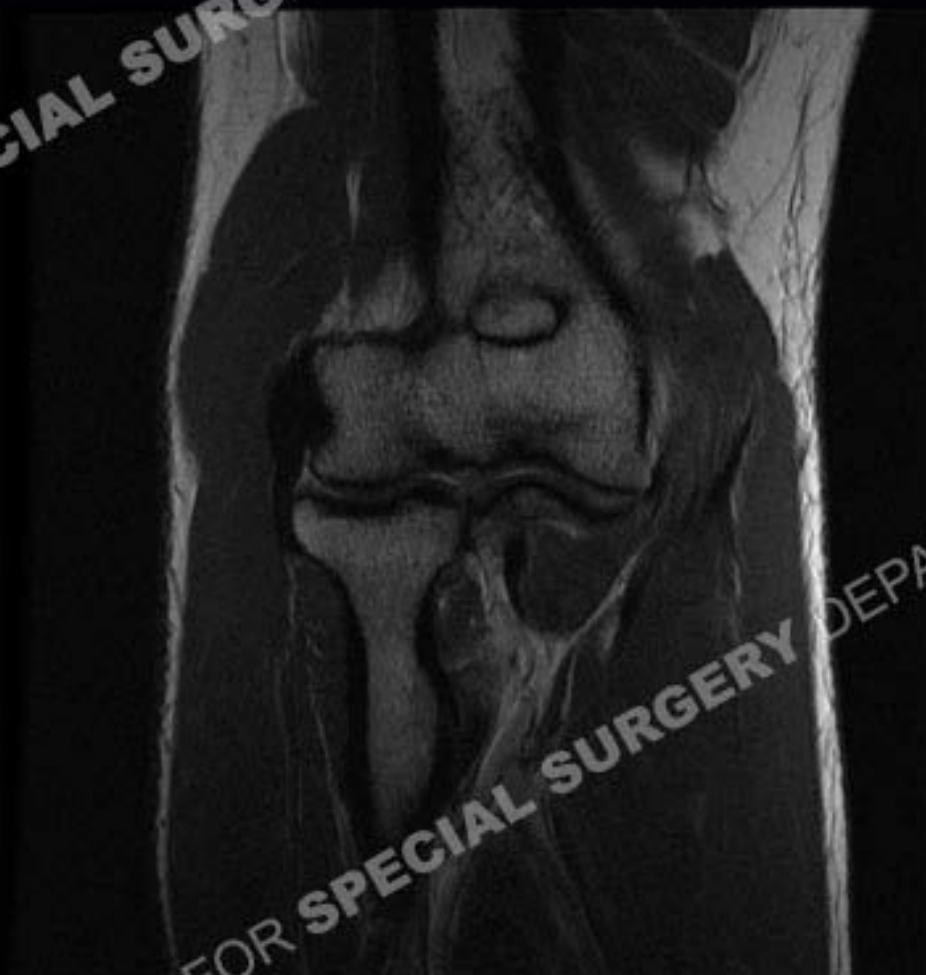

Series: 2  
Image no: 17  
Image 17 of 30

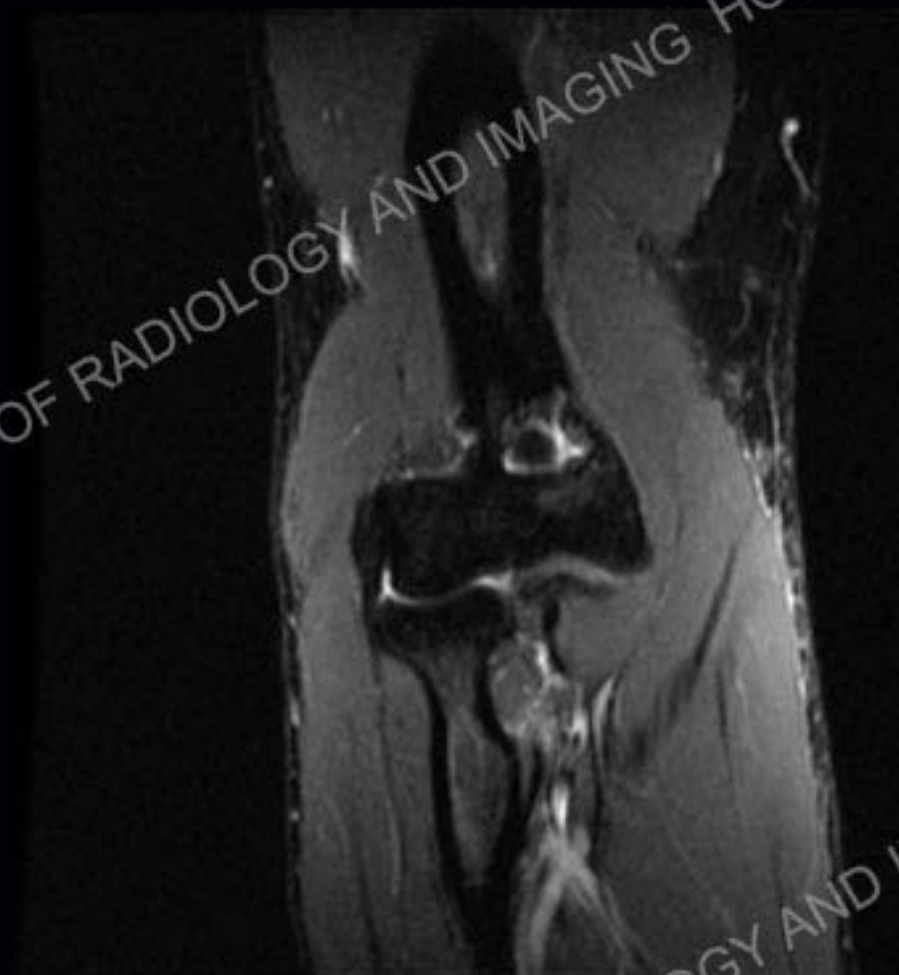
HOSPITAL FOR SPECIAL SURGERY DEPARTMENT OF RADIOLOGY AND IMAGING HOSPITAL



SPECIAL SURGERY DEPARTMENT OF RADIOLOGY



Series: 5  
Image no: 15  
Image 15 of 30



Series: 2  
Image no: 15  
Image 15 of 30

SPECIAL SURGERY DEPARTMENT OF RADIOLOGY AND IMAGING HOSPITAL

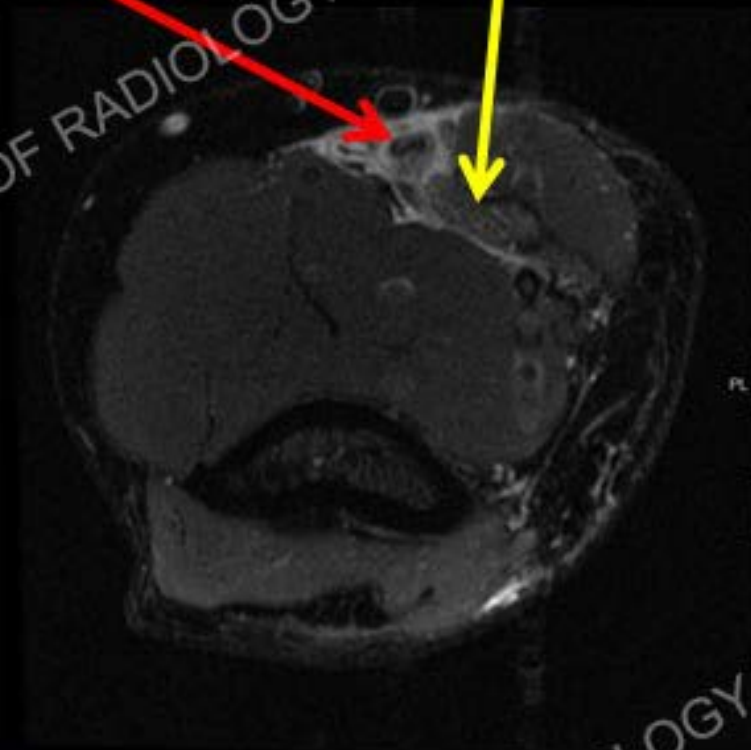
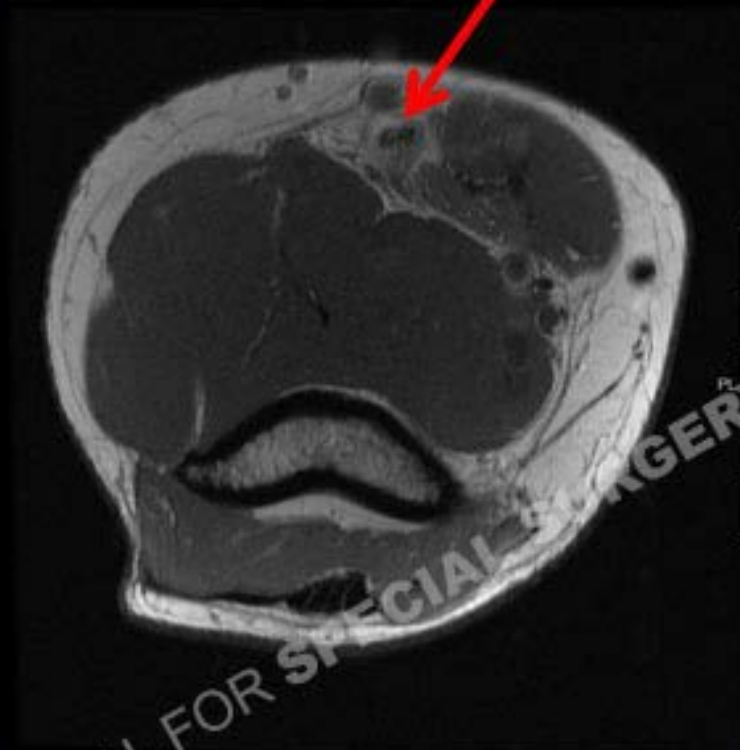
## Findings

Multiple planes of imaging demonstrate two tendons at the expected location of the distal biceps tendon. The more medial tendon demonstrates a low grade injury/strain with otherwise continuity to the radial tuberosity. The more lateral tendon demonstrates complete disruption with retraction of approximately 2.5cm from the radial tuberosity. A marked amount of edema is seen in the adjacent soft tissues.



Lateral tendon hyperintense  
(long head of the biceps)

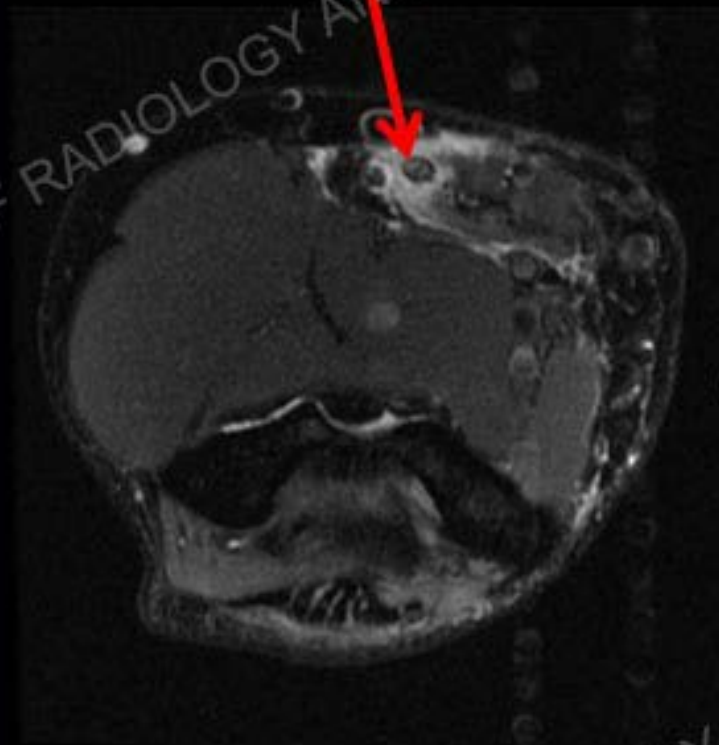
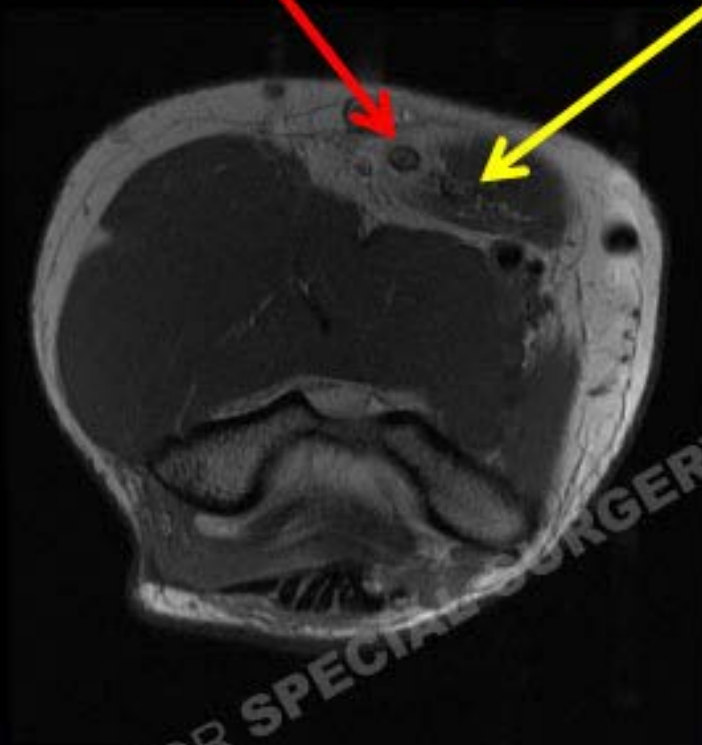
Mild edema about medial  
tendon (short head of the biceps)



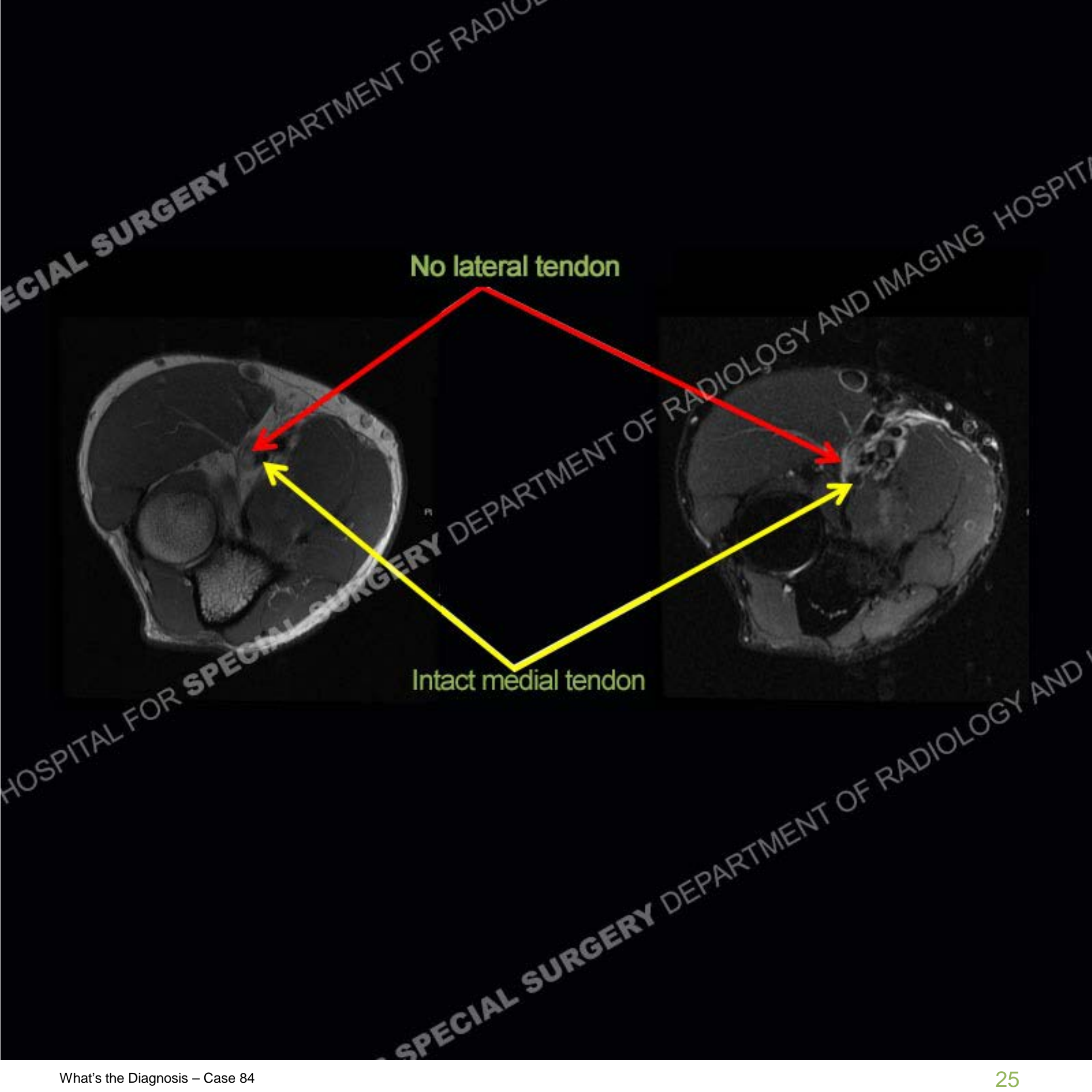
Lateral tendon ( long head)

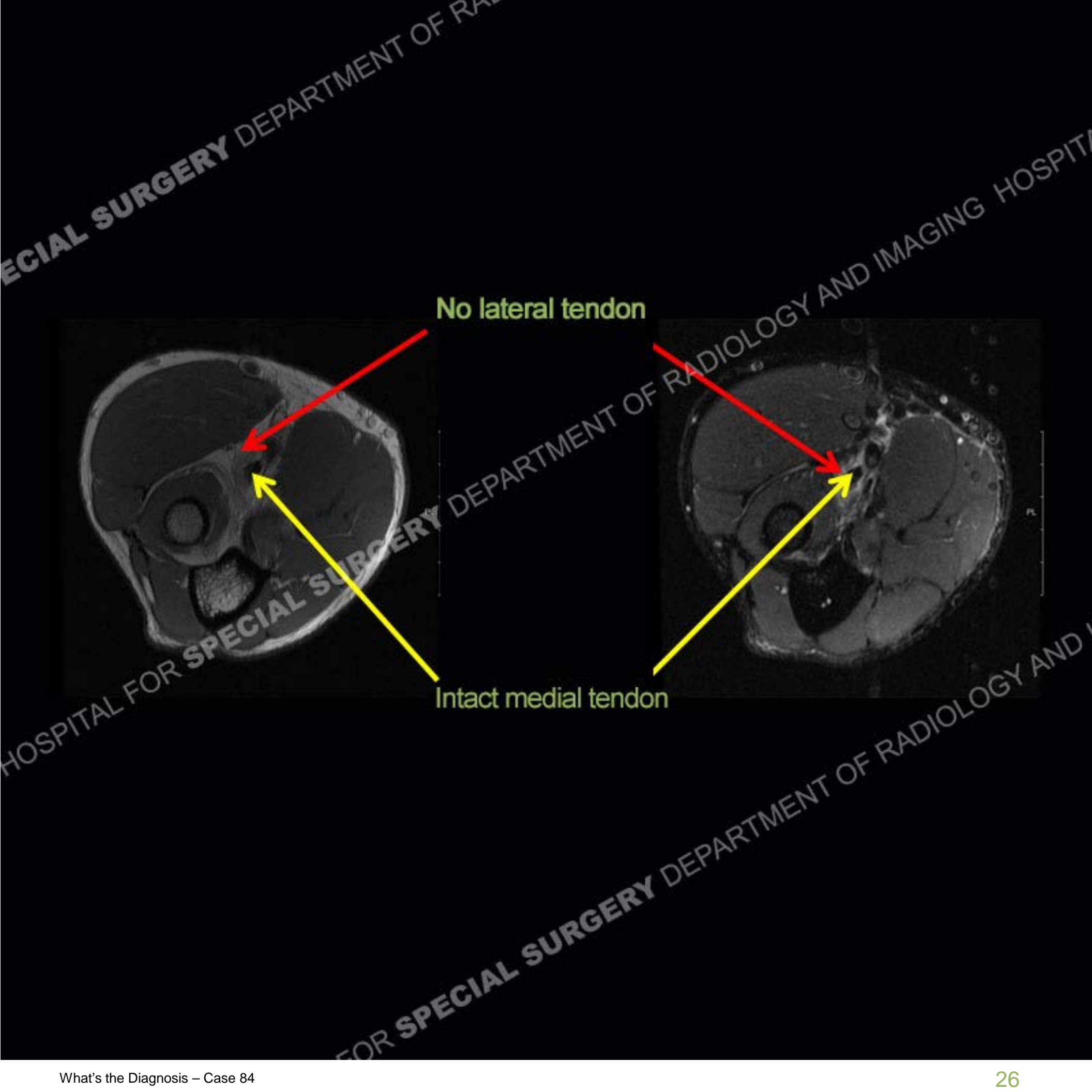
Medial tendon (short head)

Greater edema and injury about the lateral tendon





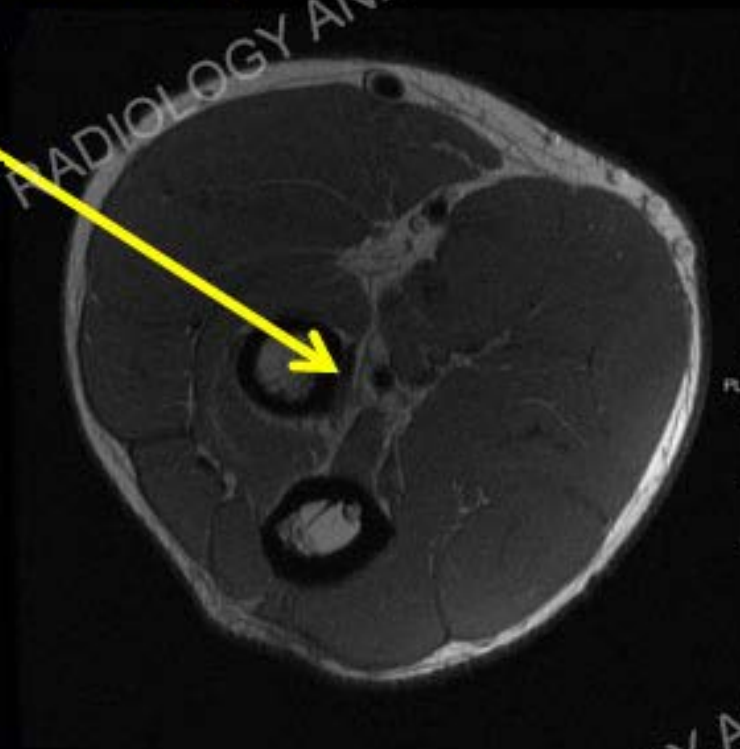
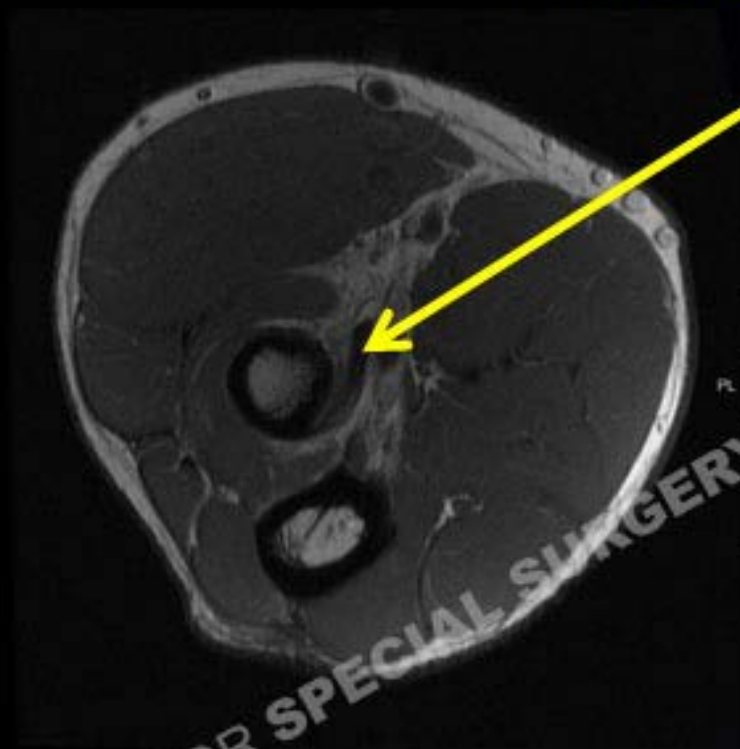


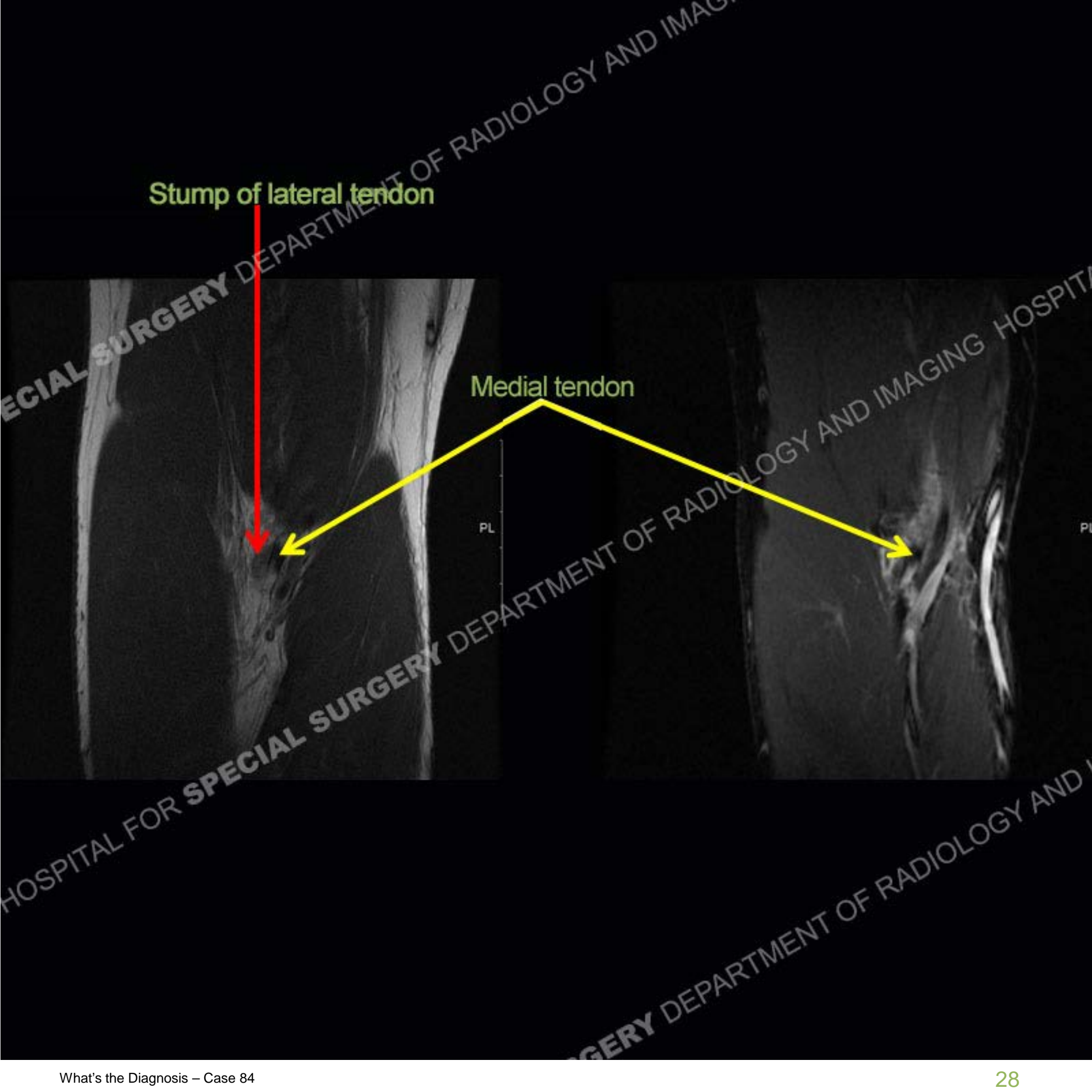
No lateral tendon

Intact medial tendon

Intact medial tendon at radial tuberosity







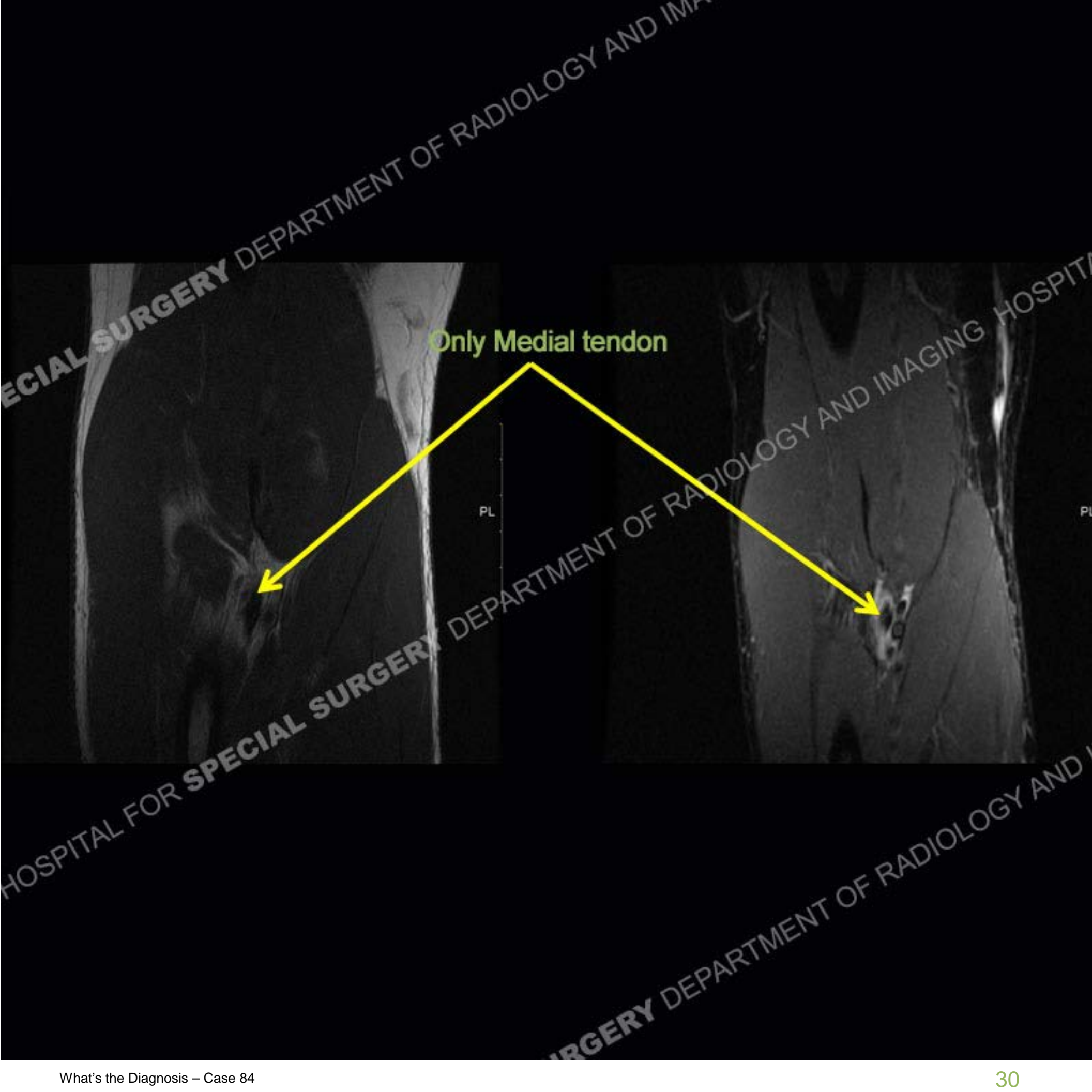Stump of lateral tendon

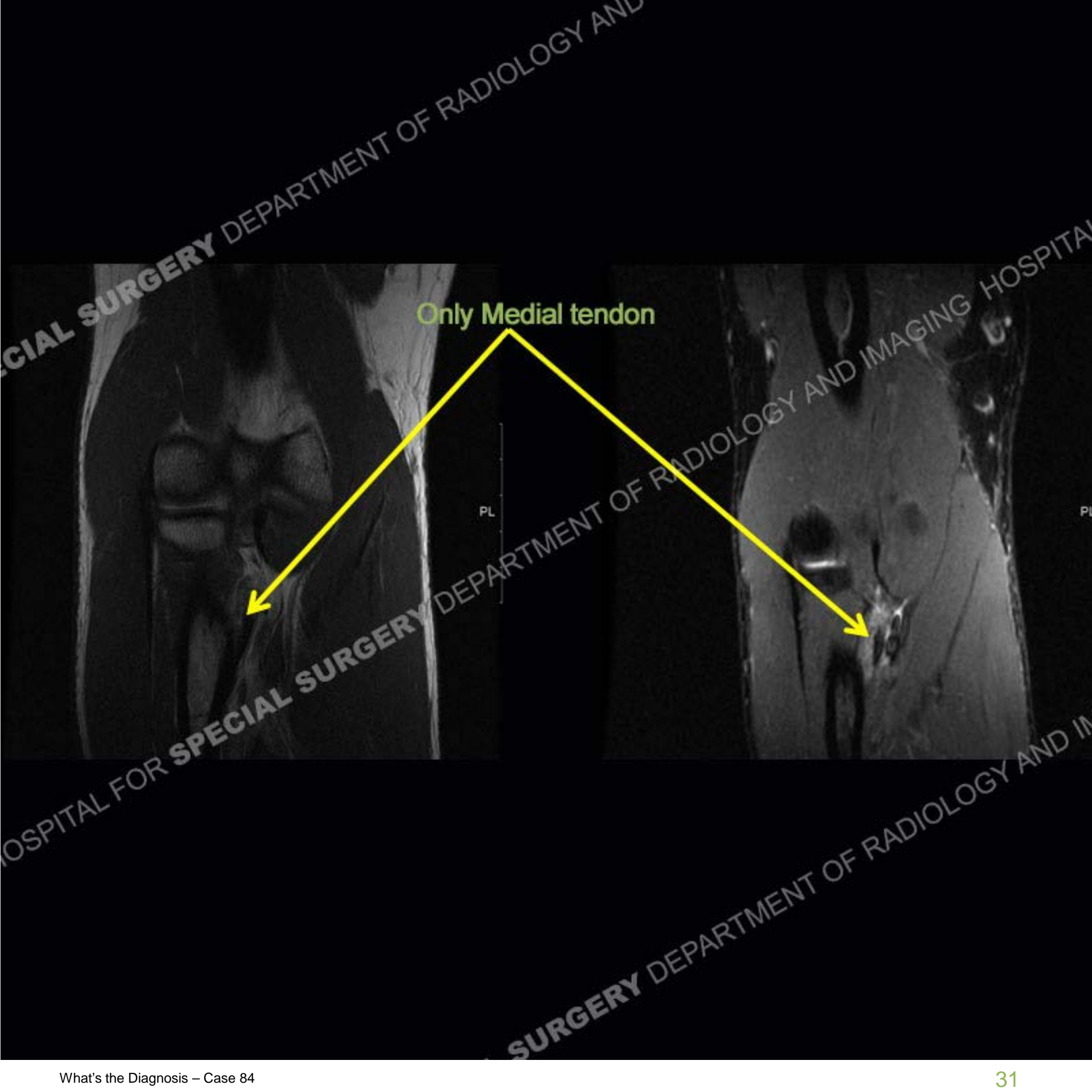Medial tendon

PL







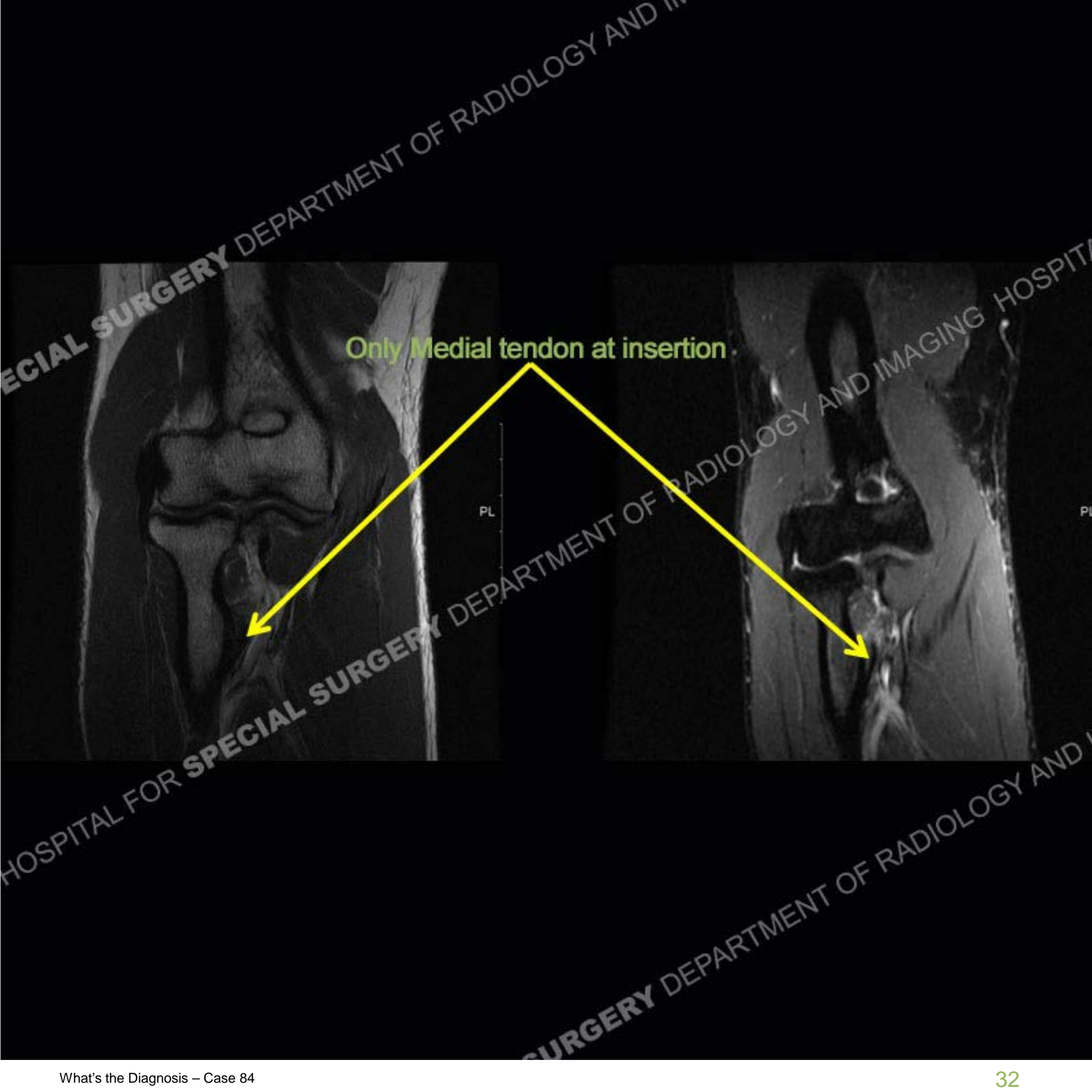

Only Medial tendon

PL

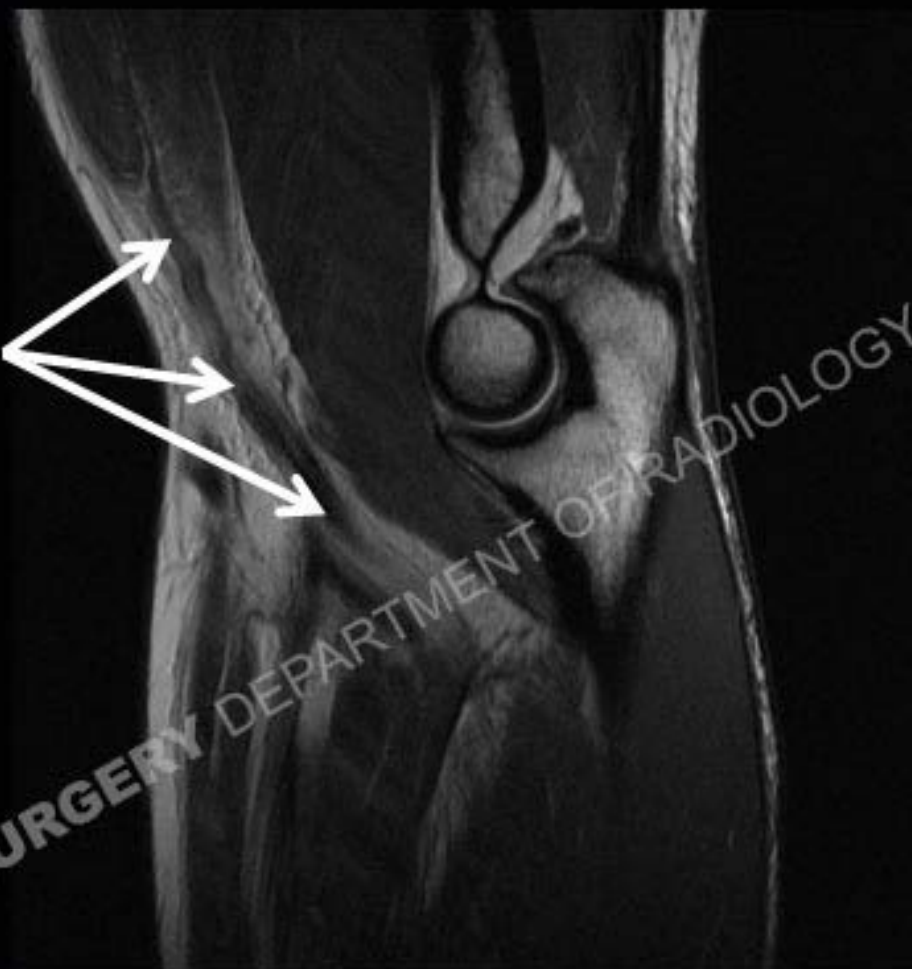PL

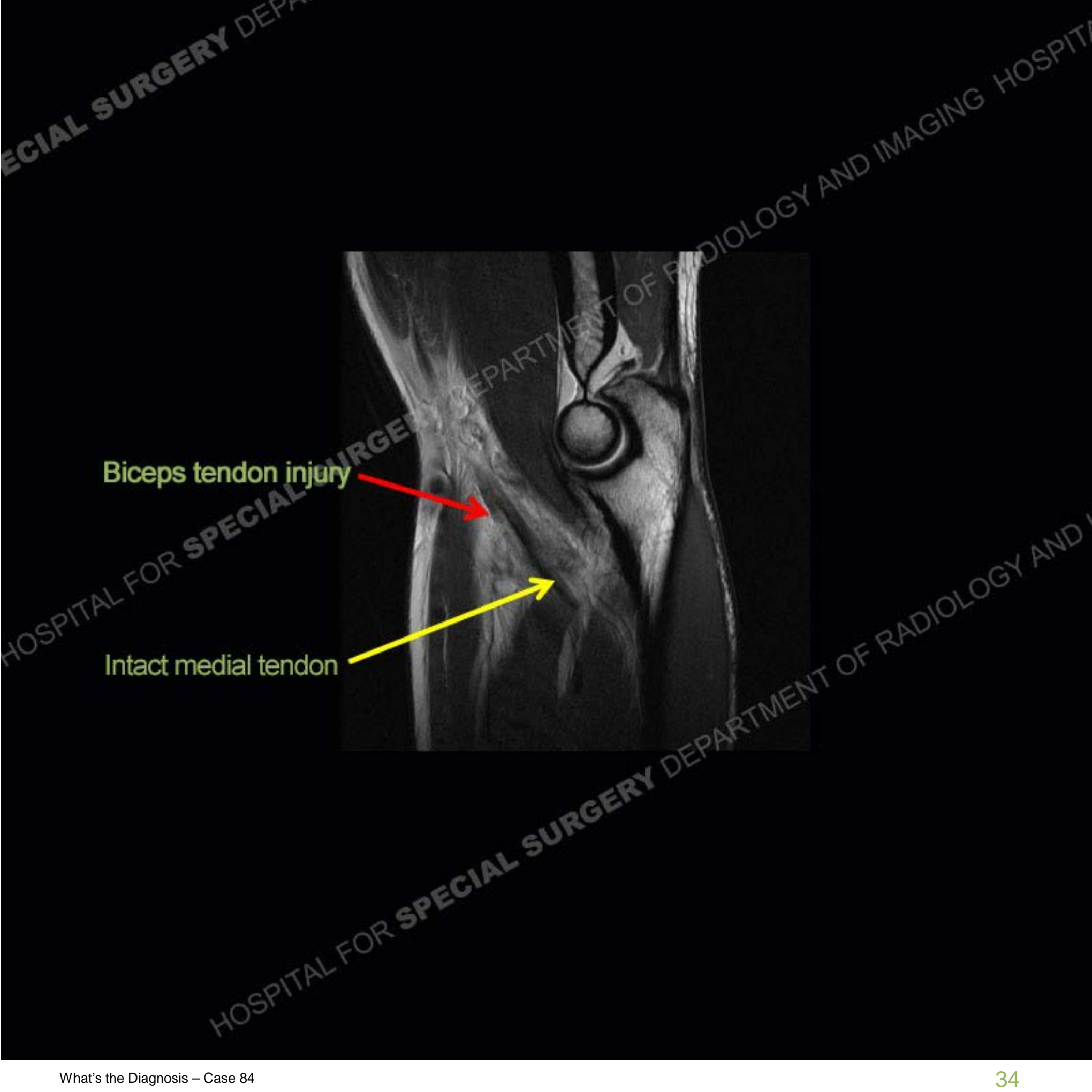





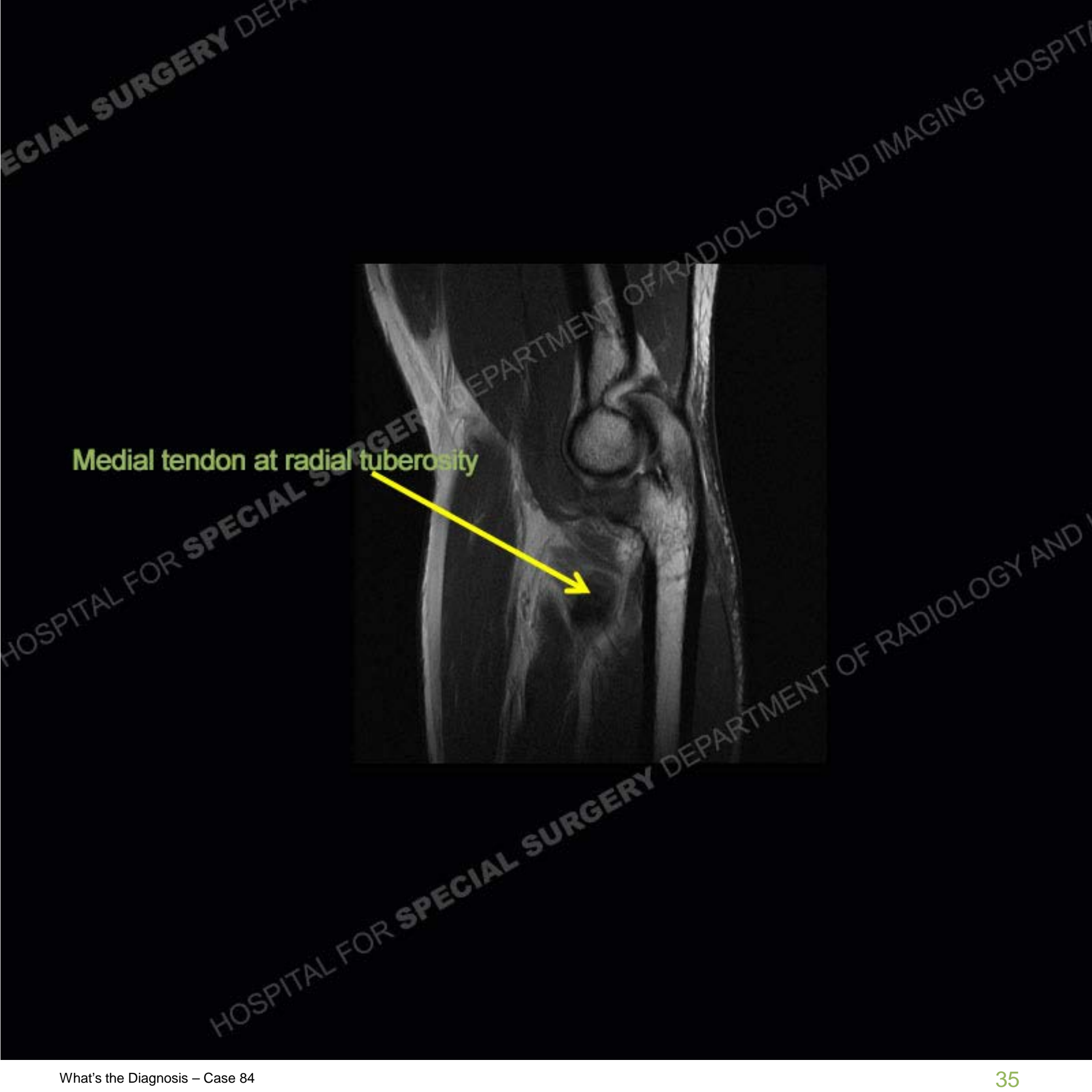Biceps tendon injury





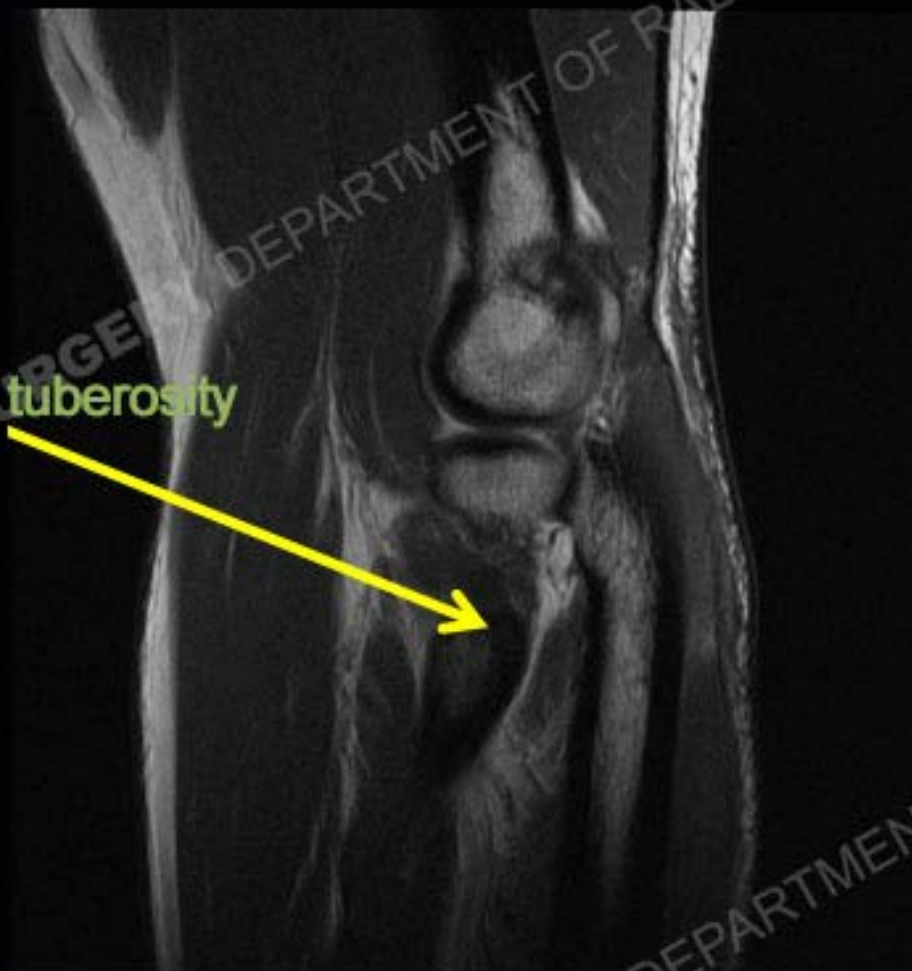
Biceps tendon injury

Intact medial tendon



Medial tendon at radial tuberosity

Medial tendon at radial tuberosity





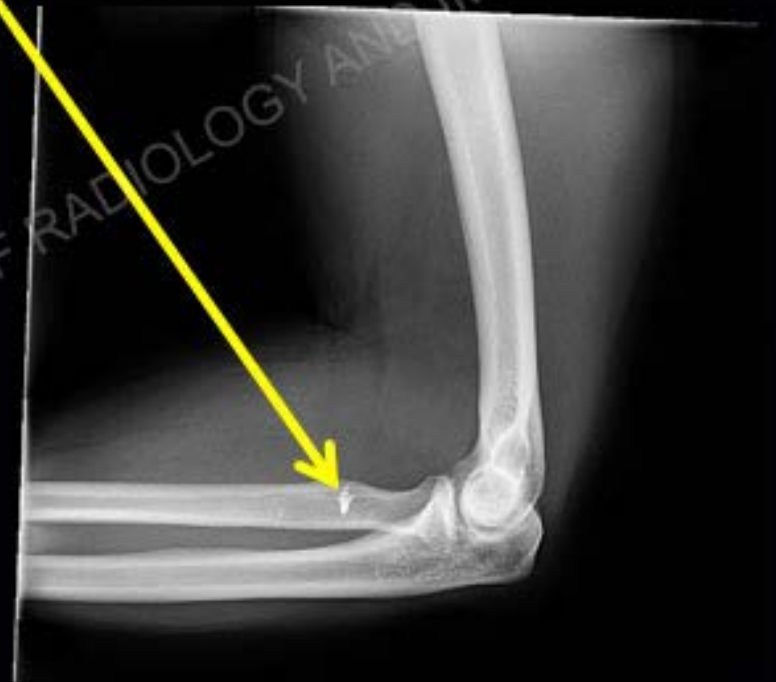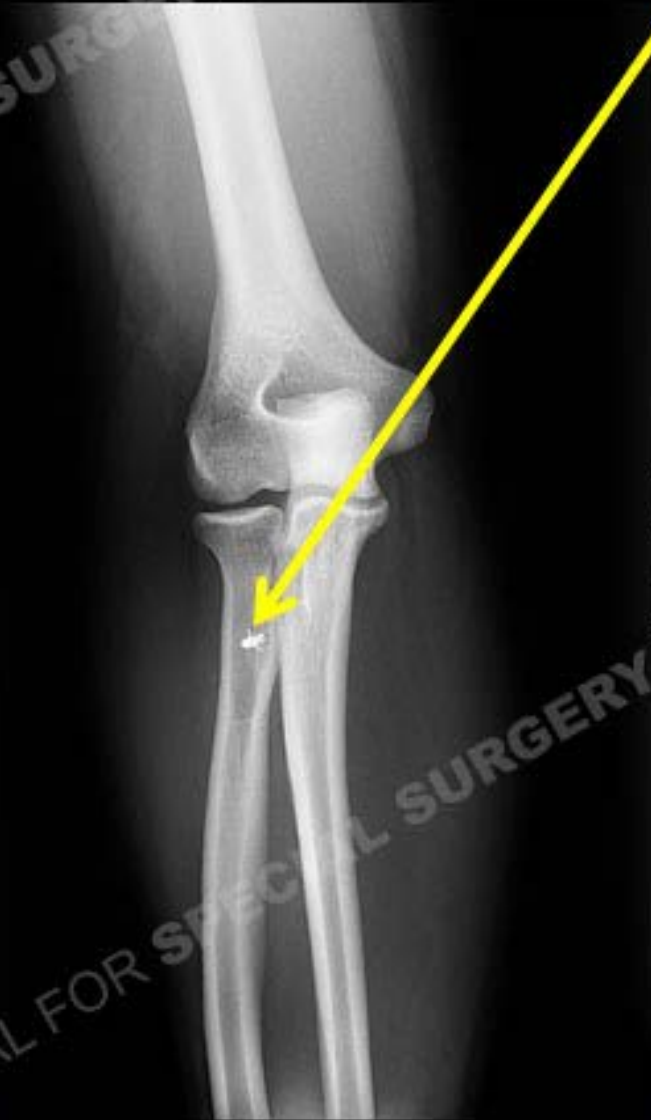## Diagnosis: Complete disruption of one tendon in the setting of a bifurcated/bifid distal biceps tendon

Disruption of the distal biceps tendon is much less common than at the proximal attachment and tends to occur in middle aged men, typically older than 40. The short and long heads of the biceps yield tendons at approximately 7cm proximal to the radial tuberosity attachment site. There is a vast variation in the degree of intertwining or decussation between the two tendons. As in this case, at times there is a persistent bifurcated or bifid architecture of the tendons with two separate tendons extending to the radial tuberosity.

When two tendons are present, the short head of the biceps is the more medial of the tendons and has a more distal insertion on the radial tuberosity. The long head of the biceps is the more lateral tendon and inserts more proximally. In the setting of a selective disruption of one of the tendons, by in large it is the short head but in this example it is the more lateral tendon or long head tendon that is disrupted. However, there has been a strain of the short head seen best on the axial IR images and hence this is not completely, an isolated or selective injury. The importance of these findings is to be aware that injury can have still been sustained even if a tendon attachment is present at the radial tuberosity and surgery may still be necessary for the selective disruption.

## Follow up

### Repair of selective disruption of the long head



## References

Bifid insertion of the distal biceps brachii tendon with isolated rupture: magnetic resonance findings. Koulouris G, Malone W, Omar IM, Gopez AG, Wright W, Kavanagh EC. J Shoulder Elbow Surg. 2009 Nov-Dec;18(6).

<http://radsourc.us/pathology-of-the-long-head-of-the-biceps-tendon/>

