History: 44 year old man with increasing loss of range of motion

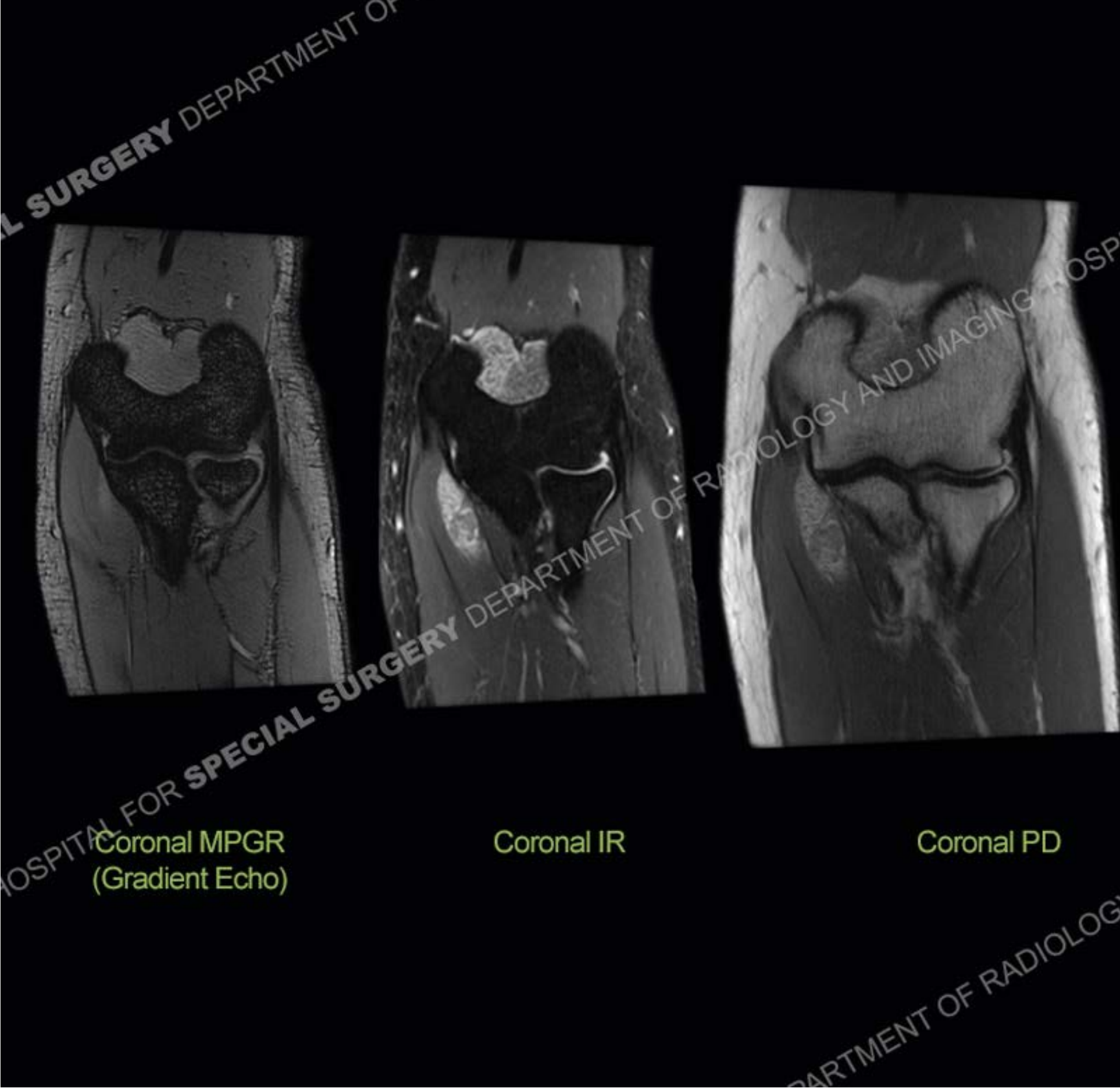

HOSPITAL FOR SPECIAL SURGERY DEPARTMENT OF RADIOLOGY AND IMAGING

Coronal MPGR

Coronal PD Images

DEPARTMENT OF RADIOLOGY AND IMAGING HOSPITAL FOR SPECIAL SURGERY

FOR SPECIAL SURGERY DEPARTMENT OF RADIOLOGY AND IMAGING HOSPITAL

Findings

Radiographs demonstrate small, punctate calcifications of the left elbow joint with preserved joint spaces and a very large joint effusion. MRI demonstrates the effusion with a marked amount of synovial proliferation in a fine, “rice body” configuration. The articular cartilage is maintained but there is indolent erosion of the distal humerus particularly seen of the olecranon fossa and coronoid fossa. The MPGR sequence shows areas of low signal or blooming only corresponding to the punctate calcifications of the radiographs.

Punctate calcification
Preserved joint spaces

HOSPITAL FOR SPECIAL SURGERY DEPARTMENT OF RADIOLOGY AND IMAGING

Joint effusion with synovial proliferation in “rice body” configuration

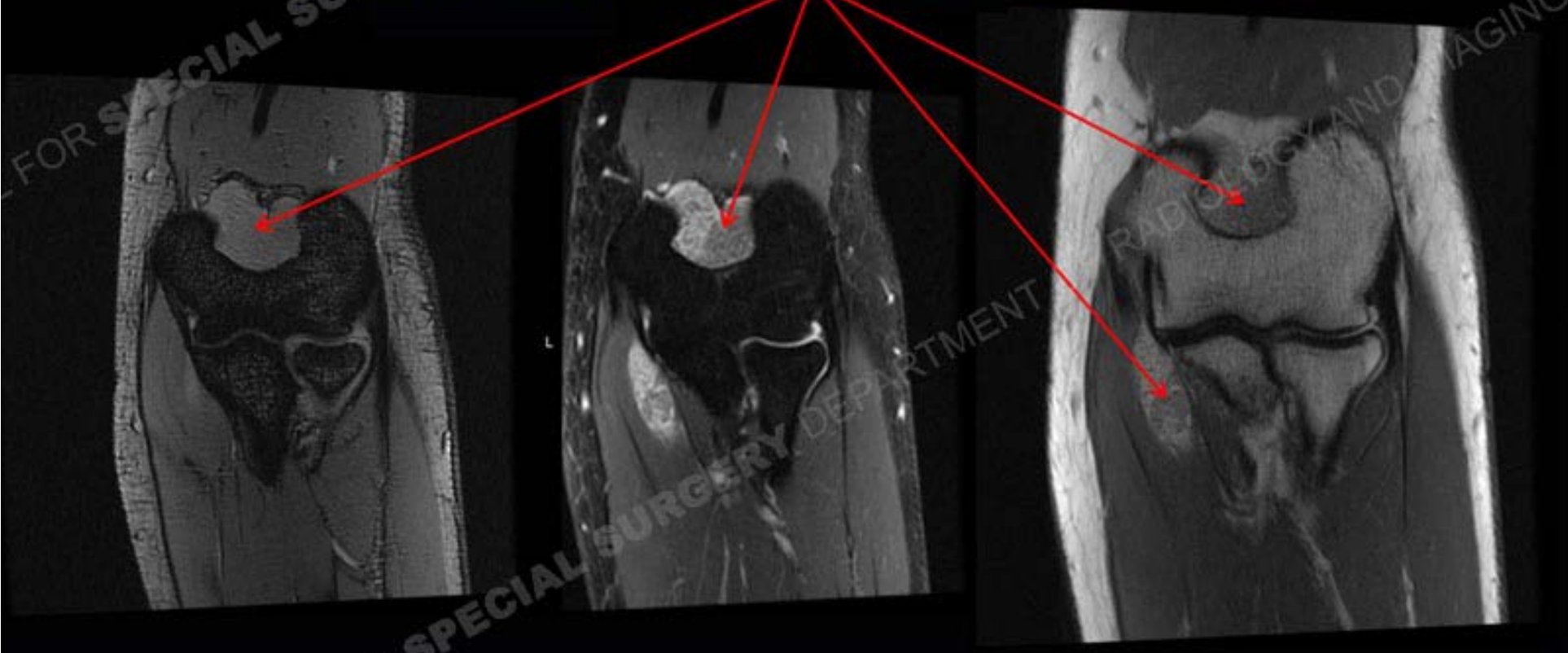

Coronal MPGR (Gradient Echo)

Coronal IR

Coronal PD

HOSPITAL FOR SPECIAL SURGERY DEPARTMENT OF RADIOLOGY AND IMAGING

Low signal on MPGR or blooming only at areas of calcification

HOSPITAL FOR SPECIAL SURGERY DEPARTMENT OF RADIOLOGY AND IMAGING

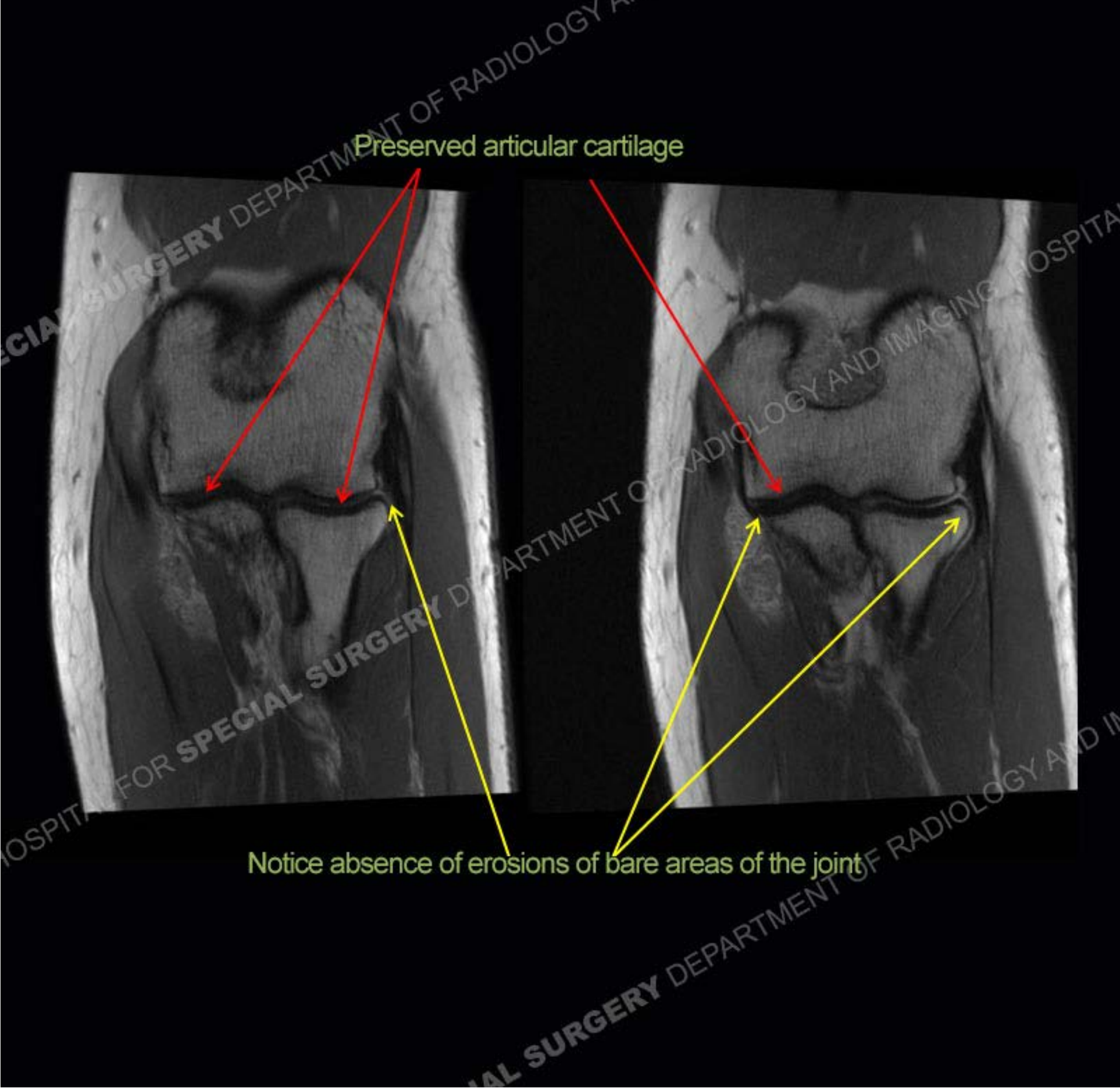
Preserved articular cartilage
Notice absence of erosions of bare areas of the joint

Indolent erosion of coronoid and olecranon fossae

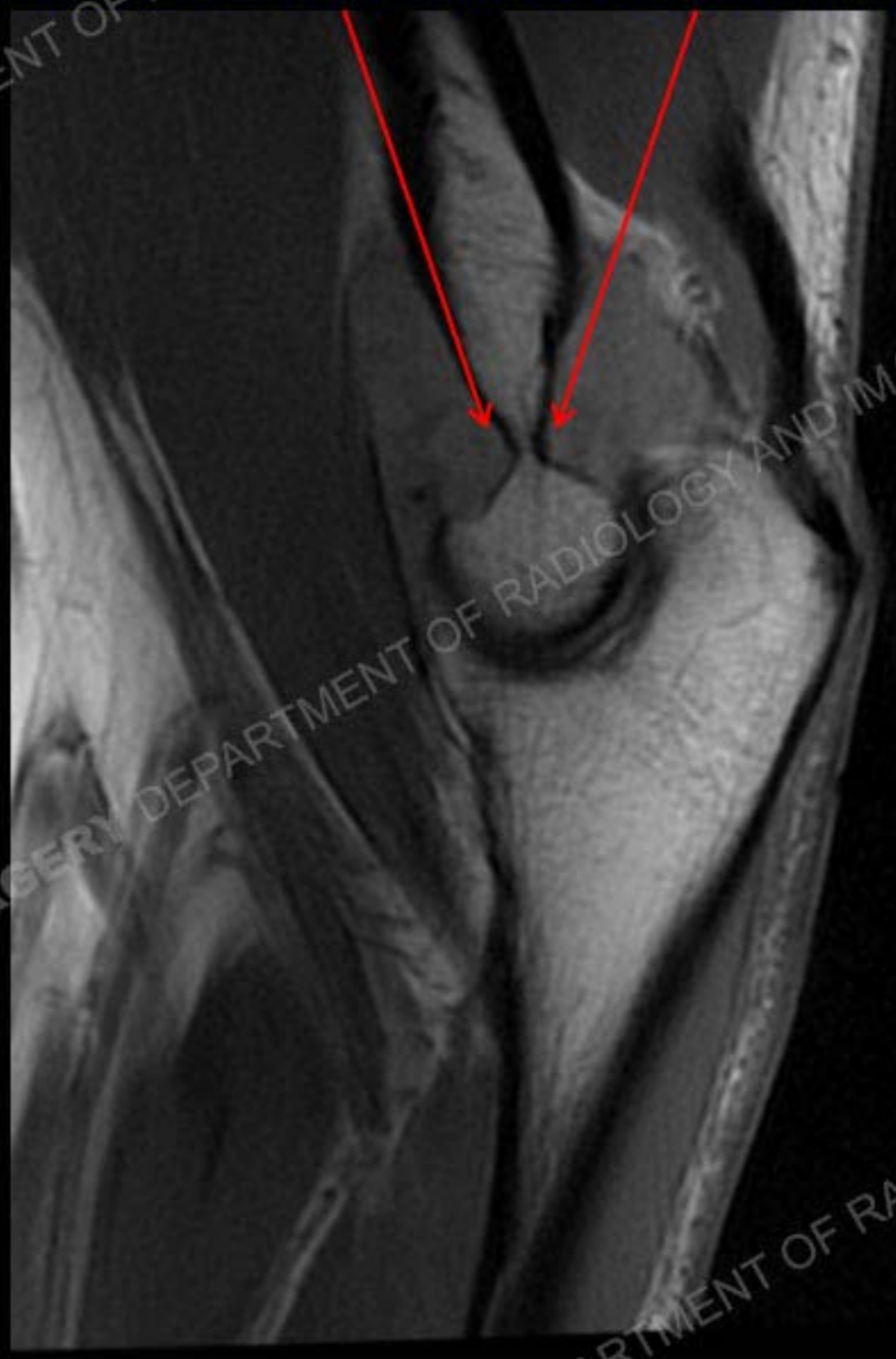

SURGERY DEPARTMENT OF RADIOLOGY AND IMAGING HOSPITAL FOR SPECIAL SURGERY

Diagnosis: Synovial Osteochondromatosis

A synovial metaplasia typically occurring in middle aged adults yielding innumerable areas of proliferated synovium and a large joint effusion with a mono-articular distribution. With time, focal areas calcify and ossify and may develop large areas of conglomerate ossification. Typically, there is relative preservation of the joint cartilage, but there may be indolent erosions particularly in less capacious joints such as the hip or elbow.

The differential diagnosis includes a “secondary” osteochondromatosis which represents multiple ossific and calcified bodies in the joint related to degenerative change. PVNS will not calcify or ossify and the synovium does not yield the rice body configuration. Classically, TB yields rice bodies but would not give small calcifications and would yield marginal erosions as well as juxta-articular osteoporosis. Rheumatoid arthritis in addition, can give a rice body configuration to the synovium but would yield erosions at the bare areas, a loss of joint cartilage and joint space, and typically involves multiple joints.