HOSPITAL FOR SPECIAL SURGERY
150 YEARS

SUMMER 2013 | VOLUME 4 | ISSUE 2

Grand Rounds from HSS

MANAGEMENT OF COMPLEX CASES

AUTHORS

Austin T. Fragomen, MD
Assistant Attending Orthopaedic Surgeon
Fellowship Director, Limb Lengthening and Complex Reconstruction
Hospital for Special Surgery
Assistant Professor of Orthopaedic Surgery
Weill Cornell Medical College

S. Robert Rozbruch, MD
Chief, Limb Lengthening and Complex Reconstruction Service
Attending Orthopaedic Surgeon
Hospital for Special Surgery
Professor of Clinical Orthopaedic Surgery
Weill Cornell Medical College

FROM THE EDITOR

In 1863, the turning point battles of Chancellorsville and Gettysburg were the bloodiest in the American Civil War. There were an estimated 51,000 casualties from both armies in the three-day Battle of Gettysburg. According to David B. Levine, MD, our eminent Emeritus Professor and author of *Anatomy of a Hospital: Hospital for Special Surgery 1863–2013**, on the evening before May 1, 1863, General Robert E. Lee and General Stonewell Jackson met to plan the Battle of Chancellorsville. The next day Hospital for Special Surgery opened its doors on lower Second Avenue in New York City as The Hospital for the Ruptured and Crippled and today is the oldest orthopaedic hospital in the nation.

During the Civil War an open, comminuted fracture of the lower extremity, unless treated with amputation within 48 hours, led to a fatality rate of 50 percent to 99 percent depending upon the length of delay. In the wake of the Boston Marathon bombings we appreciated how effectively health care providers responded to a crisis of such magnitude, with many of the 264 wounded sustaining lower extremity injuries. The cases in this volume are from the Hospital for Special Surgery Limb Lengthening and Complex Reconstruction Service; Service Chief Rob Rozbruch and his associate, Austin Fragomen. These cases dramatically demonstrate how far orthopaedic care in lower limb preservation and reconstruction has progressed in 150 years.

All volumes of Grand Rounds from Hospital for Special Surgery are also available on **www.hss.edu/complexcases**, where you will find additional images and references as well as links to related articles. We hope you find these cases to be of interest and the principles presented informative. Comments are always welcome at **complexcases@hss.edu**.

— Edward C. Jones, MD, MA, Assistant Attending Orthopaedic Surgeon

**Anatomy of a Hospital: Hospital for Special Surgery 1863-2013* by David B. Levine, MD is available at Hospital for Special Surgery and on Amazon.com

In this issue

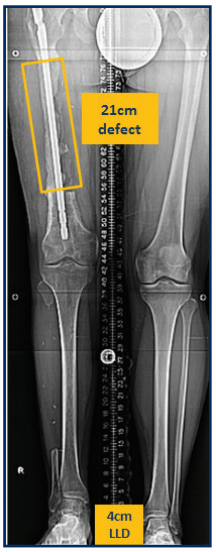

CASE 1

Recalcitrant Femoral Nonunion: A Case for Integrated Fixation

Case presented by Austin T. Fragomen, MD

CASE REPORT: A 20-year-old male was a restrained driver in a high speed auto accident. He sustained open fractures of the left tibia and left femur. With liver, spleen, and duodenal lacerations he underwent lifesaving exploratory laparotomy with splenectomy. IM nailing of the femur and tibia were also performed. He developed a septic nonunion of the femur with persistent wound drainage. Despite multiple debridements, hardware exchanges, and courses of IV antibiotics he remained infected.

The patient presented to our center 18 months after the injury malnourished, with poor knee motion and contemplating above knee amputation (Figure 1). Limb salvage was pursued using a staged technique called bone transport-over-nail. In the first stage a total of 9cm of bone was removed leaving a well vascularized bed for reconstruction. An antibiotic cement coated wire was inserted into the IM canal both to deliver local antibiotics and to prepare for later placement of an IM nail. A monolateral external fixator was placed by inserting the pins into the femur posterior to the IM canal. This would allow transport of the bone segment over the nail (Figure 2). After 4 weeks the patient returned to the operating room for the second stage. The antibiotic cement wire was removed and a custom IM nail was inserted. A femoral osteotomy was performed in the distal third around the IM nail. The bone transport segment slid proximally over the nail at 1mm per day. A total of 12cm of bone was grown through distraction osteogenesis (Figure 3). The IM nail was then locked and the external fixator removed in a third surgery 5 months after the lengthening was started. A custom locking hole that had been placed in the mid portion of the IM nail was utilized to hold the transport segment in place. A limited quadricepsplasty was performed simultaneously to improve the patient's flexion from 20 degrees pre op to 120 degrees post op. The lateral cortex of the docking site was bone grafted with 3cc of autograft from the left iliac crest.

The patient maintained protective weight bearing for 6 weeks and began physical therapy concentrating on knee range of motion. The femur healed without any further signs of infection (Figure 4). One year after removal of the external fixator the patient is back at college and walking without an assisted device.

DISCUSSION: Infected nonunion of the femur with bone loss is a difficult treatment challenge. Management with internal fixation is dangerous because of the potential for re-infection, and internal fixation does not address the large bone defect. External fixation allows for eradication of infection but is bulky and difficult for the patient to manage. Large bone transports require prolonged external fixation times. A 12cm transport would typically necessitate wearing the fixator for 12-18 months. By integrating internal and external fixation the best of both techniques can be applied. The external fixator was used to removal all infection and was later used as a motor to move the bone transport segment. The internal IM nail was used to guide the transport preventing deformity. It was later used to provide stability to the immature regenerate bone allowing for early removal of the external fixator. In this case a 12cm lengthening required only 5 months of external fixation. The concept of integrating internal with external fixation has been described in previous publications. (1, 3-5) Although there is the potential for infection using integrated fixation, the infection rate is very low particularly in the femur (2). With these advanced limb salvage techniques surgeons can be more confident about resecting large segments of poor bone to eliminate infection. ■

References continued on page 5

FIGURE 1

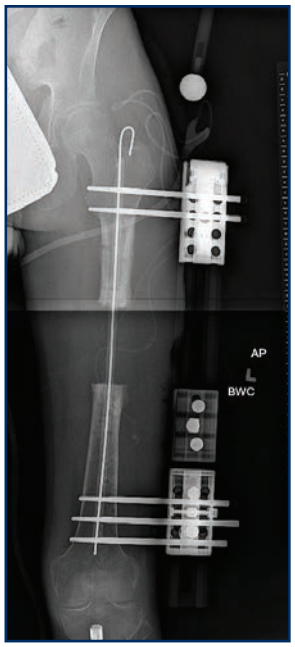

FIGURE 2

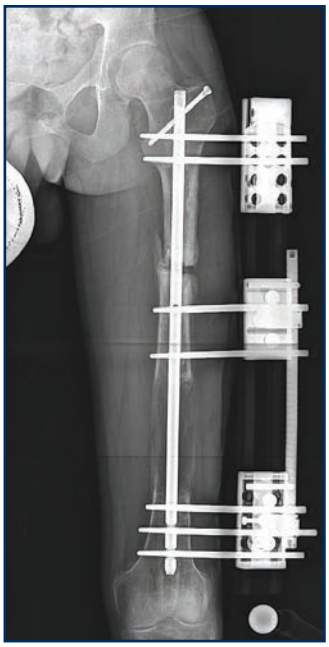

FIGURE 3

FIGURE 4

FIGURE 1: X-ray of the left femur showing sclerotic bone ends and a cement spacer at the femur nonunion site.

FIGURE 2: X-ray after a large bone resection was performed, and a vancomycin-PMMA coated guide wire was inserted into the IM canal. A monolateral external fixator was placed by inserting the pins into the femur posterior to the IM canal.

FIGURE 3: X-ray after distraction osteogenesis. The IM nail was not locked distally to allow for further lengthening after docking the transport segment.

FIGURE 4: Follow up x-ray shows a well healed docking site and circumferential healing of the regenerate with thick cortices.

CASE 2

Lengthening of 20cm in the Femur and Tibia to Equalize Leg Lengths in a Growing Child

Case presented by S. Robert Rozbruch, MD

CASE REPORT: A 9-year-old male presented to HSS with a 5.5cm Leg Length Discrepancy (LLD) (Figure 1). There was no history of infection or trauma and growth plates looked normal on x-ray. This appeared to be a congenital LLD and the predicted LLD at maturity was thought to be 7.5cm using standard prediction methods. He underwent a right femur lengthening of 5cm using a monolateral frame on the femur (Figure 2). A minimal incision quadricepsplasty was done to treat a knee extension contracture. This was uneventful and we planned to do another small lengthening as a young teenager.

However, during follow up, the growth plates were noted to be increasingly irregular. At age 12 years, the patient was noted to have 7cm of additional LLD and trochanteric overgrowth at the hip. The radiographs now demonstrated abnormal closure of all growth plates of the right lower extremity including the proximal and distal femur as well as the proximal and distal tibia. A poorly defined dysplasia affecting the growth plates was apparent. At age 12 years, he underwent a 7cm lengthening of the tibia and fibula using an Ilizarov/Taylor spatial frame (TSF) (Figure 3). Gastrocnemius recession was done to treat an equines contracture. Closure of the proximal femur trochanteric growth plate was also done to prevent progression of hip deformity.

At age 15 years, he had an additional 8cm of LLD. At that time, he underwent right femur lengthening over a nail (LON) to gain 8cm and achieve equal leg lengths (Figure 4). A contralateral left distal femur and proximal tibia epiphysiodesis was also performed to prevent additional LLD. In total, he underwent 20cm of right lower extremity lengthening in 3 stages (Figures 5, 6). The patient is now 21 years of age and has equal leg lengths, a normal gait, and normal hip, knee, and ankle range of motion. He has no functional limitations.

DISCUSSION: Although this patient initially appeared to be a typical case of congenital LLD, it became apparent that with dysfunction of all the right lower extremity growth plates, a massive LLD would ensue. Both amputation followed by prosthetic fitting and treatment with a massive platform shoe lift were not acceptable options for this family. The LLD was coming from both femur and tibia. Our plan after the initial femur lengthening was to do a lengthening of the tibia/ fibula and then to come back and repeat a femur lengthening. Also planned was an epiphysiodesis of the contralateral side to prevent additional LLD after the last lengthening at age 15 (1).

The growth plate shutdown and dysplasia were not well defined despite additional consultation with several pediatric orthopedic colleagues and a geneticist. The main practical issue of LLD was, however, addressed with three well timed lengthenings and an epiphysiodesis of the long side.

During the first femur lengthening and during the tibial lengthening, soft tissue contractures developed that were recalcitrant to physical therapy. Our minimal incision quadricepsplasty (2) was effective in treating the knee extension contracture at the end of femur distraction. Gastrocnemius recession was used to treat the ankle equines contracture during the tibial lengthening. Well-timed soft tissue releases have been very effective in our practice to preserve normal joint range of motion.

The second lengthening at age 15 was done using LON. This is a hybrid technique in which the femur is lengthened over an IM nail with an external fixator. There is no contact between internal and external fixation. The external fixator pins were

Continued on page 5

FIGURE 1: At age 9 showing 5.5cm LLD.

FIGURE 2: X-ray after 5cm of right femur lengthening using a monolateral frame.

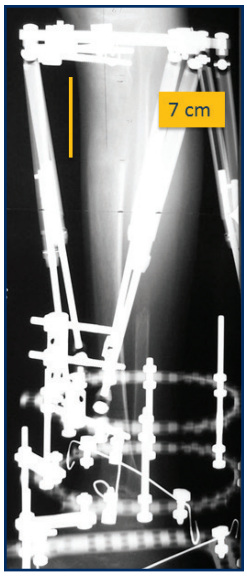

FIGURE 3: X-ray at at age 12, after a 7cm tibial/ fibula lengthening with a TSF.

FIGURE 4: X-ray at age 15, after an 8cm femur lengthening using LON technique.

FIGURE 5: Standing x-ray showing equal leg lengths after 3 right lower extremity lengthenings totaling 20cm. Left side has undergone epiphysiodesis.

FIGURE 6: At age 15 after 20cm of lengthening.

CASE 3

Trifocal Bone Transport and Motorized Intramedullary Nail to Restore Massive Limb Length Inequality After Excision of Osteosarcoma of the Femur

Case presented by S. Robert Rozbruch, MD

CASE REPORT: A 35-year-old male previously underwent resection of osteosarcoma from the right femur 5 years prior to presenting at HSS. Tumor treatment was entirely successful and the patient was cured of cancer. However, reconstructions first with ipsilateral free fibula and then with allograft both failed. The patient presented to us with a 21cm bone defect in the right femur that was stabilized with an intramedullary (IM) rod and bone cement after treatment of an infection. He additionally had 4cm of leg length discrepancy (LLD). In total, this represented 25cm of bone loss (Figure 1). The recommendation given to him from other surgeons was hip disarticulation amputation.

Limb salvage surgery was presented by us as an alternative option. The proposed plan included a trifocal bone transport over an IM nail using cable/pulley technique for the femur defect. Subsequent tibial lengthening was planned using a fully implantable motorized IM nail.

The first procedure was removal of the IM nail and bone cement revealing the 21cm femur defect. Intraoperative cultures were clear of infection. A double level osteotomy in the femur was performed followed by insertion of a locked IM nail. Cable wires were applied to the proximal and distal transport segments and pulled through the skin. An Ilizarov frame with pulleys was applied around the IM nail without any contact between internal and external fixation. Trifocal transport then began pulling the proximal and distal transport segments towards each other with gradual closure of the bone defect. Transport was done at 1mm per day following the principles of distraction osteogenesis (Figure 2).

After 4 months, the transport segments made contact and the docking site was stabilized with a plate around the IM nail and bone graft. Bone marrow aspirate concentrate (BMAC), containing mesenchymal stem cells, was injected into the lengthening sites to enhance bone healing. A few months later, the tibia was gradually lengthened 4cm to equalize the leg lengths. This was done with a fully implantable motorized lengthening IM nail. Repeat BMAC injections into the regenerate helped optimize bone healing.

At 2 year follow-up the patient has no pain, normal hip and ankle range of motion (ROM), and knee ROM of 0-120 degrees. He walks without a limp and without assistance. X-rays show full bony union of both femur and tibia, equal leg lengths, and no deformity (Figures 3, 4, 5).

DISCUSSION: Segmental bone defects often result after tumor excision. While these defects are often reconstructed with endoprosthesis, allograft, and free fibula, there are problems with fracture, infection, and loosening. We have successfully used distraction osteogenesis to reconstruct bone defects with living bone to achieve limb salvage (1,2).

This patient had a massive bone defect in the femur. We used transport over an IM nail and a trifocal technique – two lengthening sites and a shortening site. This hybrid technique allows removal of the external fixator after the end of distraction, minimizing the time in the frame (3). The cable wire and pulley modification for bone transport (4) has the particular advantage of minimizing the soft-tissue trauma caused by the fixation of the transport fragments.

Injection of mesenchymal stems cells found in BMAC has been a useful technique to enhance bone healing. During trips to the operating room for the planned staged parts of the procedure, we used this as an opportunity to inject BMAC into the regenerate and the docking site. This is a minimally invasive technique initially described for the treatment of nonunions (5).

Continued on page 5

FIGURE 1

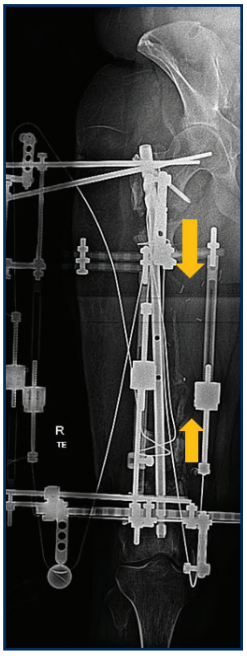

FIGURE 2

FIGURE 3

FIGURE 4

FIGURE 5

FIGURE 1: Preoperative x-ray showing a 21cm femur defect spanned with IM rod and cement plus additional LLD of 4cm.

FIGURE 2: Femur x-ray showing bone transport with cable wires and pulleys.

FIGURE 3: Follow-up standing x-ray showing equal leg lengths following femur reconstruction and tibial lengthening with a motorized IM nail.

FIGURE 4: Follow-up lateral x-ray of the femur showing bone union following trifocal bone transport.

FIGURE 5: Follow-up clinical photo showing normal alignment and equal leg lengths.

CASE 1 CONTINUED

REFERENCES:

1. Kim HJ, Fragomen AT, Reinhardt K, Hutson J, Rozbruch SR. Lengthening of the femur over an existing intramedullary nail. *J Orthop Trauma.* 2011 Nov;25(11):681-4.
2. Kocaoglu M, Eralp L, Rashid HE, et al. Reconstruction of segmental bone defects due to chronic osteomyelitis with use of an external fixator and an intramedullary nail. *J Bone Joint Surg Am* 2006;88:2137-45.
3. Li Z, Zhang X, Duan L, et al. Distraction osteogenesis technique using an intramedullary nail and a monolateral external fixator in the reconstruction of massive post osteomyelitis skeletal defects of the femur. *Can J Surg.* 2009;52(2):103-111.
4. Paley D, Herzenberg JE, Paremain G, et al. Femoral lengthening over an intramedullary nail. A matched case comparison with Ilizarov femoral lengthening. *J Bone Joint Surg* 1997;79:1464-80.
5. Raschke M, Mann JW, Oedekoven G, et al. Segmental transport after unreamed intermedullary nailing. Preliminary report of a monorail system. *Clin Orthop Relat Res.* 1992;282:233-40.

AUTHOR DISCLOSURES:
Dr. Austin T. Fragomen is a consultant for Smith & Nephew and receives royalties from Small Bone Innovations.

CASE 2 CONTINUED

placed posterior and distal to the IM nail. At the end of distraction which was 3 months in this case, the IM rod was locked and the fixator was removed. This technique has been very effective for decreasing the time in external fixation and preventing fracture (3).

This patient was treated at the time of transition between hardcopy x-rays and the digital image system. He was part of a study (4) that examined both x-rays and determined that the digital image system at HSS was as accurate and more convenient for measuring leg lengths and deformity on long standing radiographs.

In summary, this case illustrates an excellent functional and aesthetic outcome following 20cm (8 inches) of limb lengthening in 3 stages. Adjuvant procedures including epiphysiodesis, quadricepsplasty, and gastrocnemius recession were all used to achieve limb salvage in this child. ■

REFERENCES:

1. Goldman V, McCoy TH, Harbison M, Fragomen AT, Rozbruch SR: Limb Lengthening in Children with Russell-Silver Syndrome: A Comparison to Other Etiologies. *J Children's Orthop* 2013, 7:151-6.
2. Khakharia S, Fragomen AT, Rozbruch SR. Limited Quadricepsplasty for Contracture during Femoral Lengthening. *Clin Orthop Rel Research* 2009 Nov; 467 (11):2911-7.
3. Mahboubian S, Seah M, Schachter L, Fragomen AT, Rozbruch SR: Femoral Lengthening with Lengthening Over a Nail has Fewer Complications than Intramedullary Skeletal Kinetic Distraction. Epub 2011 Dec 6. *Clin Orthop Rel Research* 2012, 470(4):1221-31.
4. Kahkaria S, Bigman D, Fragomen AT, Rozbruch SR: Comparison of PACS and Hardcopy 51-inch Radiographs for Measuring Leg Length and Deformity. *Clin Orthop Rel Research* 2011 Jan; 469(1):244-250.

AUTHOR DISCLOSURES:
Dr. S. Robert Rozbruch is a consultant for Smith & Nephew and receives royalties from Small Bone Innovations.

CASE 3 CONTINUED

In summary, this case illustrates an excellent functional and aesthetic outcome following reconstruction of a 21cm femur bone defect and additional limb lengthening. Bone transport over a nail with the cable wire and pulley technique was used to reconstruct the femur, and a motorized internal lengthening nail was used to lengthen the tibia 4cm. In total, limb salvage was achieved with extreme bone lengthening of 25cm (10 inches). ■

REFERENCES:

1. McCoy T, Kim HJ, Cross MB, Fragomen A, Healey JH, Athanasian EA, Rozbruch SR. Bone Tumor Reconstruction with the Ilizarov Method. *J Surg Oncology* 2013, 107:343-352.
2. Tsuchiya H: Reconstruction after bone tumor resection. in Rozbruch SR, Ilizarov S: *Limb Lengthening and Reconstruction Surgery*, Informa Healthcare USA Inc., New York, 2007
3. Eralp L, Kocaoglu M, Rashid H: Reconstruction of segmental bone defects due to chronic osteomyelitis with use of an external fixator and an intramedullary nail. Surgical technique. *J Bone Joint Surg* 2007, 89 suppl 2 Pt.2: 183-95.
4. Weber M, Siebert CH, Heller KD, Birnbaum K, Kaufmann A: Segmental transport utilizing cable wires and pulleys mounted on an Ilizarov frame- A new technique. *J Bone Joint Surg* 1999; 81 (Suppl B):148.
5. Hernigou P, Poignard A, Beaujean F, Rouard H. Percutaneous autologous bone-marrow grafting for nonunions. Influence of the number and concentration of progenitor cells. *J Bone Joint Surg Am.* 2005;87:1430–7.

AUTHOR DISCLOSURES:
Dr. S. Robert Rozbruch is a consultant for Smith & Nephew and receives royalties from Small Bone Innovations.

HOSPITAL
FOR
SPECIAL
SURGERY

150 YEARS

535 East 70th Street
New York, NY 10021
www.hss.edu/complexcases

Grand Rounds from HSS

MANAGEMENT OF COMPLEX CASES

DESIGN/PRODUCTION:
Marcia Ennis | Director, Education Publications & Communications
Paggie Yu | Assistant Designer, Education Publication & Communications

Hospital for Special Surgery is an affiliate of NewYork-Presbyterian Healthcare System and Weill Cornell Medical College.

Each author certifies that Hospital for Special Surgery has approved the reporting of this case and that all investigations were conducted in conformity with ethical principles of research.

Find Hospital for Special Surgery on the web! **www.hss.edu/cme**