

# Knee Fusion: Indications & Technique

Advanced TSF Course, Memphis, TN; August 2-3, 2013

## **S. Robert Rozbruch, MD**

Chief, Limb Lengthening & Complex Reconstruction Service  
Professor of Clinical Orthopedic Surgery



LIMB **LENGTHENING**.COM

# Indications

- ◉ Destruction of knee
  - TKR not option
    - Risk of infection
    - Poor soft tissue
    - Arthrofibrosis
  - Failed TKR
    - Multiple failures
    - Poor soft-tissues
    - Loss of extensor mechanism
    - Stiff knee
    - Virulent organism

# Technical

- Frame versus nail
- Gradual versus acute shortening
- Bone lengthening vs. Shoe lift
  - Femur vs. tibial lengthening

# Options/ algorithm

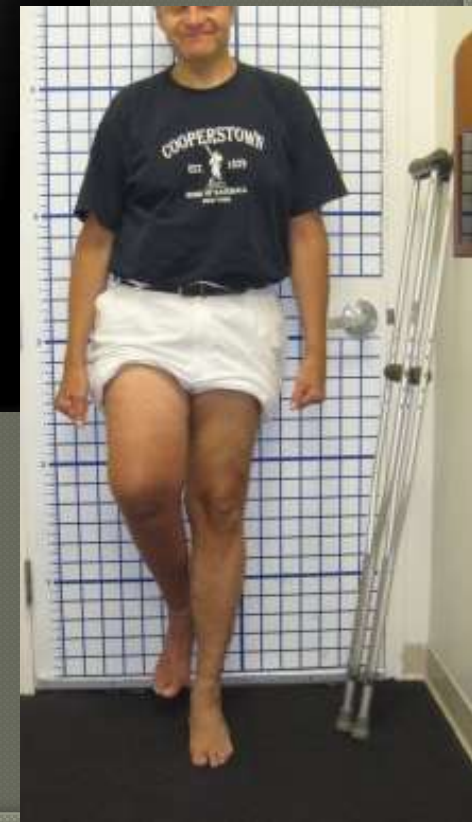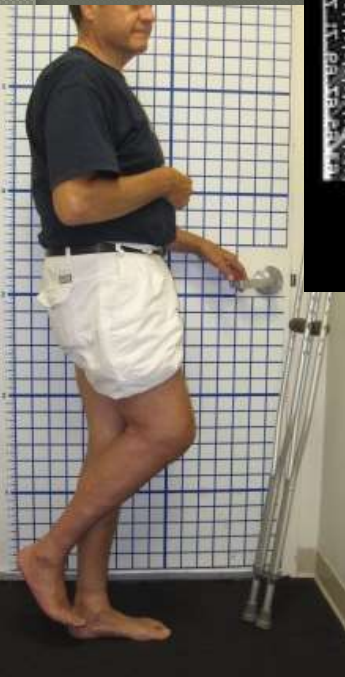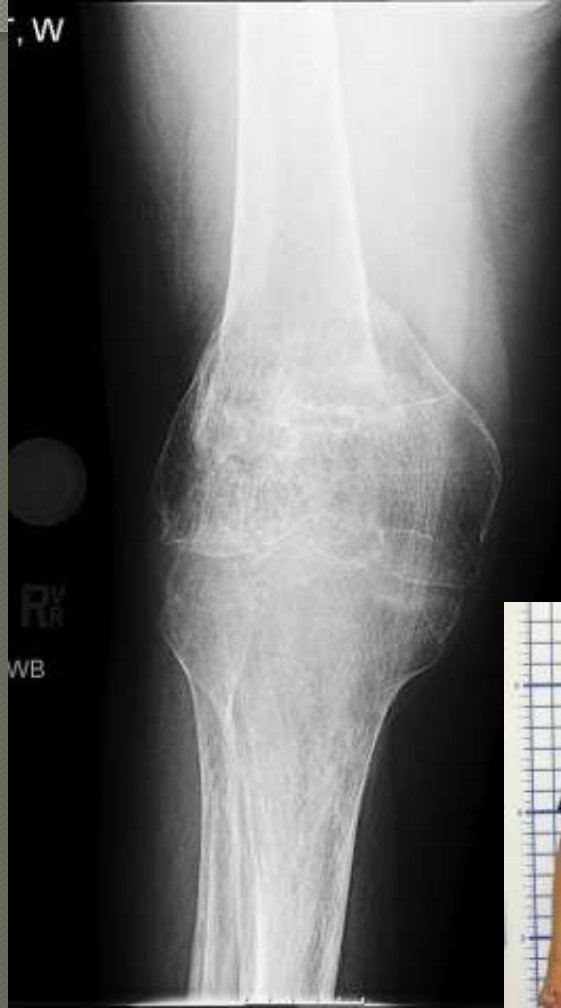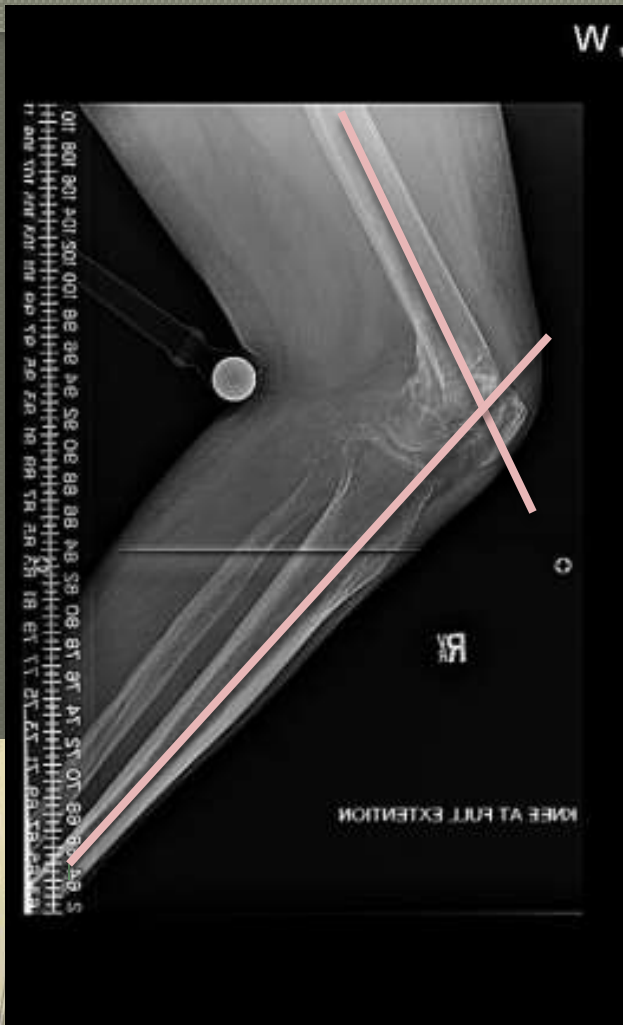
## ◉ IM nail

- With antx cement
- Staged lengthening with nail

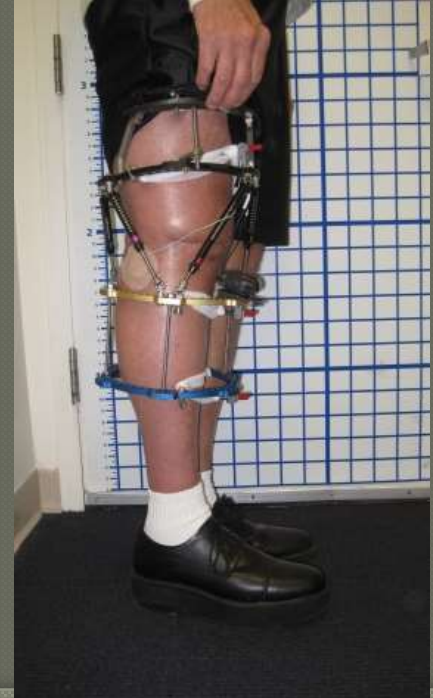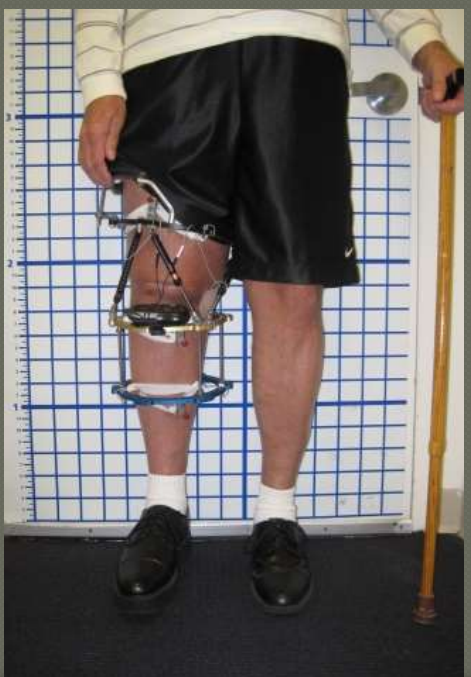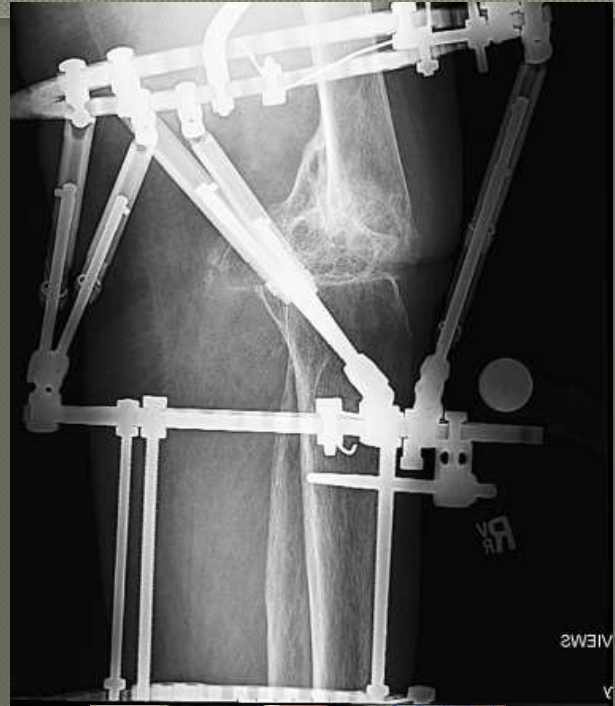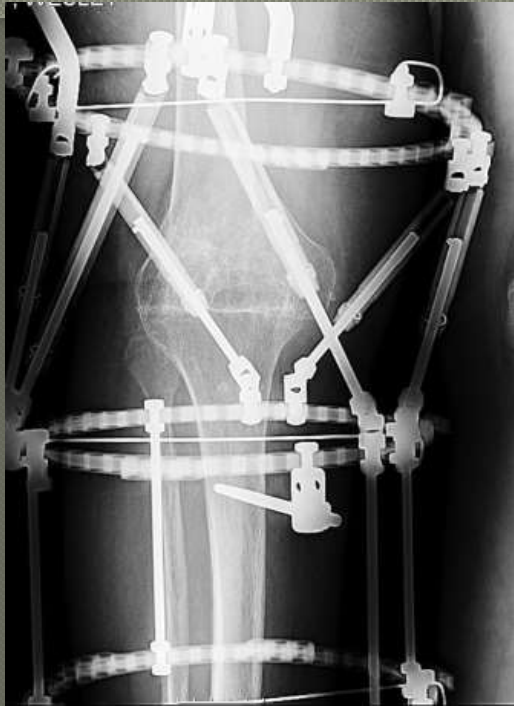## ◉ Circular frame

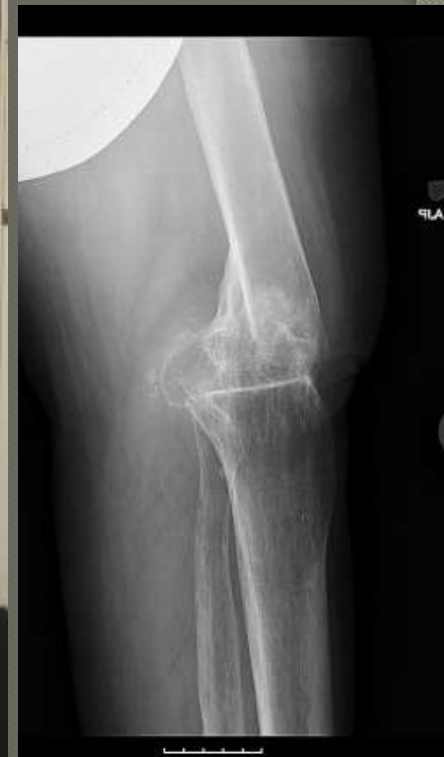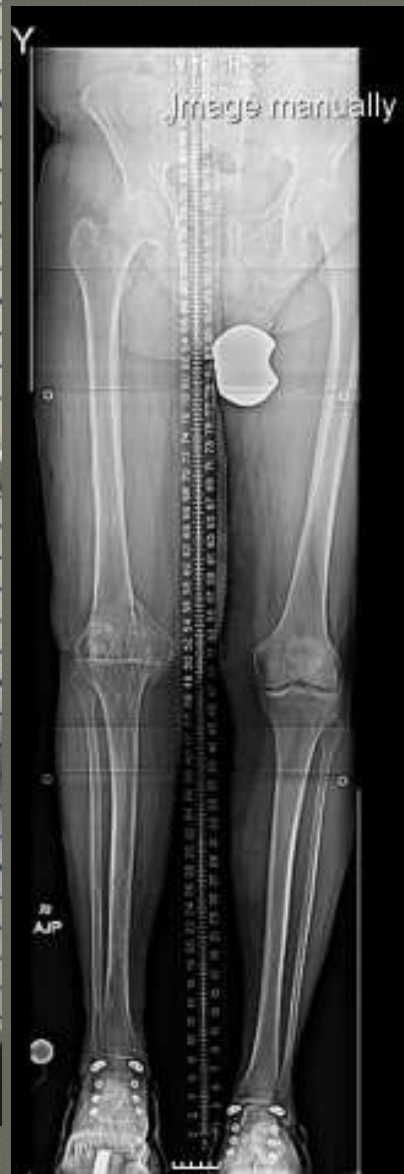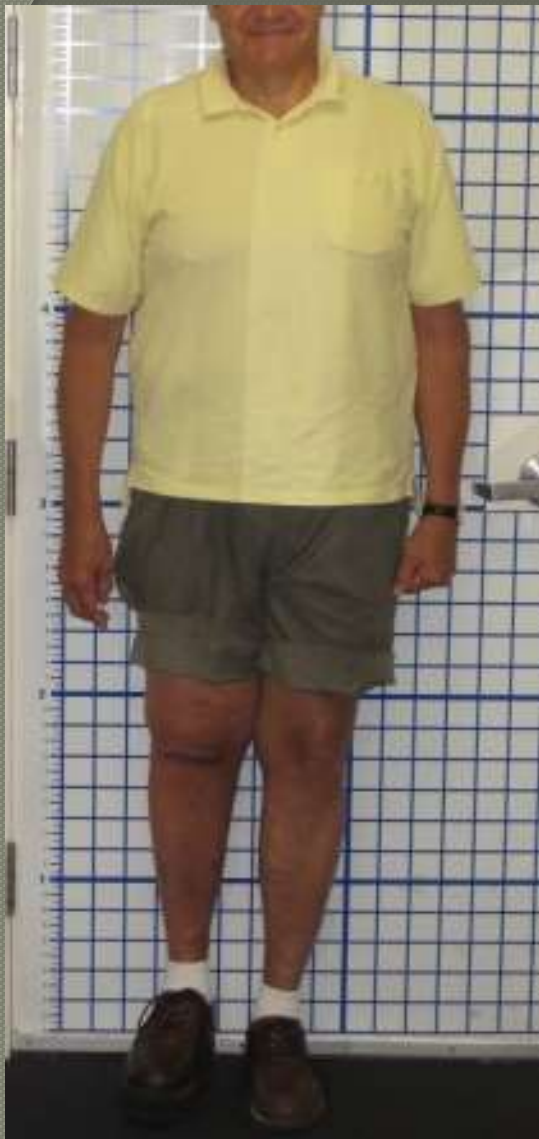- Acute shortening
- Gradual shortening
- Limb lengthening/ transport

## ◉ Staged IM nail after frame



55 y/o M  
Femur condyle fracture 3 yrs ago  
Pain, RSD, contracture  
60 deg flexion contracture





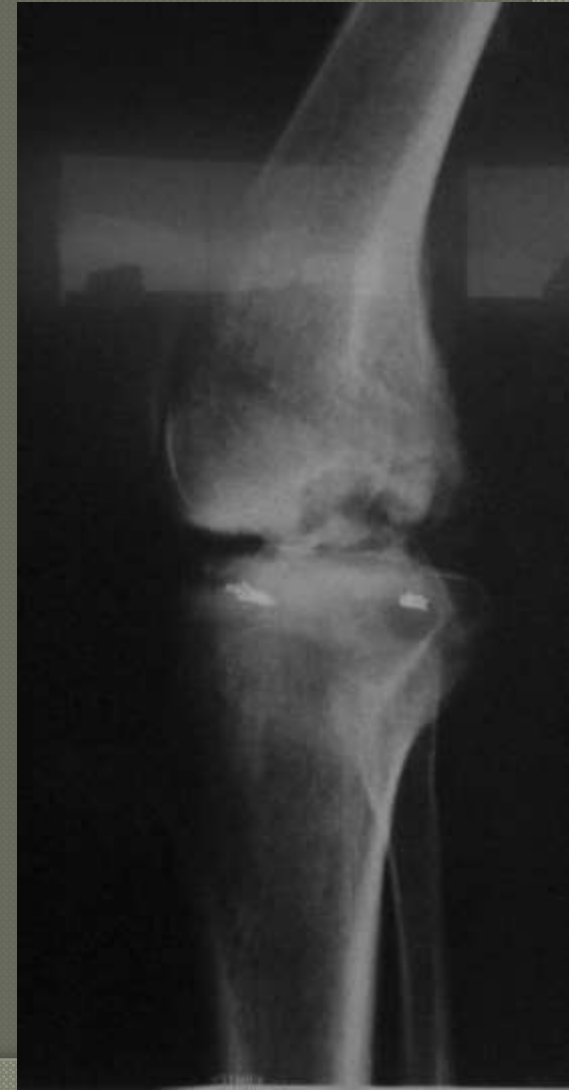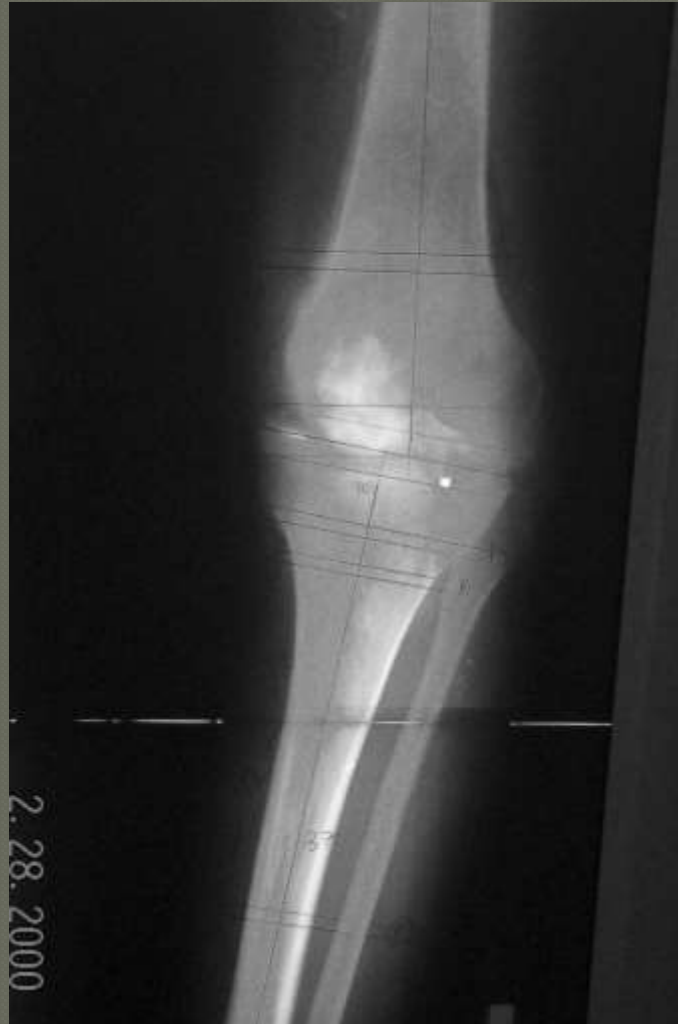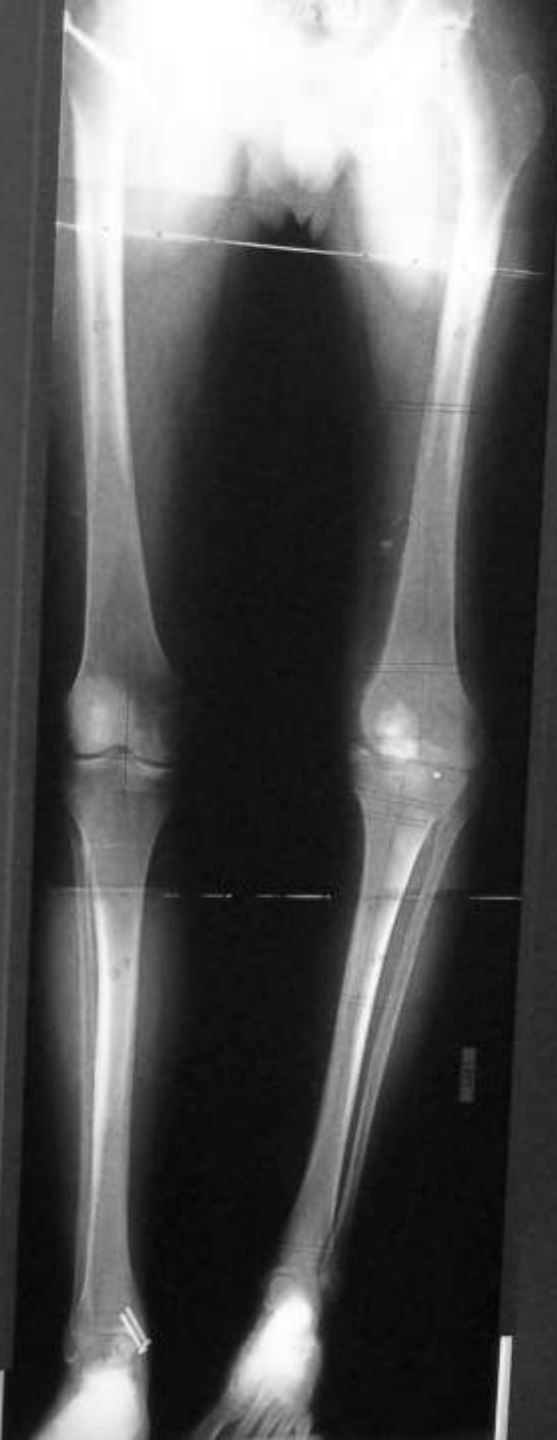Aim for 10 deg flexion  
And 1.5 cm shortening



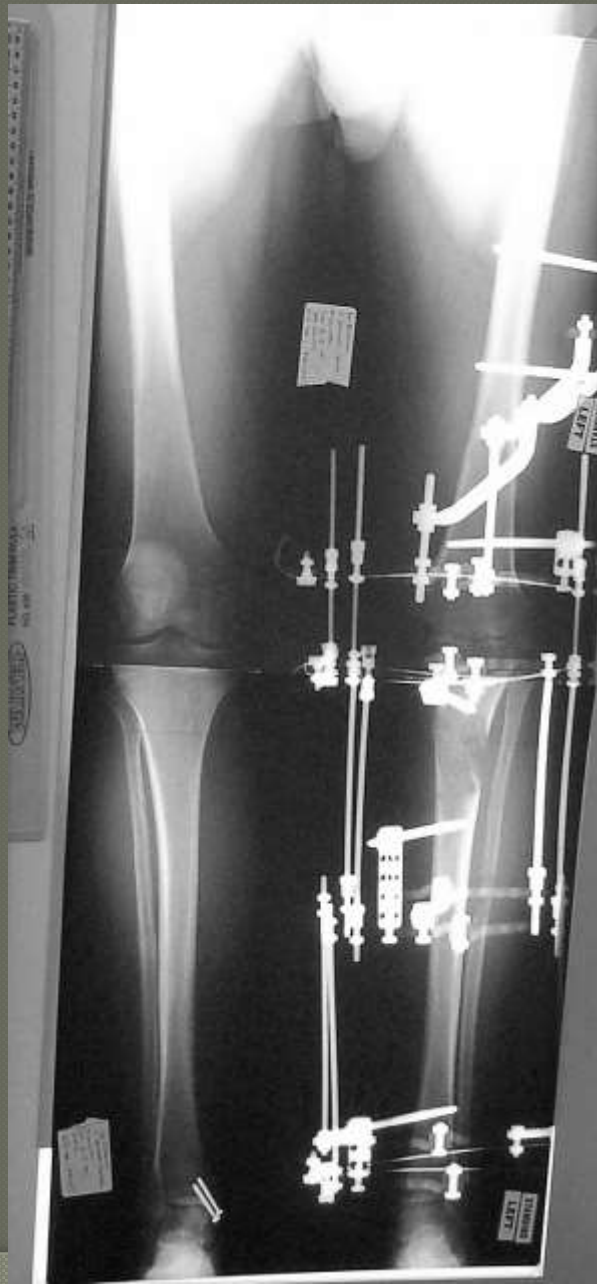

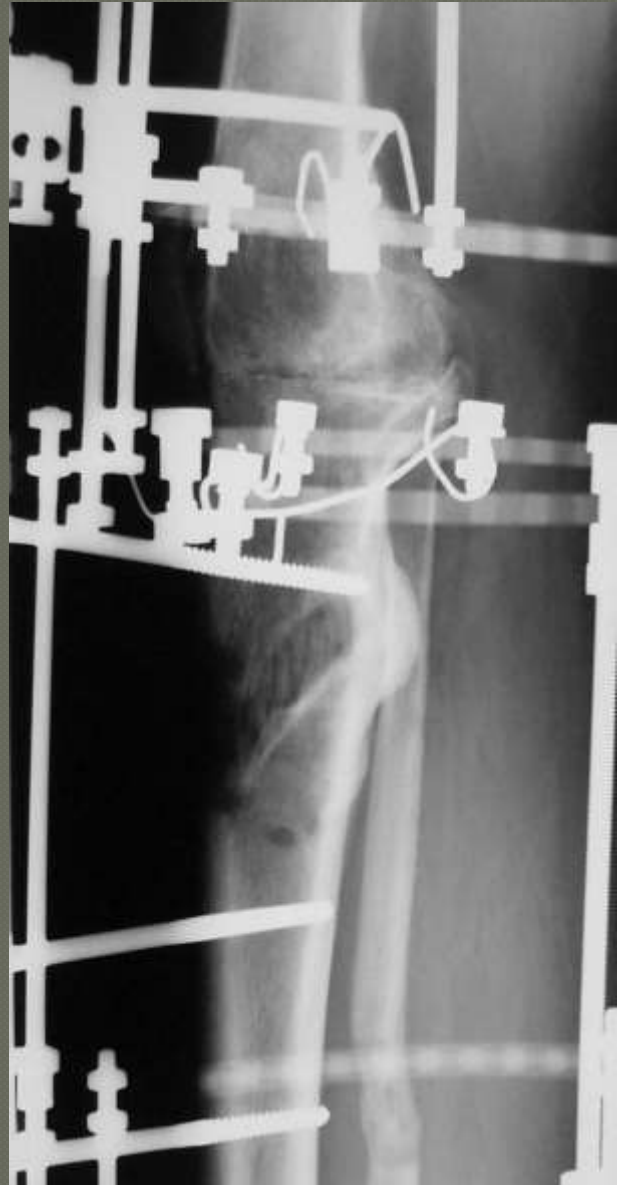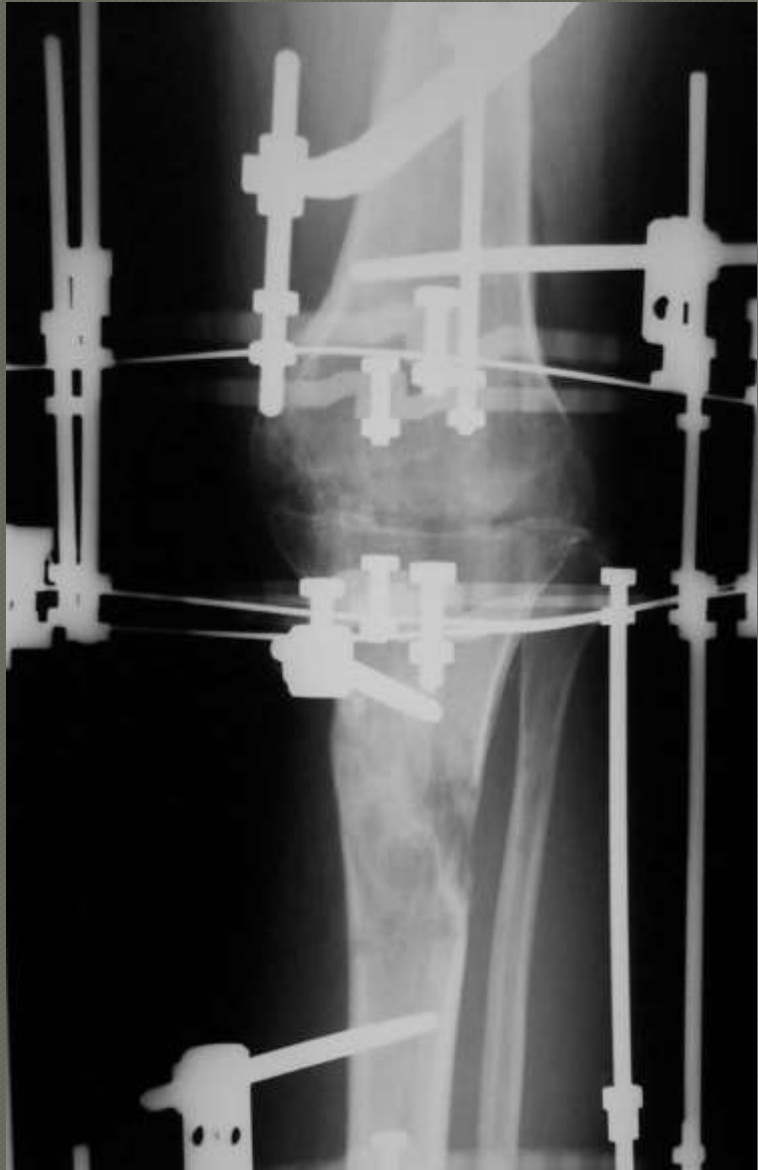# Daniel, preop

Septic arthritis and  
osteomyelitis  
post trauma

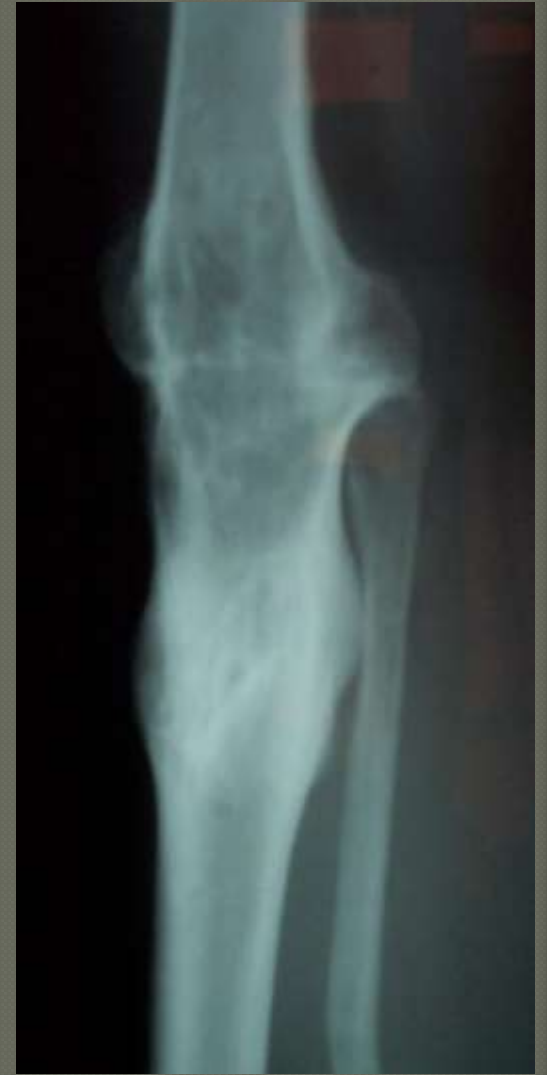
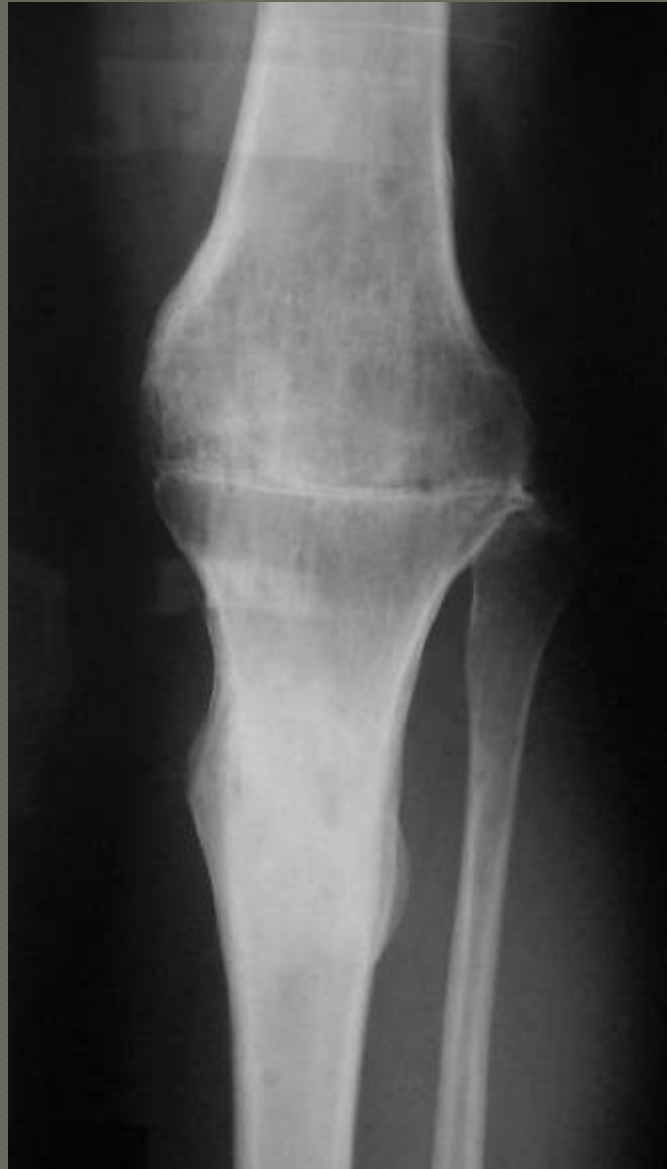
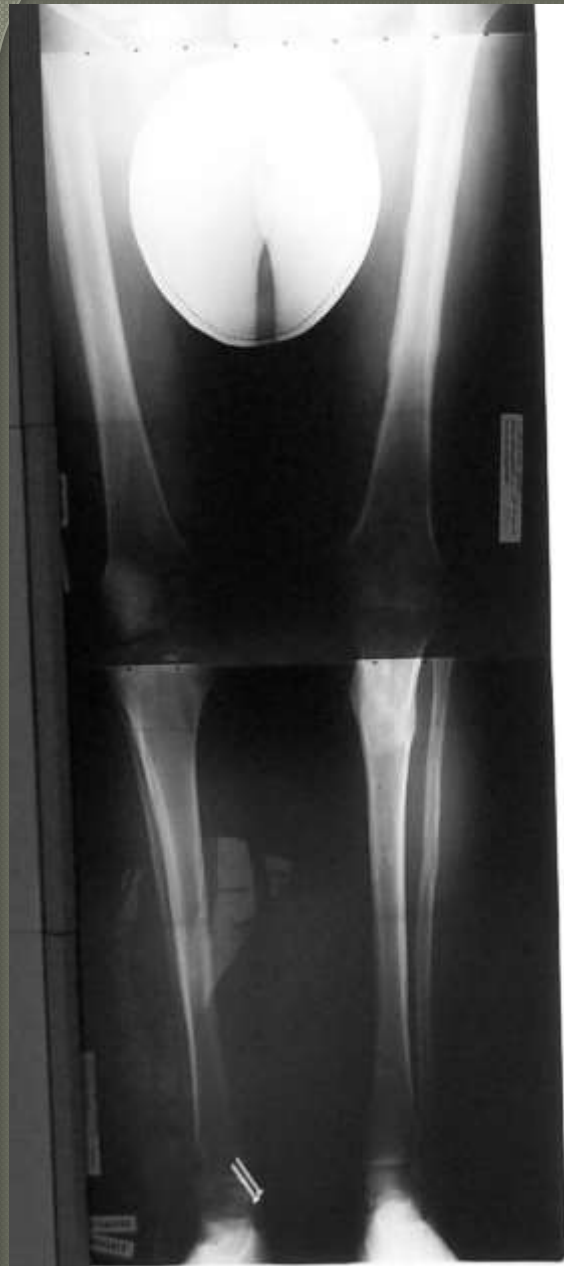# End Distraction, 3months, 4 cm lengthening



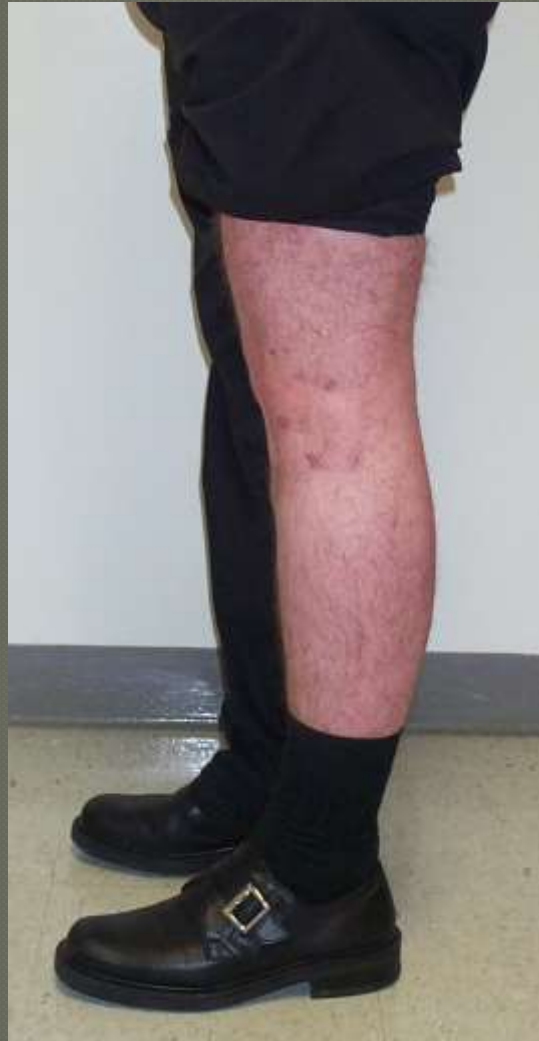

2 years, with desired 1.5 cm shortening

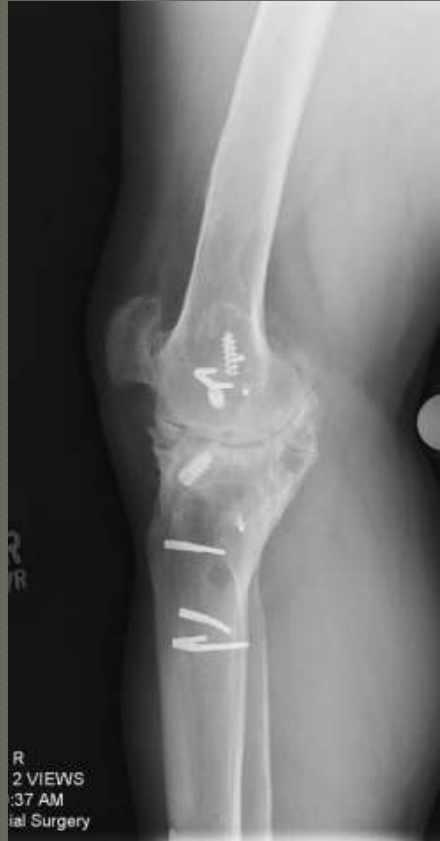
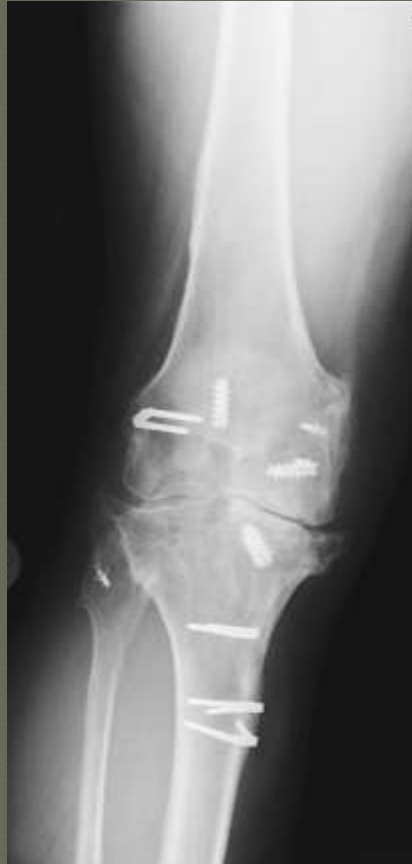
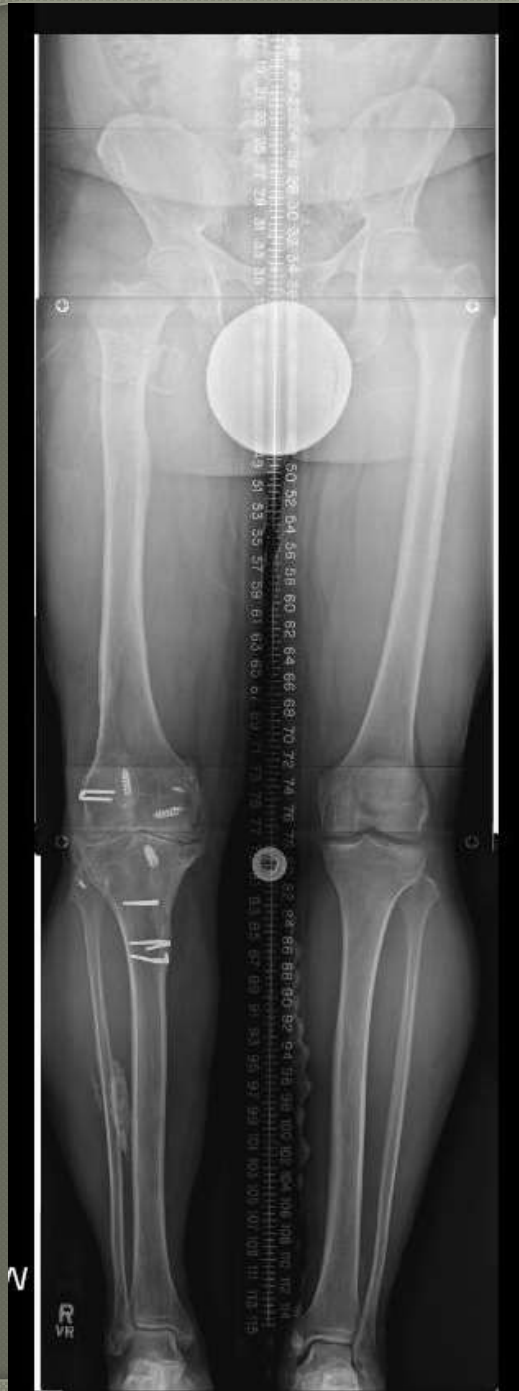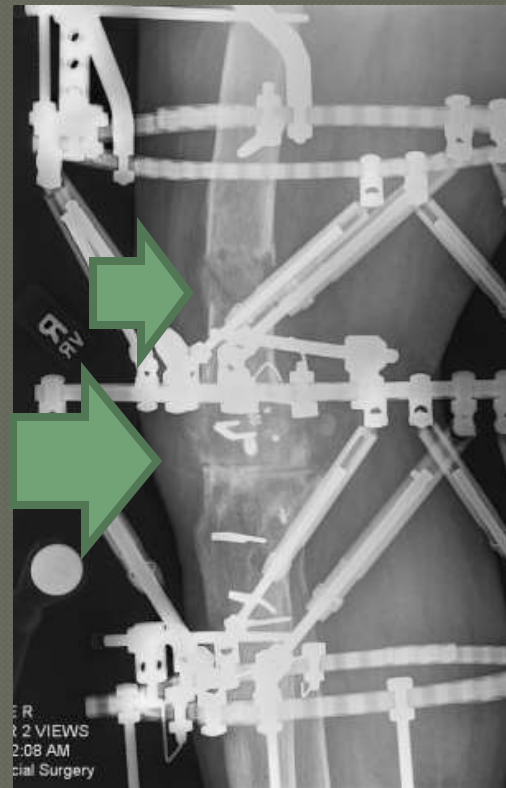



15 months

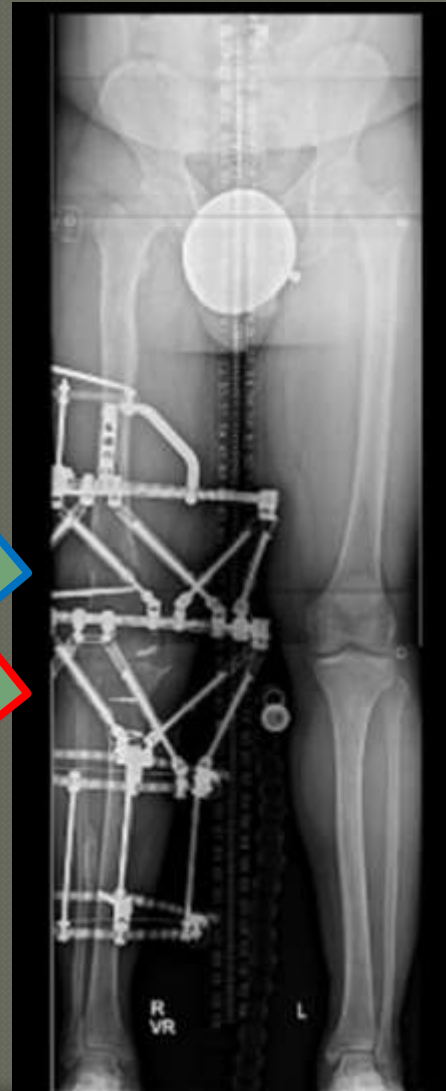
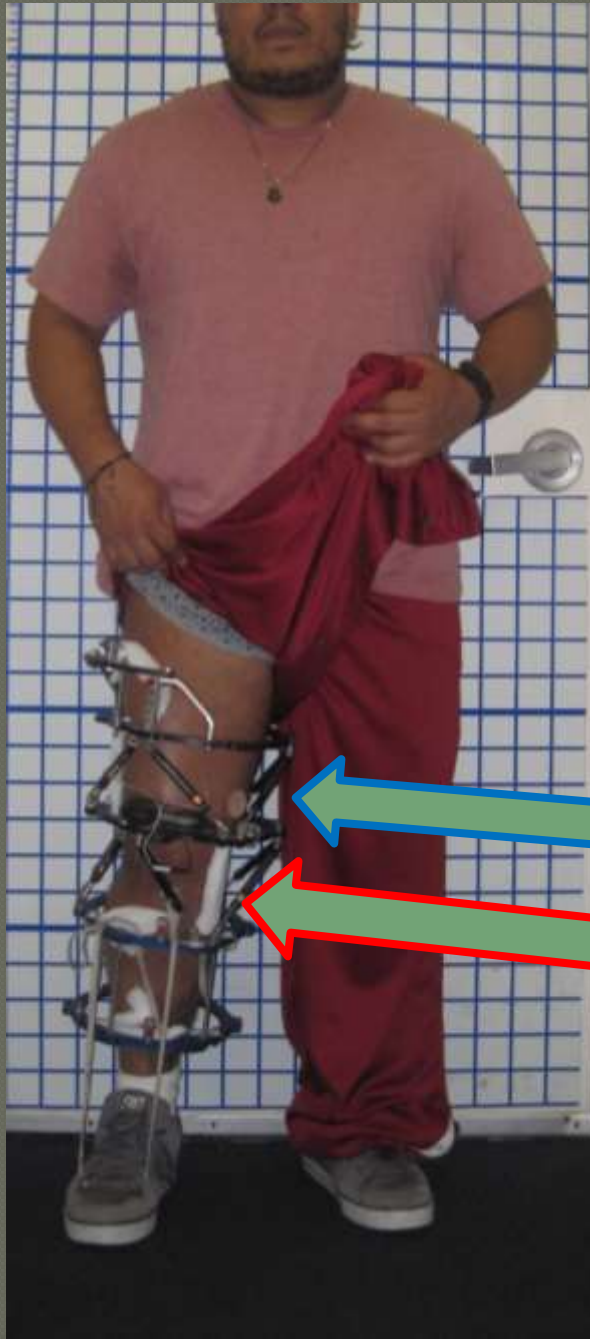


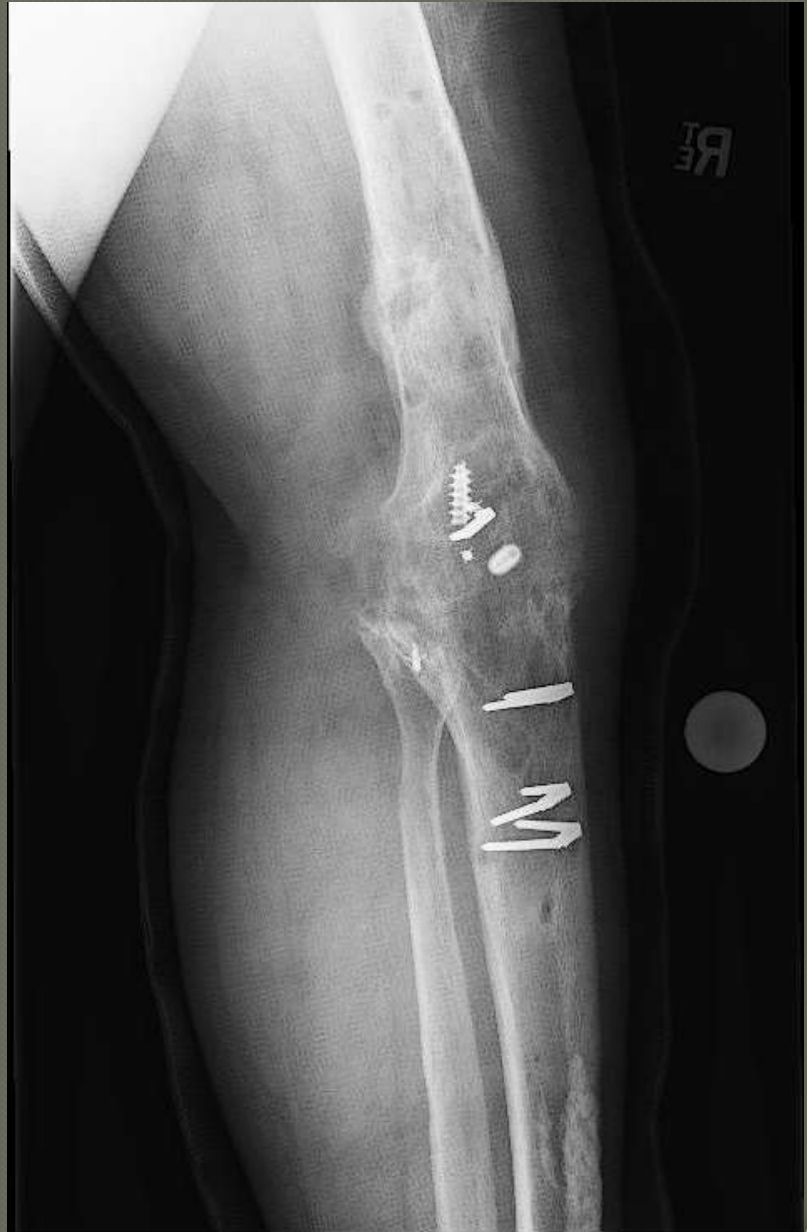
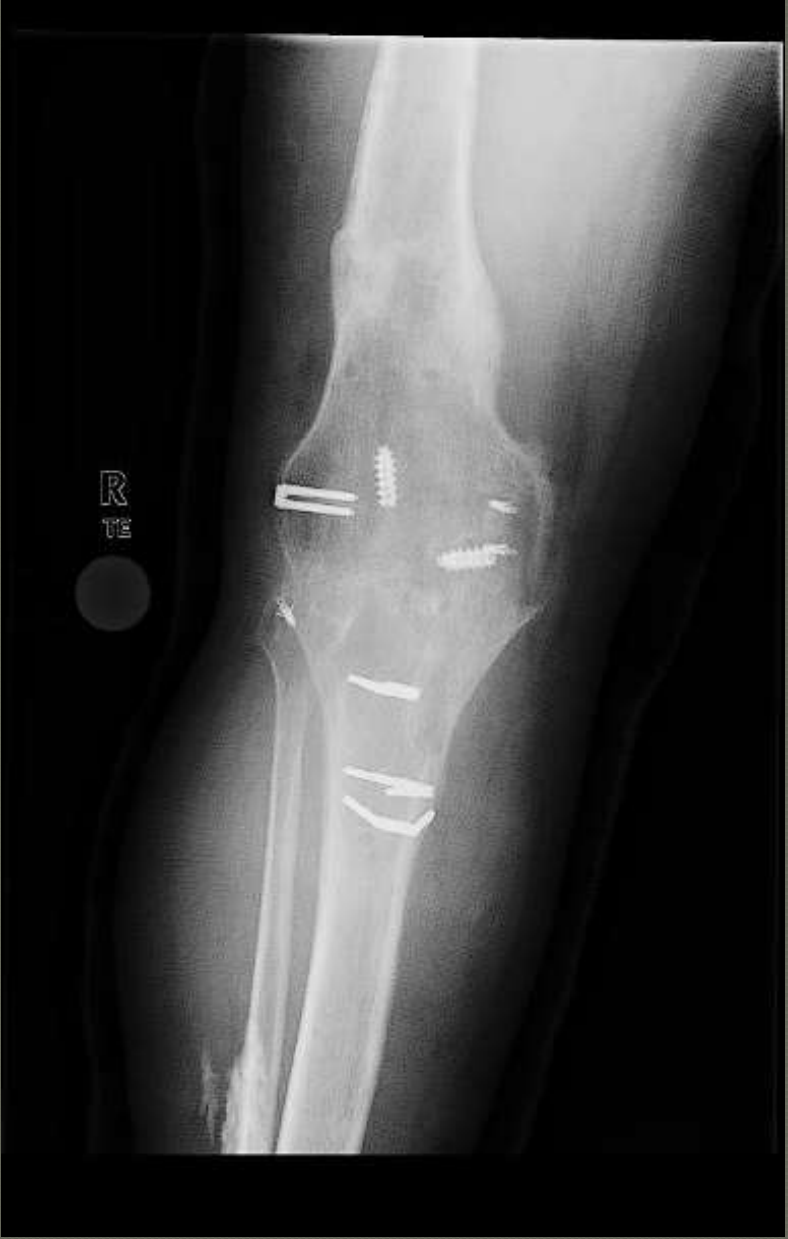








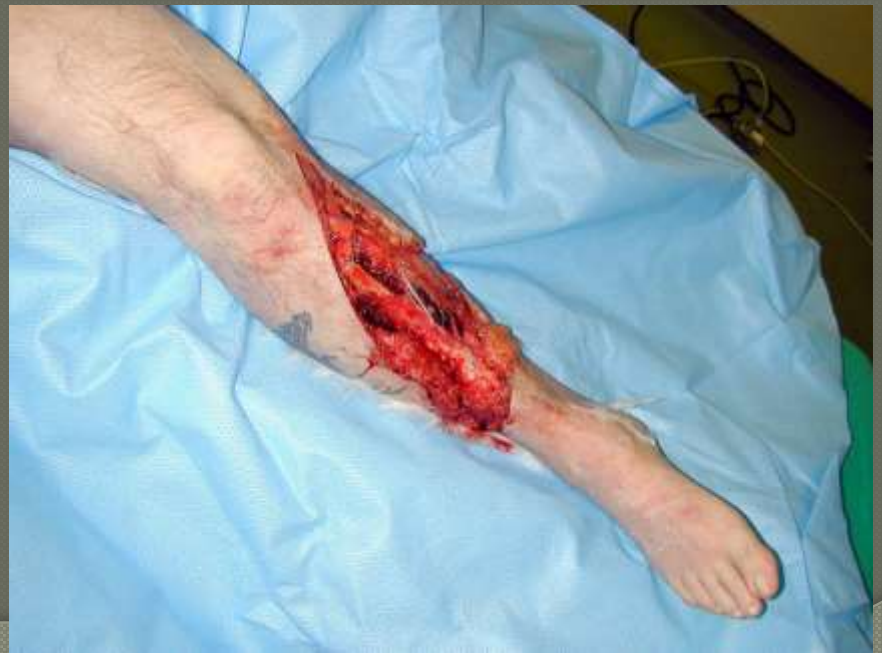
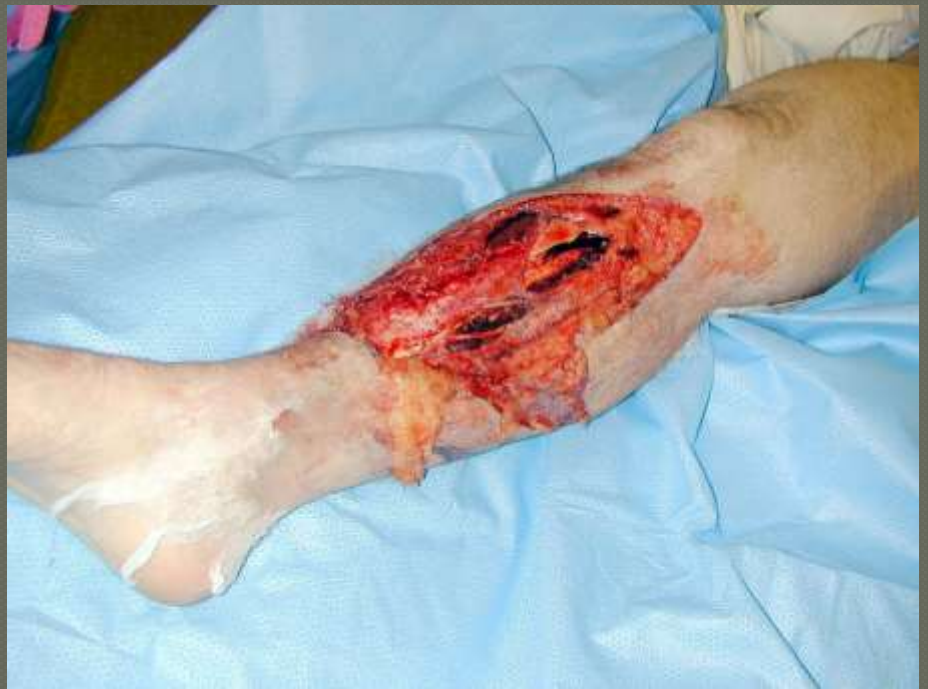
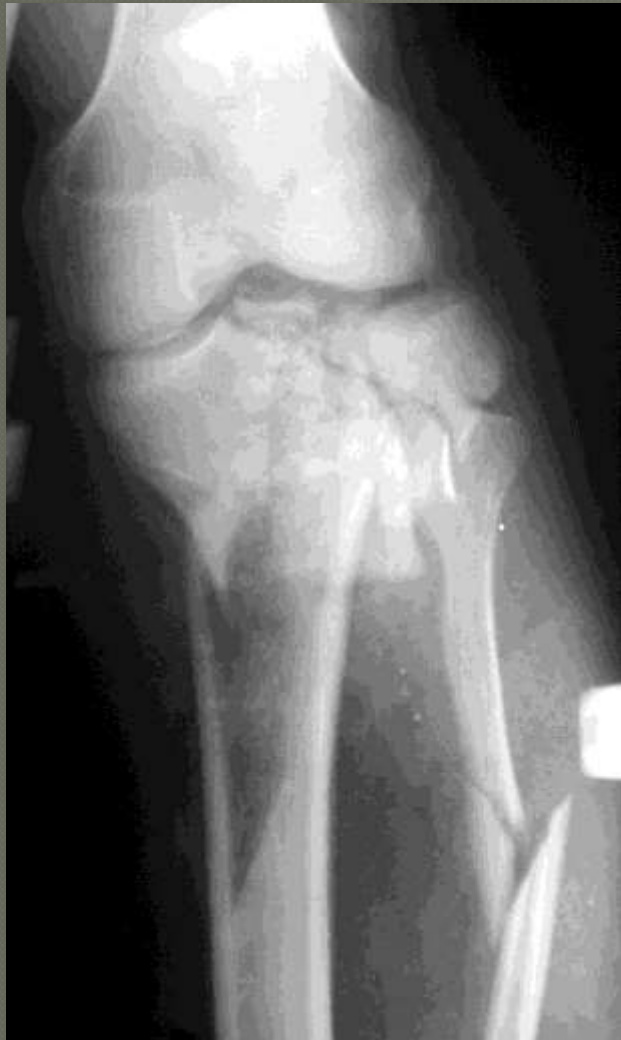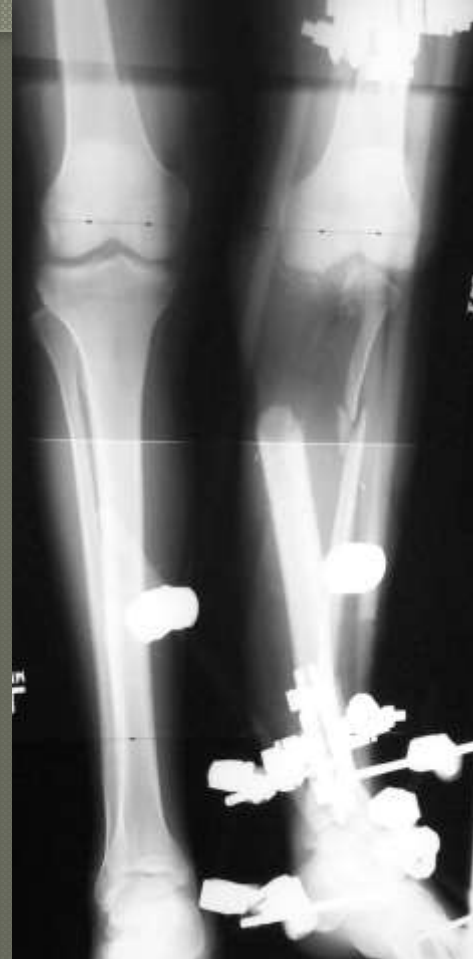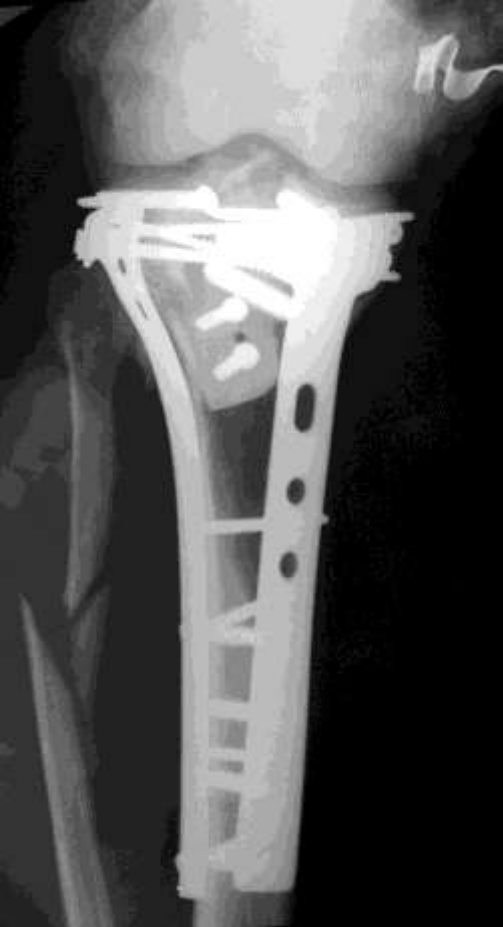STEVEN: case 2

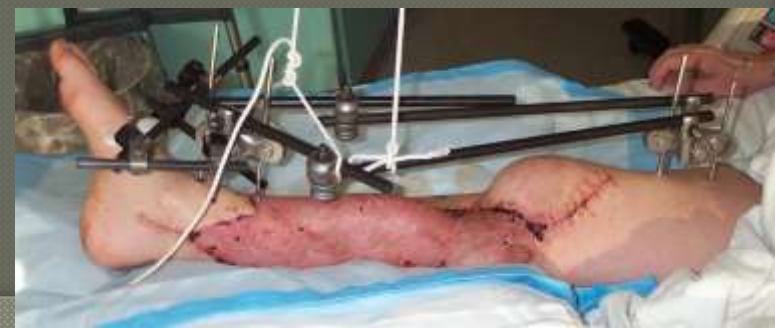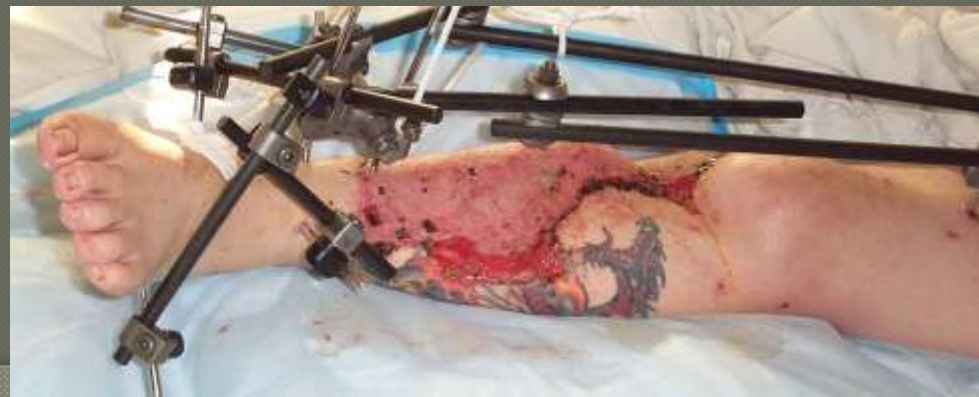INJURY

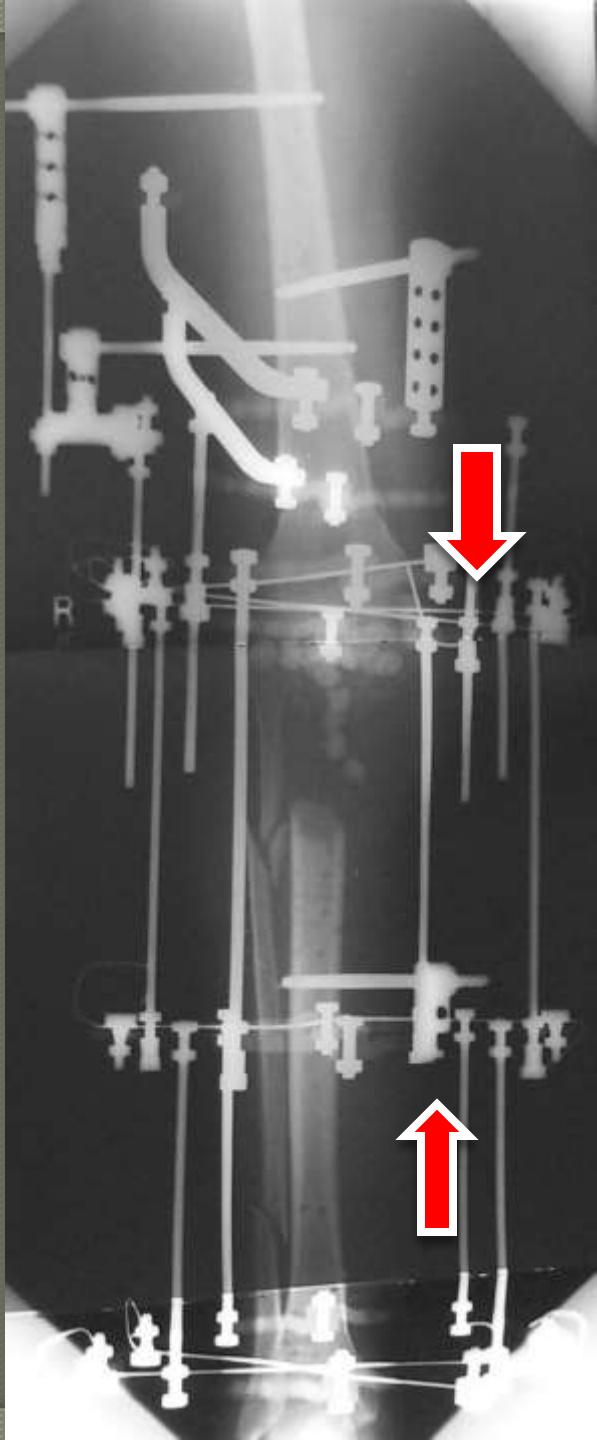
MCA vs sanitation truck





Preop  
12 cm defect

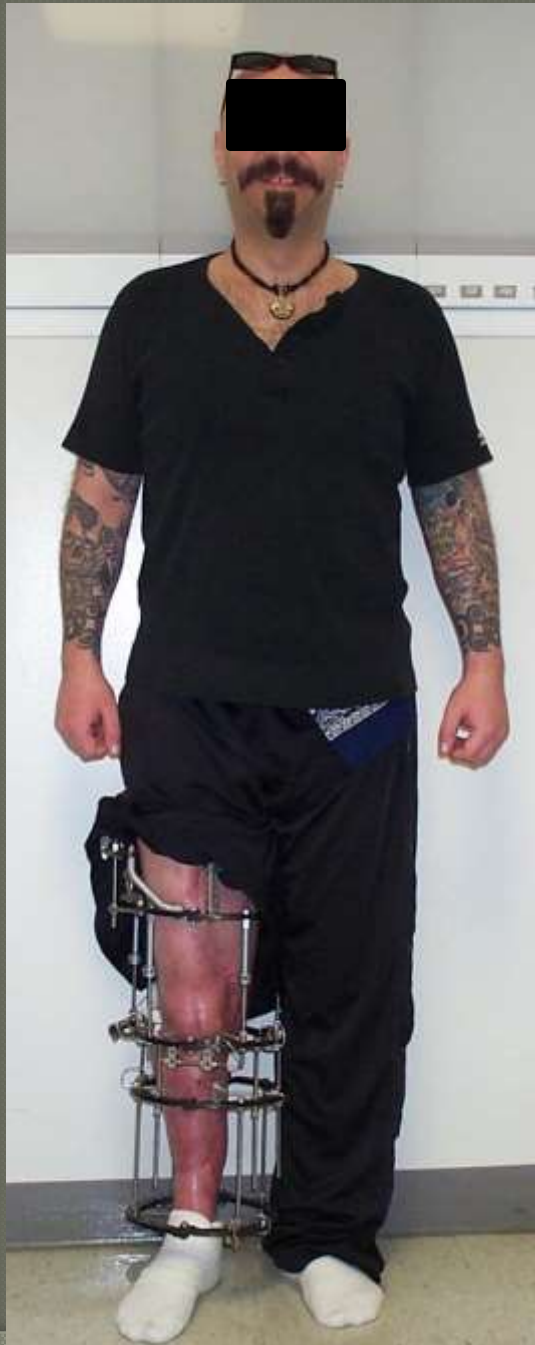



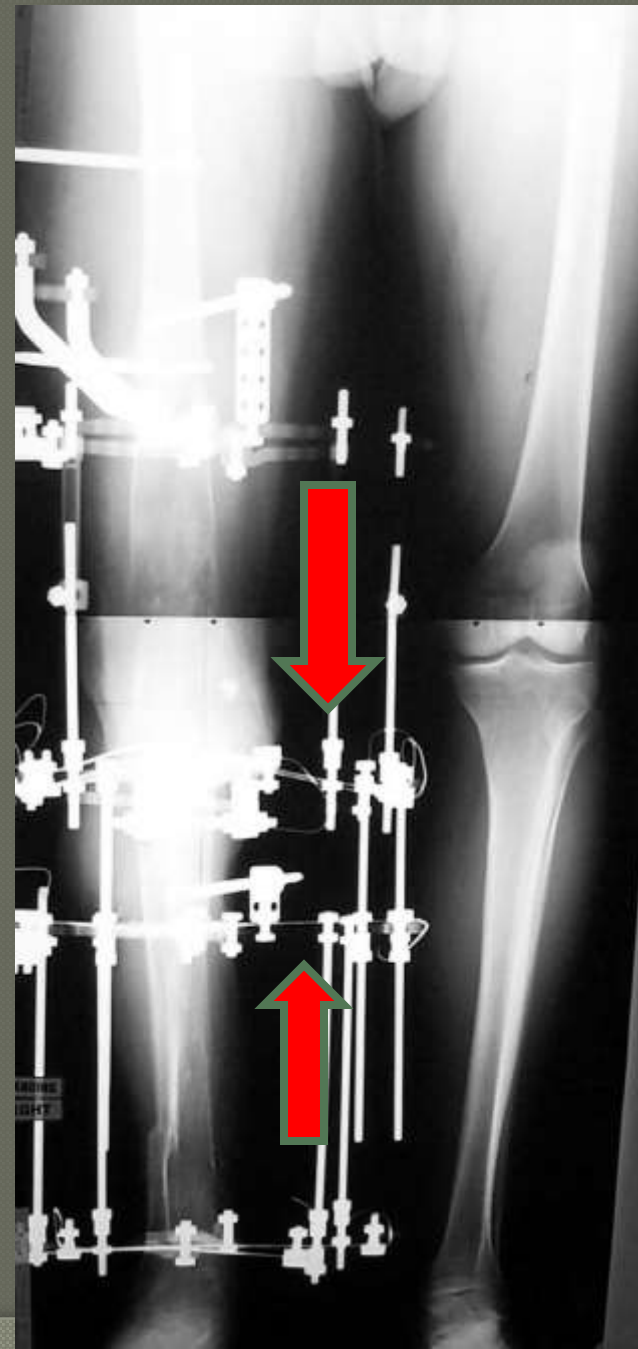
Postop #1

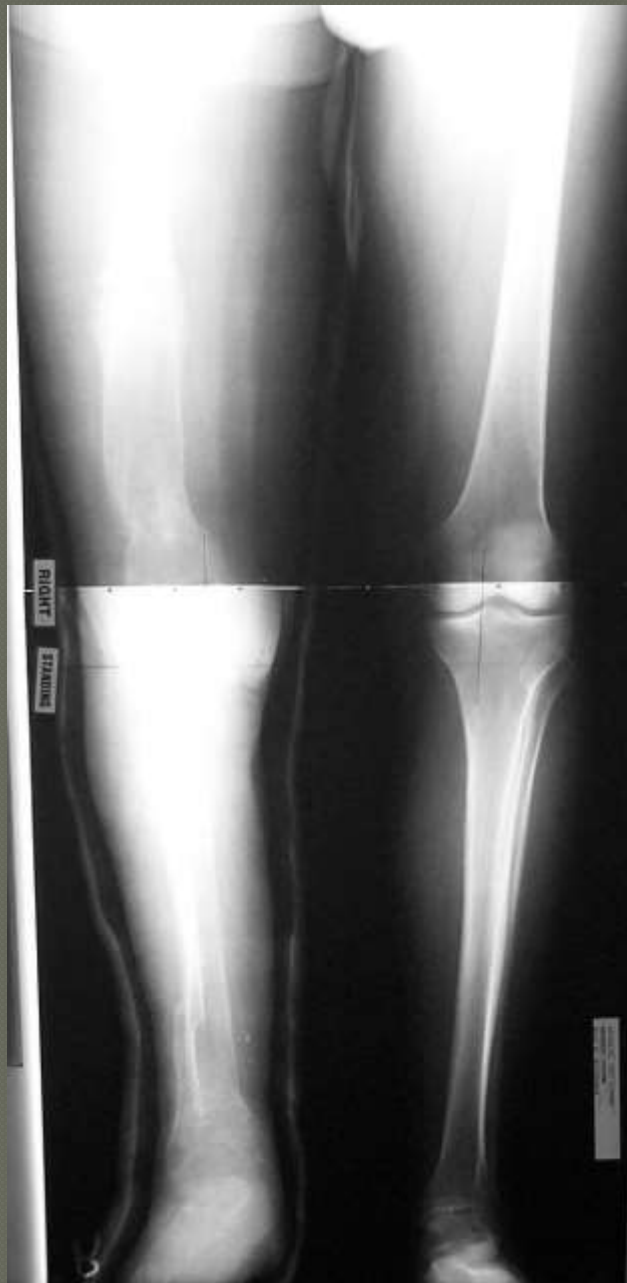
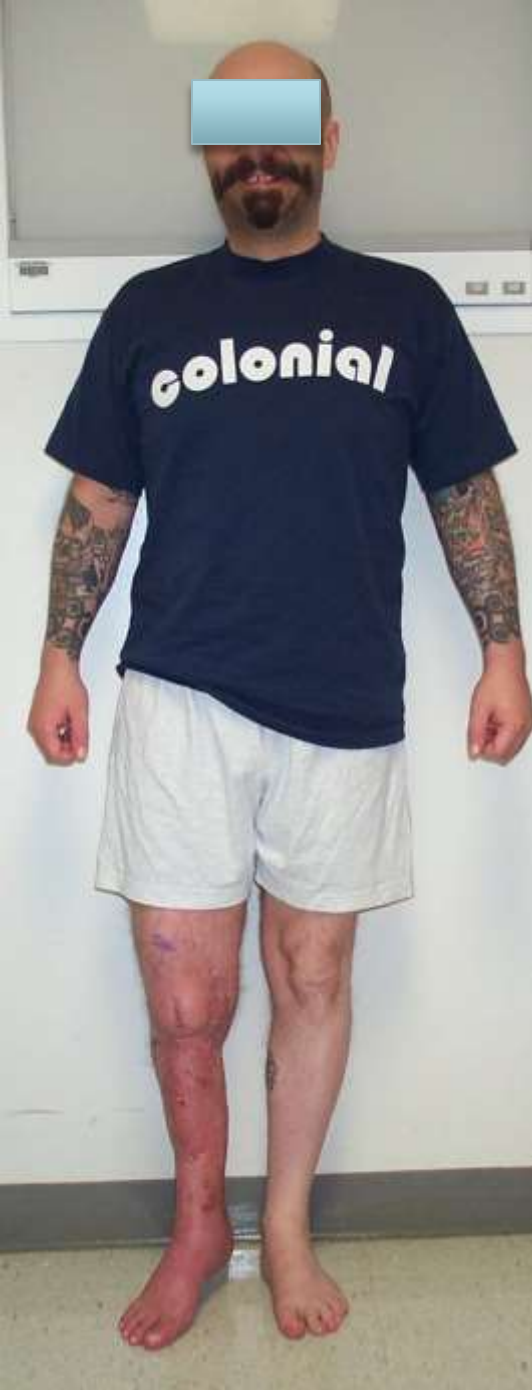
10 months



12 months

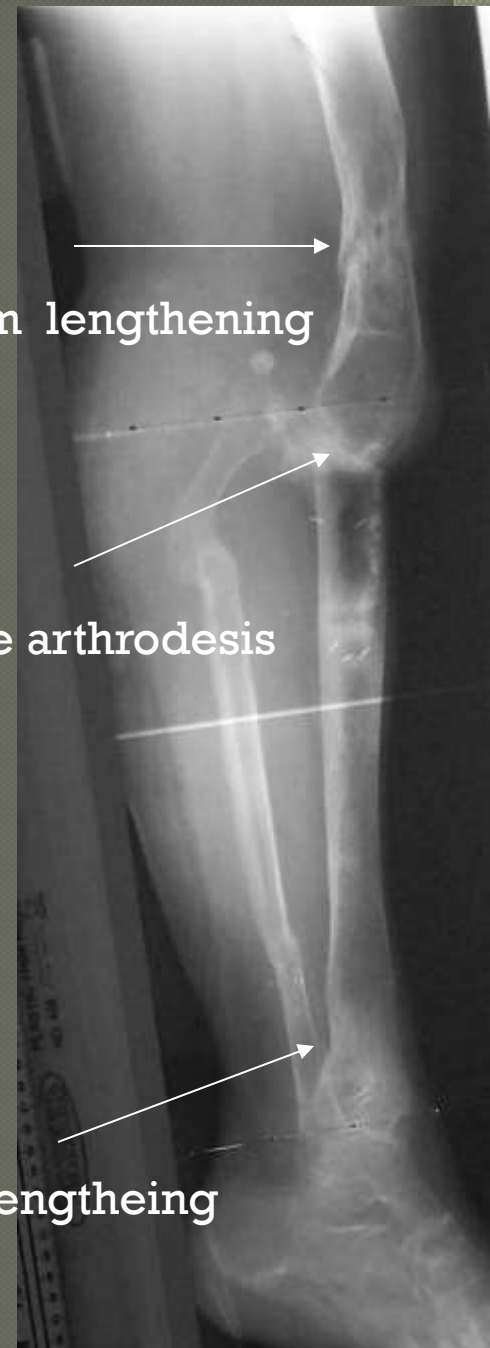



7 cm lengthening

Knee arthrodesis

4.5 cm lengthening



## Knee Arthrodesis With Simultaneous Lengthening Using the Ilizarov Method

S. Robert Rozbruch, MD, Svetlana Ilizarov, MD, and Arkady Blyakher, MD

**Objective:** To determine whether knee arthrodesis with simultaneous lengthening using the Ilizarov method for a nonreconstructable knee joint with bone loss and infection is a successful salvage procedure.

**Design:** Retrospective review of patients.

**Setting:** University hospital-based orthopedic practice.

**Patients:** From 1999 to 2001, 4 consecutive patients with a nonreconstructable knee joint, bone loss, and infection after trauma underwent knee arthrodesis with simultaneous lengthening.

**Intervention:** Arthrodesis of the knee with simultaneous limb lengthening through an osteotomy of the tibia and/or femur and the use of an Ilizarov frame. External bone stimulation was used at the knee arthrodesis site and the lengthening sites. Application of this device began during the early distraction phase and continued until frame removal.

**Main Outcome Measures:** Bony union at the arthrodesis and bone lengthening sites, alignment of the lower extremity, limb length discrepancy, infection, pain, and outcome scales (SF-36 scores and American Academy of Orthopedic Surgeons lower limb modules).

**Results:** Bony union of the knee arthrodesis and lengthening sites and good alignment were achieved in all 4 patients. Mean amount of lengthening was 5.4 cm (range 2.5–11.5 cm). Average time in frame was 11 months (range 6–17 months). Limb length discrepancy after treatment averaged 1.8 cm (range 0.8–3.7 cm). Mean duration of follow-up after frame removal was 35 months (range 28–48 months). At follow-up, infection had not recurred, pain was not present, and assistive devices were not needed for ambulation. Average SF-36 scores improved in all 8 categories, and the average American Academy of Orthopedic Surgeons lower limb modules improved from a mean of 33 (range 11–37) to a mean of 68 (range 51–76).

**Conclusion:** Knee arthrodesis with simultaneous lengthening can be performed successfully using the Ilizarov method. It enables surgeons to optimize limb length during knee arthrodesis. The use of

external fixation and the avoidance of internal implants may be advantageous in the presence of or history of infection. The Ilizarov frame provides stability that allows weight bearing during treatment.

**Key Words:** bone defect, bone transport, knee arthrodesis, lengthening, external fixation, infection, Ilizarov

(J Orthop Trauma 2005;19:171–179)

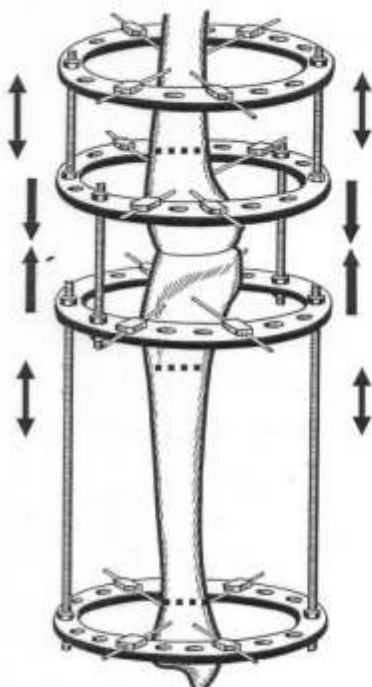
Arthrodesis of the knee is a salvage procedure that may be indicated for a young patient with a nonreconstructable knee joint, bone loss, and infection. Different techniques of knee fusion have been proposed, such as intramedullary nailing, plating, or external fixation with uniplanar or multiplanar (circular) frames.<sup>1–4</sup>

The presence or history of infection makes internal fixation and bone grafting less desirable and carries an increased risk of recurrence of infection.<sup>5–8</sup> Knee arthrodesis in the setting of extensive bone loss would result in unacceptable limb shortening and difficulty with bone apposition. Persistent infection and loss of bone stock have been associated with failures of arthrodesis, and above-knee amputation often is recommended for patients with these conditions.<sup>9</sup>

Many studies of knee arthrodesis using uniplanar external fixation, circular external fixation, or intramedullary nailing have been conducted. However, the practice of simultaneous limb lengthening has been only sporadically noted in case reports.<sup>7–20</sup> The Ilizarov method offers a comprehensive approach for dealing with infection, bone loss, and knee joint destruction by using knee arthrodesis and simultaneous bone lengthening with dynamic circular external fixation (Fig. 1).<sup>5,8–13</sup> The purpose of this study was to evaluate our treatment of these most challenging cases. Our goal was to determine whether this comprehensive approach is a successful method of treatment in terms of patient function, resolution of pain, eradication of infection, and achievement of normal limb alignment, optimal limb length, and bony union.

### MATERIALS AND METHODS

Between 1999 and 2001, 4 patients at our institution underwent a knee arthrodesis procedure and simultaneous lengthening using the Ilizarov method (Table 1). The patients



**FIGURE 1.** Schematic illustration of an Ilizarov construct for knee arthrodesis and lengthening. Note the compression across the arthrodesis site and distraction at osteotomy sites (dotted lines) of the distal femur, proximal tibia, and/or distal tibia.

were all men with an average age of 39 years (range 33–45 years), average height of 71 inches (range 66–72 inches), and average weight of 191 pounds (range 145–230 pounds). All patients had a history of trauma, multiple surgical operations, and infection. Three of the patients had sustained proximal tibial fractures, and 1 had an anterior cruciate ligament tear. As a result of injury, infection, and surgical operations, these patients presented with an average lower extremity longitudinal deficiency of 7.2 cm (range 4–14.5 cm) from shortening and

bone loss. All patients had been offered an above-knee amputation before receiving our treatment. The average interval from index trauma to knee arthrodesis was 2.9 years (range 6 weeks–9 years). The patients had undergone an average of 9.5 previous surgical operations (range 3–16 operations). Soft tissue was compromised about the knee area in all patients, and 3 of them had required a previous free-flap procedure. One patient presented to us with an intramedullary rod and a cement spacer. Two patients had varus deformity of the knee; 1 of the 2 had a contralateral foot drop, and the other had a contralateral posttraumatic hip arthritis and flexion contracture. Two patients were smokers; 1 of them later quit smoking during treatment. One patient was nonambulatory, and 3 were using crutches for ambulation. Two patients had active infection with positive intraoperative cultures. Two other patients had history of recent infection. No patient had diabetes.

Bifocal compression-distraction osteosynthesis technique<sup>12</sup> was used for 3 patients, with lengthening performed at the proximal tibial osteotomy site (Fig. 2). Two of the 3 patients underwent amputation for lengthening 8 and 11 weeks, respectively, after the arthrodesis procedure. Bone transport was performed in 1 patient with 14.5 cm of bone loss in a trifocal fashion,<sup>13</sup> and bone lengthening was accomplished through femoral and distal tibial osteotomies with simultaneous shortening across the bone defect. This patient underwent planned bone grafting at the docking site (Fig. 3).

Two patients had positive intraoperative cultures and received a 6-week course of intravenous antibiotics. The other 2 patients had a recent history of infection that had been treated with antibiotics, and their intraoperative cultures showed no bacterial growth. They were not given another course of intravenous antibiotics (Table 1). External bone stimulation was used for all patients. It was started during the early distraction phase and continued until bony healing was achieved and frame removal performed. Ultrasound (Exogen; Smith & Nephew, Memphis, TN) was used for 3 patients, and capacitive coupling electrical stimulation (EIBI, Parsippany, NJ) was used for 1. This was done empirically to enhance bone healing at the arthrodesis site and at the lengthening sites in this challenging group of patients.

Full weight bearing was encouraged throughout the entire treatment. After frame removal, a long lower limb cast was applied. Patients were instructed to be 30% partial weight bearing in the cast for the first 2 weeks. The long lower limb cast was then changed, and weight bearing as tolerated was allowed in the cast for the next 4 weeks.

Clinical and radiographic parameters were assessed. Radiographs included 51-inch standing bipodal radiographs for measurement of limb length discrepancy and alignment.<sup>14</sup> Quality of life was assessed by using outcome scores measured preoperatively and at the most recent follow-up examination. The Medical Outcomes Study 36-item short-form health survey (SF-36) was used to assess quality of life. The American

Accepted for publication October 21, 2004.

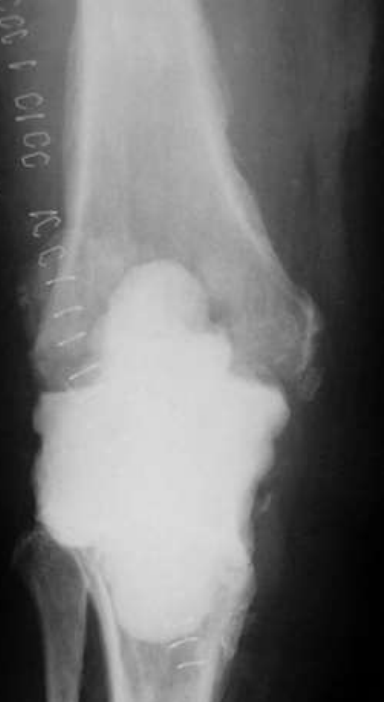From the Institute for Limb Lengthening and Reconstruction, Hospital for Special Surgery, Weill Medical College of Cornell University, New York, NY.

Reprints: S. Robert Rozbruch, MD, Hospital for Special Surgery, 535 East 70th Street, New York, NY 10021 (e-mail: rozbruch@hss.edu). Copyright © 2005 by Lippincott Williams & Wilkins



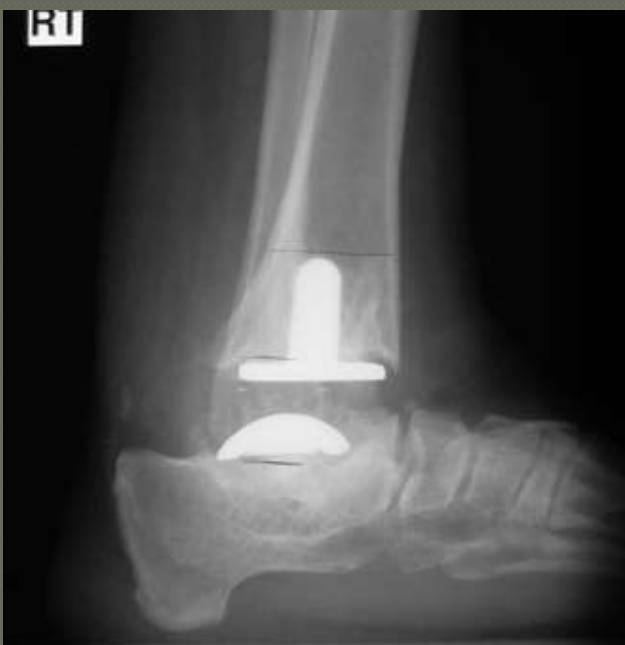

RIGHT AP  
SUPINE



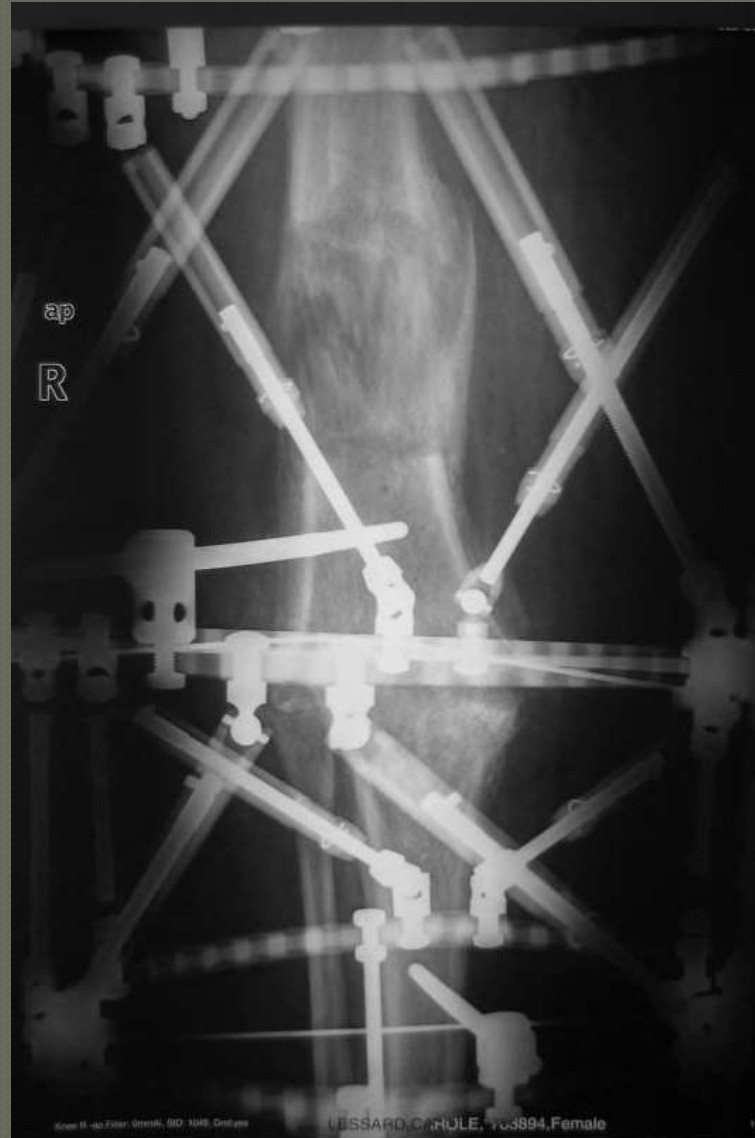
# Problems

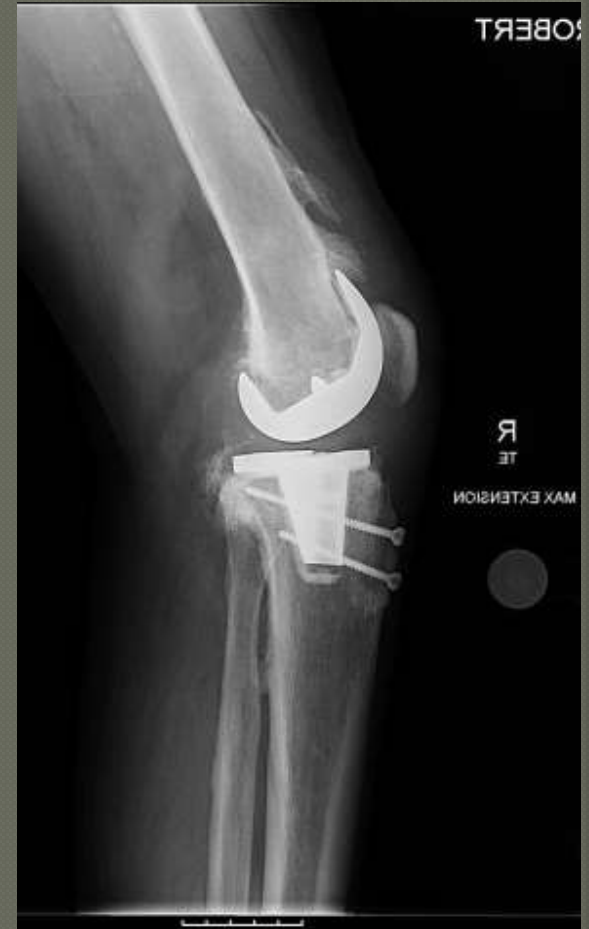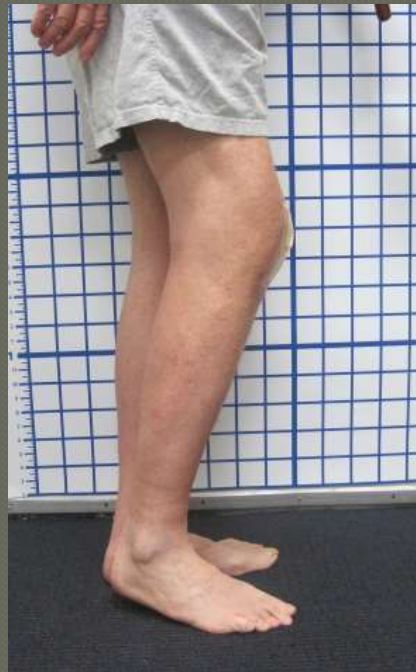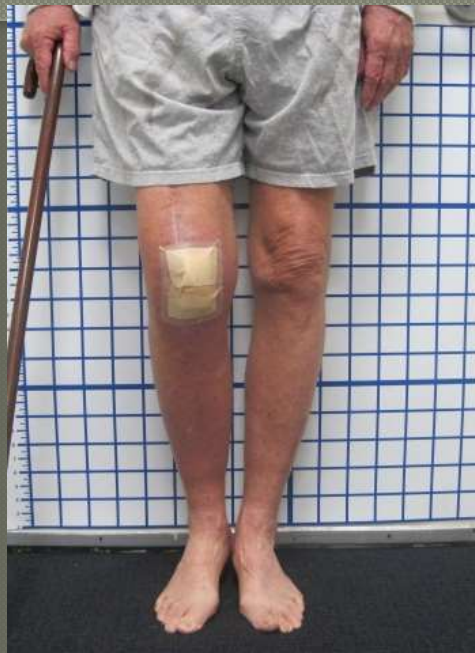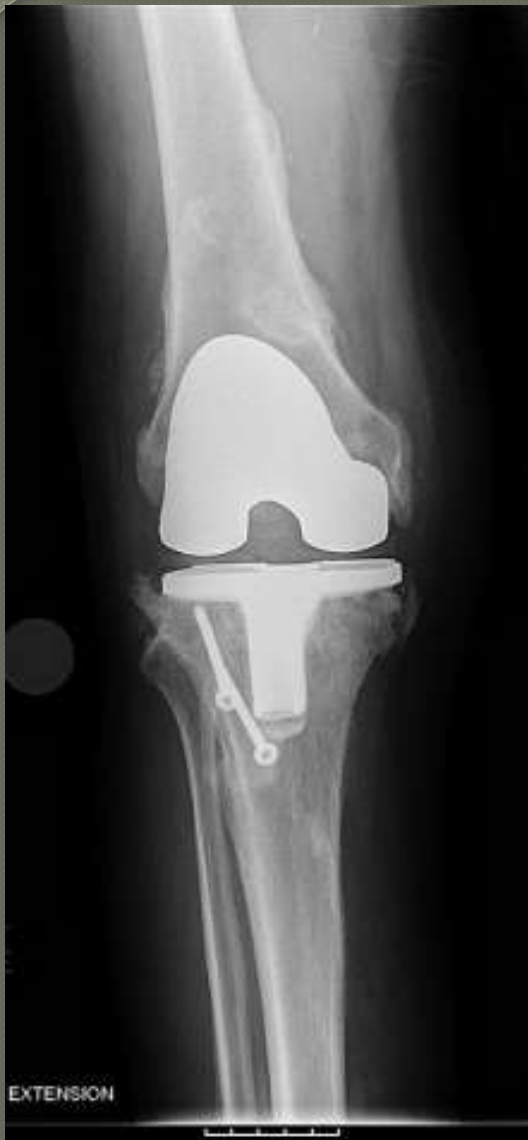- Bone loss/ defect
- Infection
- Soft-tissue envelope
- LLD
- Deformity
- Scar tissue
- Poor host



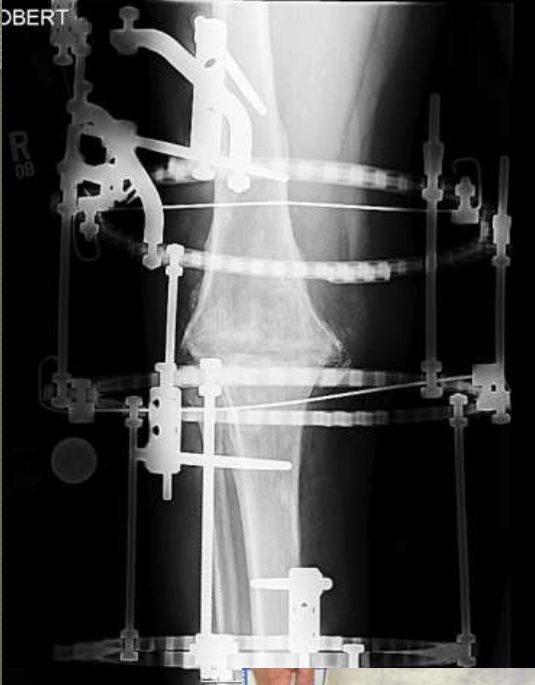# Goals

- Eradicate infection
- Fuse joint
- Single stage surgery
- Optimize leg length

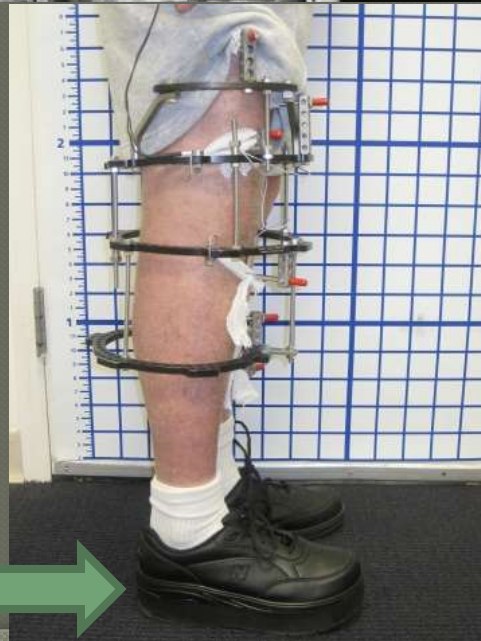
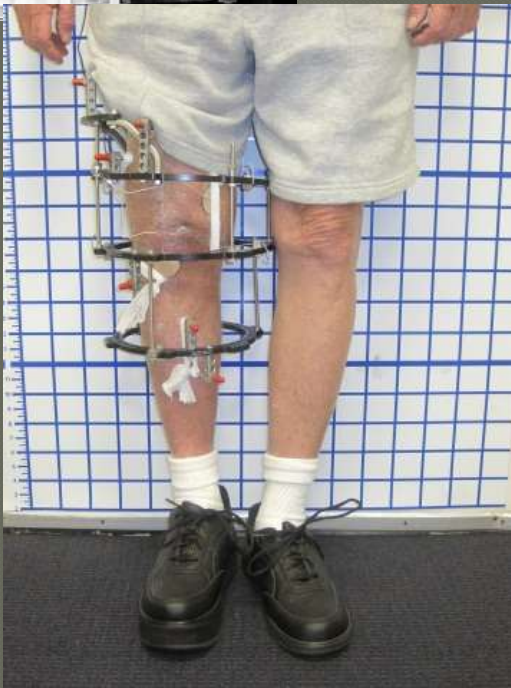
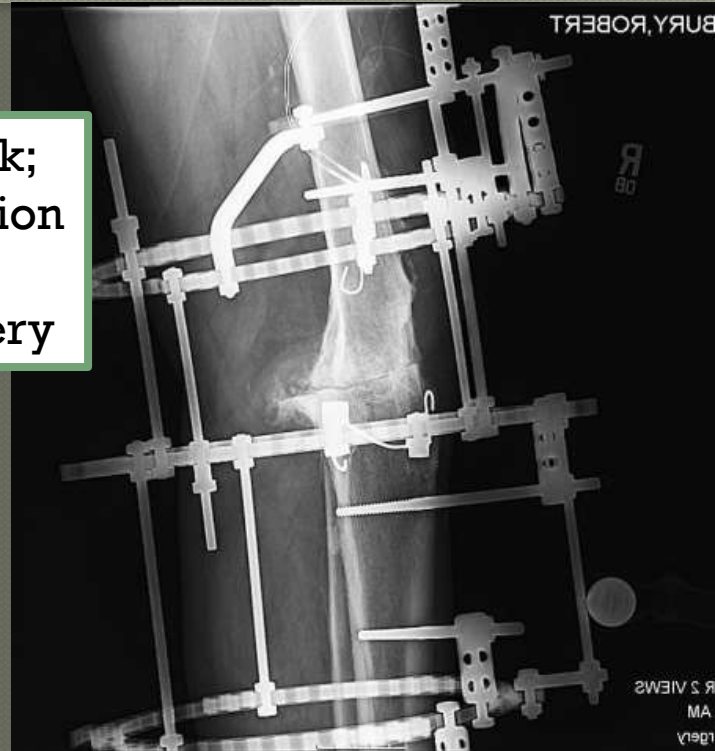

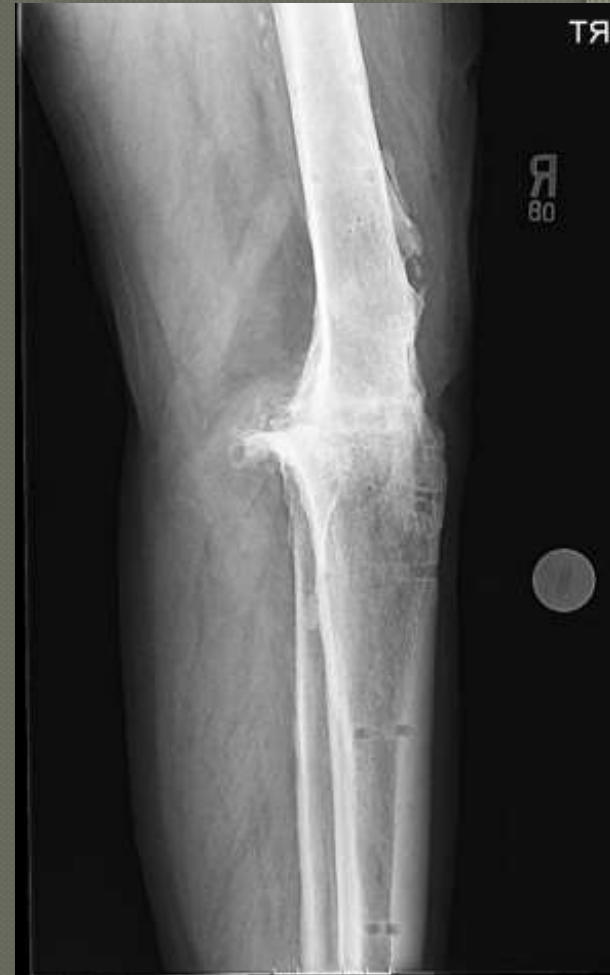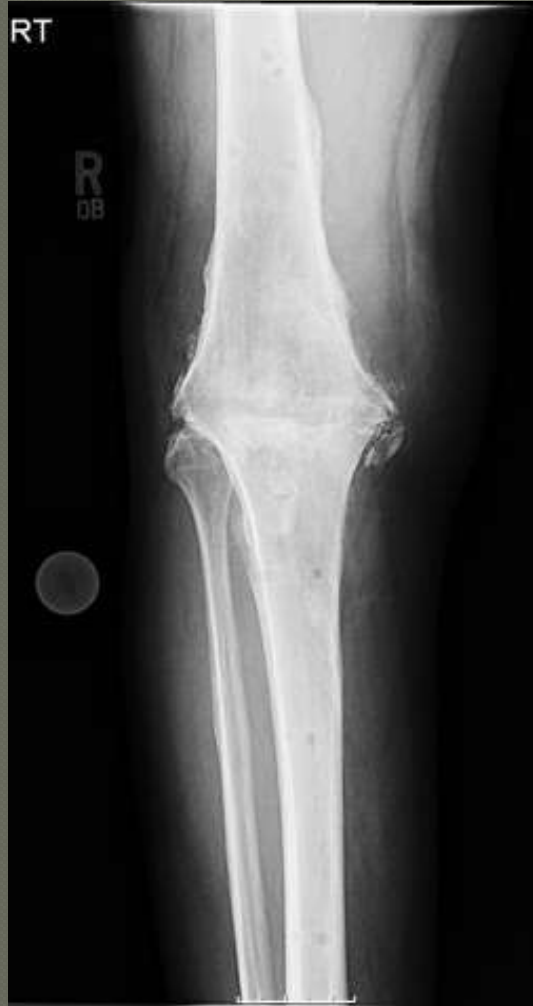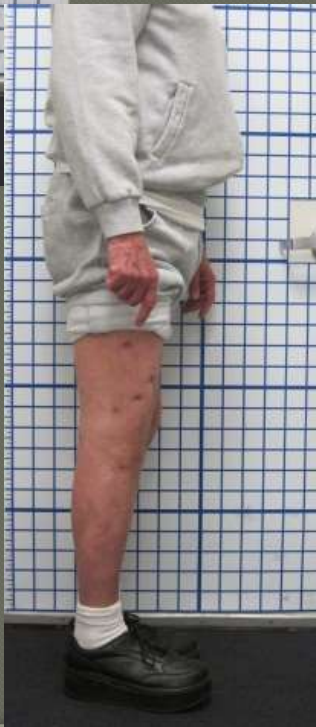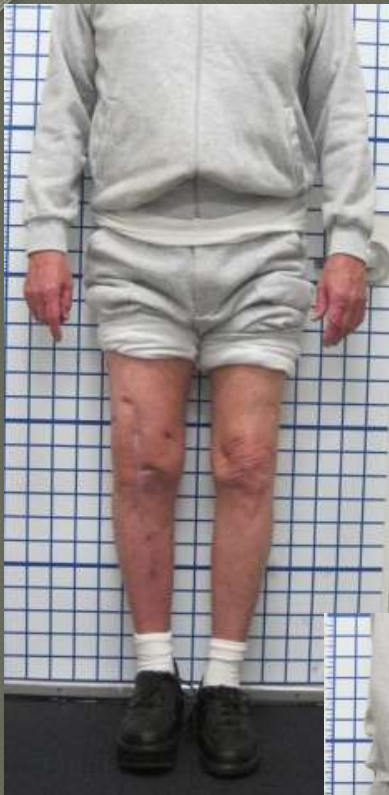Infected; knee contracture



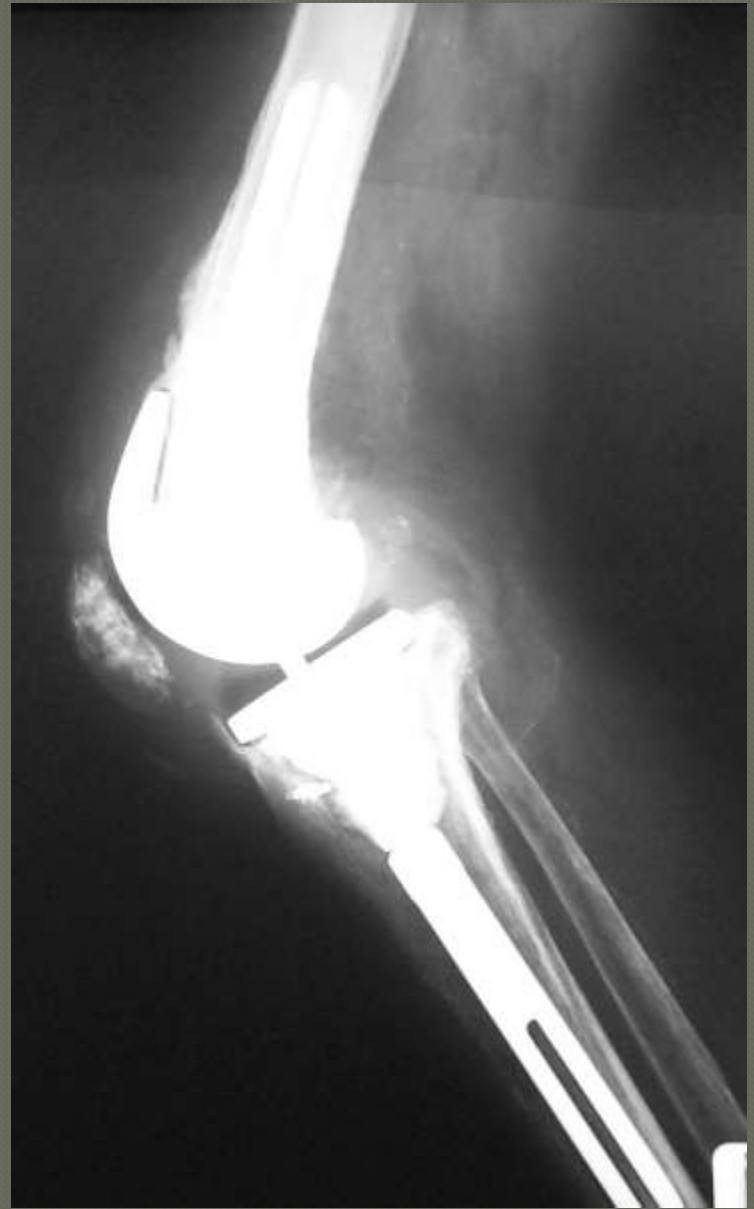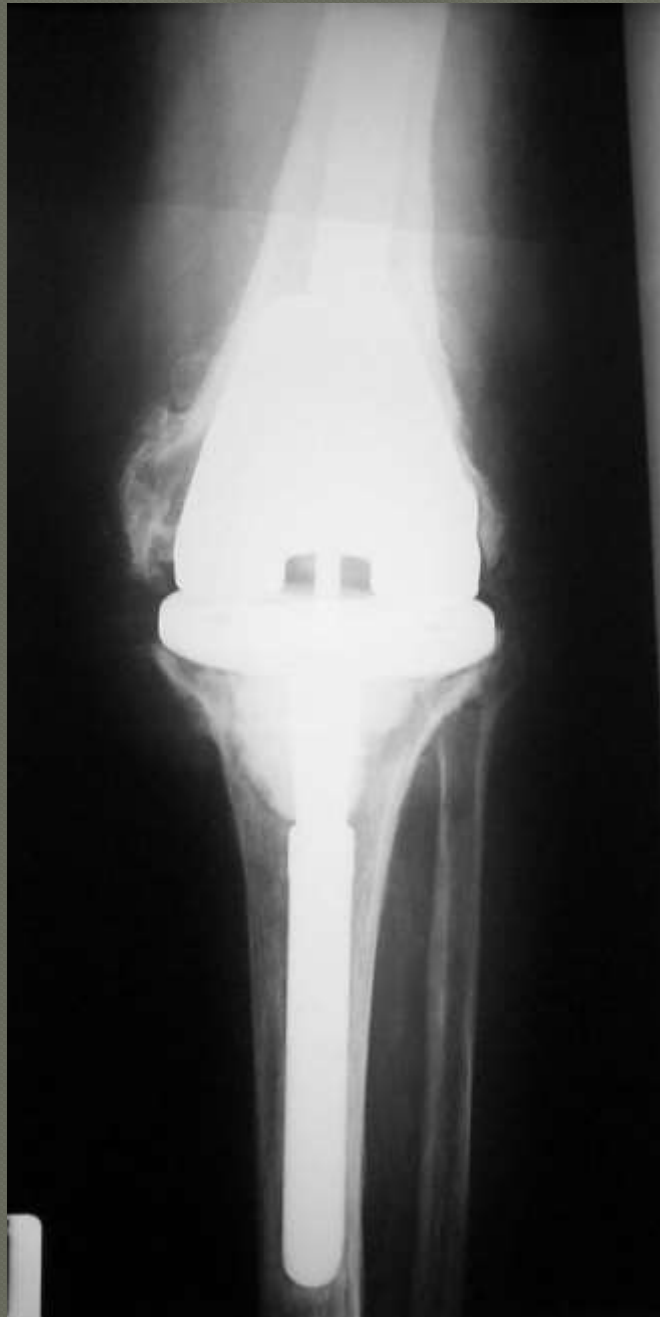Good bone stock;  
Great compression  
With frame  
One stage surgery



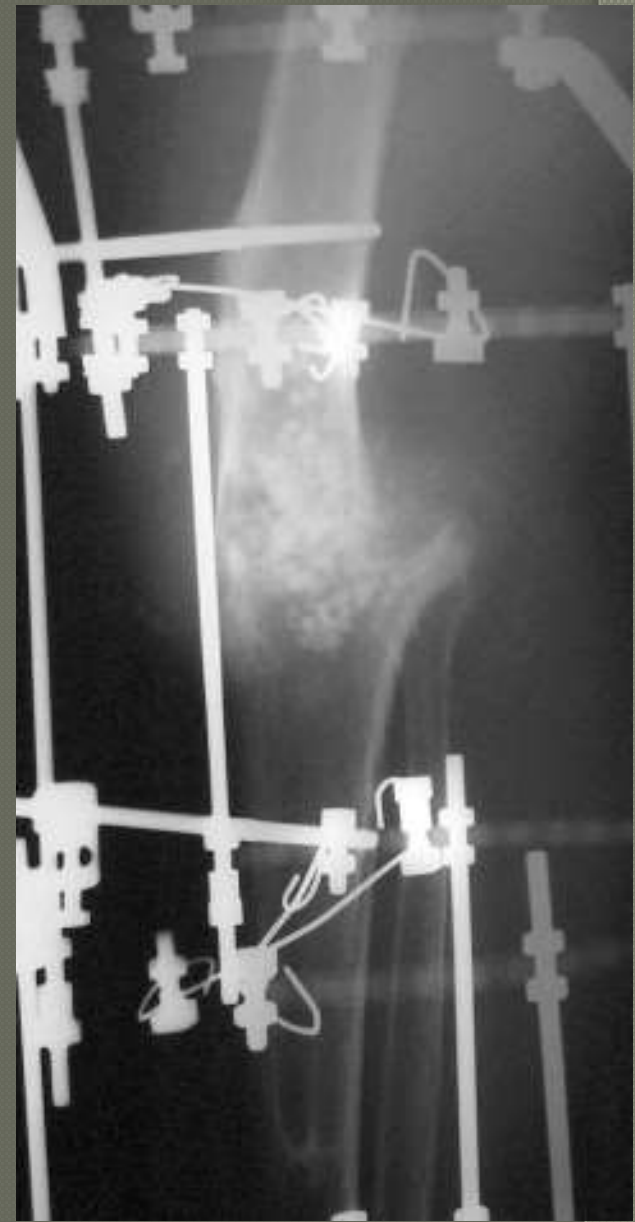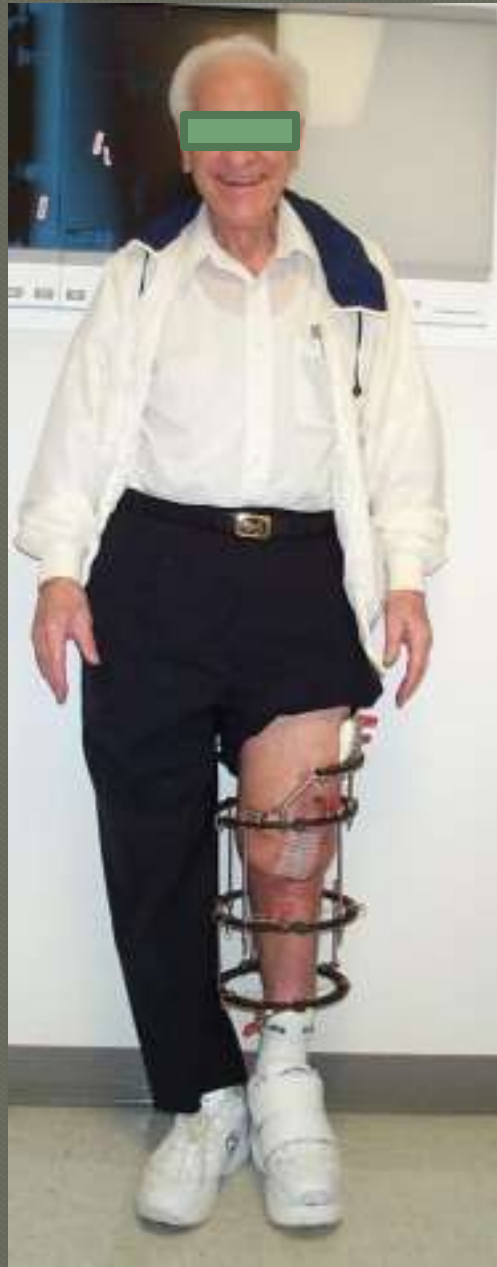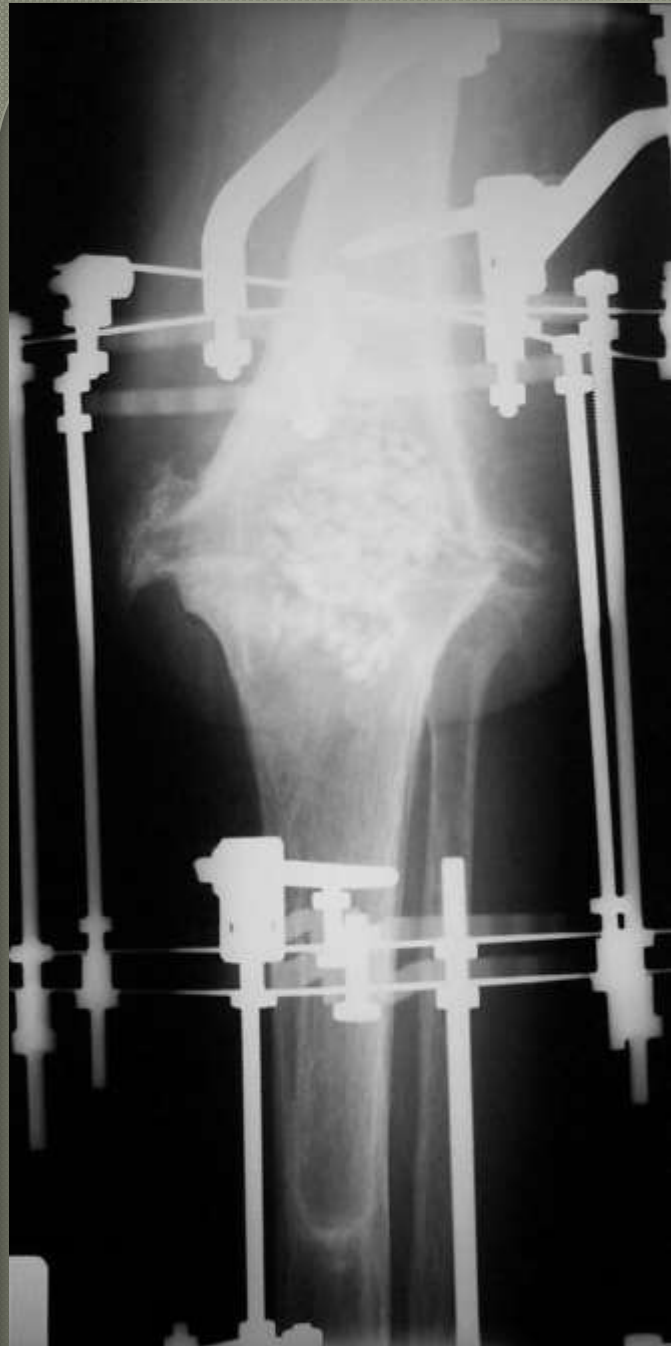10 degrees flexion  
4 months in frame



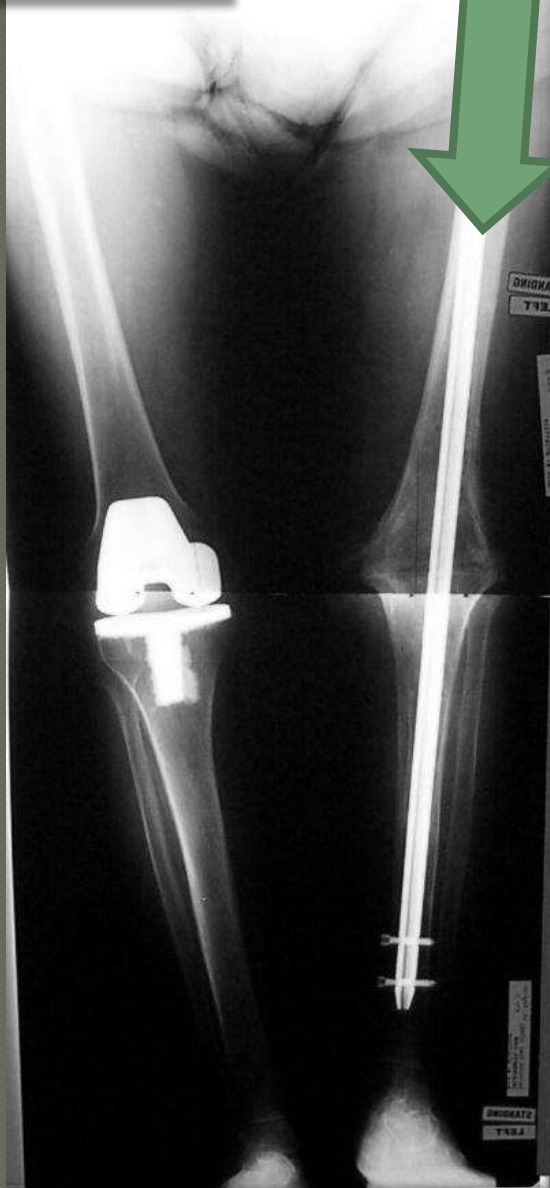
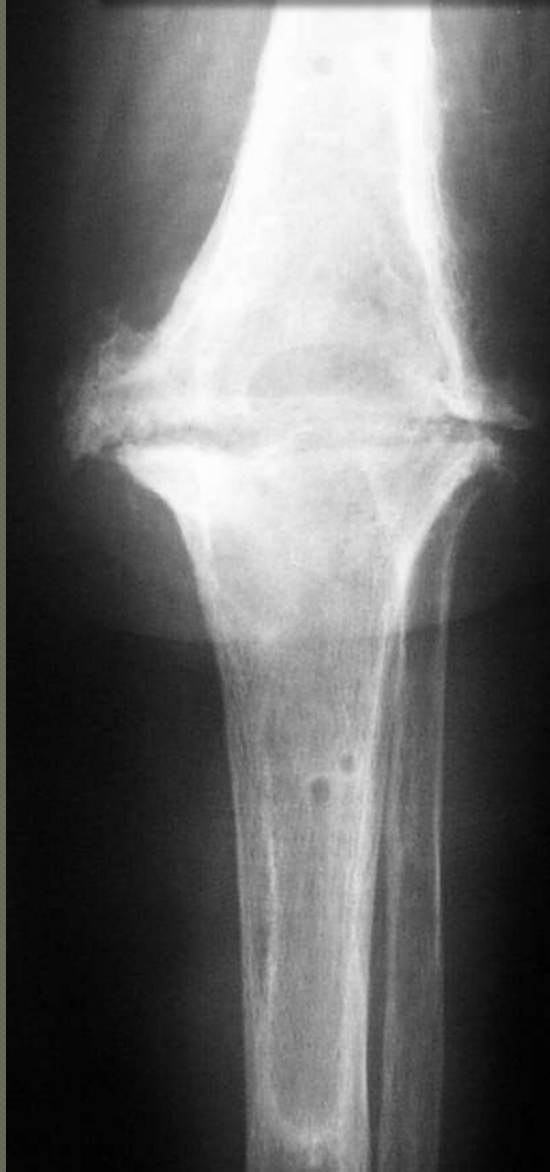




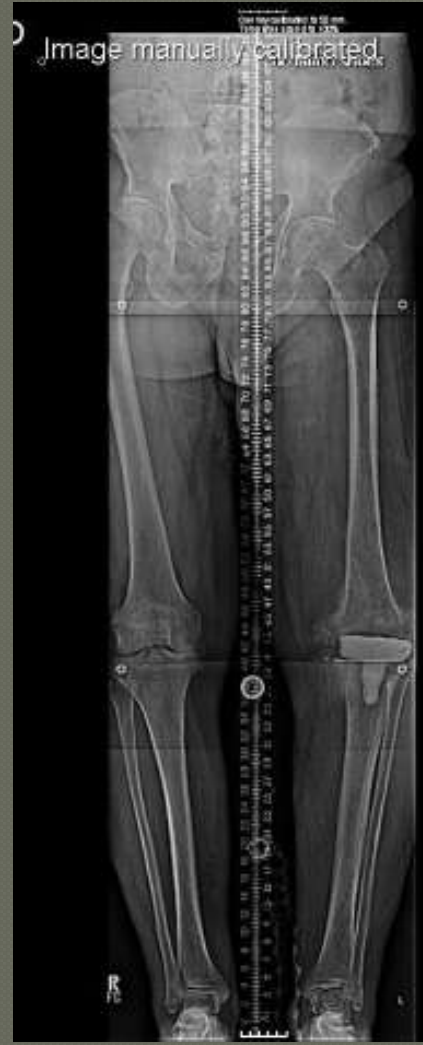
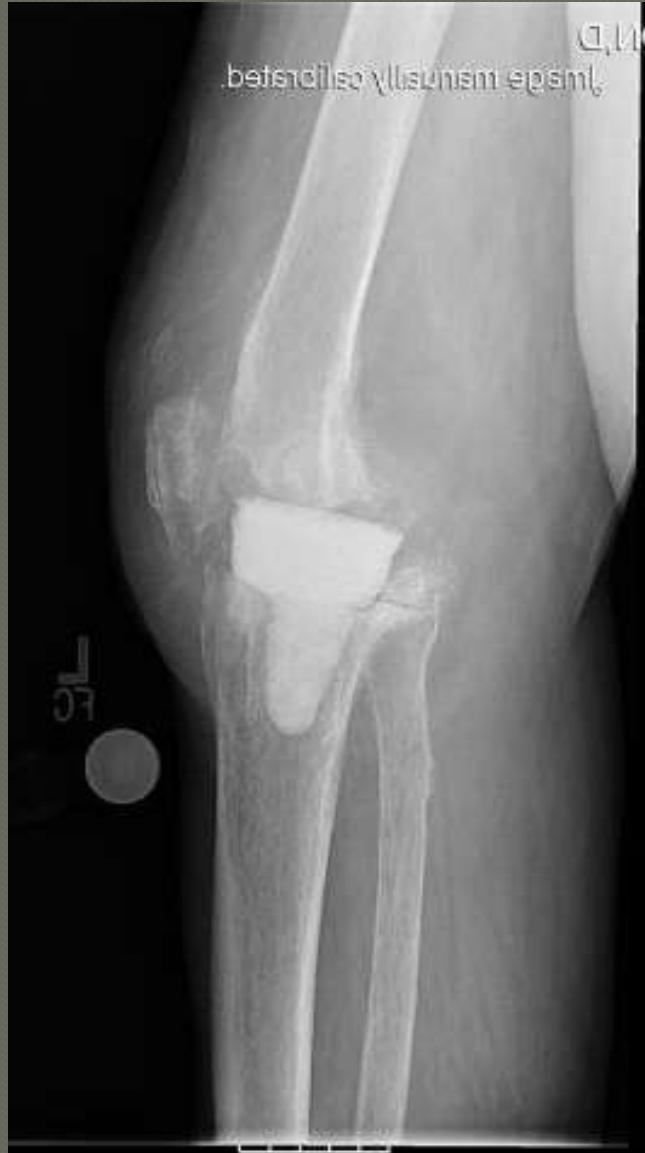
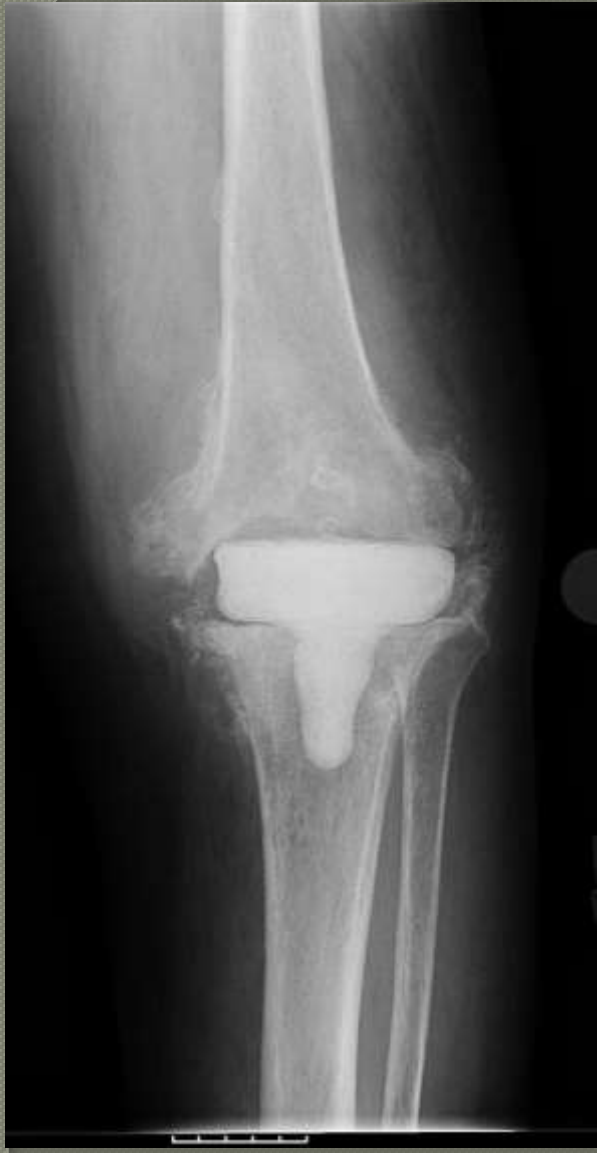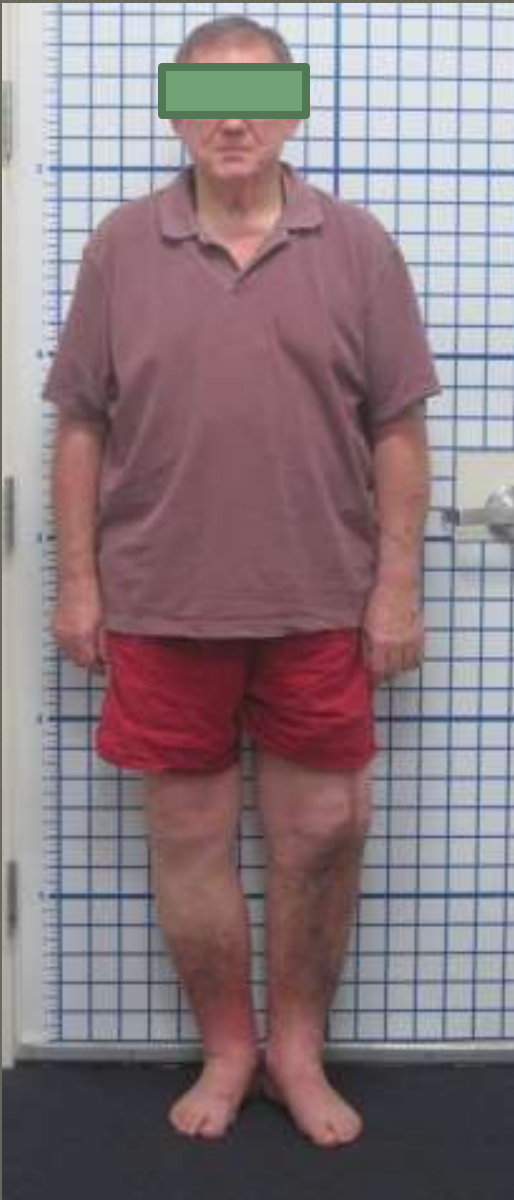Refracture; nonunion  
Poor bone stock; spot welding



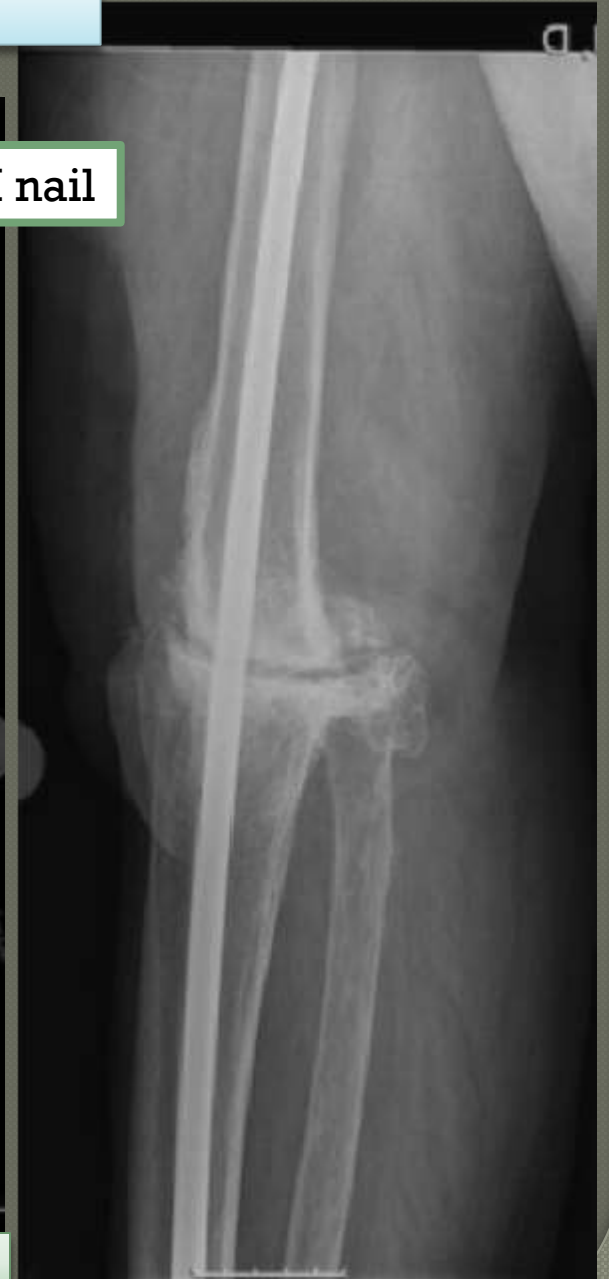
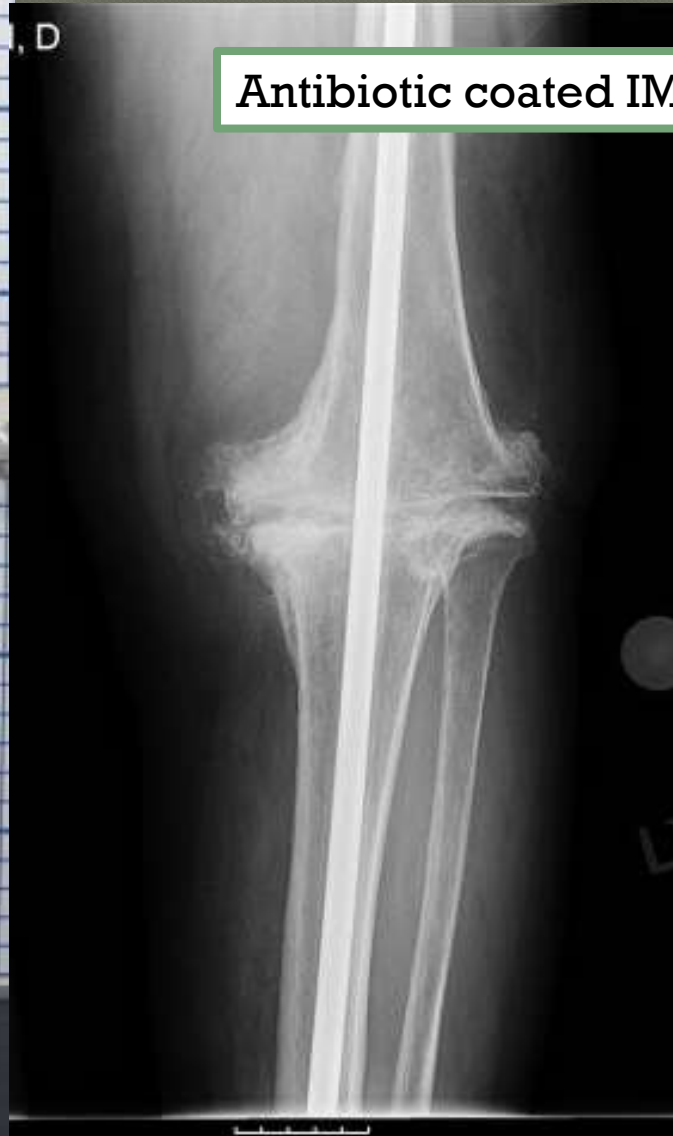


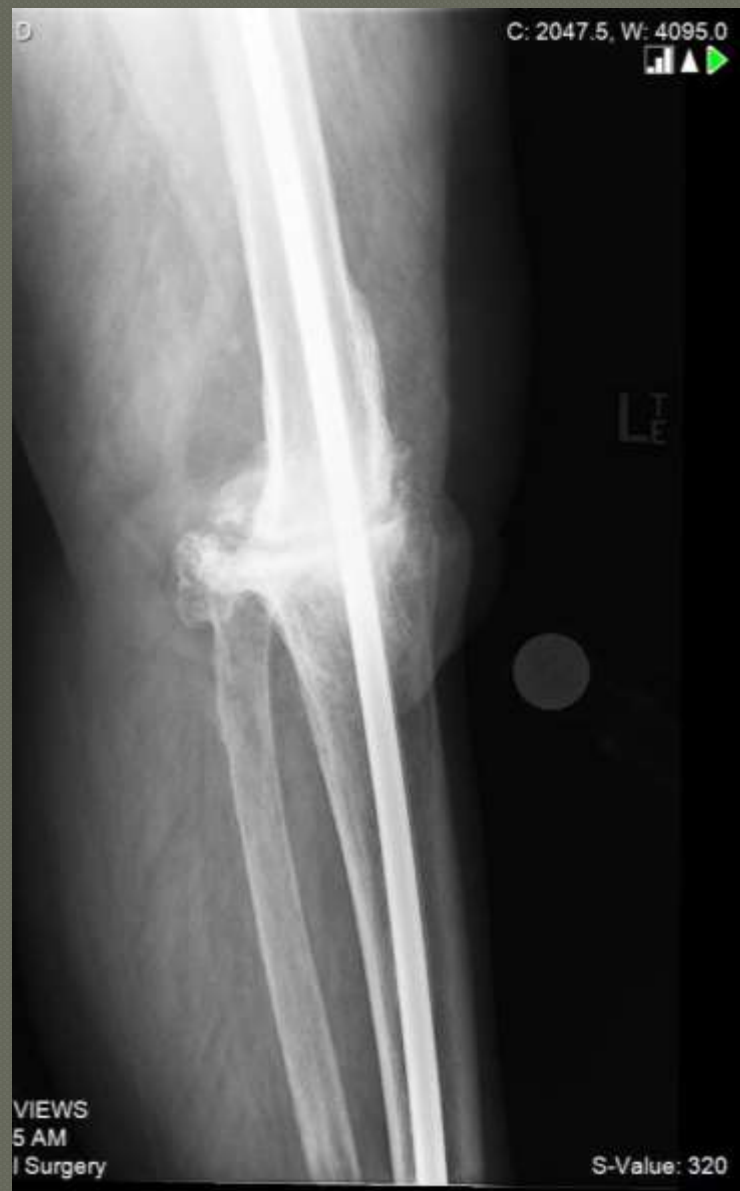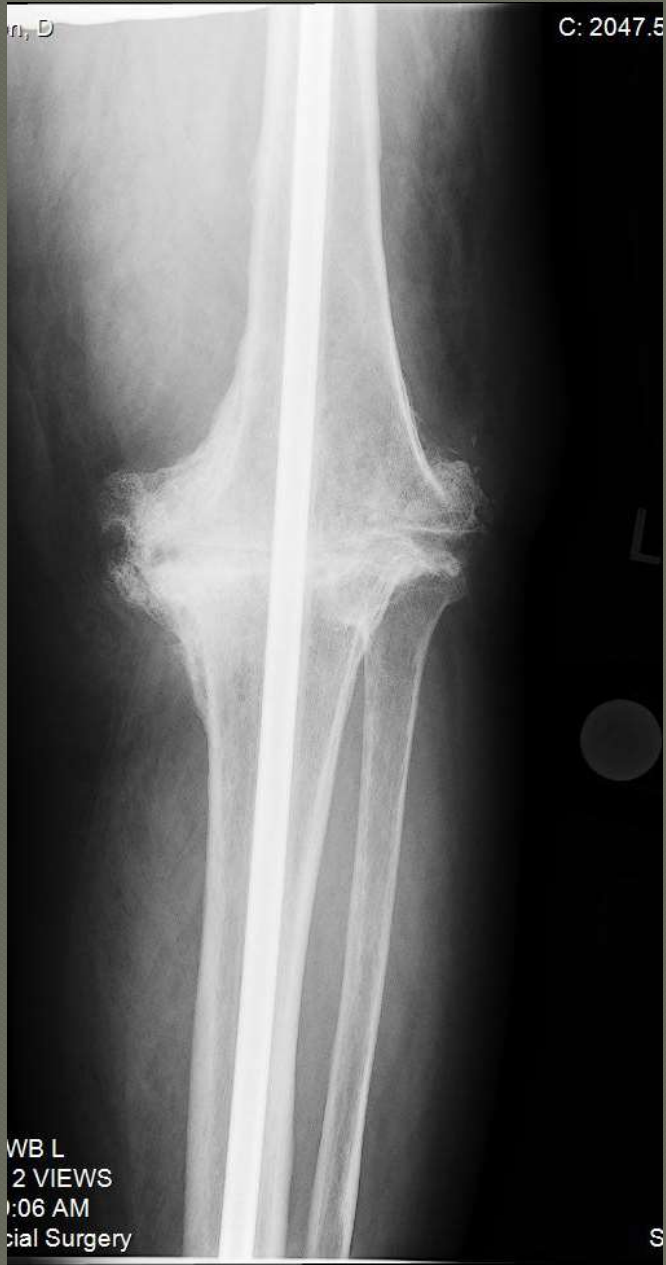Smith & Nephew nails are not FDA cleared for this use and Smith & Nephew does not promote this use



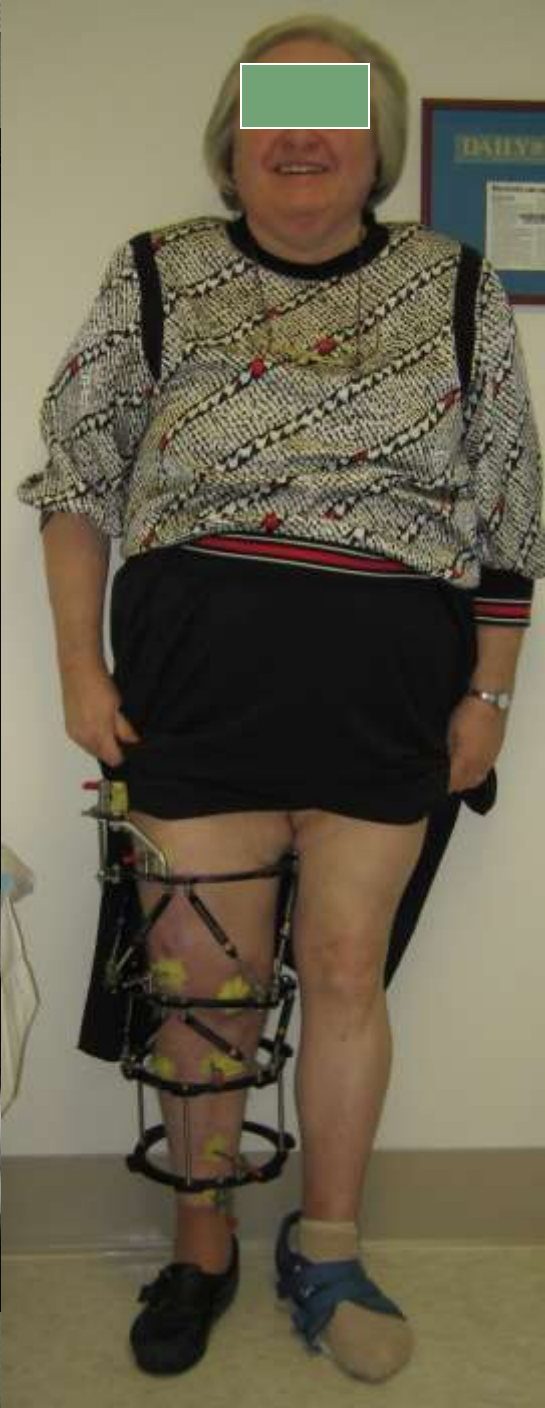

Antibiotic coated IM nail




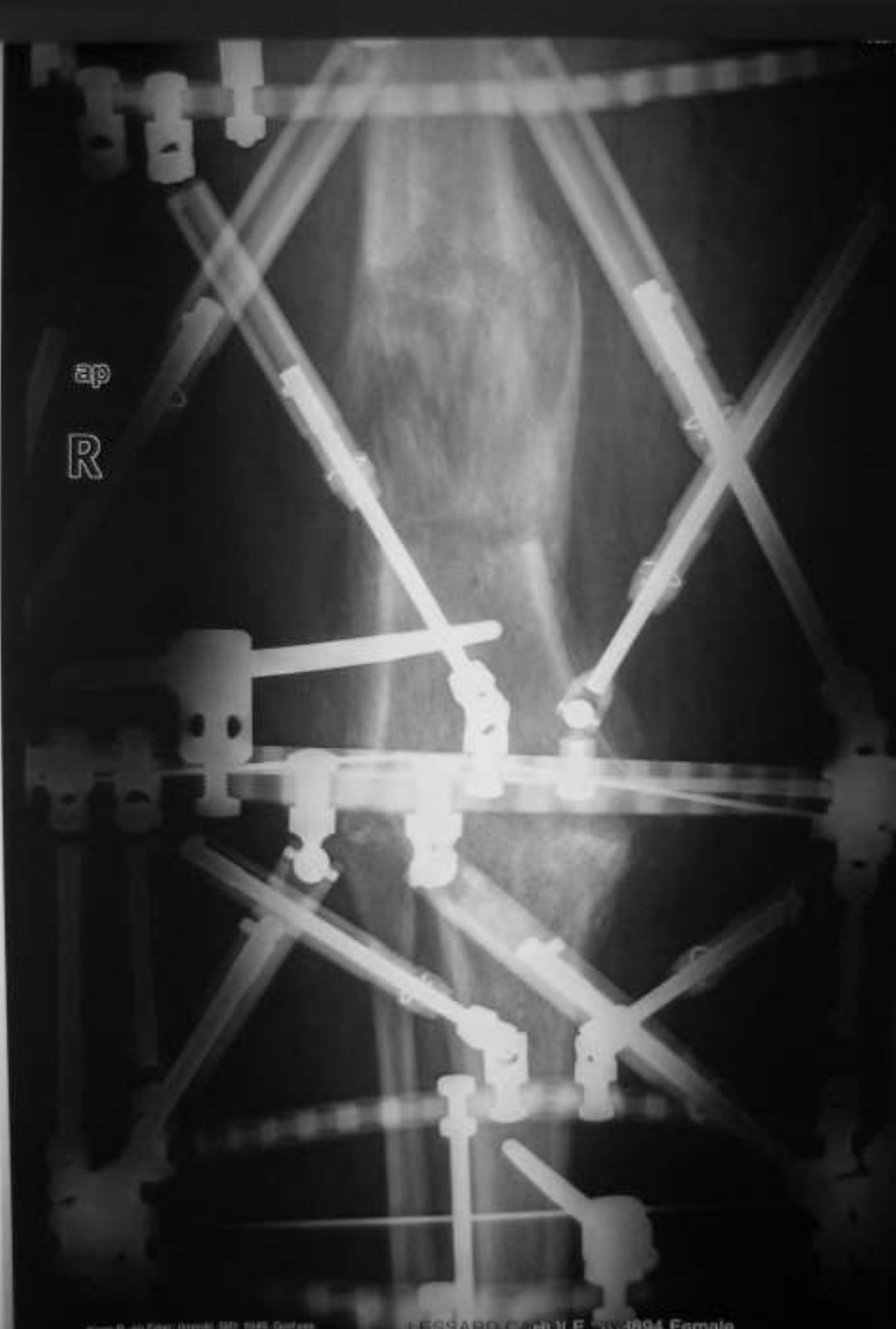
Acute shortening; difficult to get compression

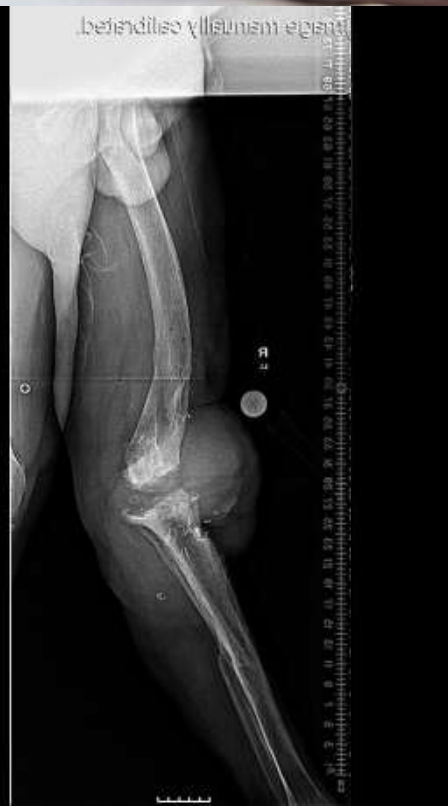
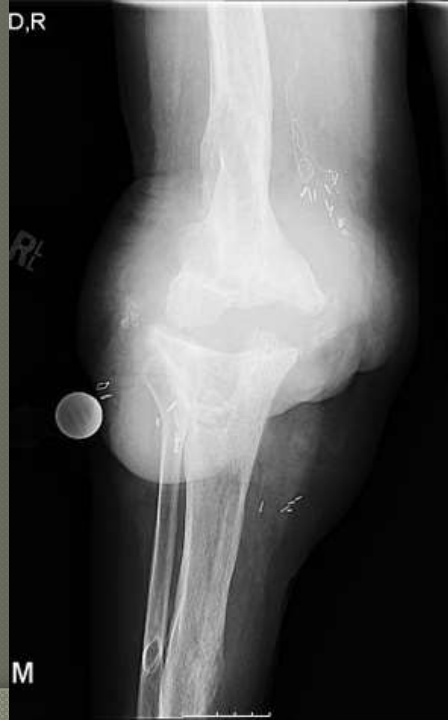
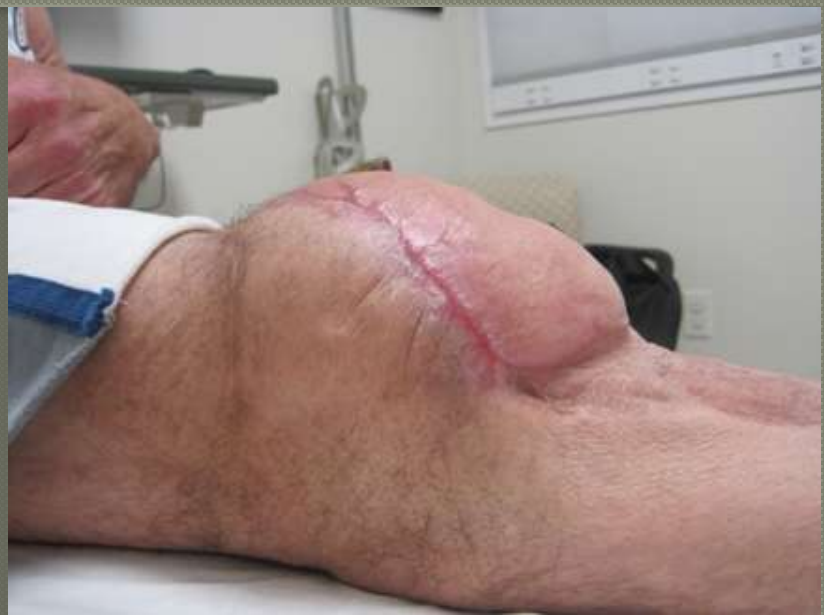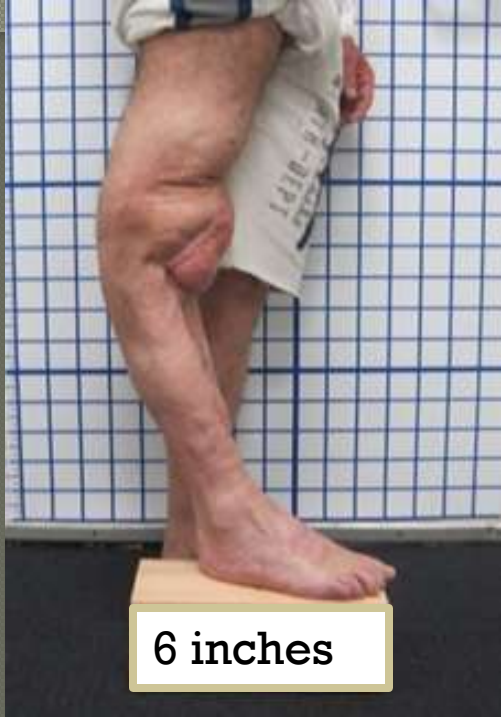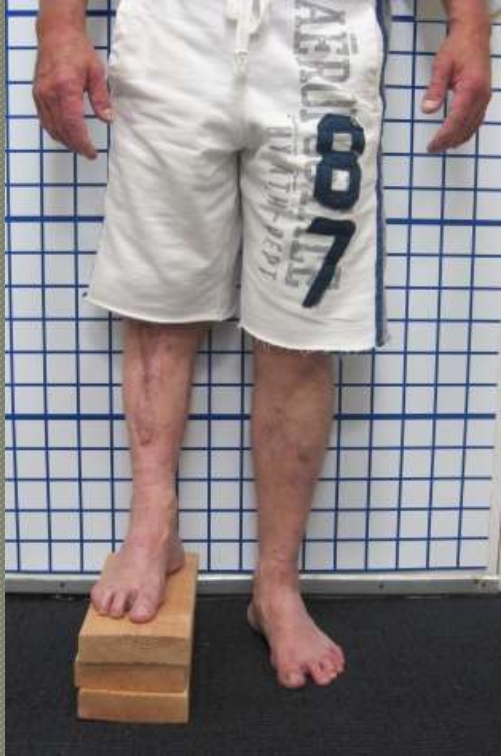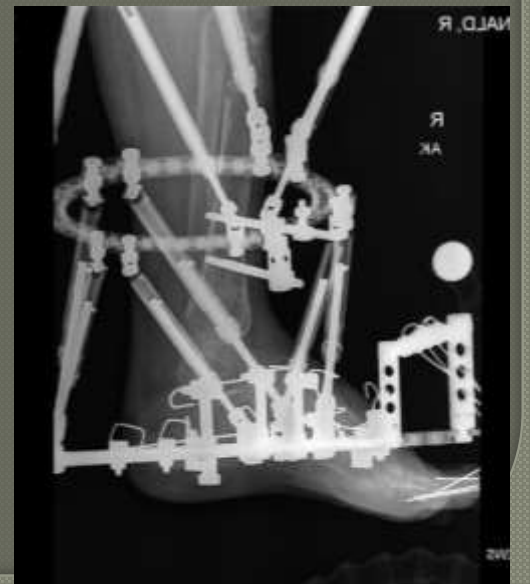
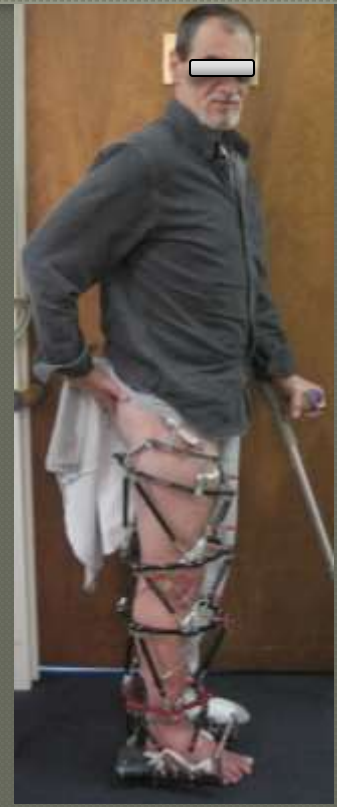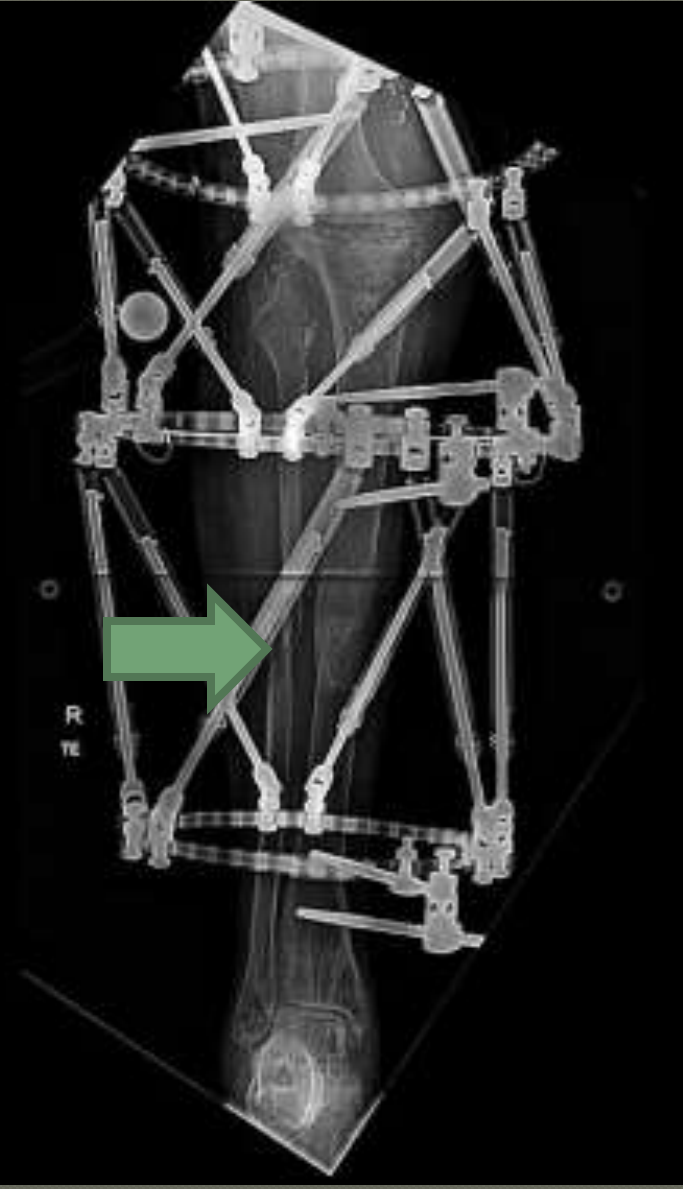
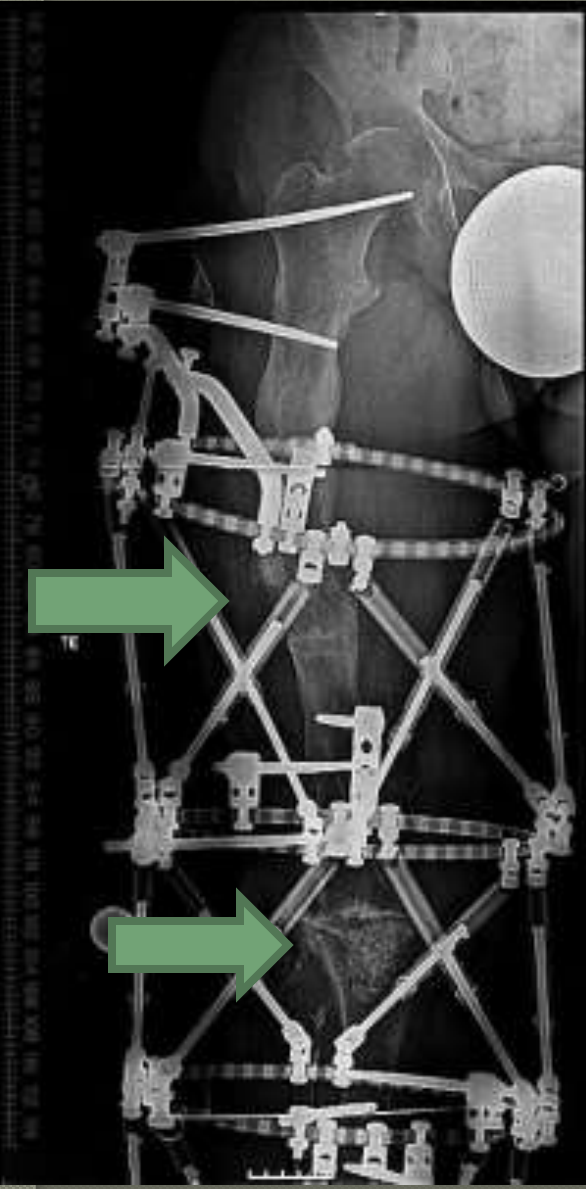








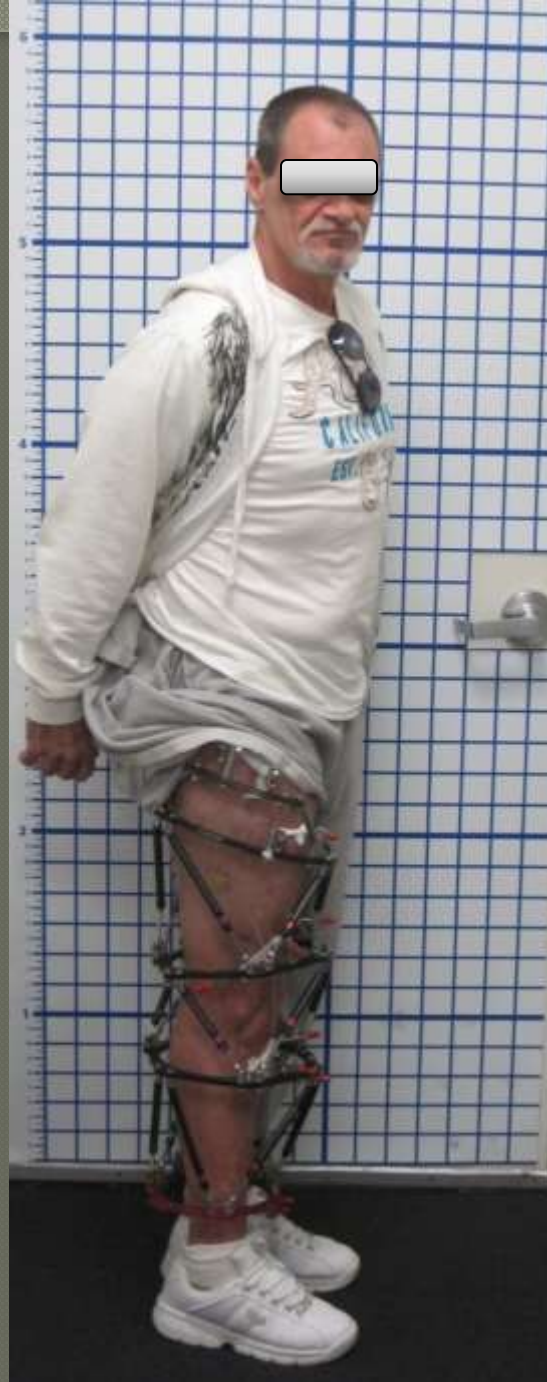
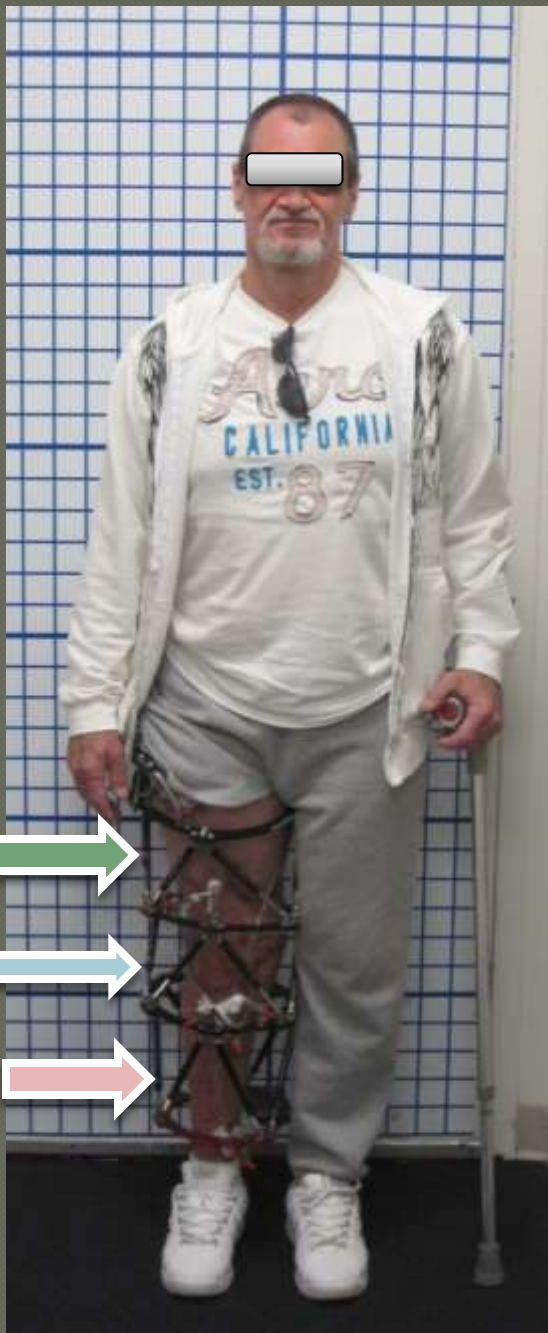


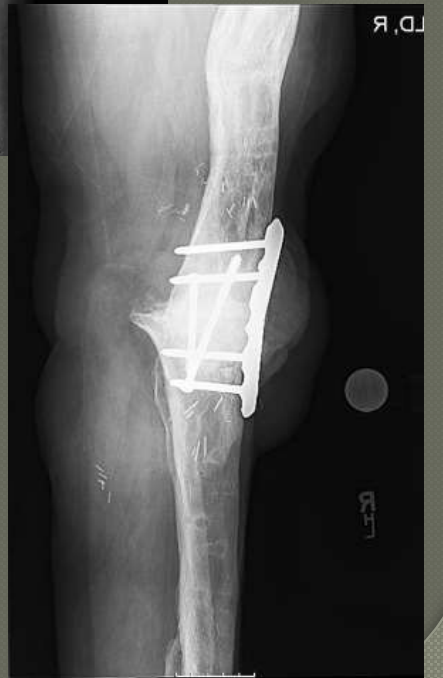
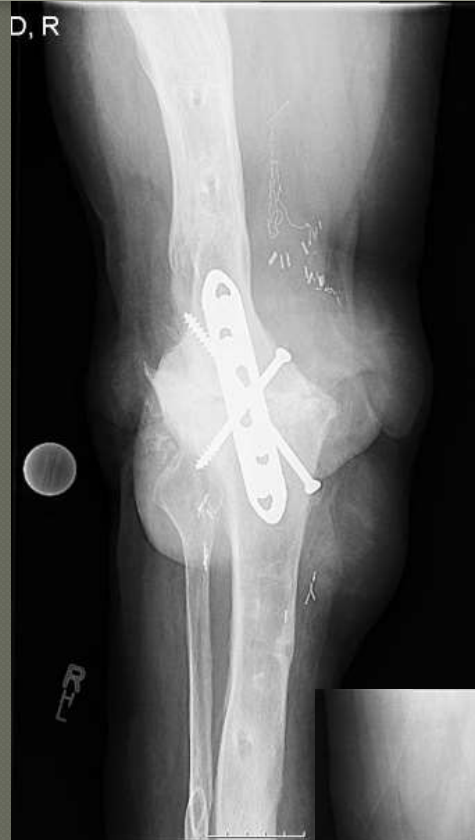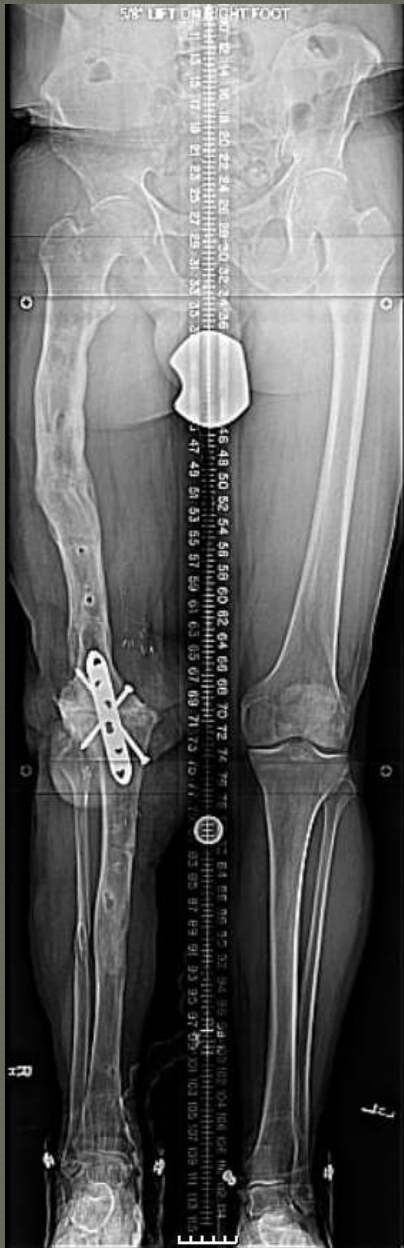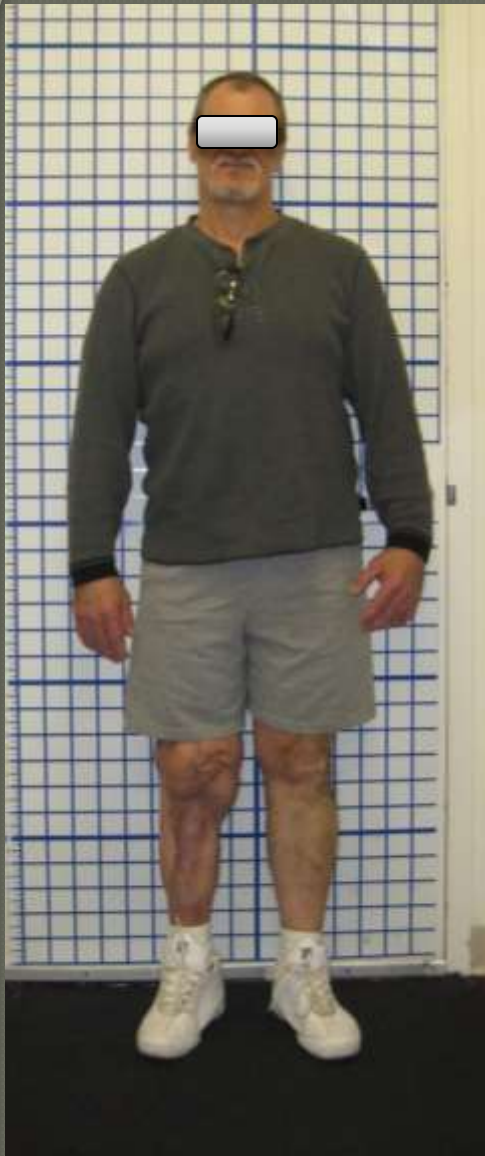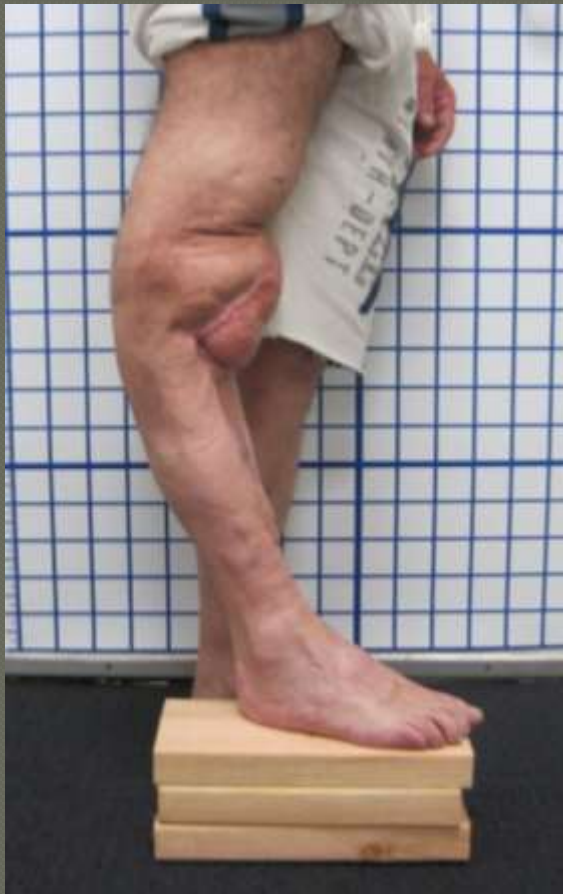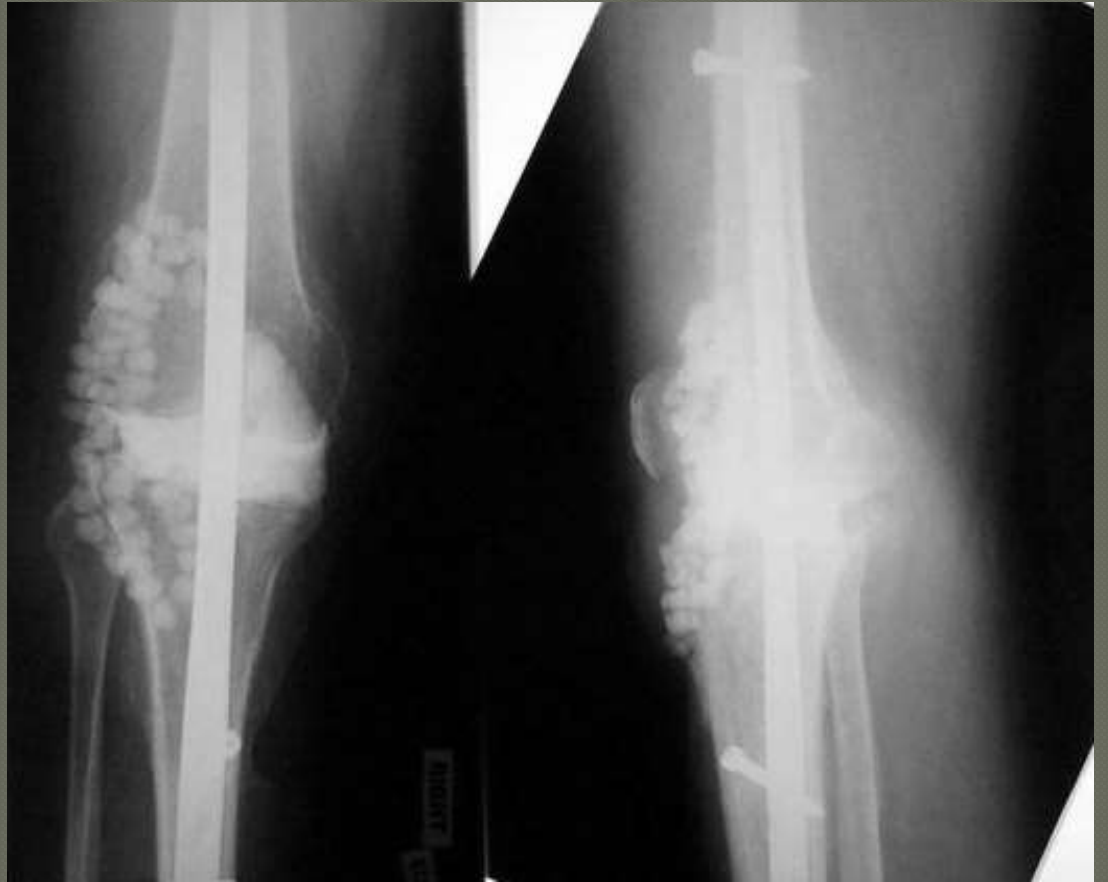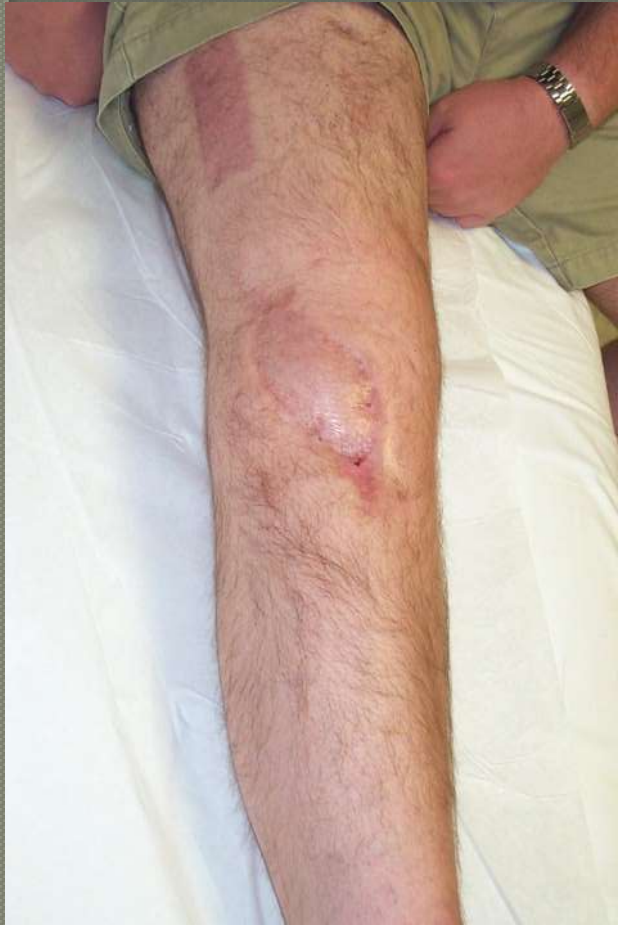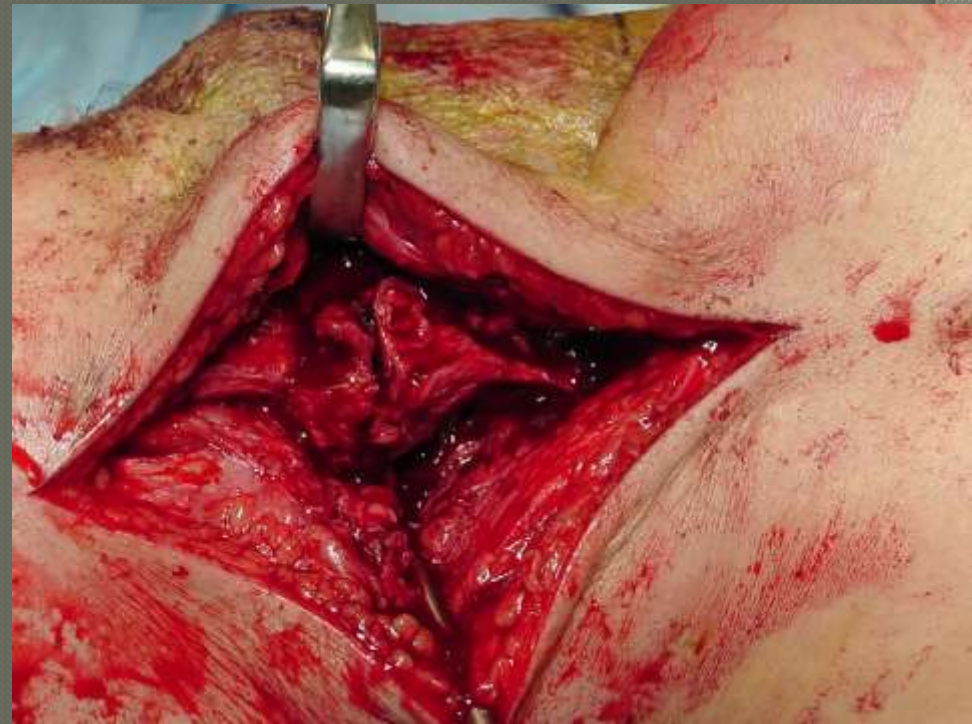




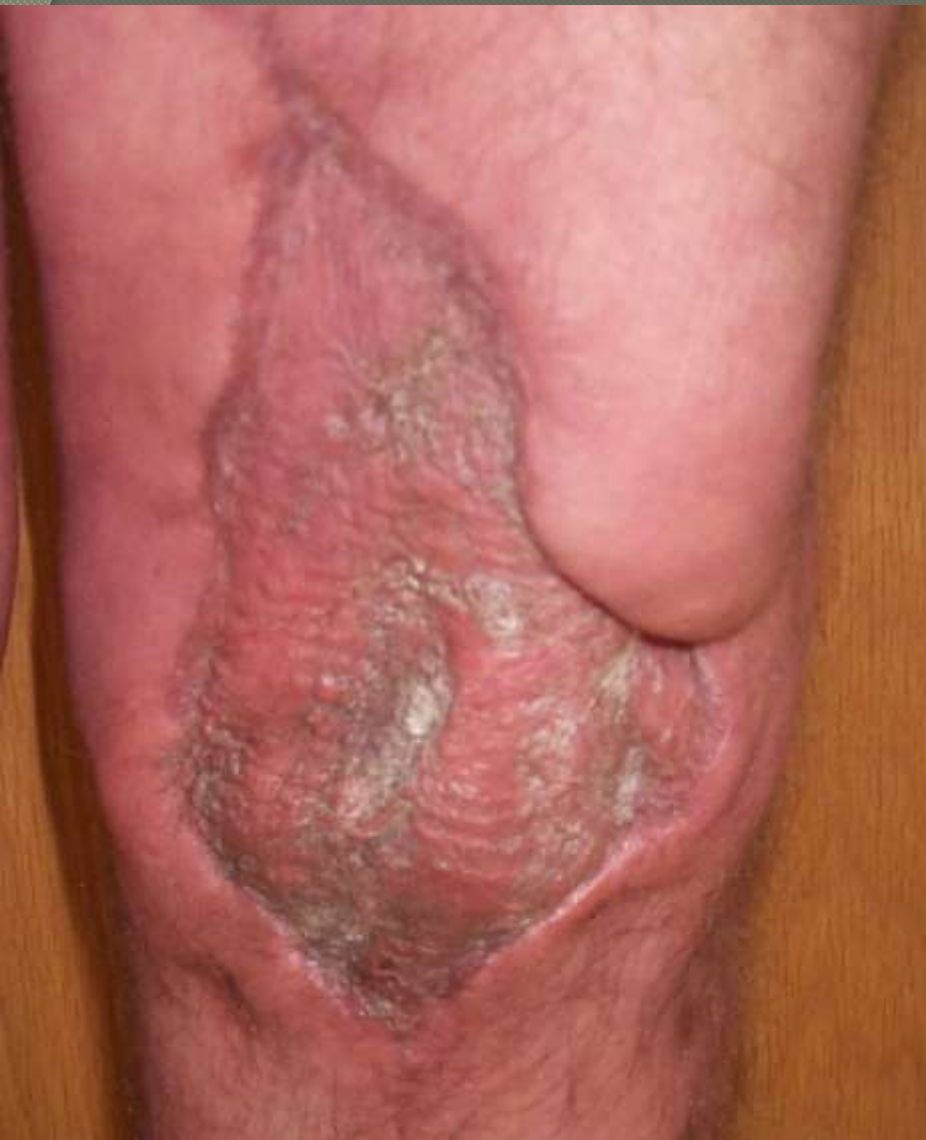preop

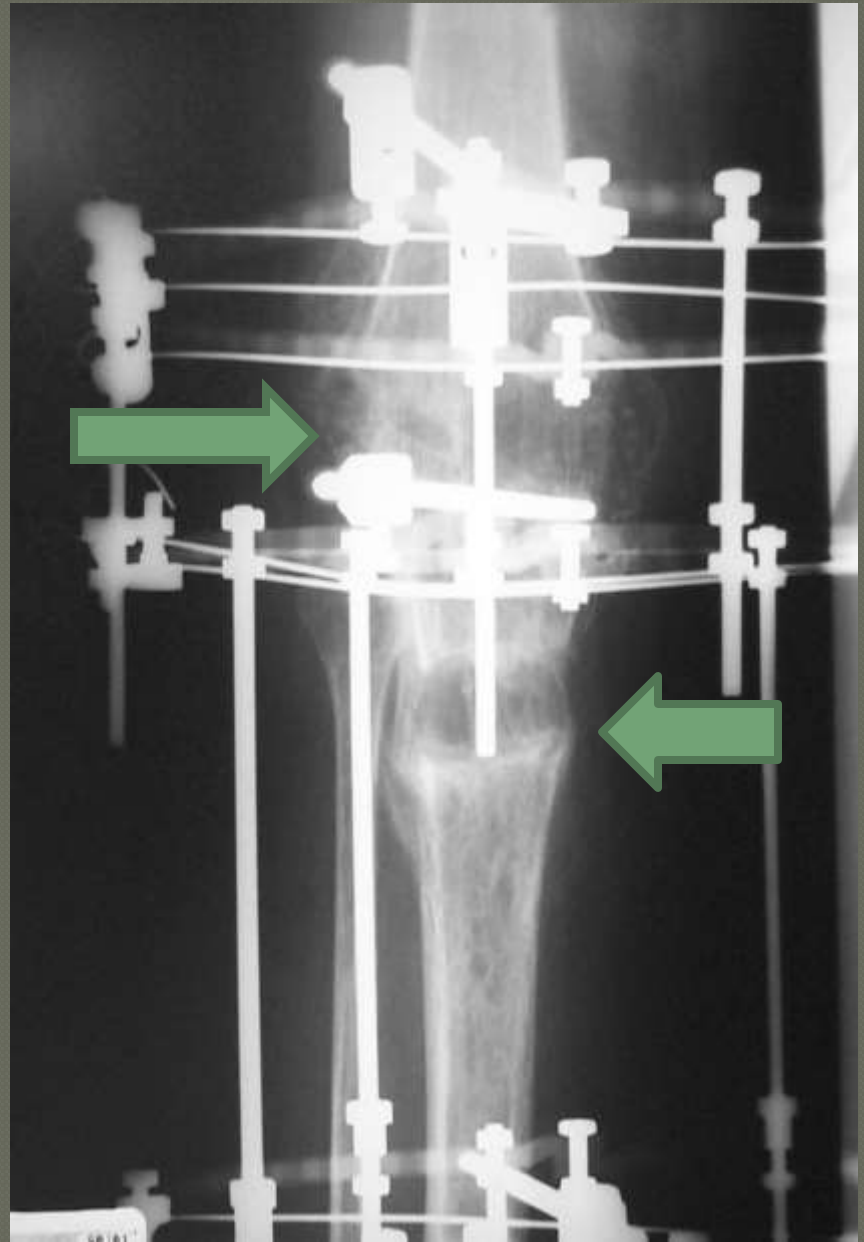
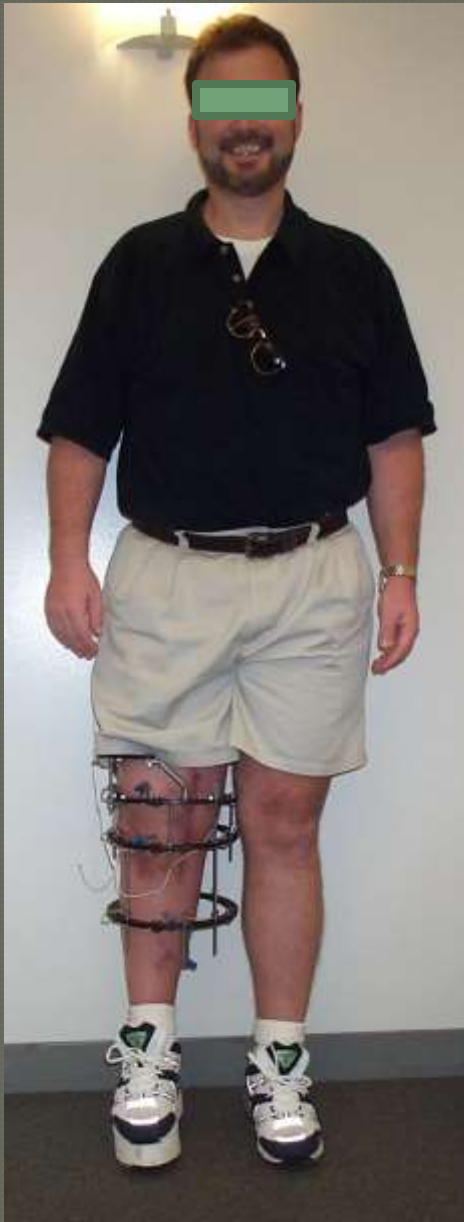


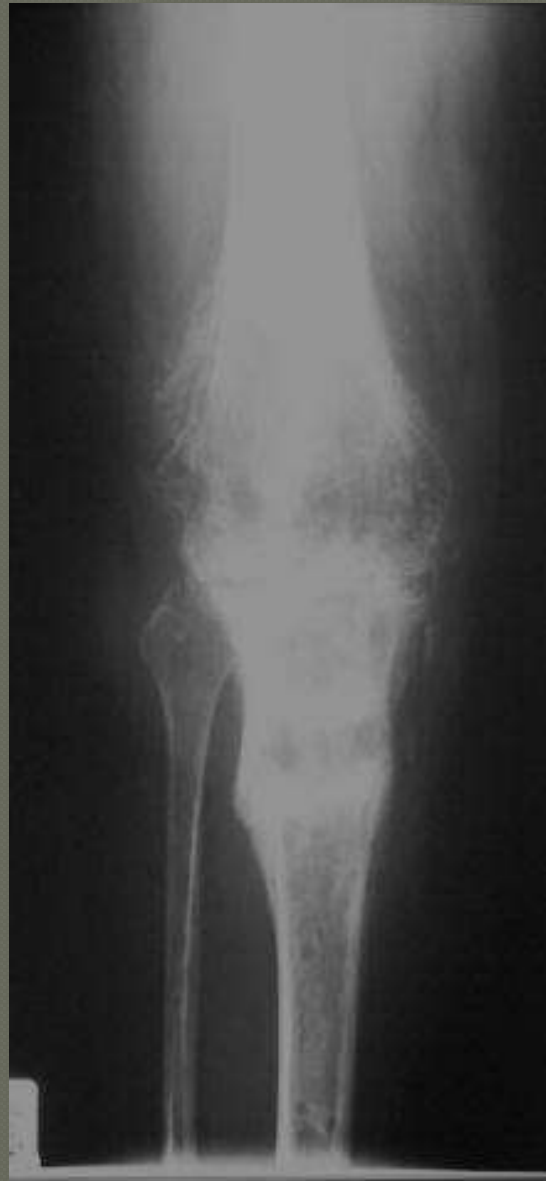


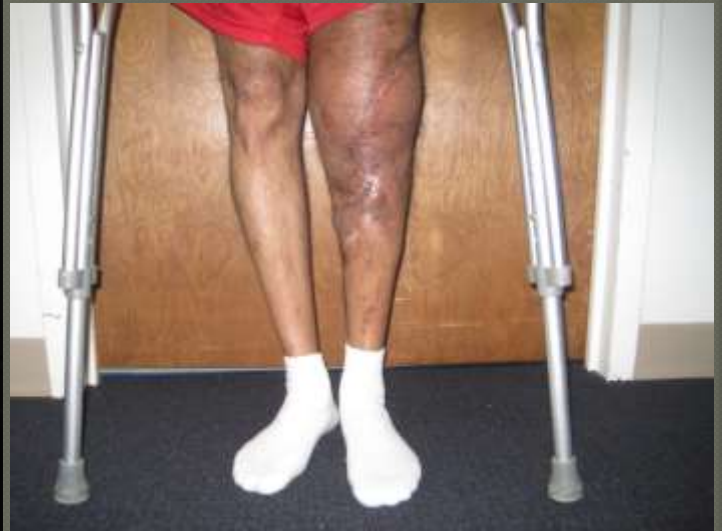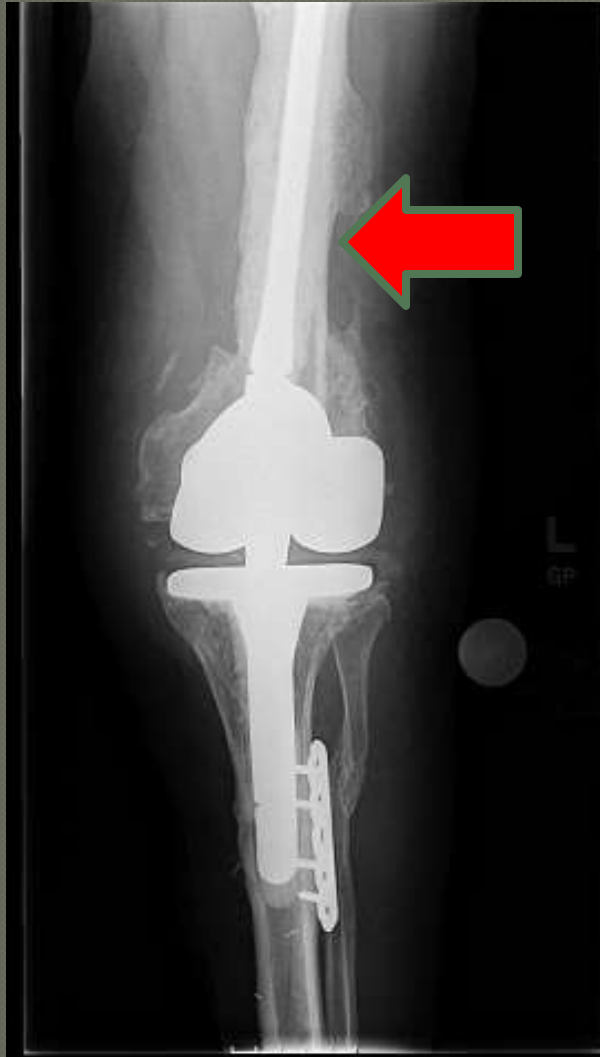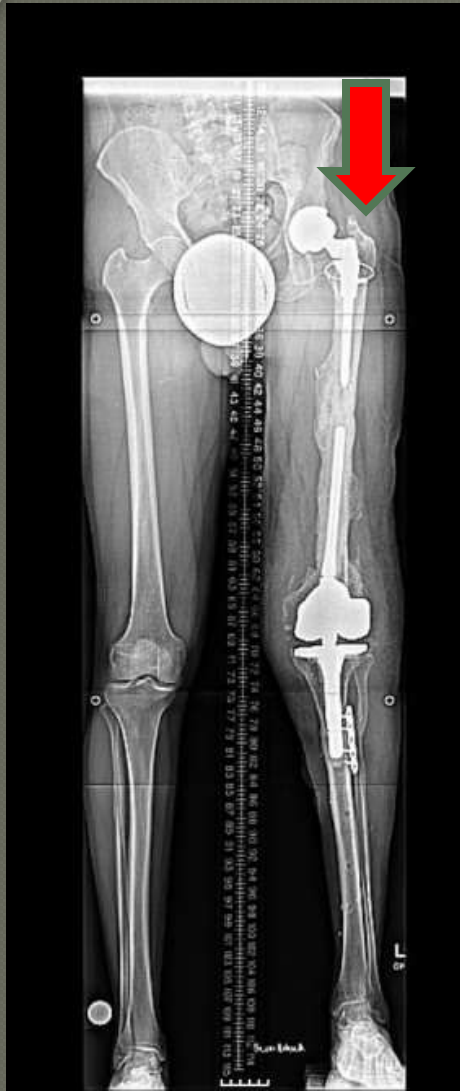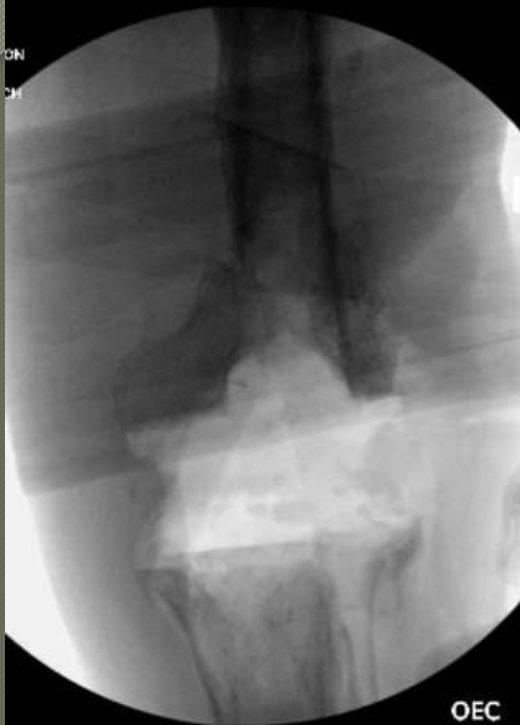Lateral approach to avoid  
Anterior skin



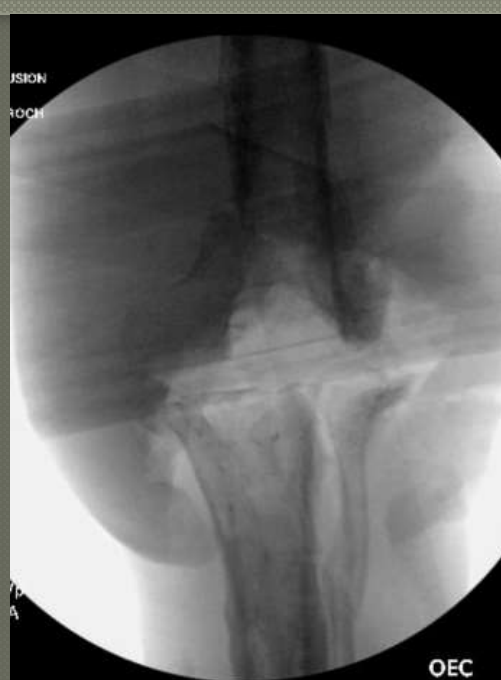




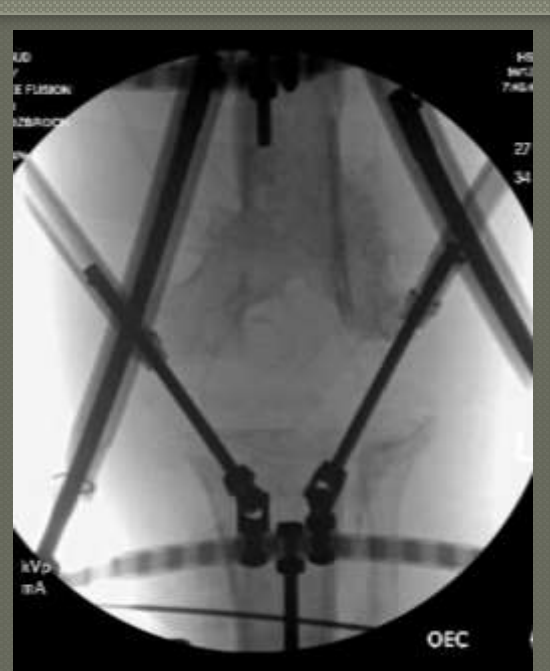


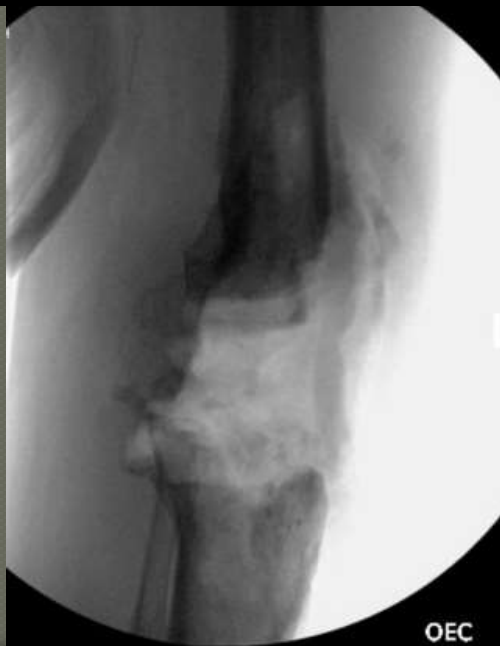OEC



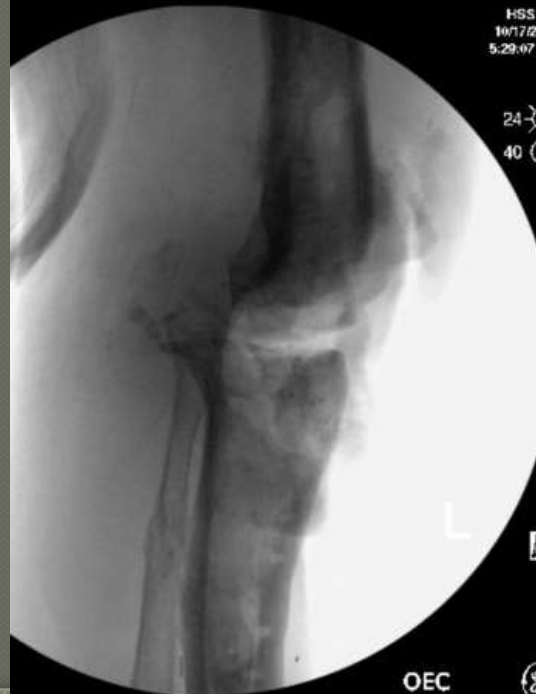OEC



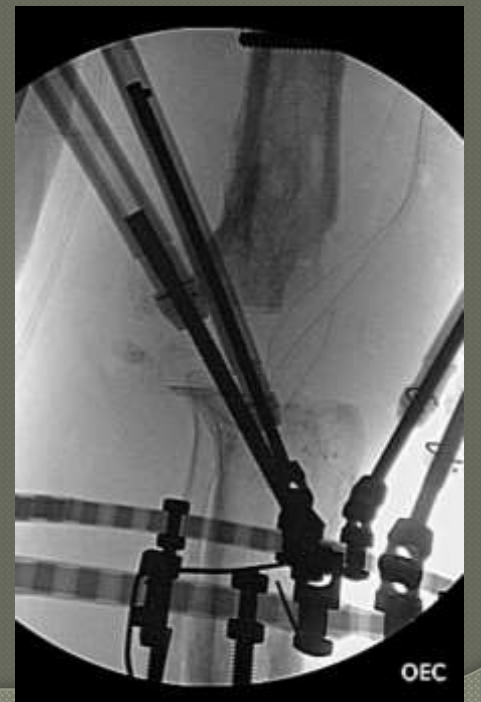OEC



OEC



OEC



OEC

ON  
CH

SION  
ROCH

UD  
E FUSION  
ZBROO

16  
M/2  
7/6/0

27  
34

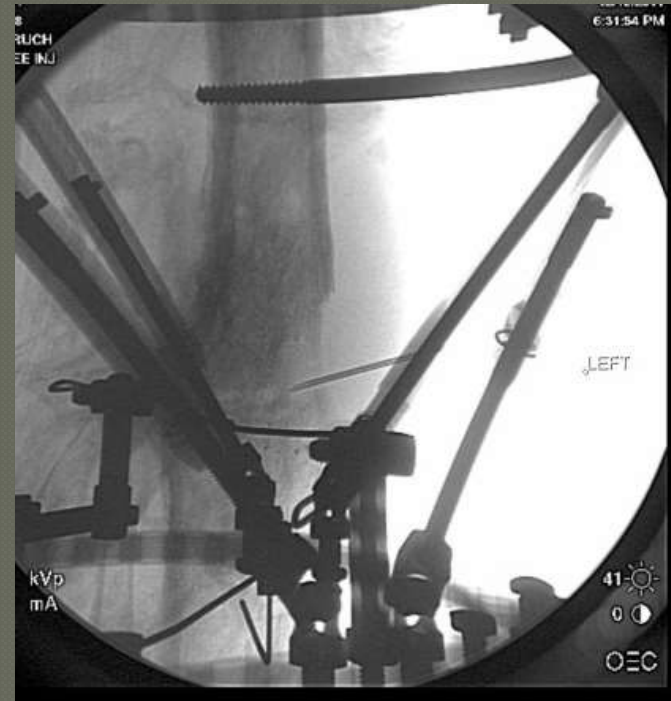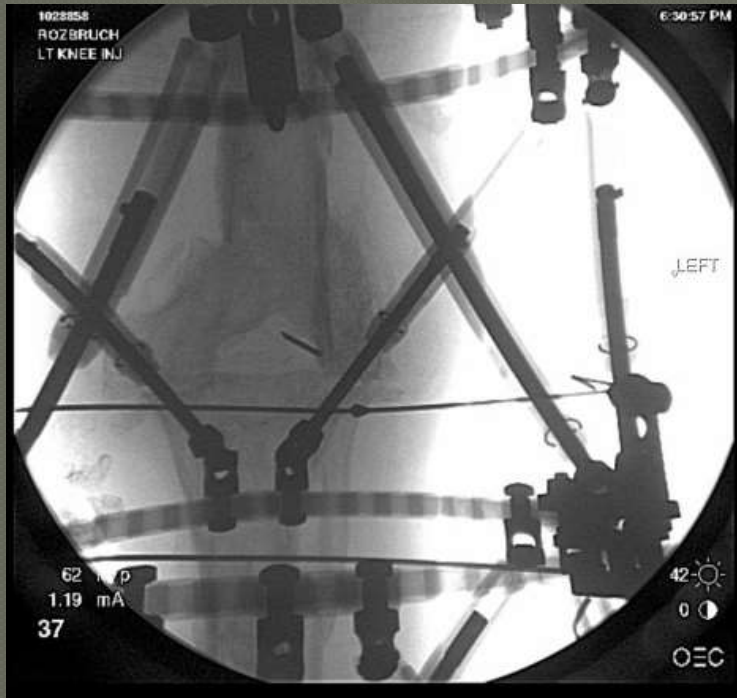KVp  
mA

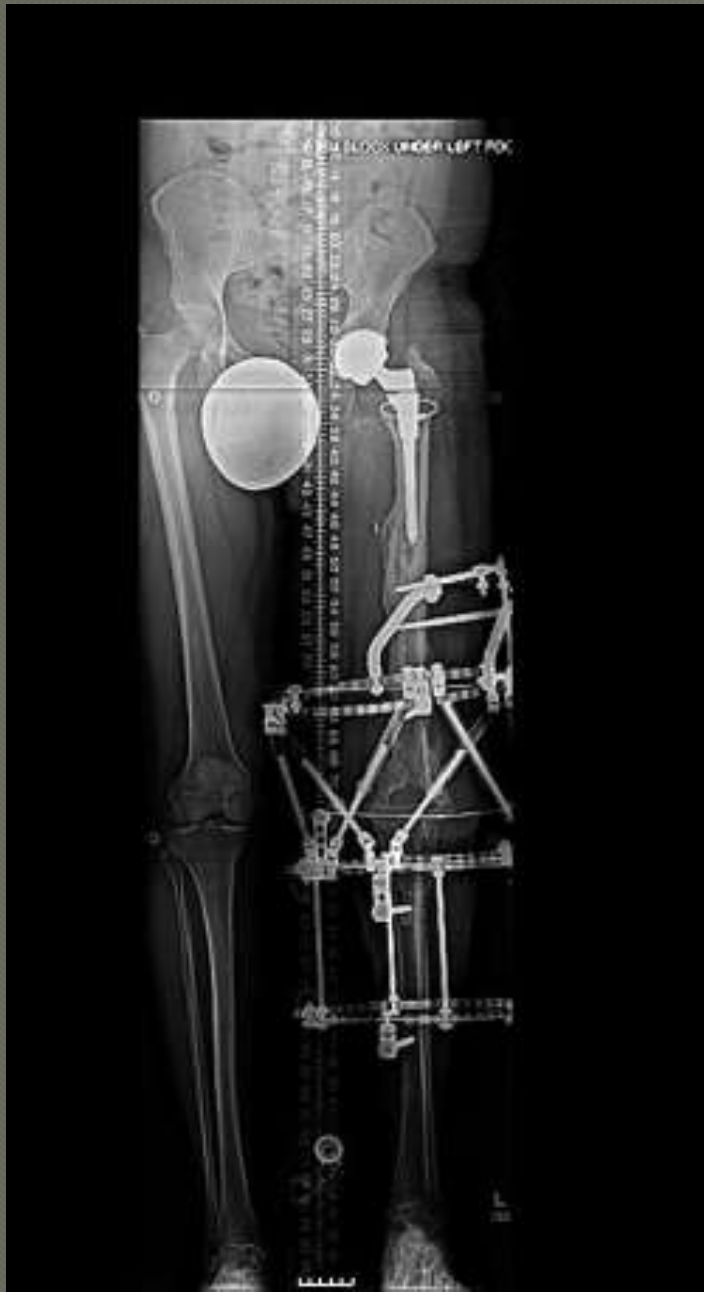HSS  
16/17/2  
5:29:07

24  
40

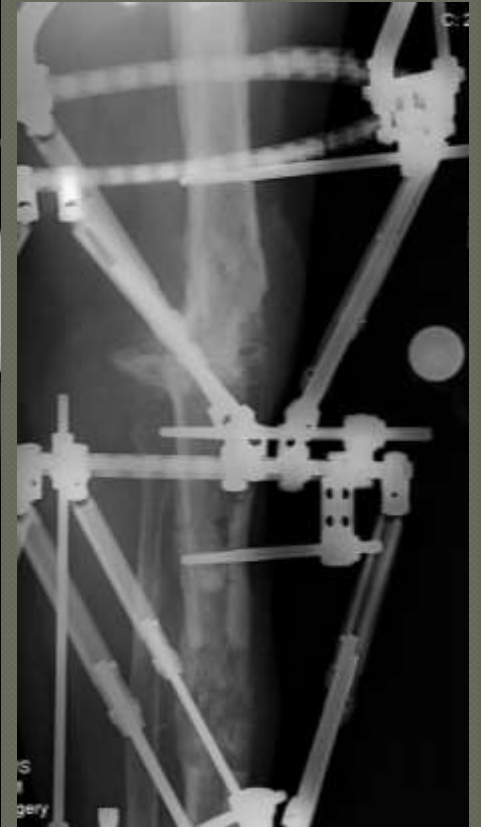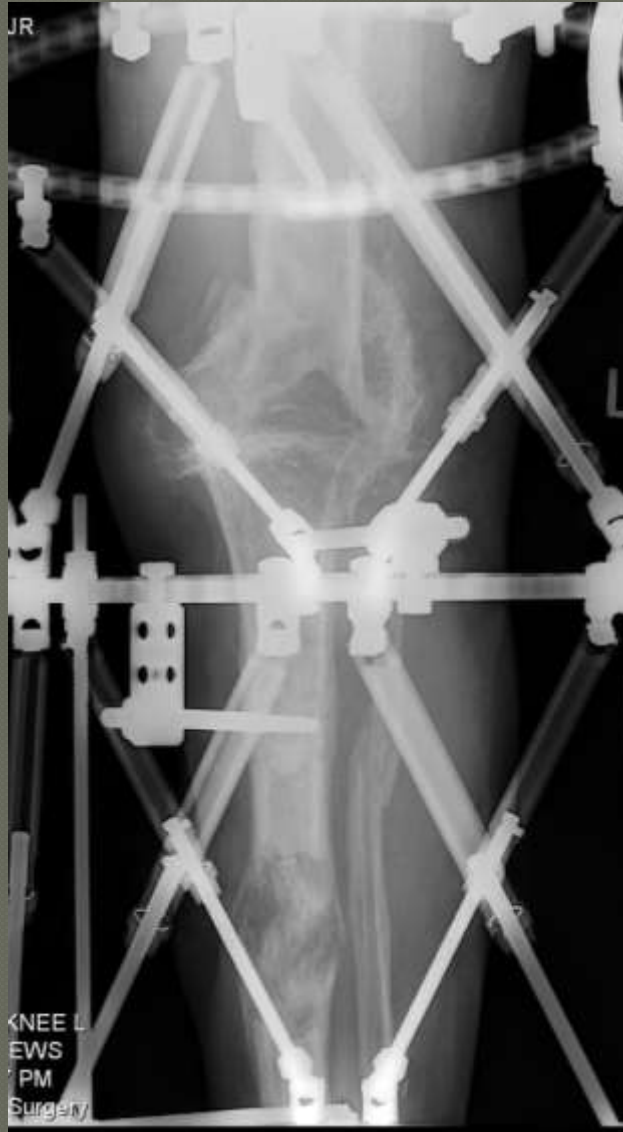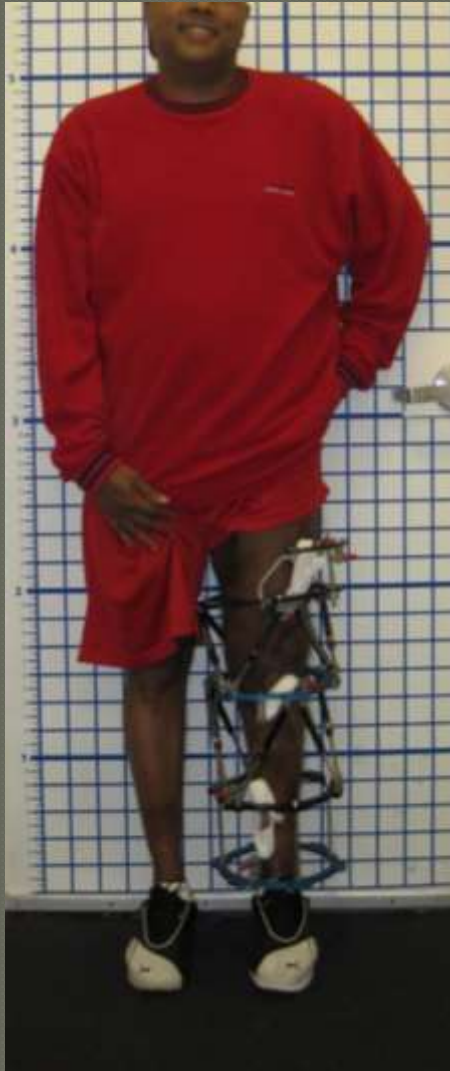L

L



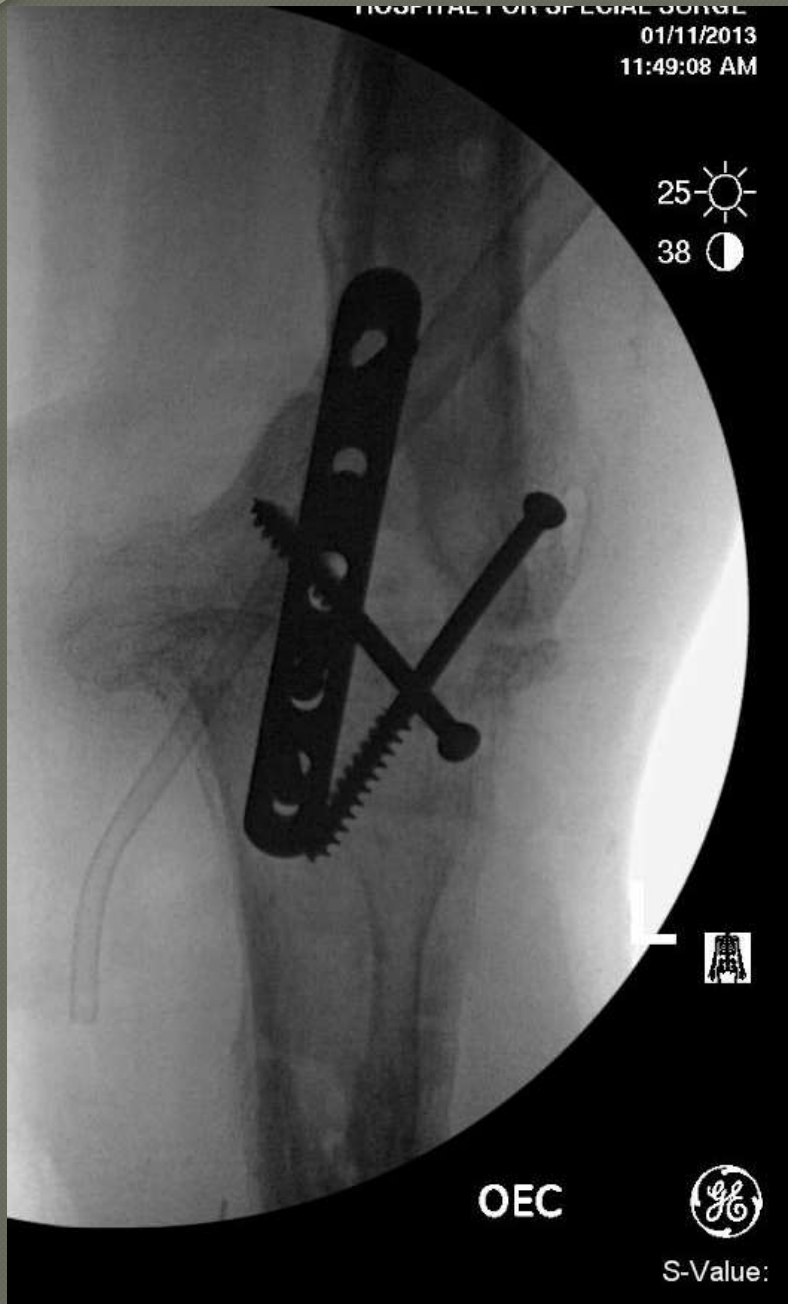


LLD



HOSPITAL FOR SPECIAL SURGE  
01/11/2013  
11:49:08 AM

25 ☀  
38 🌑

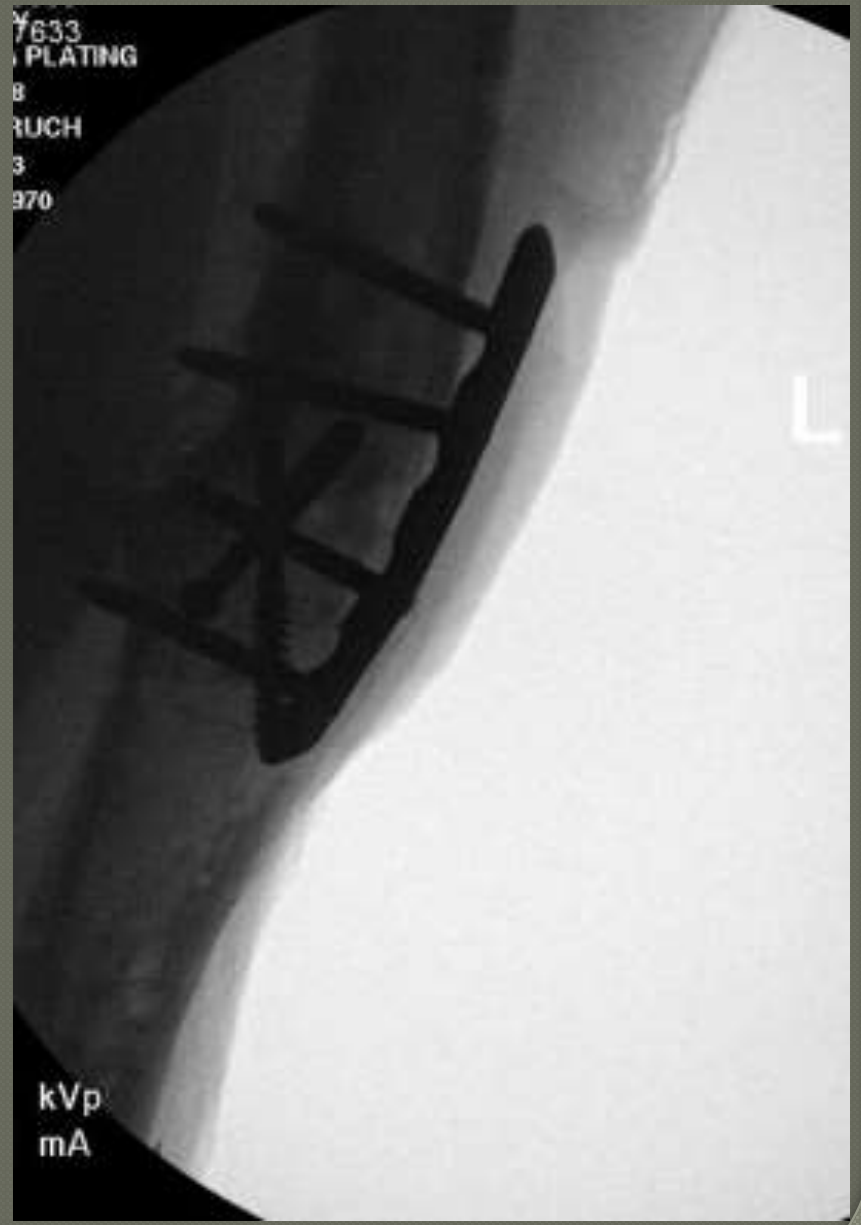


OEC



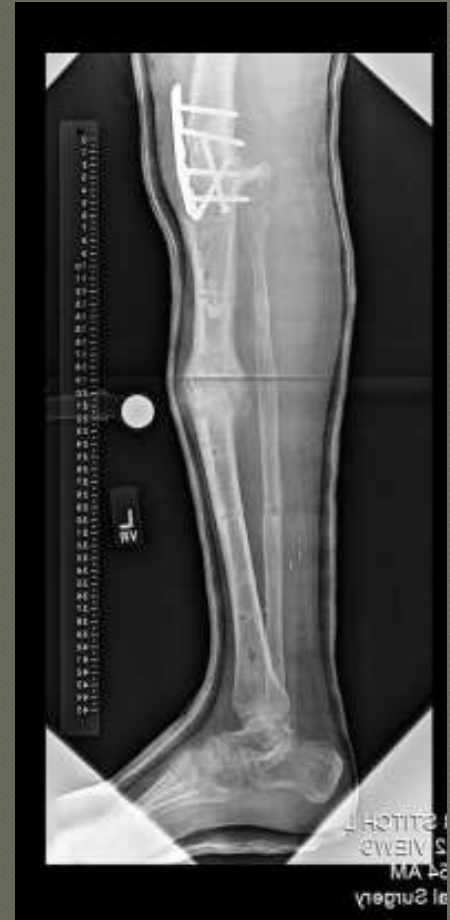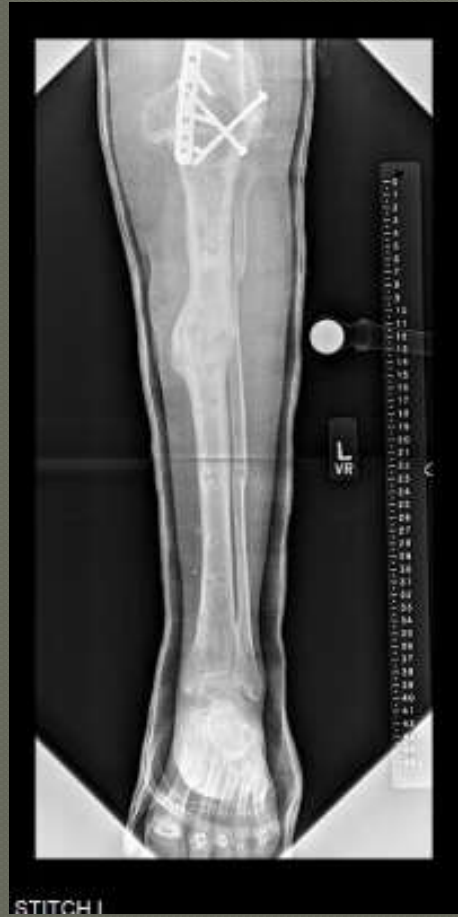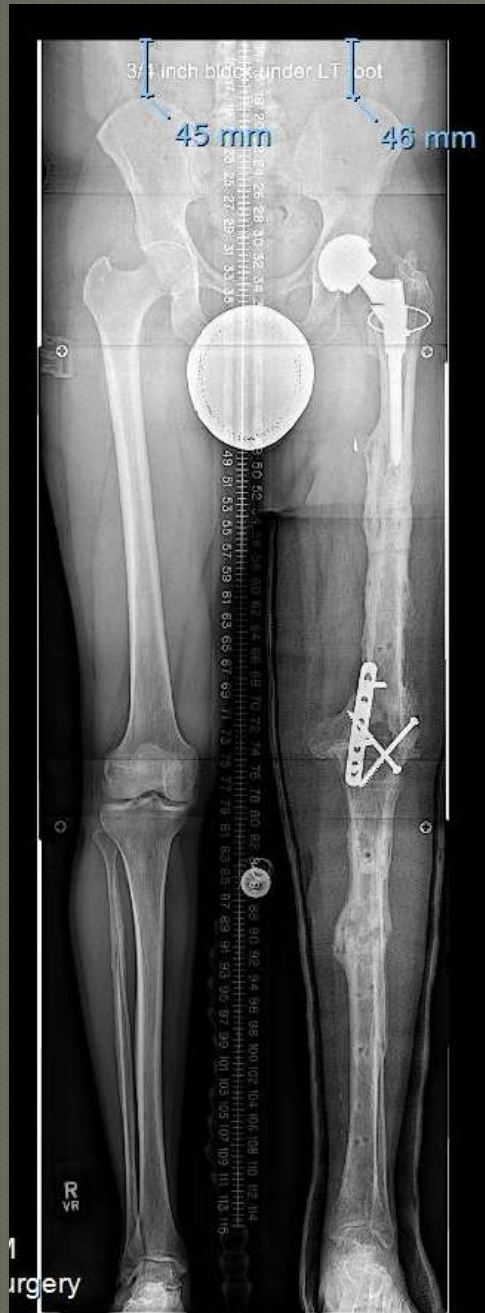
S-Value:

7633  
PLATING  
B  
RUCH  
3  
970

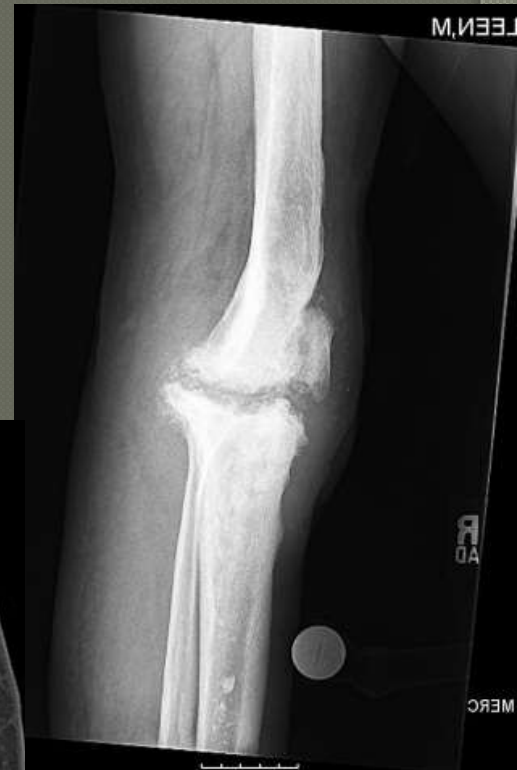
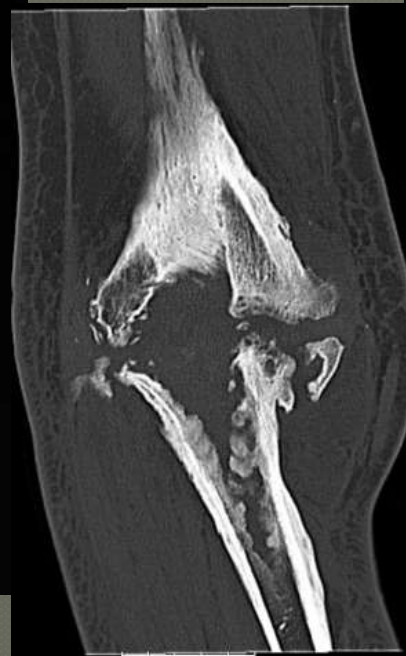
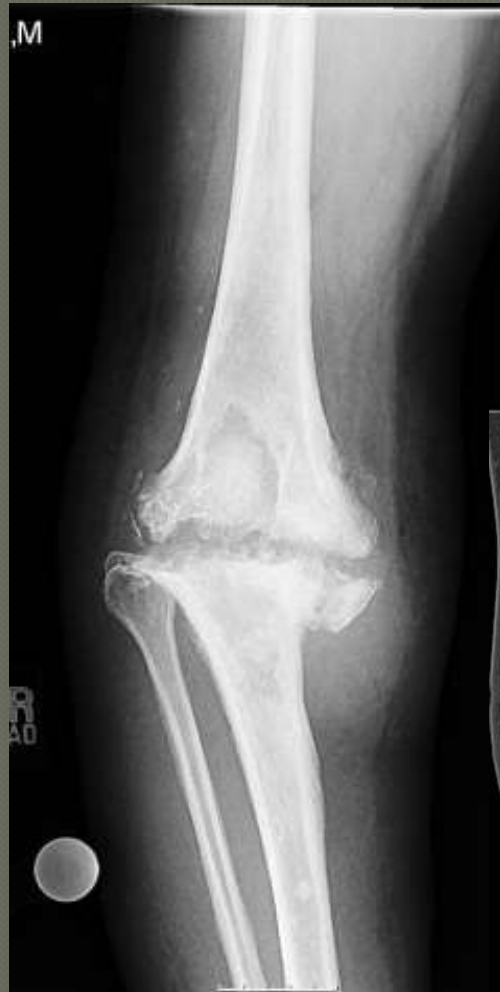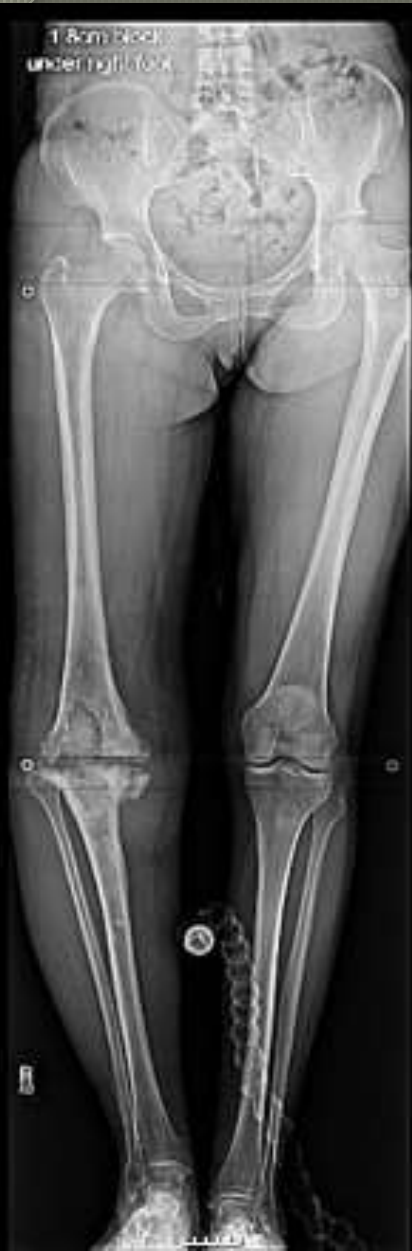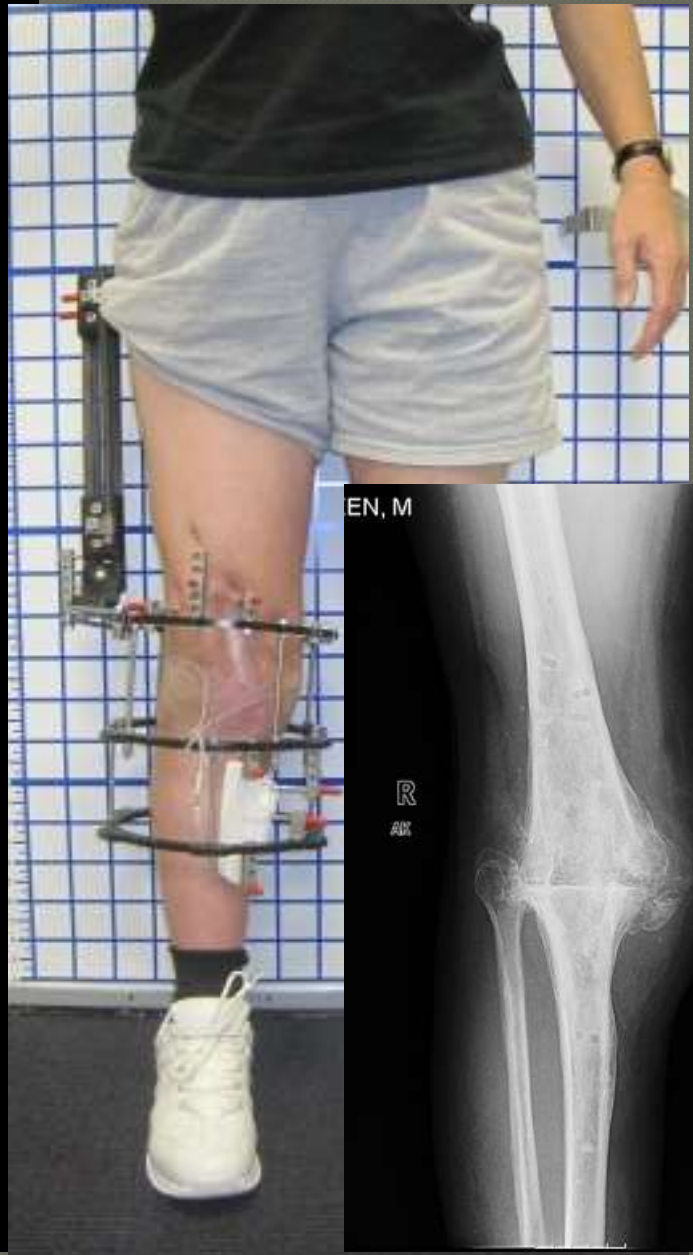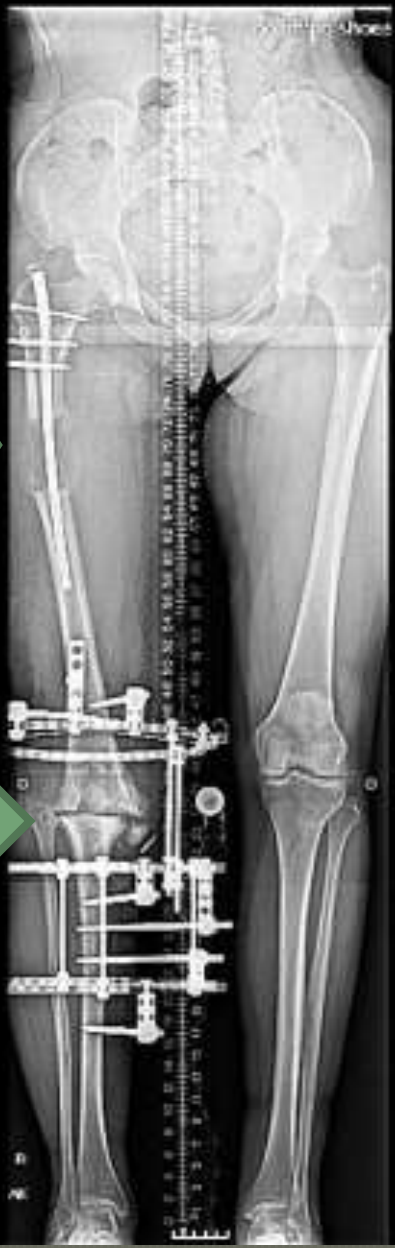kVp  
mA





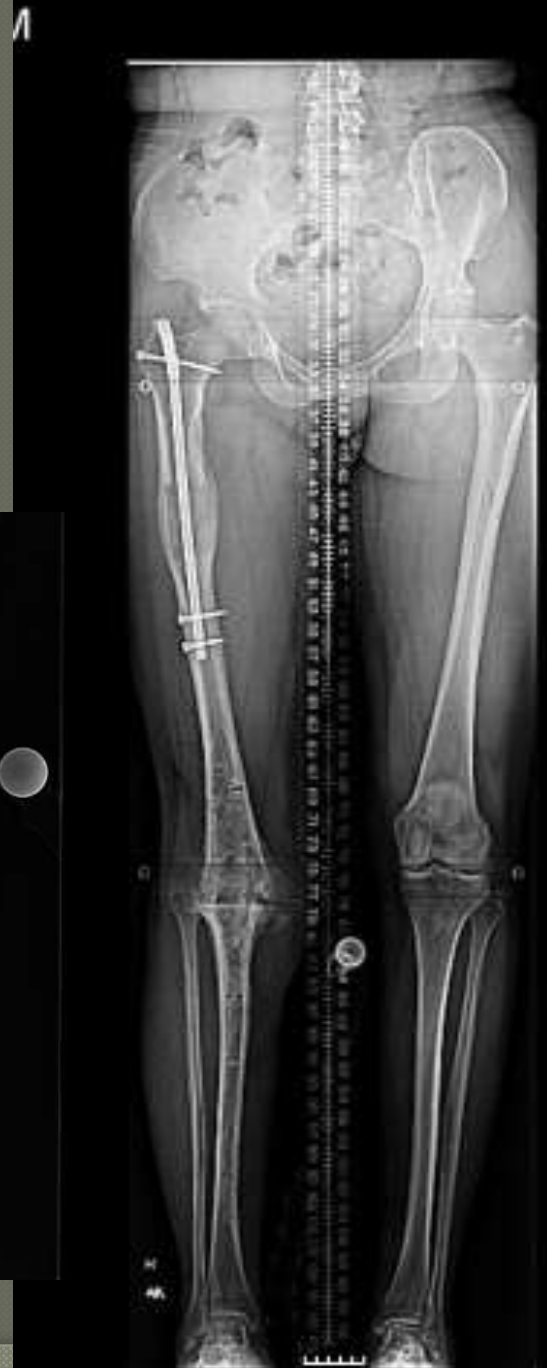





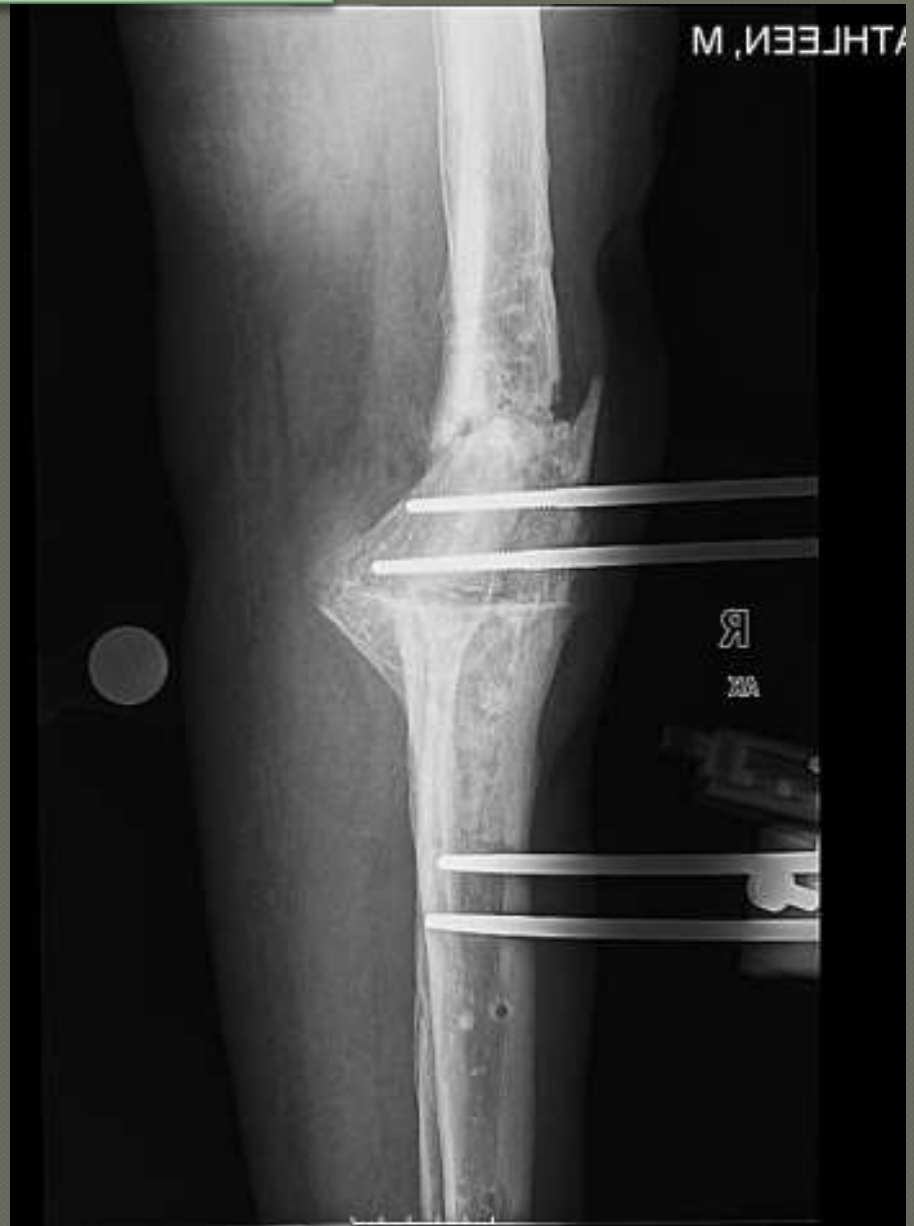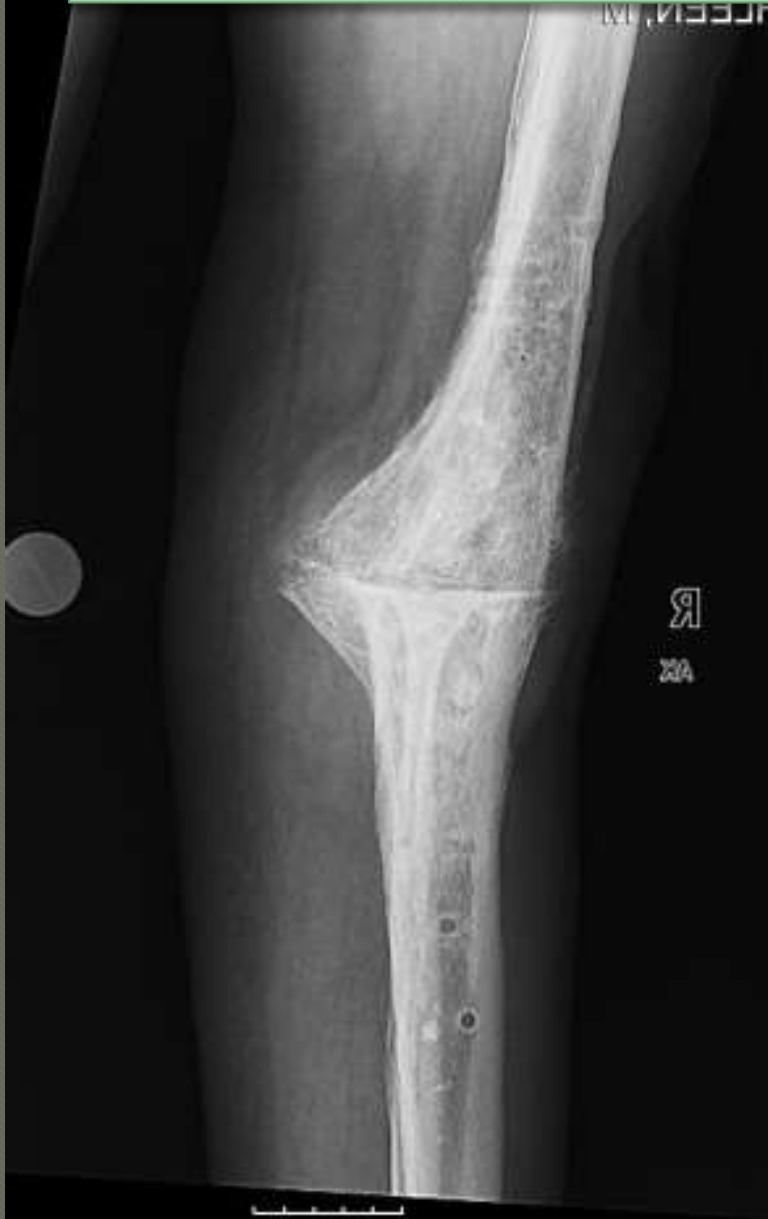EN, M

R  
AK



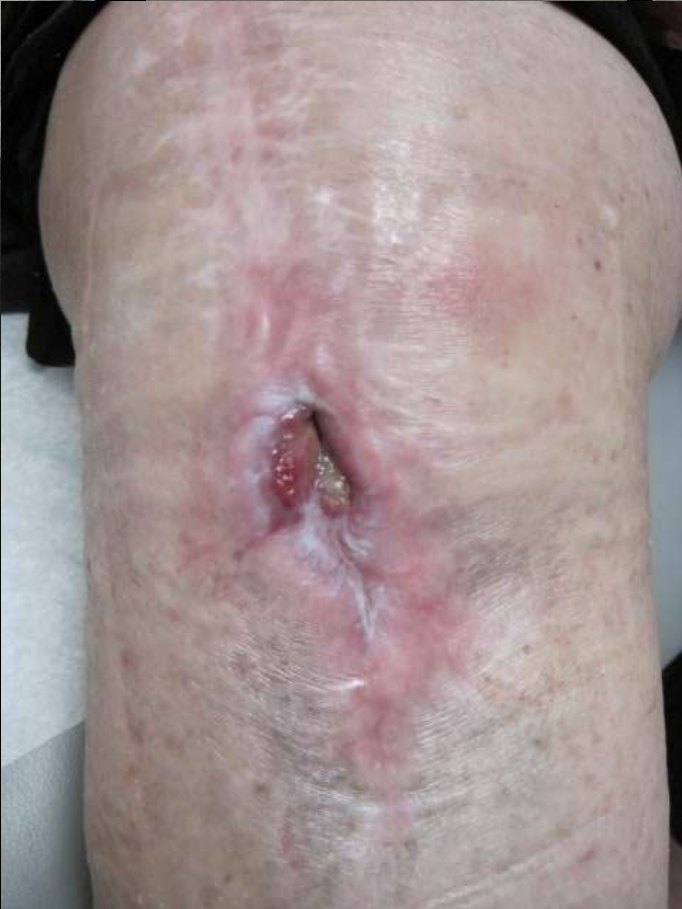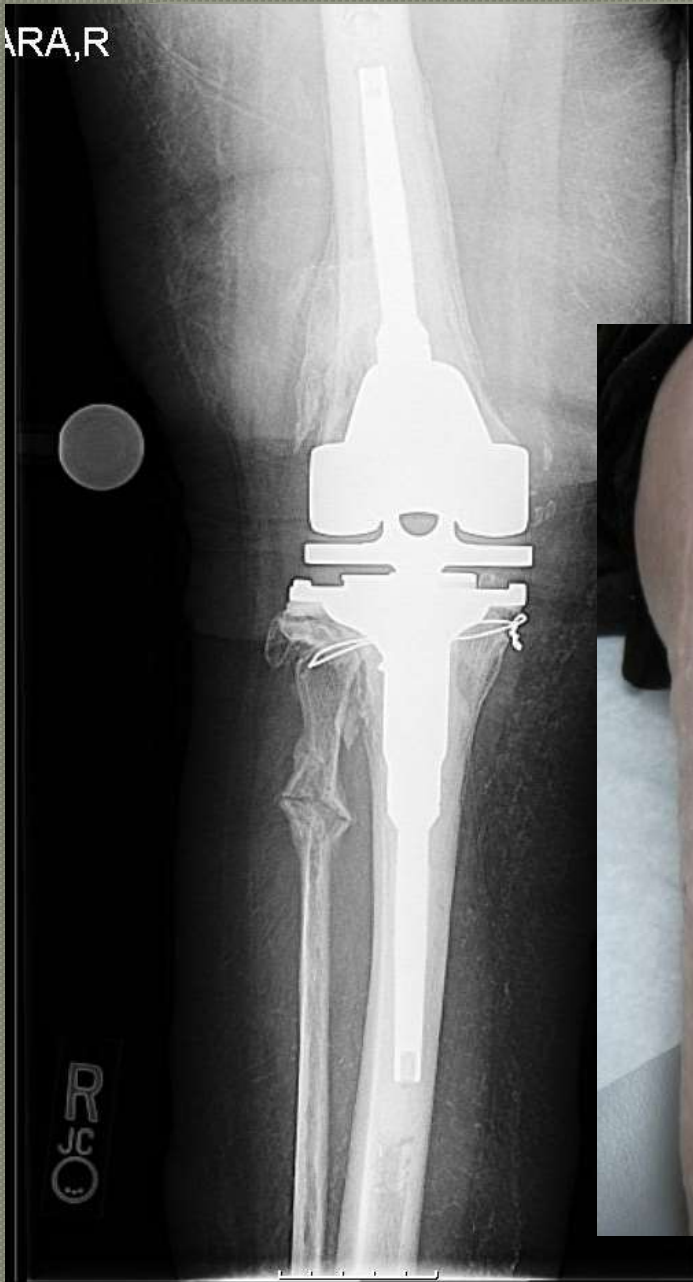1

Extension from ant. bone loss is dysfunctional

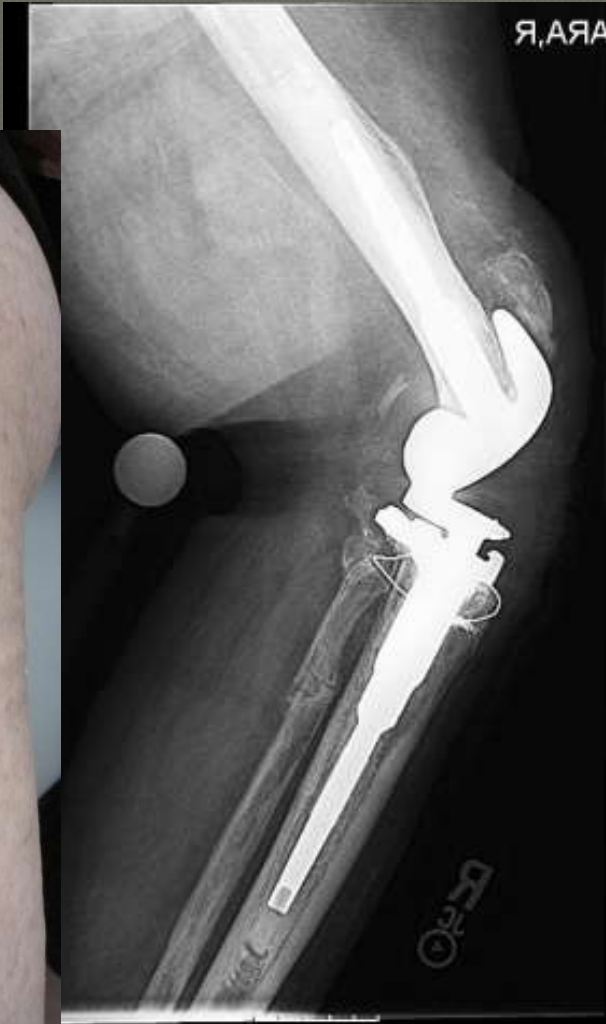


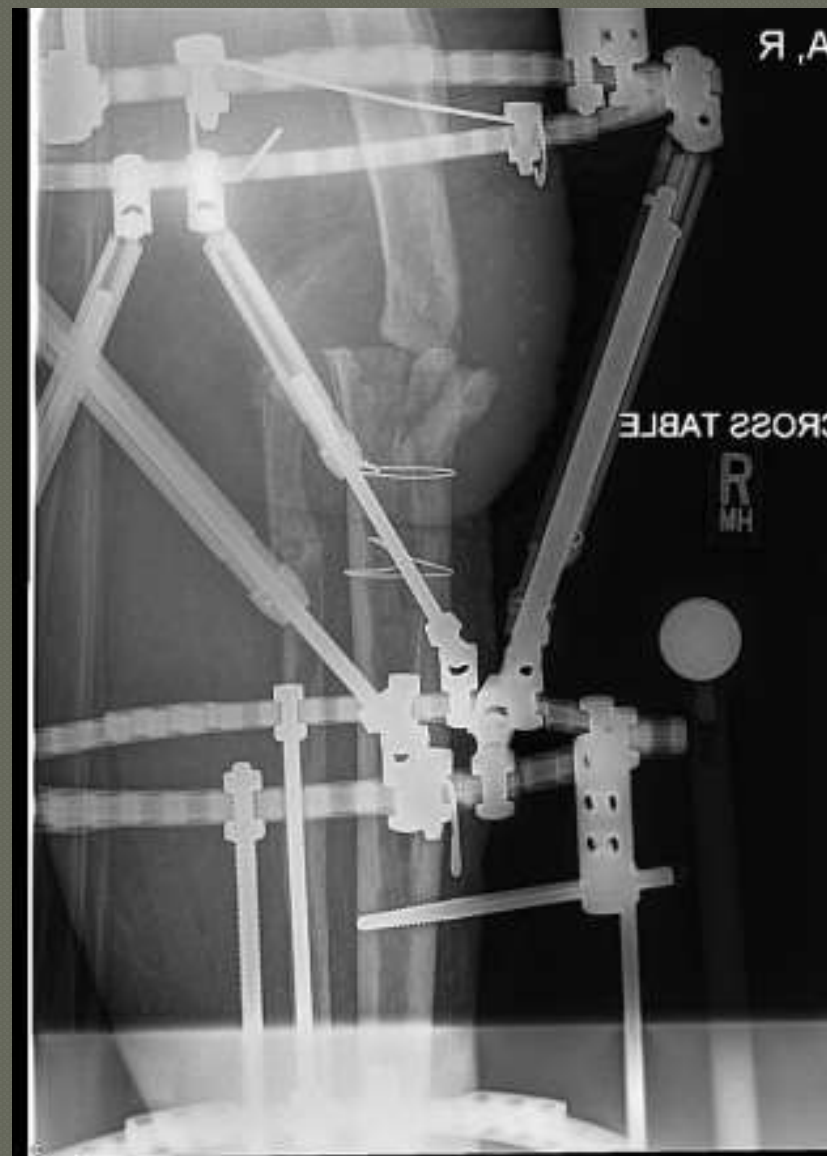

ARA,R



ARBARA,R



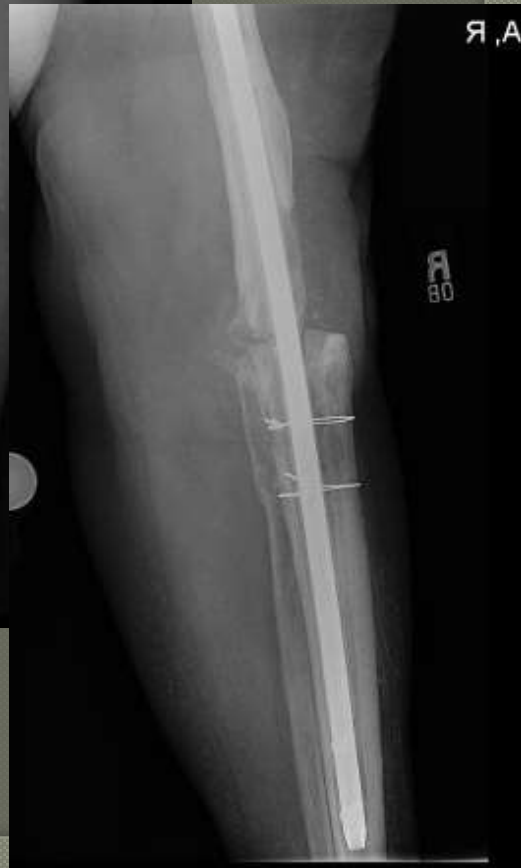
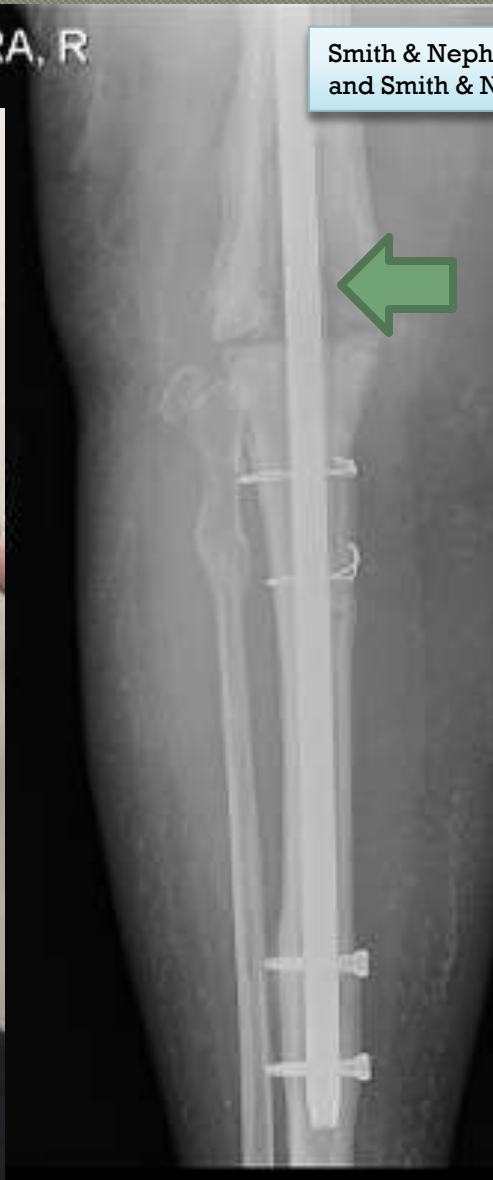
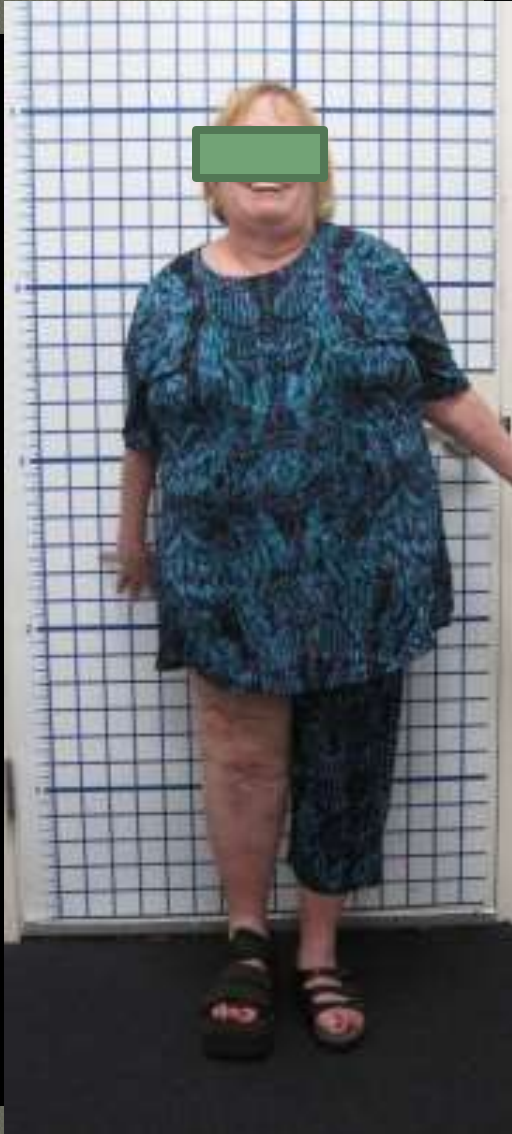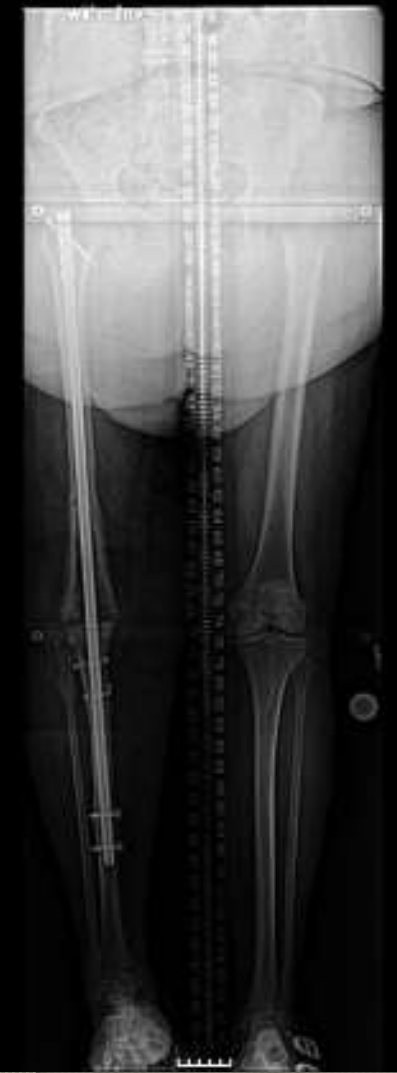Defect closed gradually; poor bone stock for healing

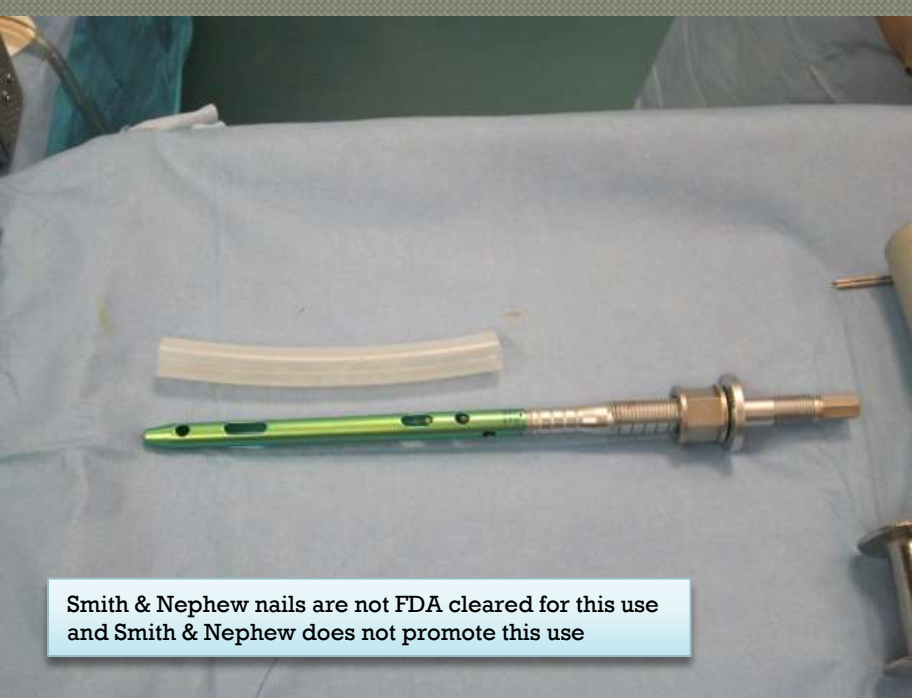


RA, R

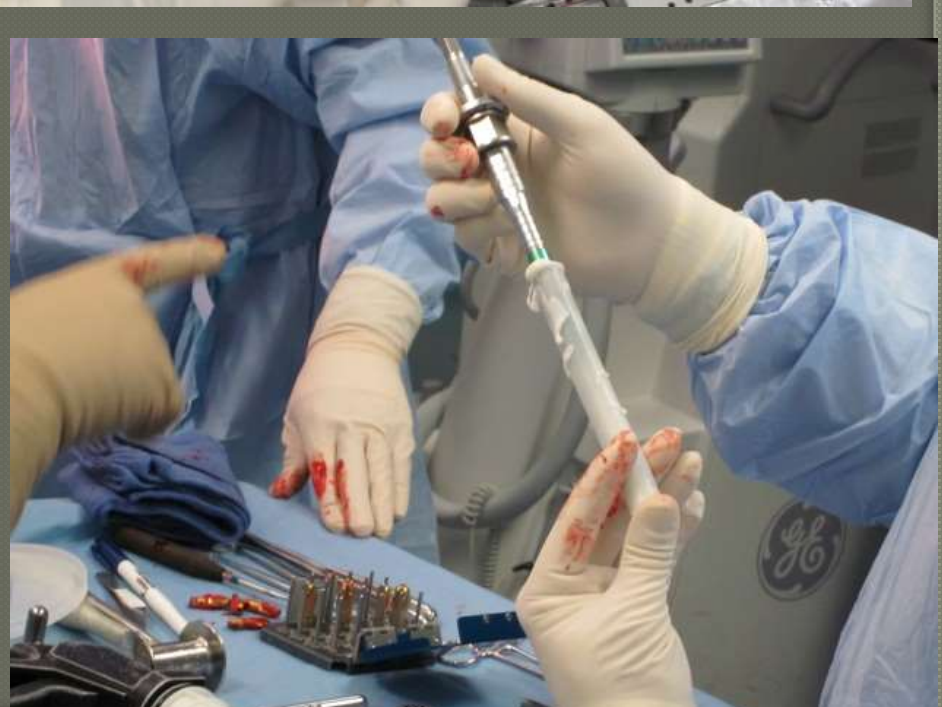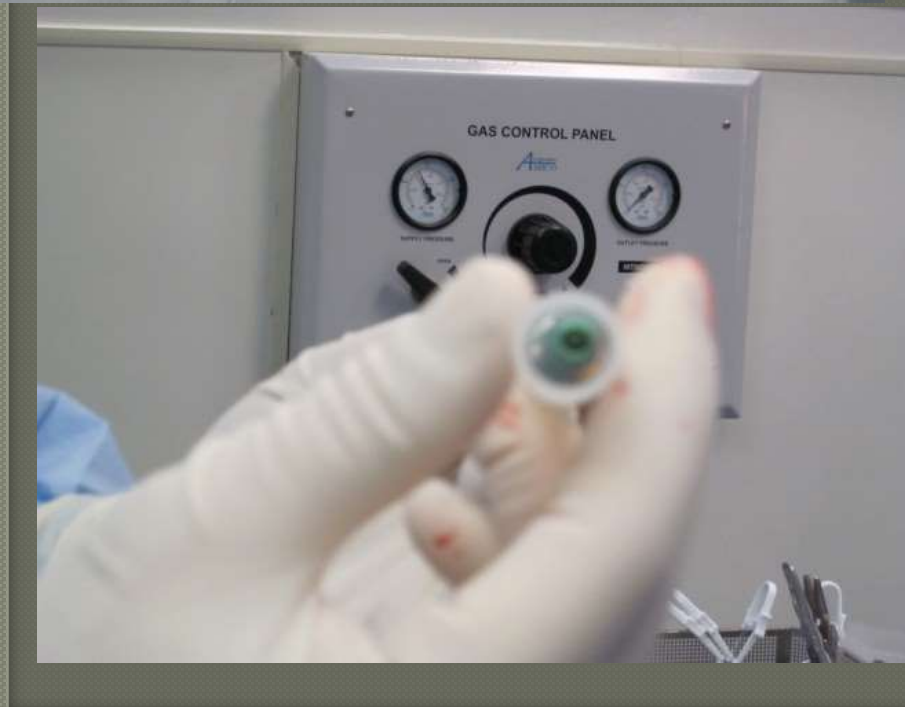
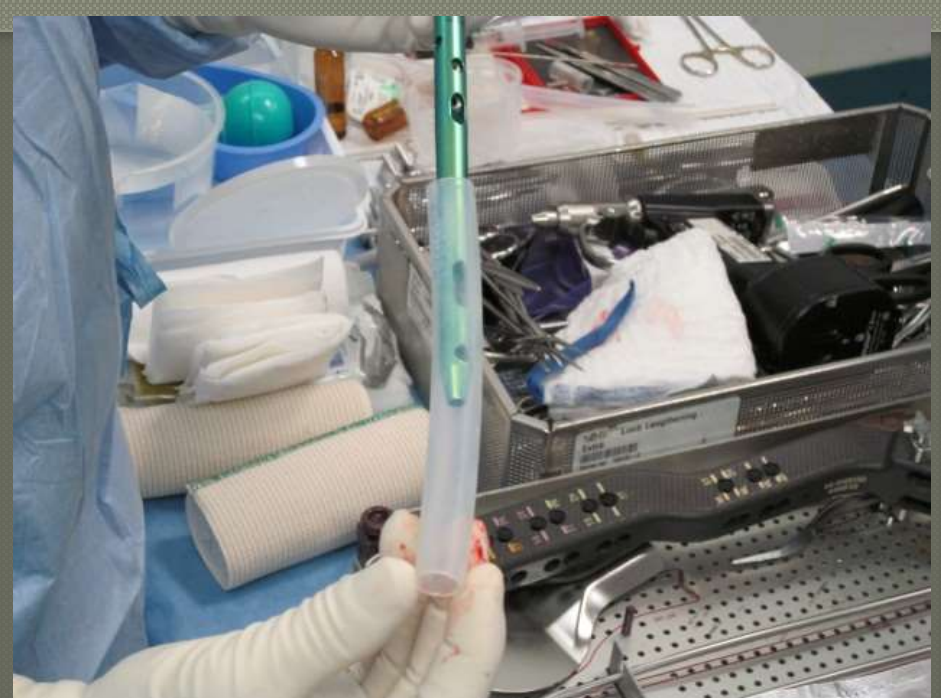Smith & Nephew nails are not FDA cleared for this use and Smith & Nephew does not promote this use



Secondary IM nailing with antx coated rod

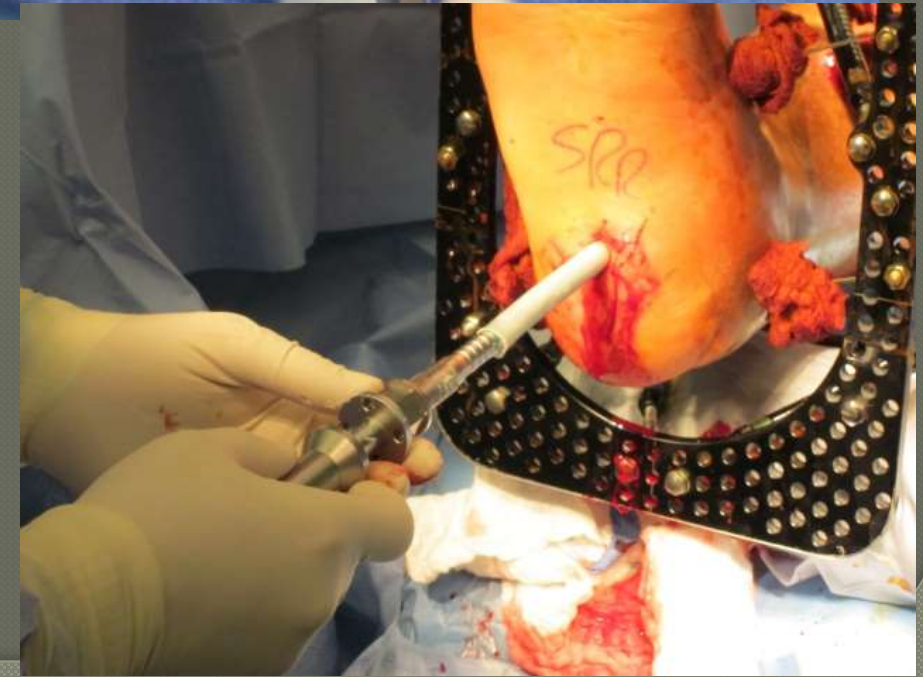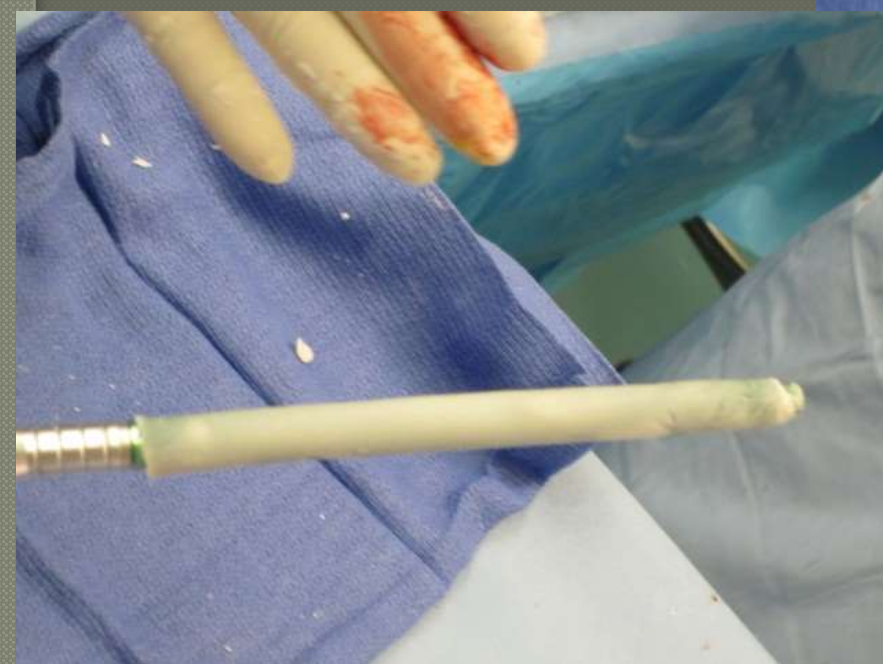

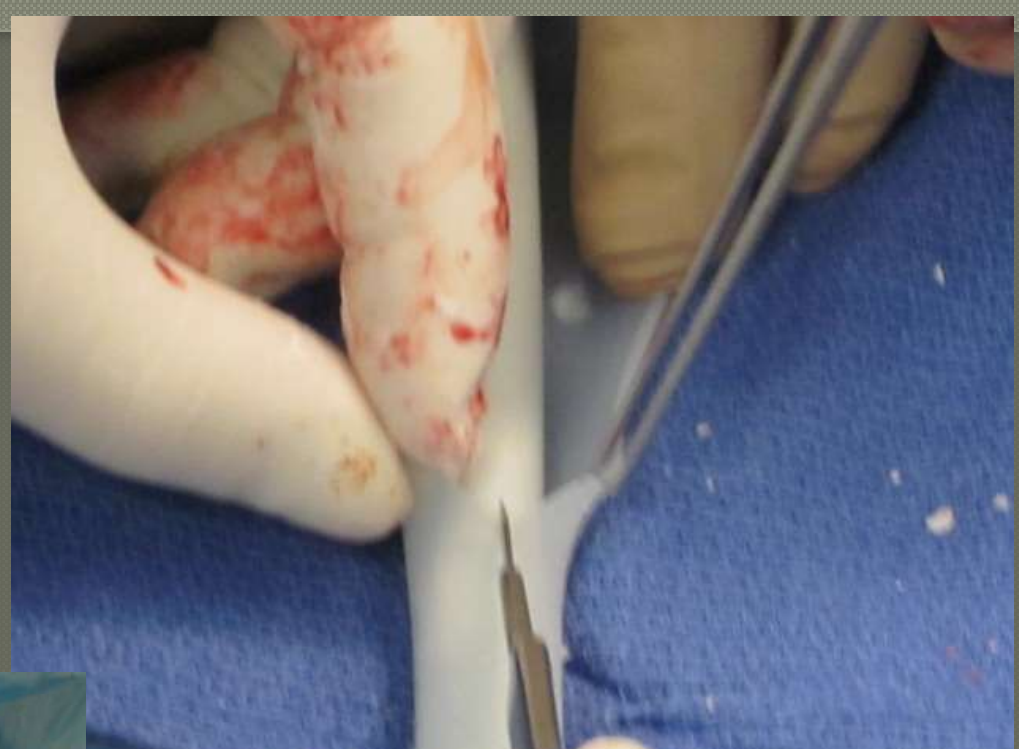
Smith & Nephew nails are not FDA cleared for this use and Smith & Nephew does not promote this use



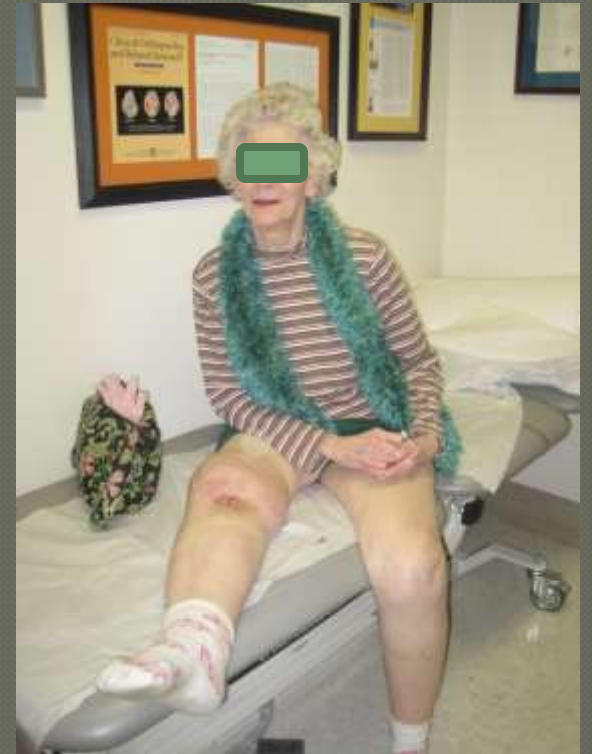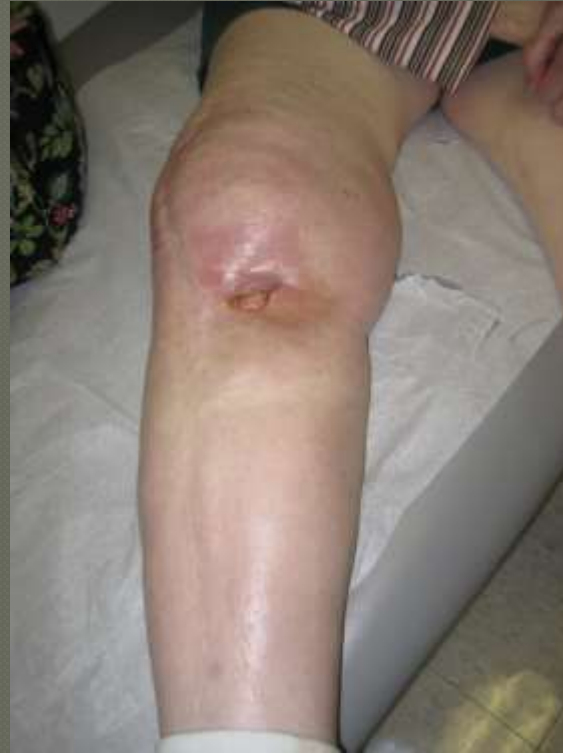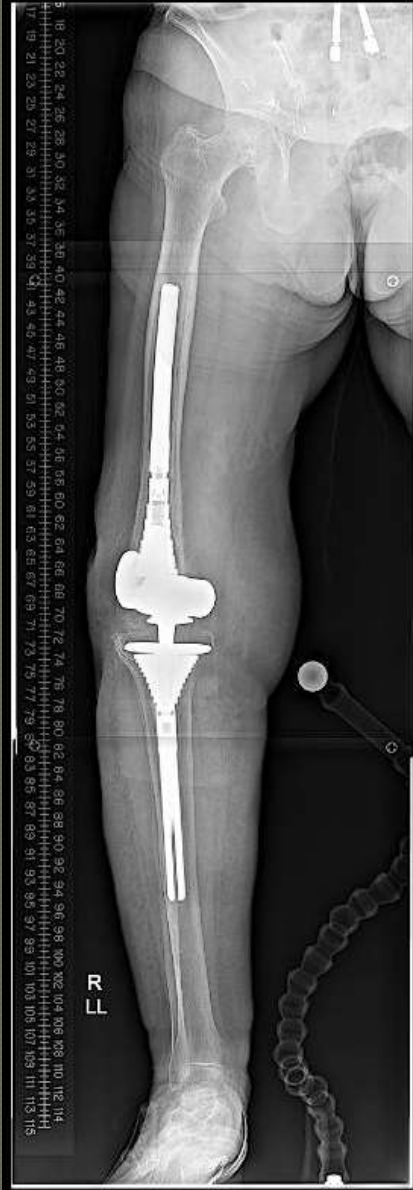(1.0) 3.4 T

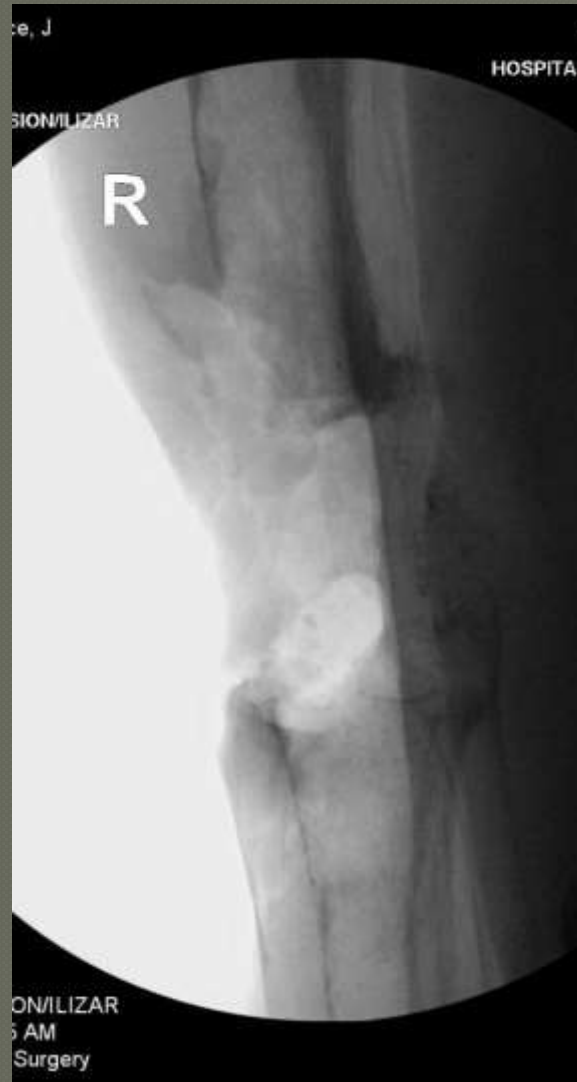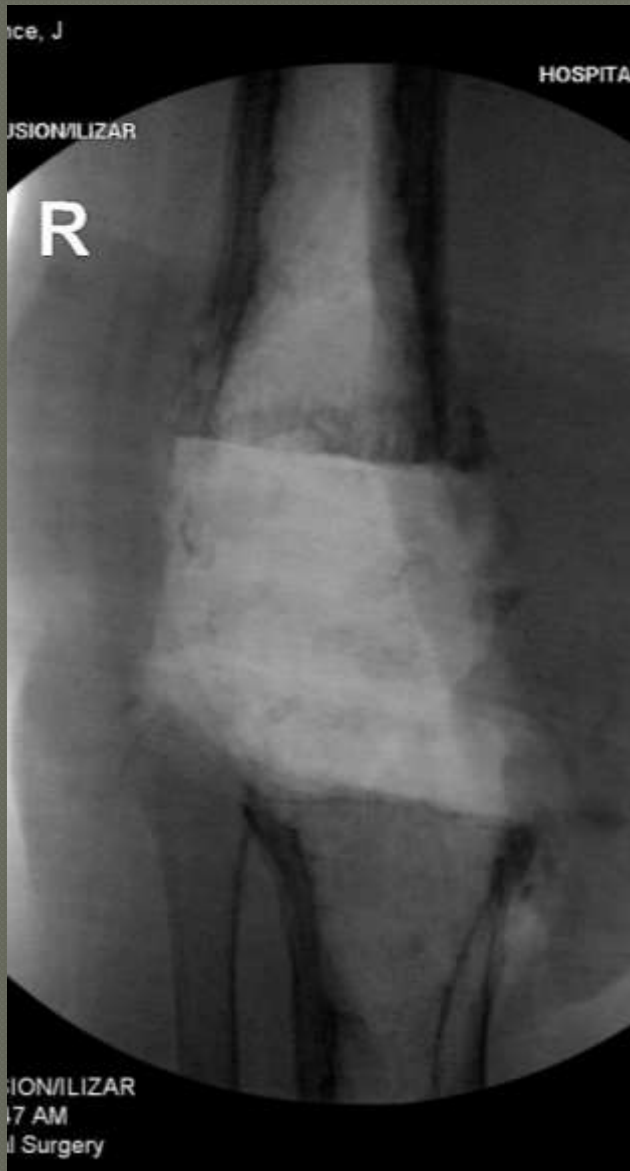2g Vanco  
3.4g Tobra.  
per bag cement

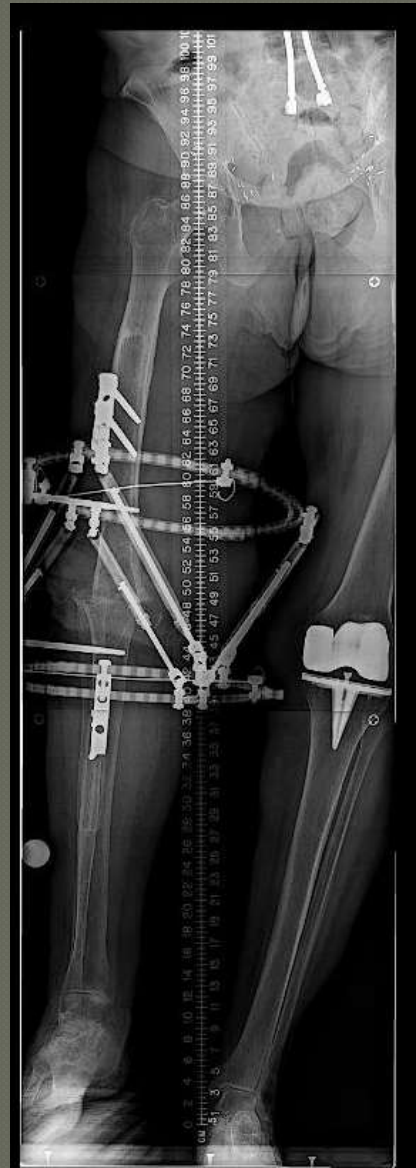
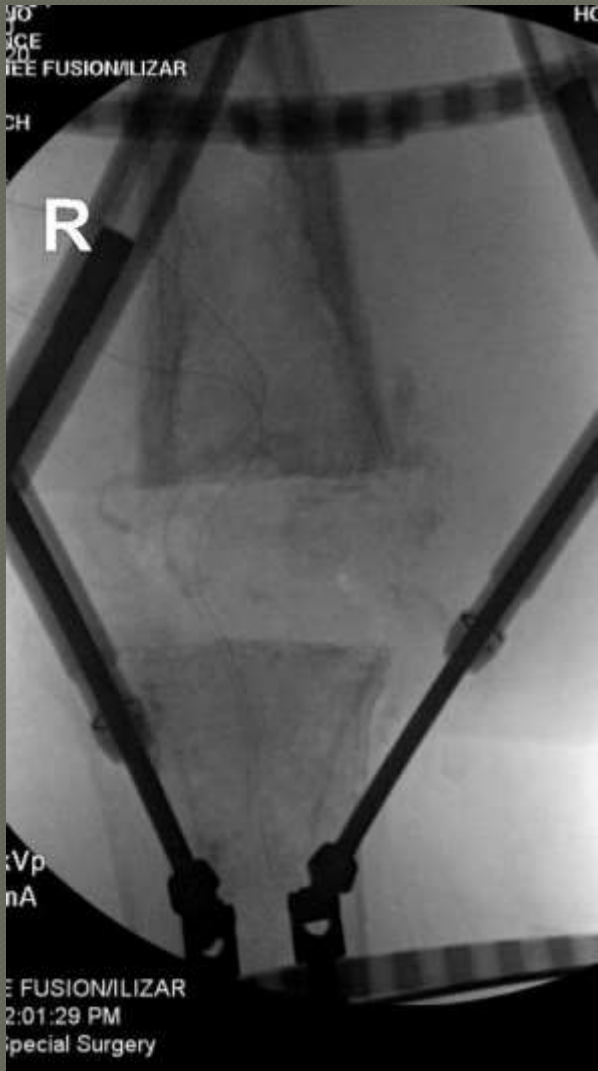

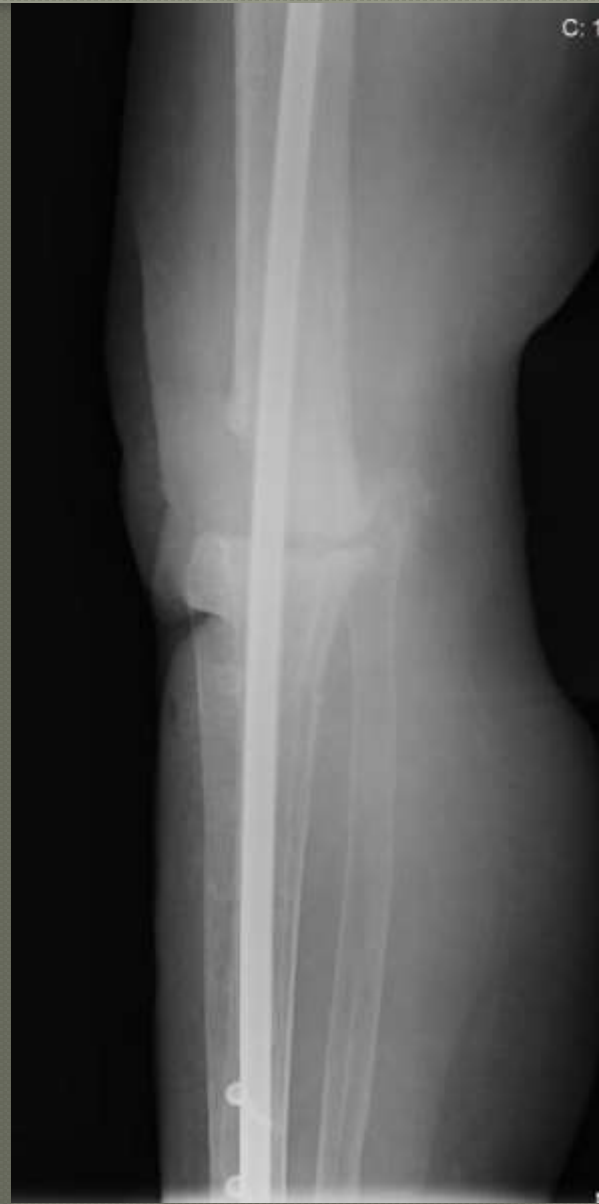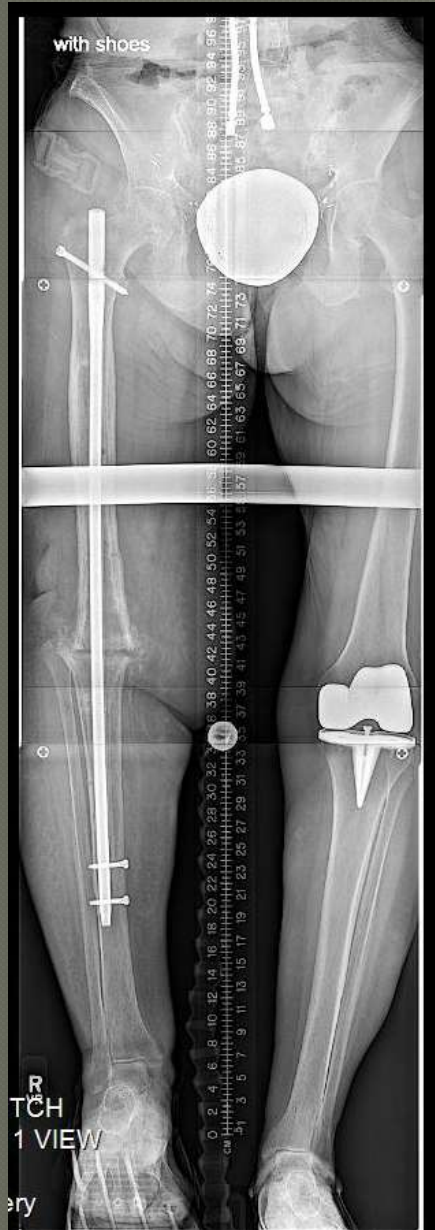Smith & Nephew nails are not FDA cleared for this use  
and Smith & Nephew does not promote this use







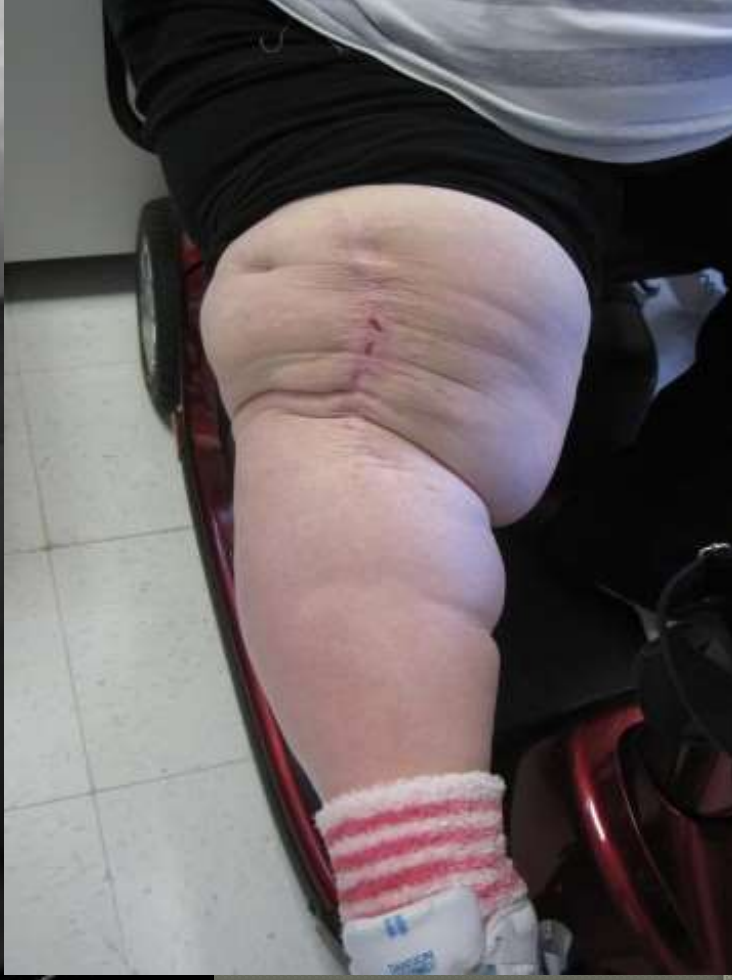
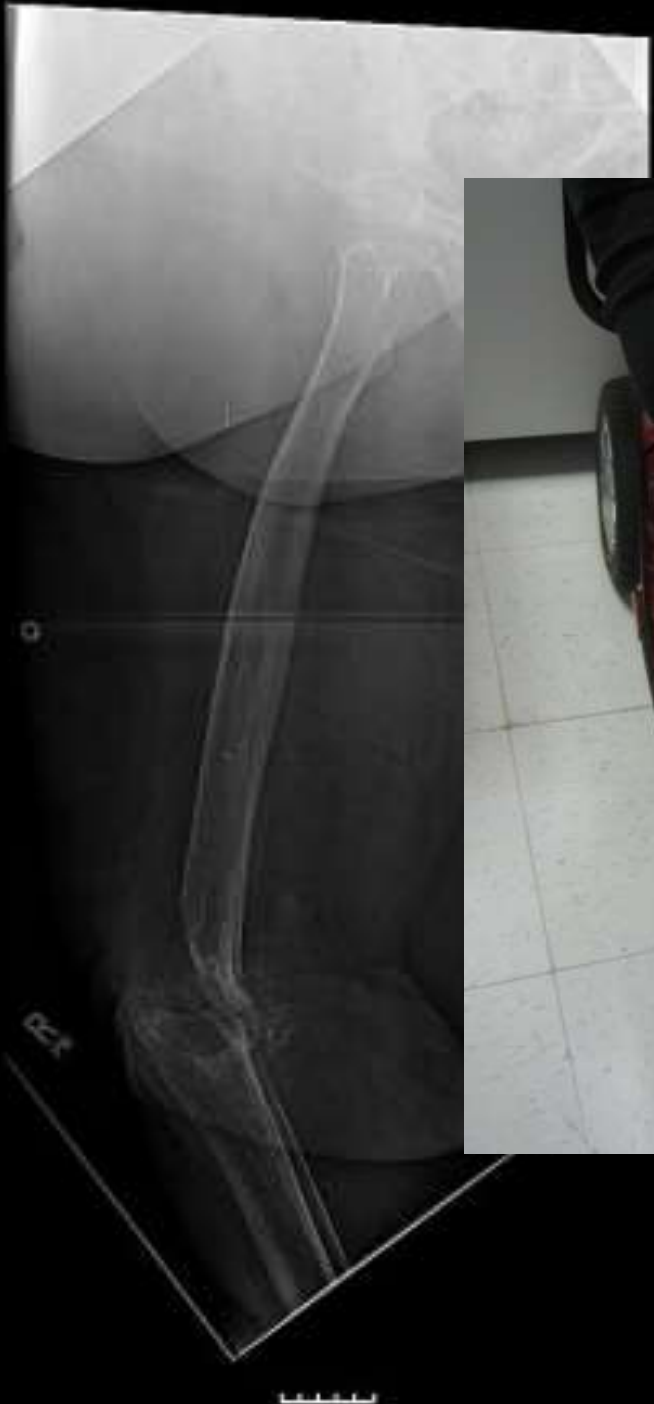
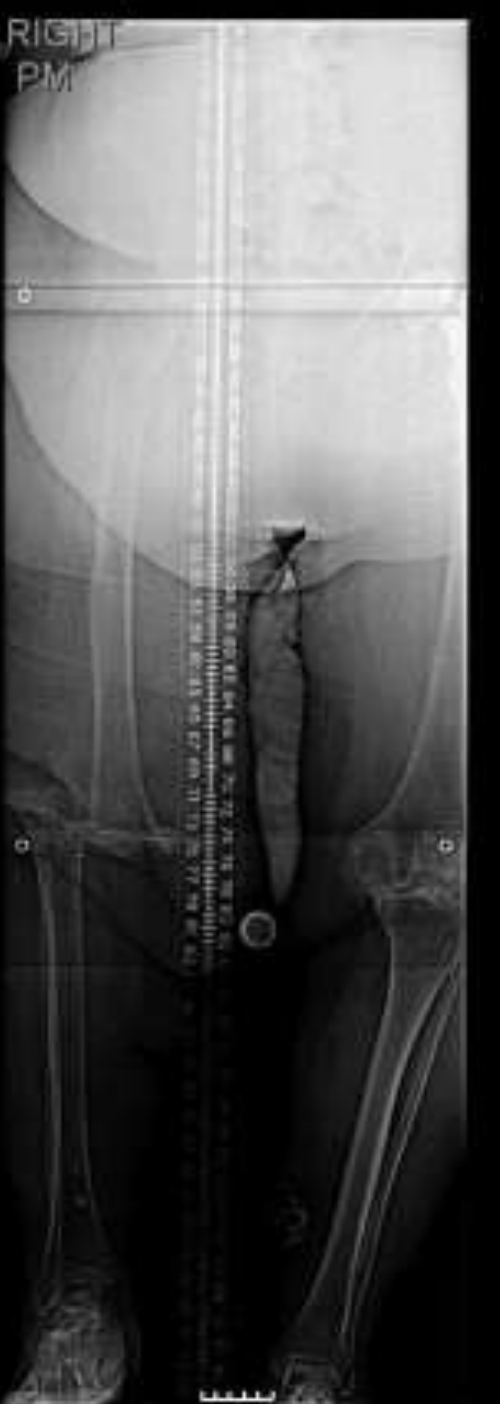


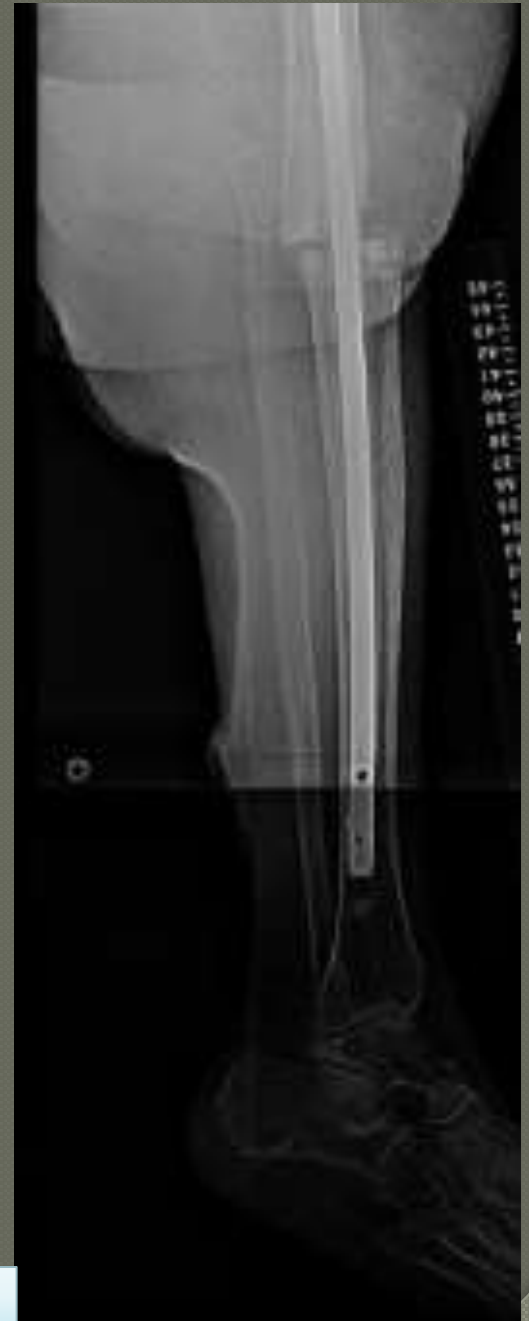
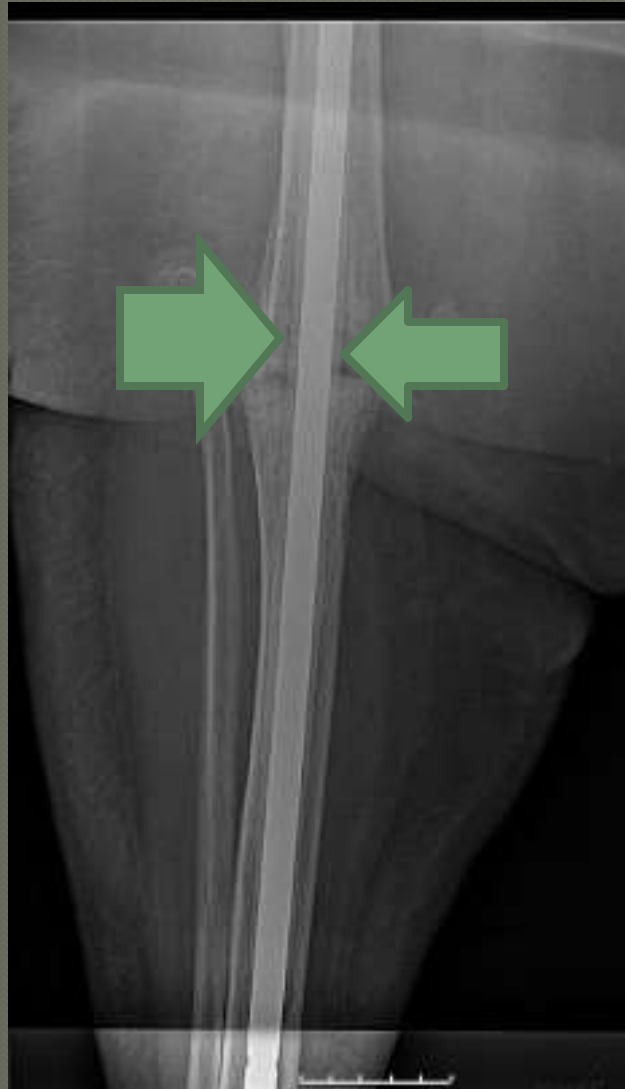
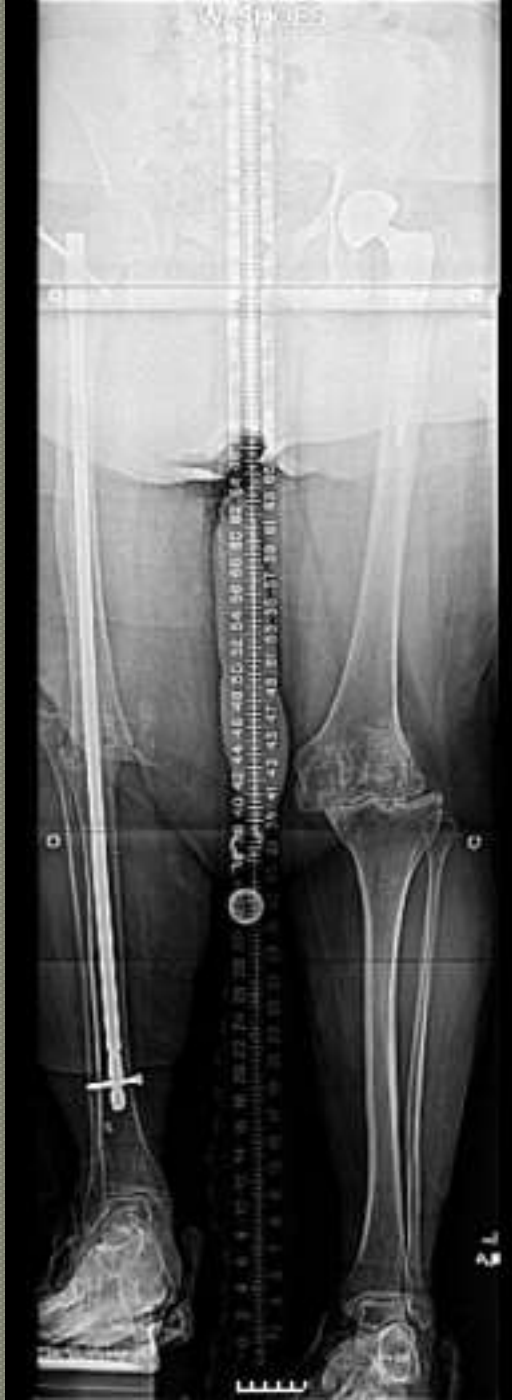
RIGHT  
PM





Smith & Nephew nails are not FDA cleared for this use and Smith & Nephew does not promote this use



# What have I learned?

## ◎ Soft-tissue

- Medial & lateral approaches
- Gradual shortening
- Use VAC

## ◎ Knee fusion

- 10 deg. Flexion
- 1.5 cm shortening
- One stage surgery/ avoid large spacers
- Easier with fewer revision surgeries
- IM rod is good when bone stock poor
- Antibiotic coated locked rod
- MIS PC plating /screws to prevent refracture

Smith & Nephew nails are not FDA cleared for this use  
and Smith & Nephew does not promote this use

# Advantages of Ilizarov

- Great stability from multi-planar frame
- Less risk in active or h/o infection
- Ability to achieve precise anatomic alignment
- Adjustment of position post-operatively
- Gradual compression to stimulate arthrodesis
- Ability to be WBAT
- Easy to remove
- *Simultaneous lengthening or bone transport*

# Discussion

- Knee arthrodesis and simultaneous leg lengthening can be done successfully
- Optimize leg lengths during arthrodesis
- Optimal leg alignment
- Advantageous in presence or history of infection

# Summary

- Main indications for knee arthrodesis is destroyed knee joint with infection and bone loss
- Ilizarov frame is advantageous
- Fusion alone results in excessive LLD
- Simultaneous lengthening can optimize LLD to about 1.5 cm in young patient
- Older patient-would use shoe lift
- Equinus contracture is problem
- Would lengthen distal femur ideally if possible



# Knee Arthrodesis as Limb Salvage for Complex Failures of Total Knee Arthroplasty

LLRS 7/27/12

Raul Kuchinad MD FRCSC, Austin T. Fragomen MD, S. Robert Rozbruch MD  
Hospital for Special Surgery  
New York, NY



**HOSPITAL FOR  
SPECIAL SURGERY**

LIMB .COM

The logo for Limb Lengthening features the word "LENGTHENING" in blue, enclosed within a black rectangular frame that has tick marks on all four sides, resembling a measurement tool.

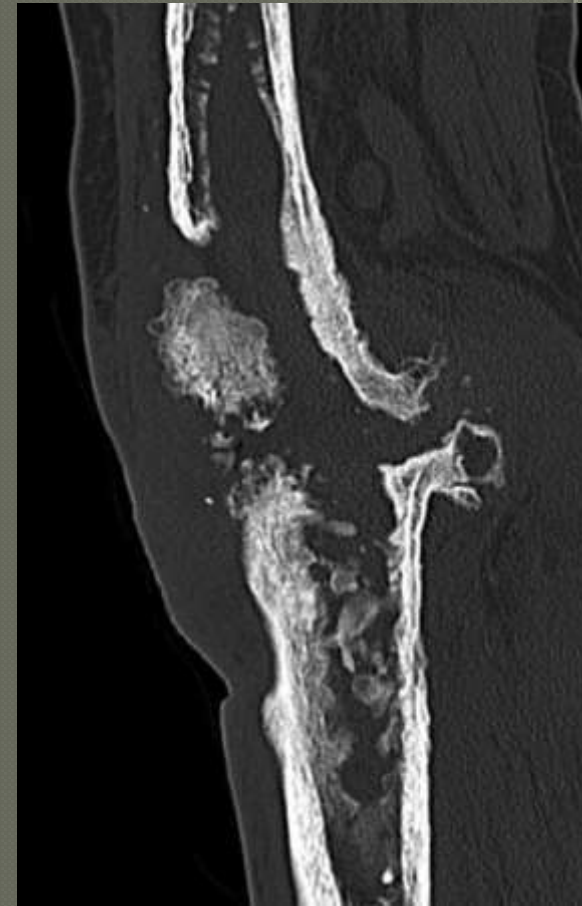
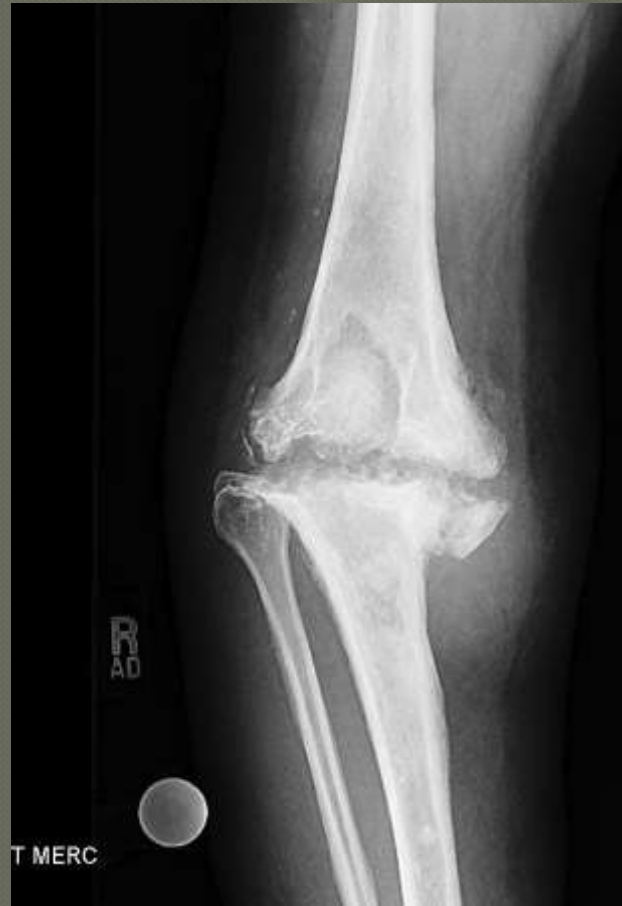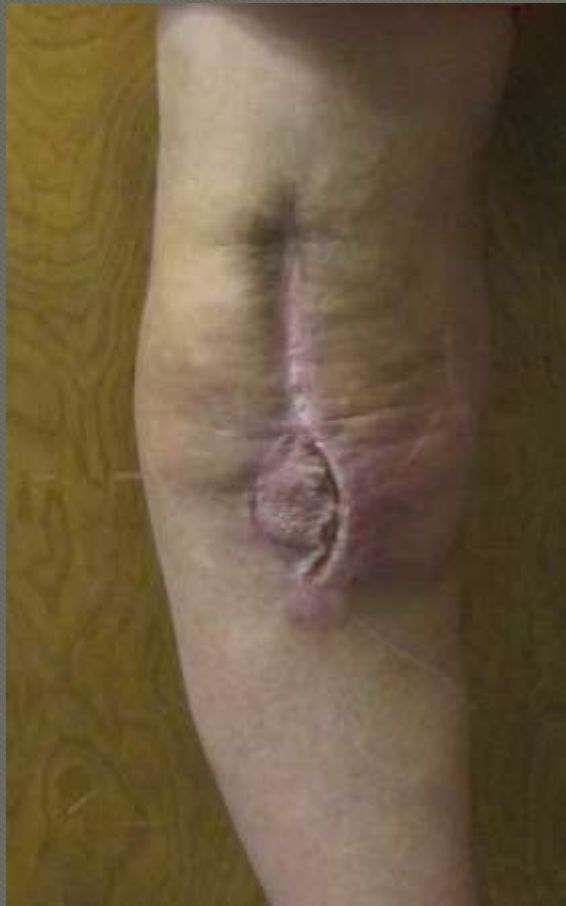# Disclosures

- No Disclosures

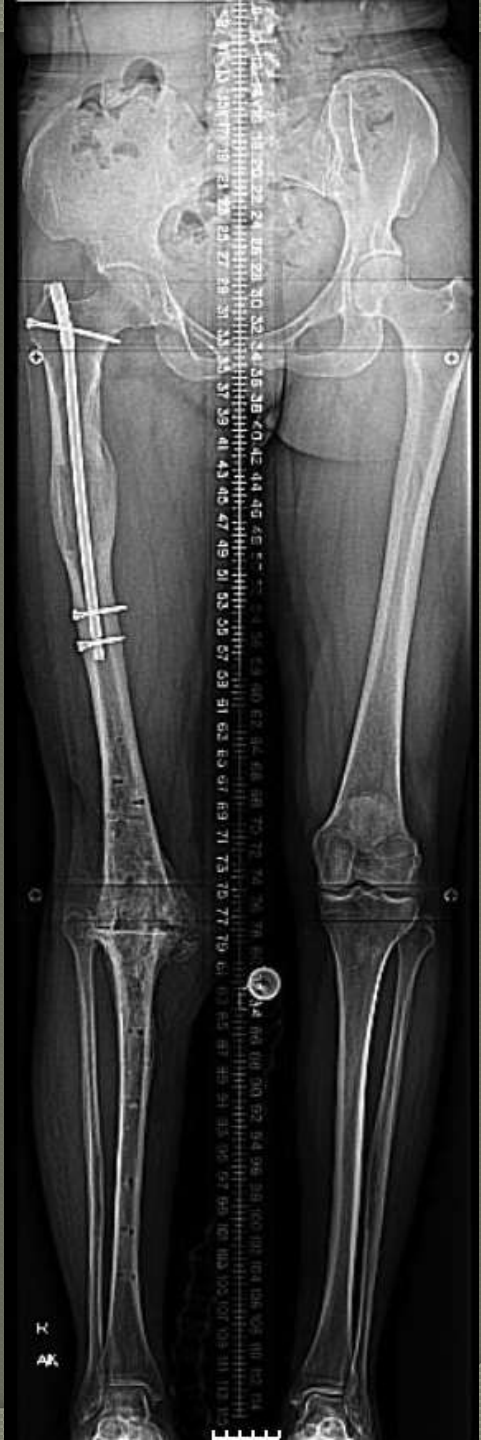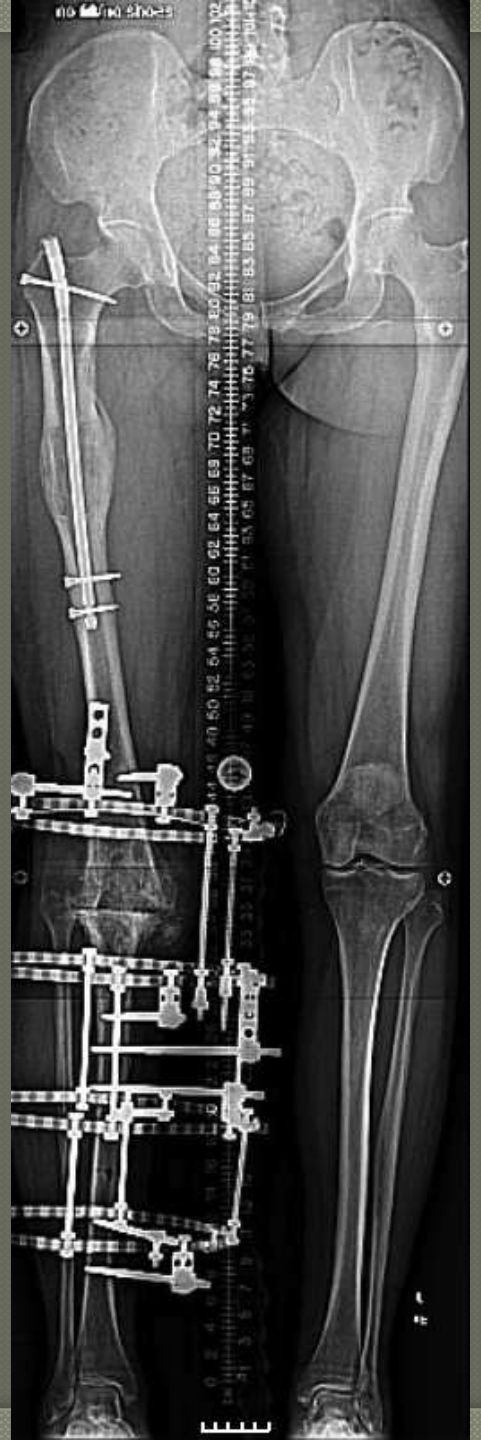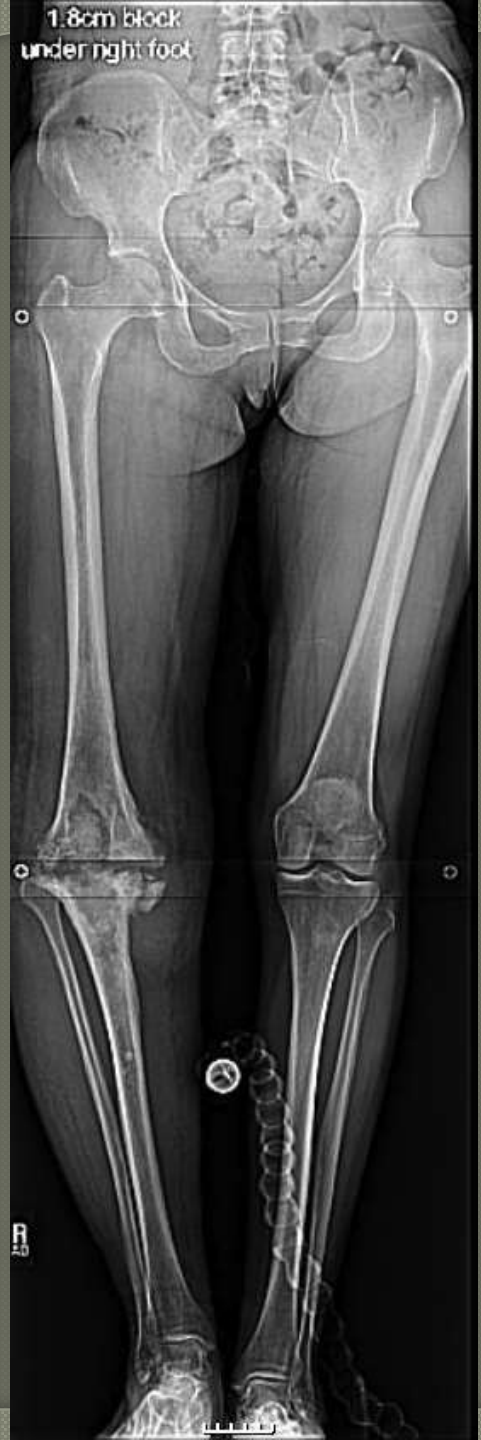# Background

- Patients with multiple failures of total knee replacement (TKR) present a difficult challenge for the limb salvage surgeon.
- Multiple revisions, infection, bone loss, and soft-tissue compromise make this a problem
- Above-knee amputation (AKA) versus limb salvage opinion is commonly sought

# Case Example



1.8cm block  
under right foot



# The Question(s)

- What is the outcome of knee fusion and reconstruction in this challenging group of patients?
- What is the amount of bone loss and how can it be handled?
- What is an algorithm for treatment ?

# Methods

- Retrospective case series from single surgeon
- Bone loss, leg length discrepancies (LLD), presence of infection, number of TKR surgeries
- Fusion methods, lengthening procedures and complications were documented

# Demographics

Number of Patients	Age Yrs (SD)	Sex Distribution	BMI (SD)	F/U Months (Range)
22	66.9 (14.9)	11M:11F	31.4 (6.8)	42 (6-120)



7/22 patients (32 %) underwent bone lengthening procedures (average age 52 +/- 6.7 years)



# Non-Lengthened Group

	Primary TKA	Single Revision	Multiply Revised
No. of Patients	5	6	4
Active Infection	5/5	5/6	2/4

# Non-Lengthened Group

	<b>Ilizarov<sup>1</sup> Frame</b>	<b>IM Nail</b>	<b>Plating Construct</b>	<b>Hybrid<sup>2</sup> Technique</b>	<b>Monolateral Frame</b>	<b>Addition of Internal Fixation</b>
<b>No. of Patients</b>	5	5	1	2	1	2
<b>Acute Docking</b>	60 %	100 %	100 %	0 %	100 %	N/A

- 1) 2 Patients had gradual docking due to difficulty closing soft-tissue envelope
- 2) Hybrid technique involved conversion from Ilizarov to IM Nail
- 3) Internal fixation performed at time of frame removal or after

# Non-Lengthened Group

	<b>Pre-Op Bone Loss (cm)</b>	<b>Intra-Op Bone Loss (cm)</b>	<b>Pre-Op LLD (cm)</b>	<b>Post-Op LLD (cm)</b>
<b>Avg.</b>	3.1	4.4	3.2	4.5
<b>SD</b>	1.0	1.9	1.6	2.5

# Non-Lengthened Group

	Patellectomy	Flaps	Non-Union	Eradication of Infection	Successful Limb Salvage	Time in Frame (Mons)
No. of Patients	15/15	4/15	1/15	13/15	13/15	6.4 (2.1)

# Lengthened Group

	<b>Primary TKA</b>	<b>Single Revision</b>	<b>Multiply Revised</b>
<b>No. of Patients</b>	2	3	2
<b>Active Infection</b>	1/2	3/3	2/4

# Lengthened Group

	<b>Pre-Op Bone Loss (cm)</b>	<b>Intra-Op Bone Loss (cm)</b>	<b>Pre-Op LLD (cm)</b>	<b>Immediate Post-op LLD (cm)</b>
<b>Avg.</b>	4.7	7.3	4.6	7.9
<b>SD</b>	1.8	3.9	2.2	3.5

All patients in the Lengthened group treated with multiplanar external fixation

# Lengthened Group

	<b>Femur Lengthening Only</b>	<b>Tibial Lengthening Only</b>	<b>Femur and Tibia</b>
<b>No. of Patients</b>	4/7	2/7	1/7

	<b>Total Lengthening (cm)</b>	<b>Time in Frame (Mons)</b>	<b>EFI</b>	<b>Final LLD (cm)</b>
<b>Avg.</b>	6.3	13.1	2.0	1.6
<b>SD</b>	2.9	3.4	0.9	0.7

# Lengthened Group

	Patellectomy	Addition of Internal Fixation <sup>1</sup>	Mal-Union	Eradication of Infection	Successful Limb Salvage <sup>2</sup>
No. of Patients	7/7	2	1/7	7/7	6/7

1) Plating/cannulated screws done prophylactically and time of frame removal

2) Patient with amputation had acute emboli 1 year after fusion frame removed



# Algorithm for Treatment

Group	Problem	Fusion Option(s)
TKR with minimal bone loss	Presence of refractory infection	ABx coated IM Nail *, Ilizarov Method, Hybrid Techniques
TKR with massive bone loss	Unable to acutely oppose bone ends	Ilizarov method with use of gradual shortening
TKR with wound problem	Wound Closure/Soft-tissue Envelope	Ilizarov method with use of gradual shortening for closure
TKR with proximal THR	THR/Less Femur to work with	Ilizarov Method avoiding proximal prosthesis

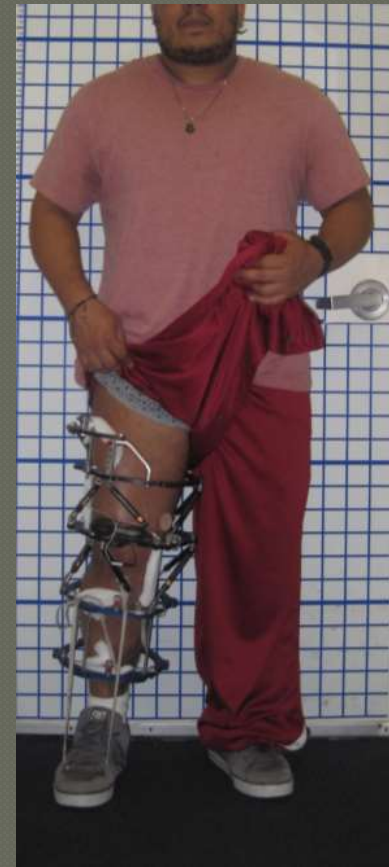\* Smith & Nephew nails are not FDA cleared for this use and Smith & Nephew does not promote this use

# Summary

- Knee arthrodesis can be successfully accomplished as an alternative to AKA in the multiply failed TKR patient.
- Bone lengthening is effective for managing the bone defect and the LLD in a younger patient population
- Bone loss and the soft-tissue envelope dictate the knee fusion method and in some cases more than one method is needed.

# Indications for frame

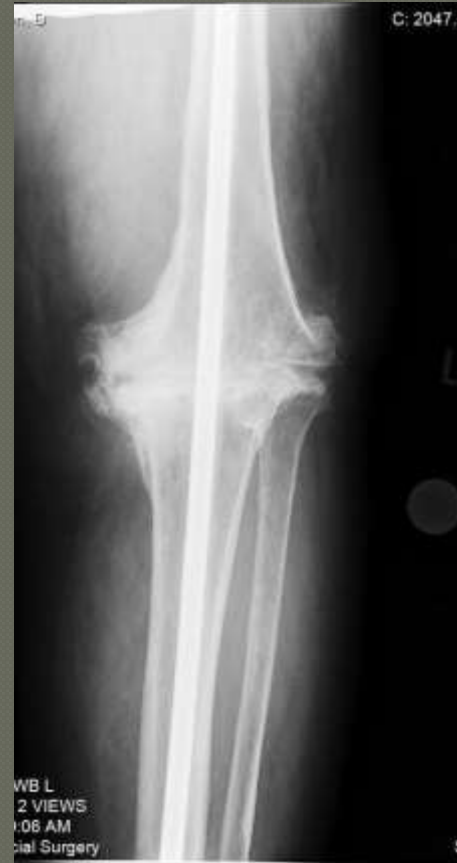- Cannot acutely shorten
- Goal is the lengthen leg
- THR above



# Indications for Antx Rod

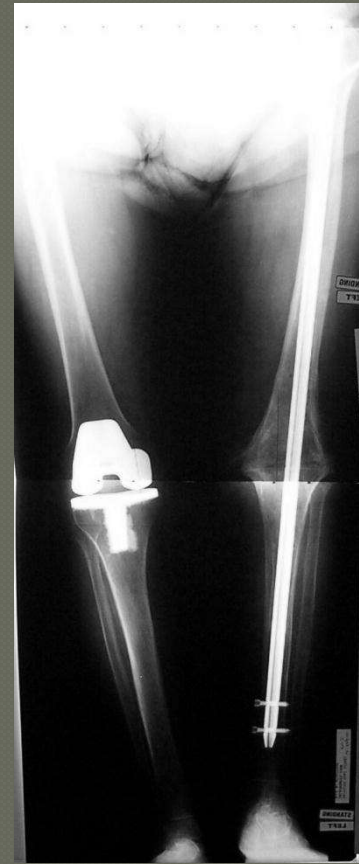- Can acutely shorten
- Accept LLD
  - Can remove nail and lengthen with ILN in future

\* Smith & Nephew nails are not FDA cleared for this use and Smith & Nephew does not promote this use



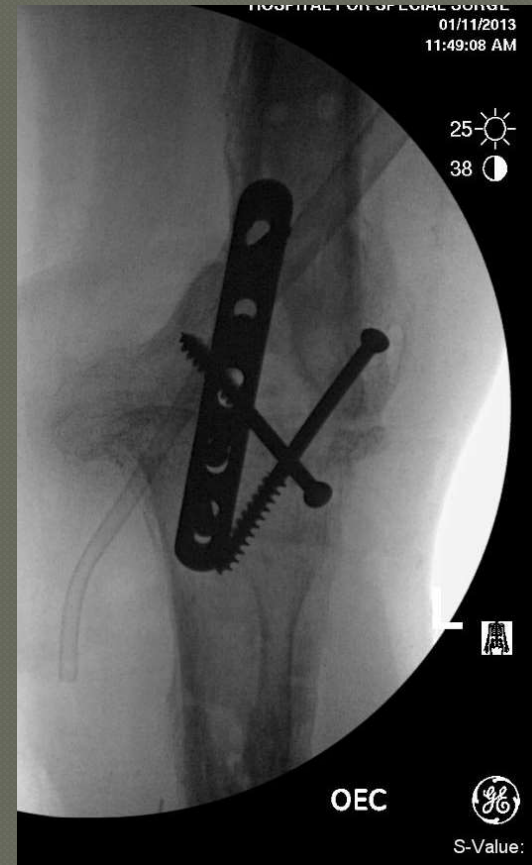# Indications for Frame then Rod

- Cannot acutely shorten
- Poor bone stock
  - Spot welding
  - High risk of refracture of fusion
- Accept LLD



# Indications for prophylactic stabilization with plate screws

- Poor bone stock
  - Spot welding
- High risk of fracture after frame removal



# Thank You



LIMB .COM

[www.hss.edu/limblengthening](http://www.hss.edu/limblengthening)