

Adult Femur Lengthening Algorithm

LLRS Specialty Day, AAOS Annual Meeting
New Orleans, LA; March 15, 2014

S. Robert Rozbruch, MD

Chief, Limb Lengthening & Complex Reconstruction Service
Professor of Clinical Orthopedic Surgery



HOSPITAL FOR
SPECIAL SURGERY



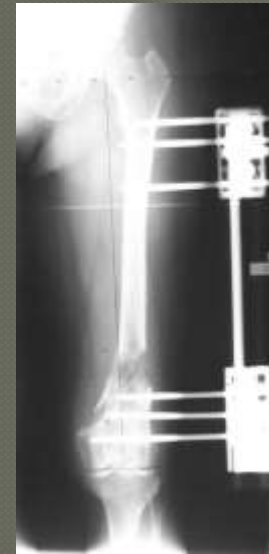
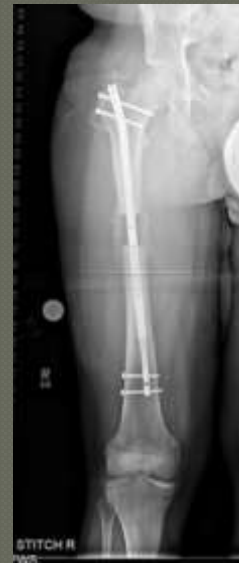LIMB **LENGTHENING**.COM

Disclosures

Small Bone Innovations: consultant and royalties
Smith and Nephew: consultant

Treatment options

- ◉ External Fixation
- ◉ Integrated Fixation
 - LON
 - LATN
 - LAP
- ◉ Internal lengthening nail
 - Piriformis
 - Trochanteric entry
 - retrograde



External Fixation

◉ Historical

◉ Indications

- When other techniques are contraindicated

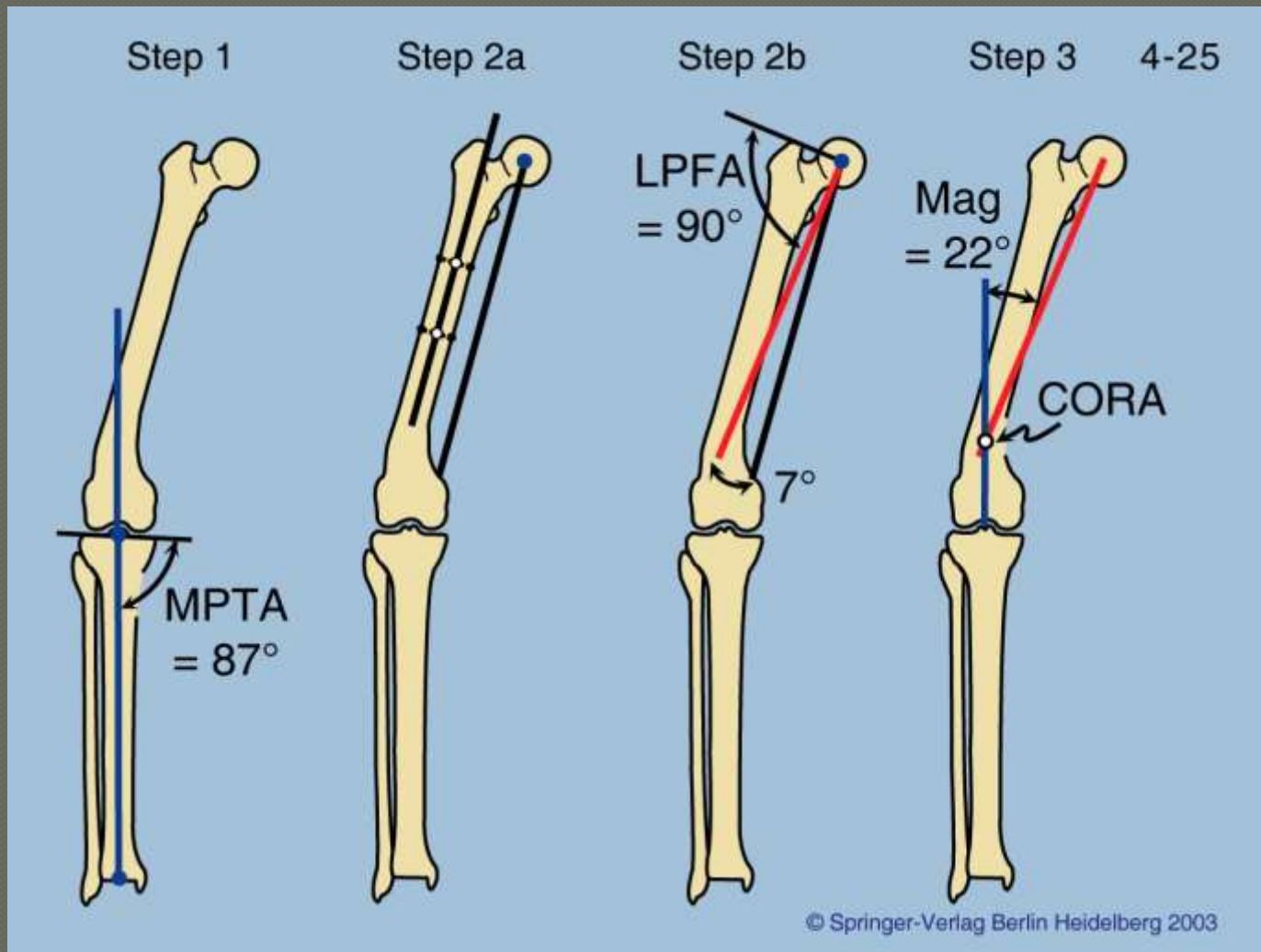
◉ Pros

- Quick surgery
- Minimally invasive
- Little blood loss
- versatile

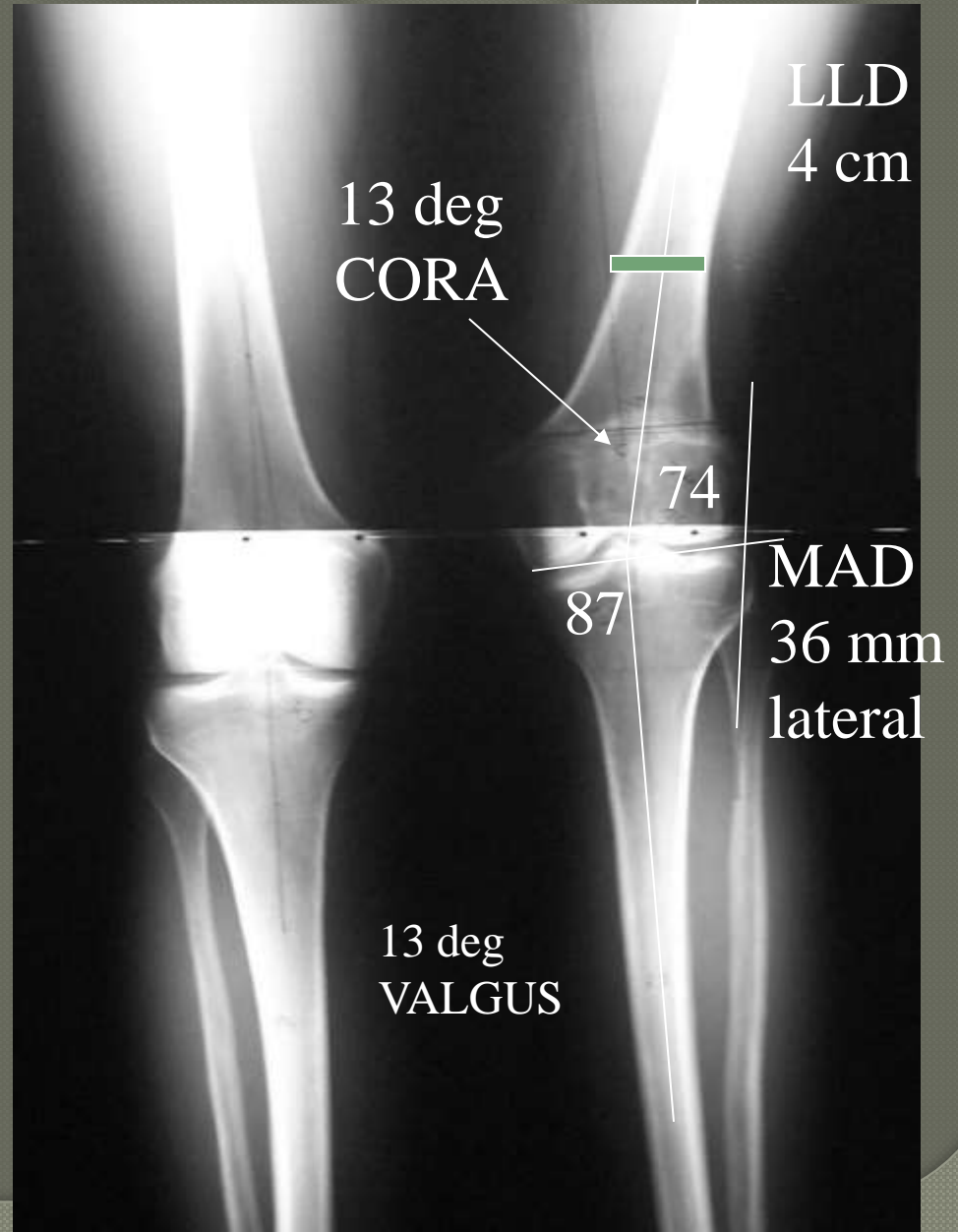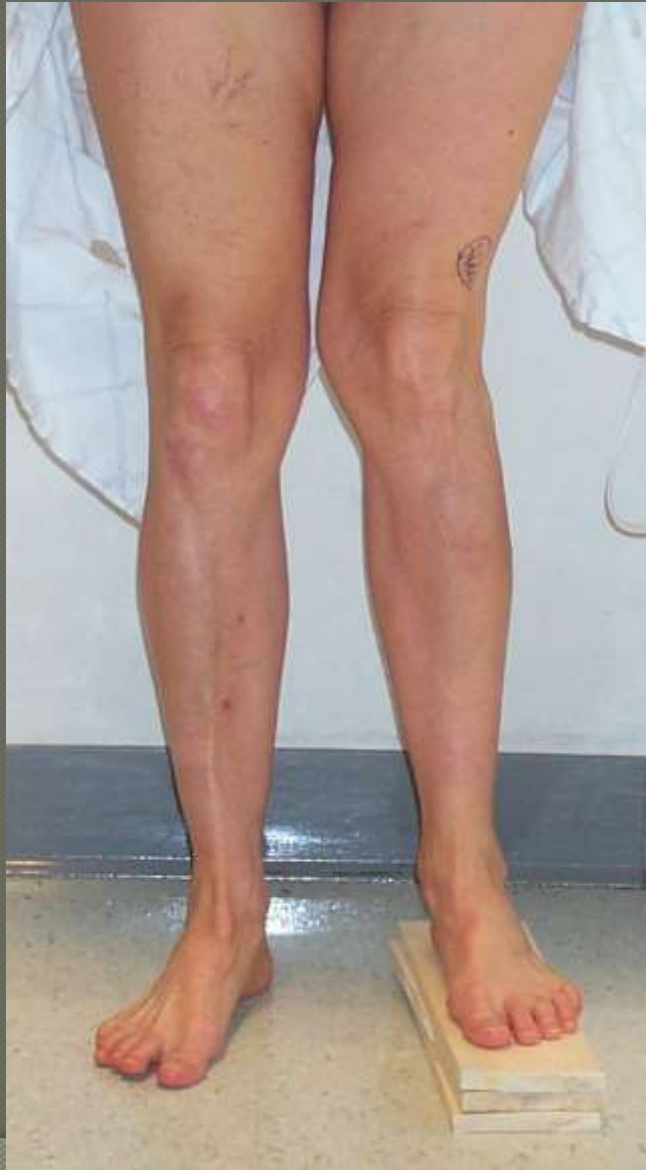◉ Cons

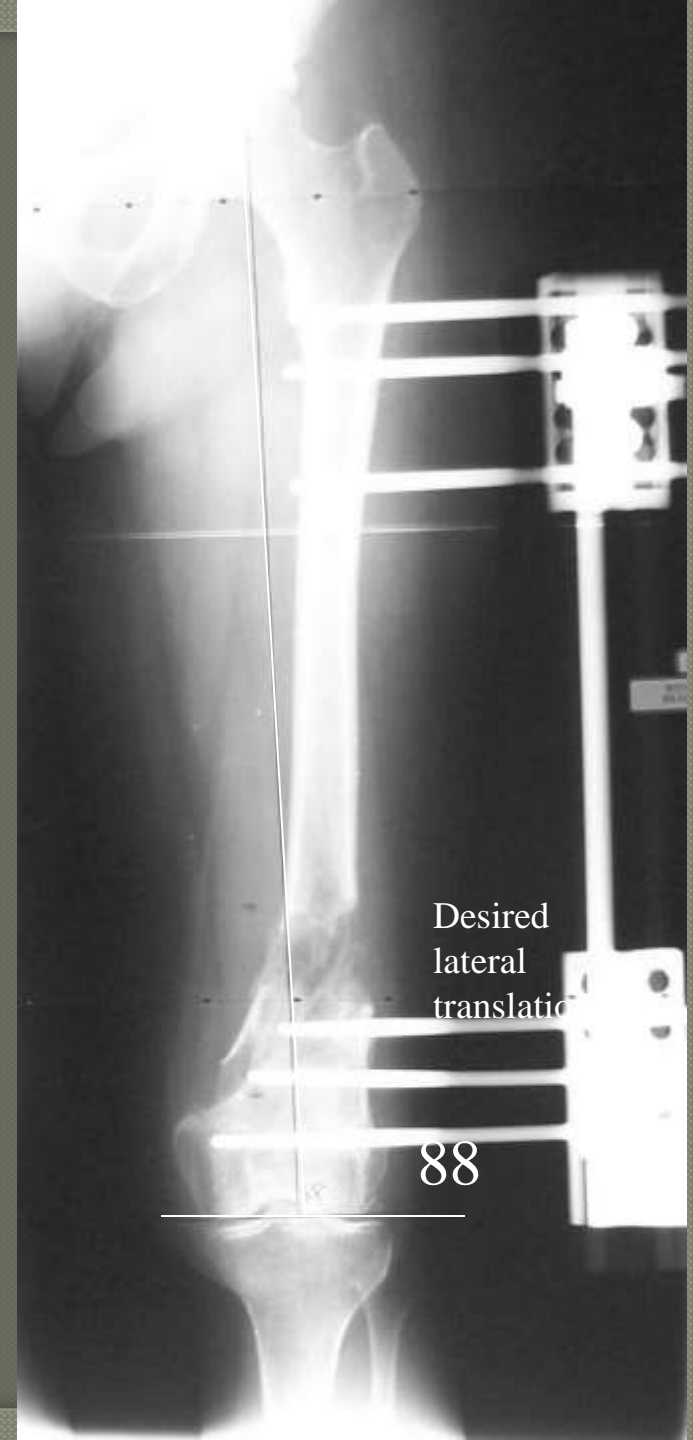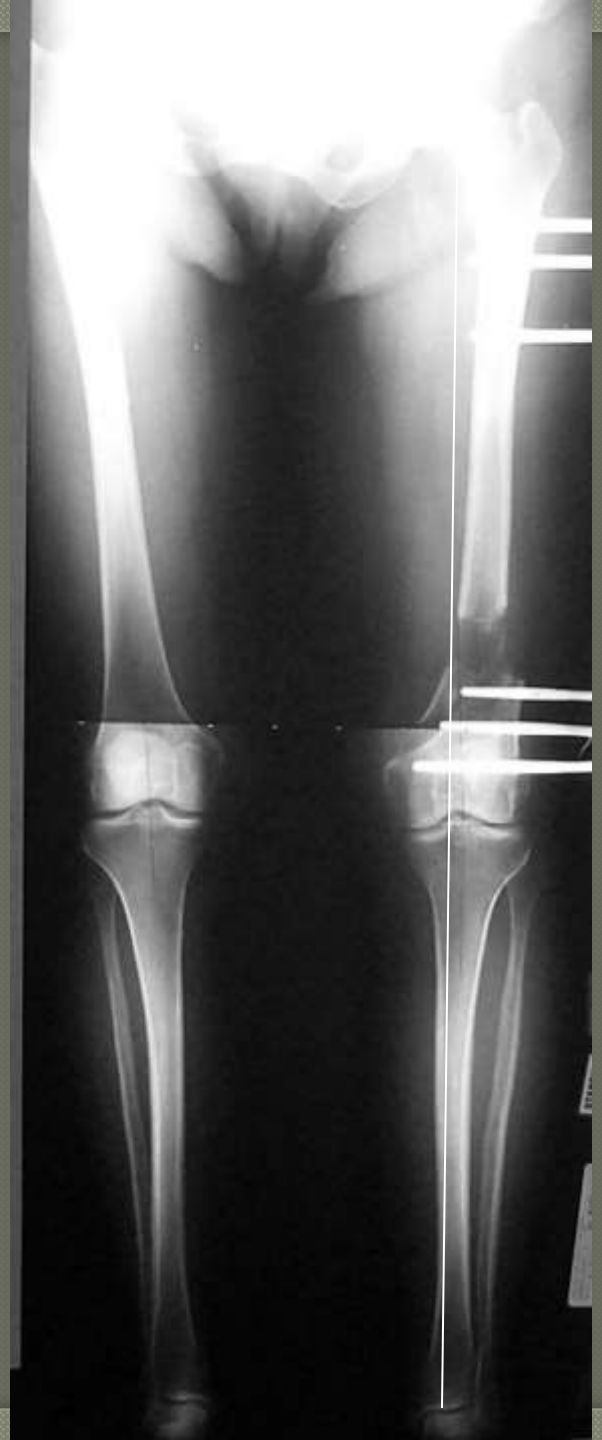- Pin site problems
- Long EFI

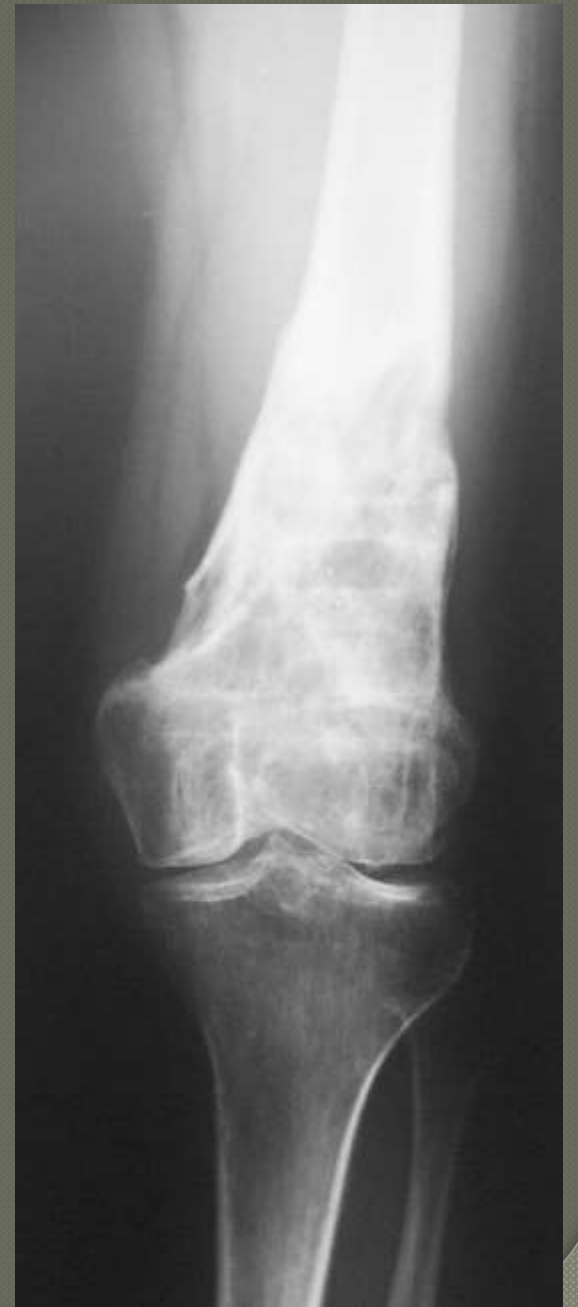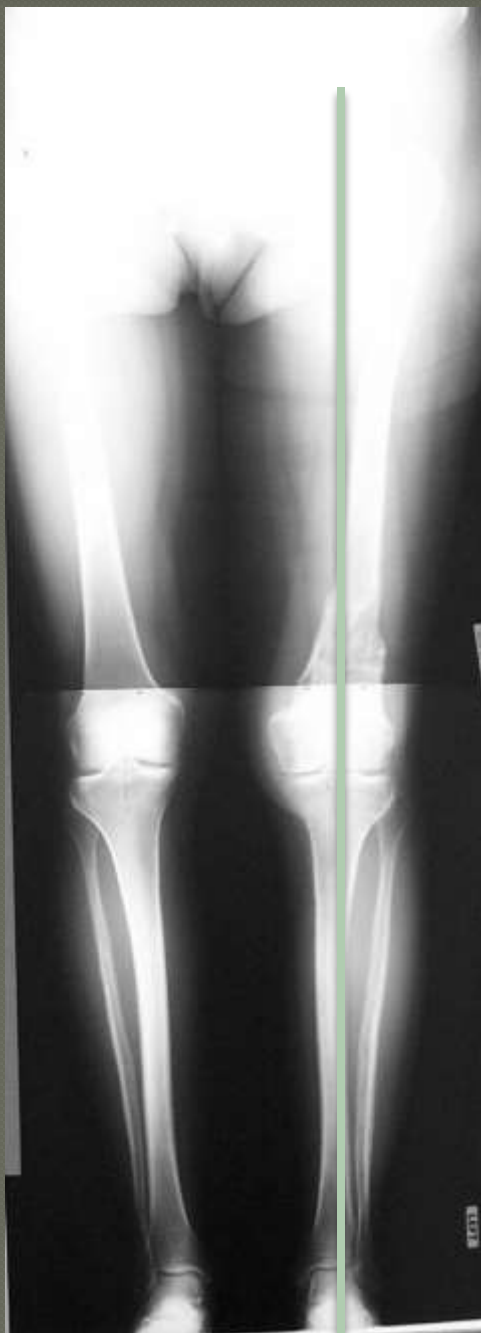Normal tibia and Varus femur



Normal tibia, valgus femur







Integrated Fixation

- ◉ Lengthening over nail (LON)

- ◉ Lengthening and then plating (LAP)

- ◉ Lengthening and then Nailing (LATN)

- ◉ Pros

- Decreased time in external fixation

- ◉ Cons

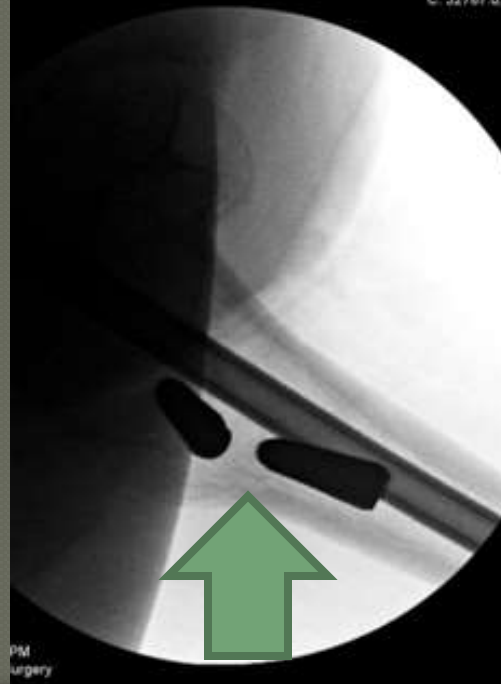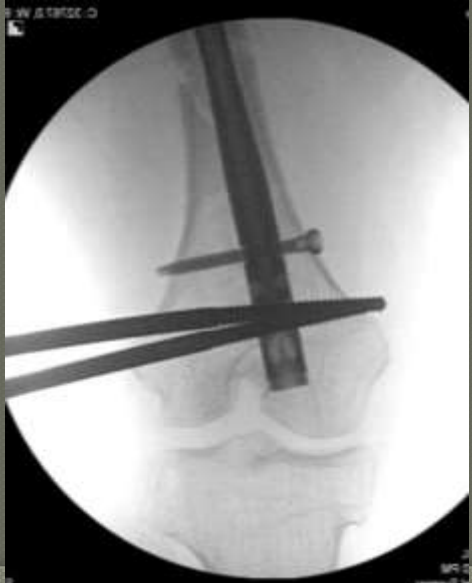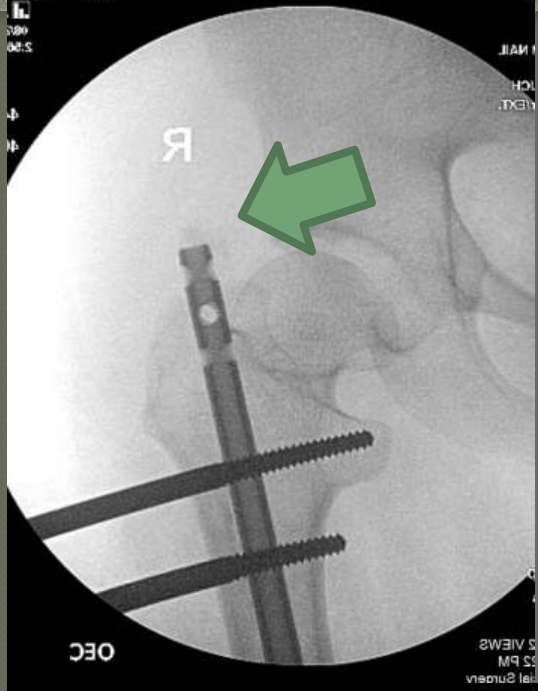
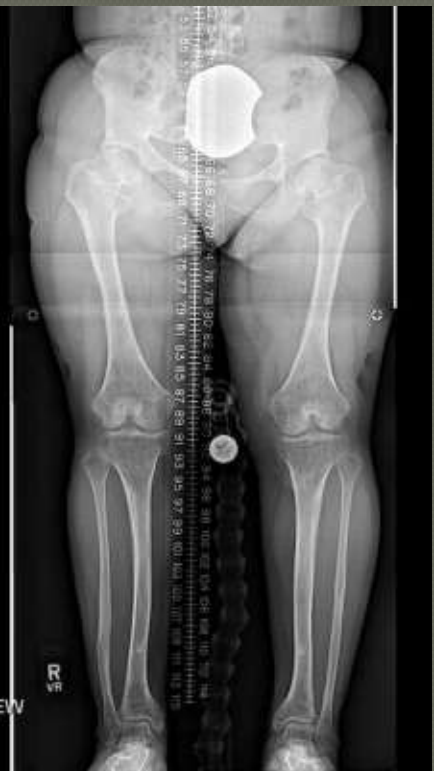- 2 surgeries
- Still wear ex fix

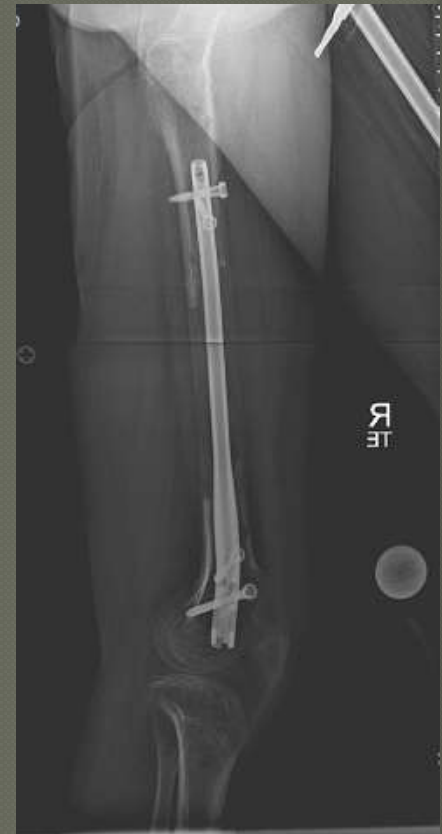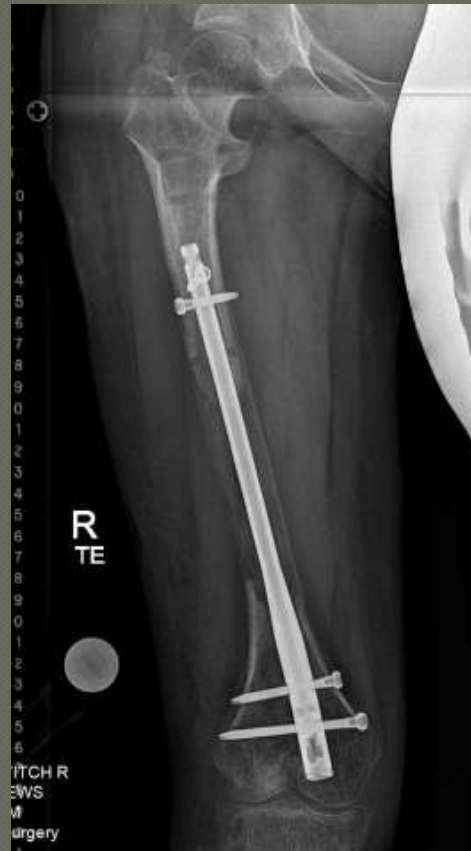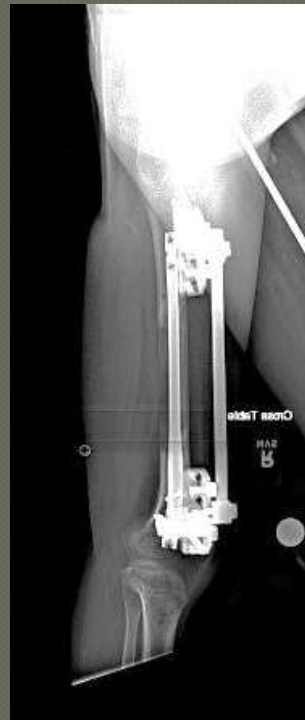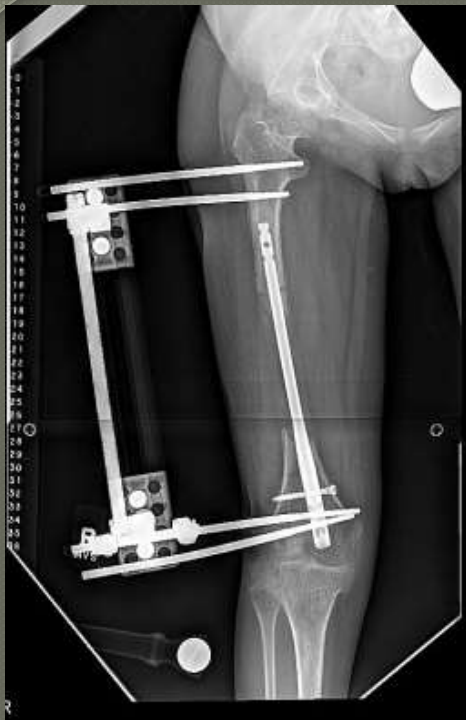
Clin Orthop Relat Res (2012) 470:1221–1231
DOI 10.1007/s11999-011-2204-4

CLINICAL RESEARCH

Femoral Lengthening with Lengthening over a Nail has Fewer Complications than Intramedullary Skeletal Kinetic Distraction

Shahab Mahboubian DO, MPH, Matthew Seah MBChB,
Austin T. Fragomen MD, S. Robert Rozbruch MD





10 cm lengthening

Lengthening of the Femur Over an Existing Intramedullary Nail

Han Jo Kim, MD, Austin T. Fragomen,* Keith Reinhardt, MD,* James J. Hutson, Jr, MD,†
and S. Robert Rozbruch, MD‡*

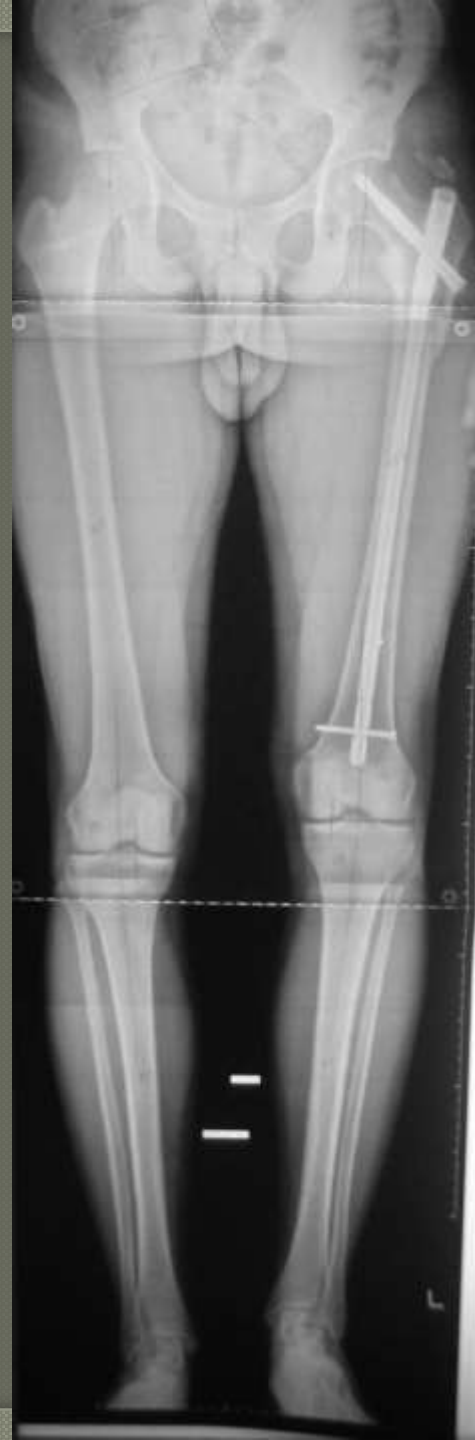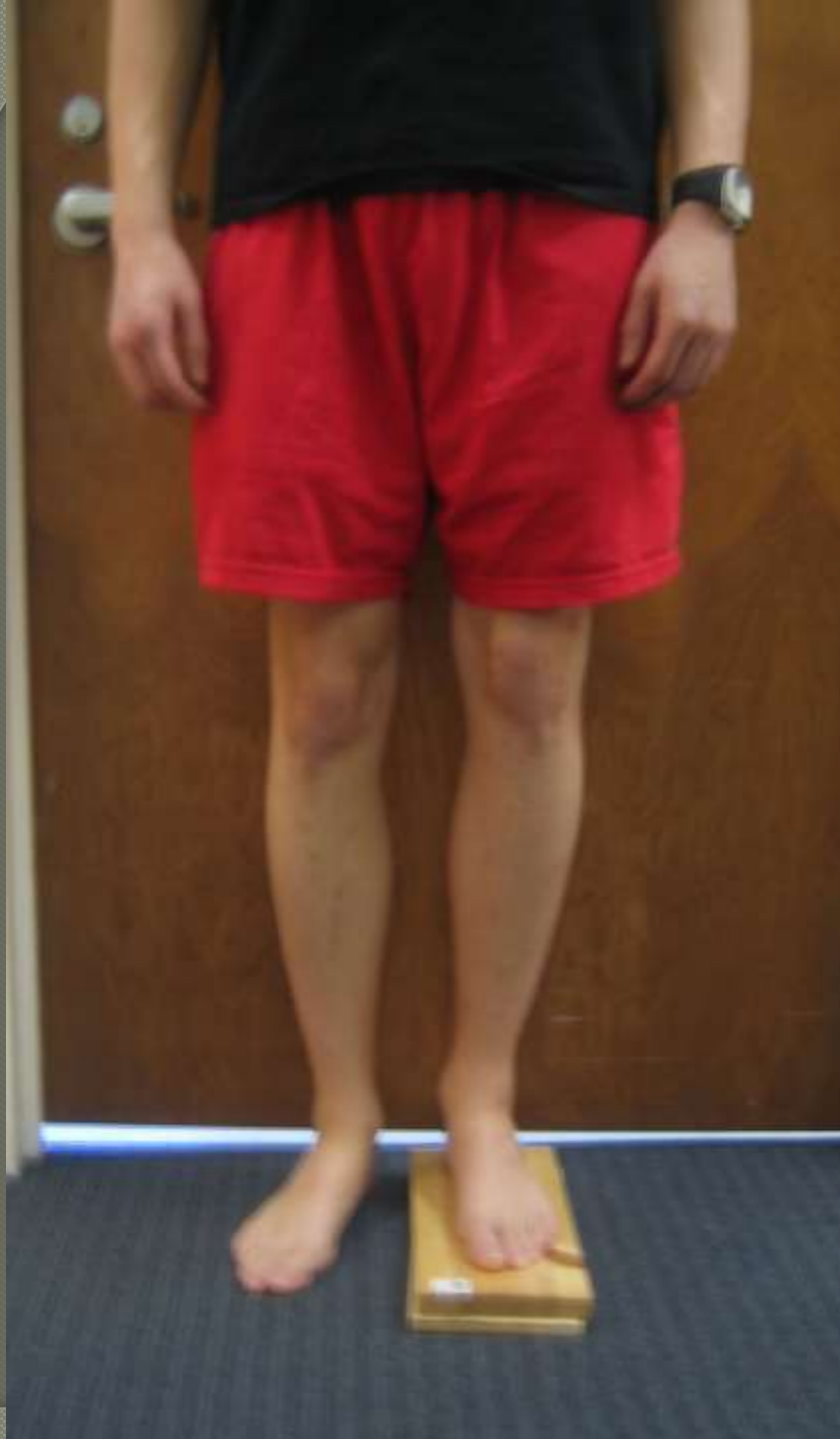Summary: Leg length discrepancies can occur despite successful union of femur fractures after intramedullary nailing (IMN). Often, the leg length discrepancy can result in significant disability to the patient, altered gait biomechanics, pelvic obliquity, and pain. Therefore, a successful clinical result for such deformities after IMN involves addressing the leg length inequality. Femoral reconstruction with an osteotomy around an existing intramedullary nail was introduced to address axial deformity correction and limb lengthening without changing or removing a previously inserted IMN. This technique uses the principles of lengthening over an IMN. The presence of the nail has minimized the time needed for the external fixator because the nail supports the regenerate bone or osteotomy during the consolidation phase. With this technique, surgery is minimized by avoiding the need for exchange nailing.

Key Words: posttraumatic deformity, Ilizarov, femur, osteotomy, intramedullary nail

(J Orthop Trauma 2011;25:681–684)

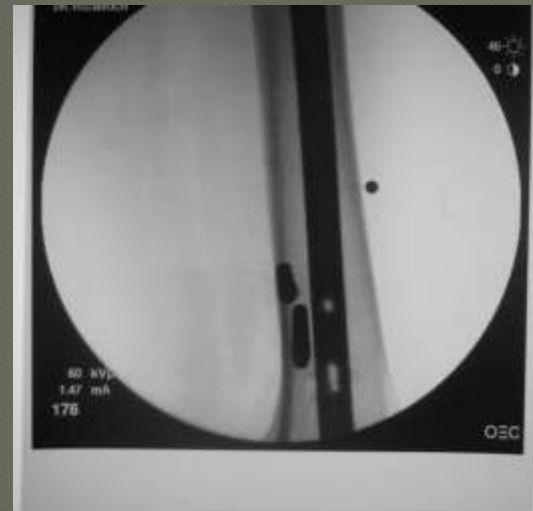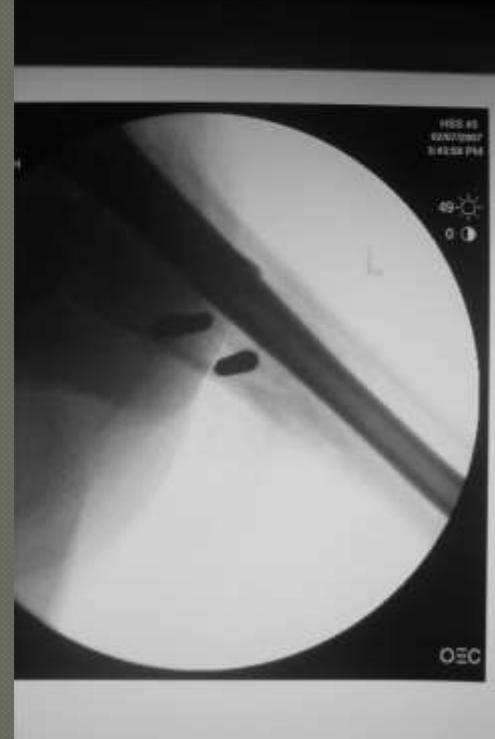
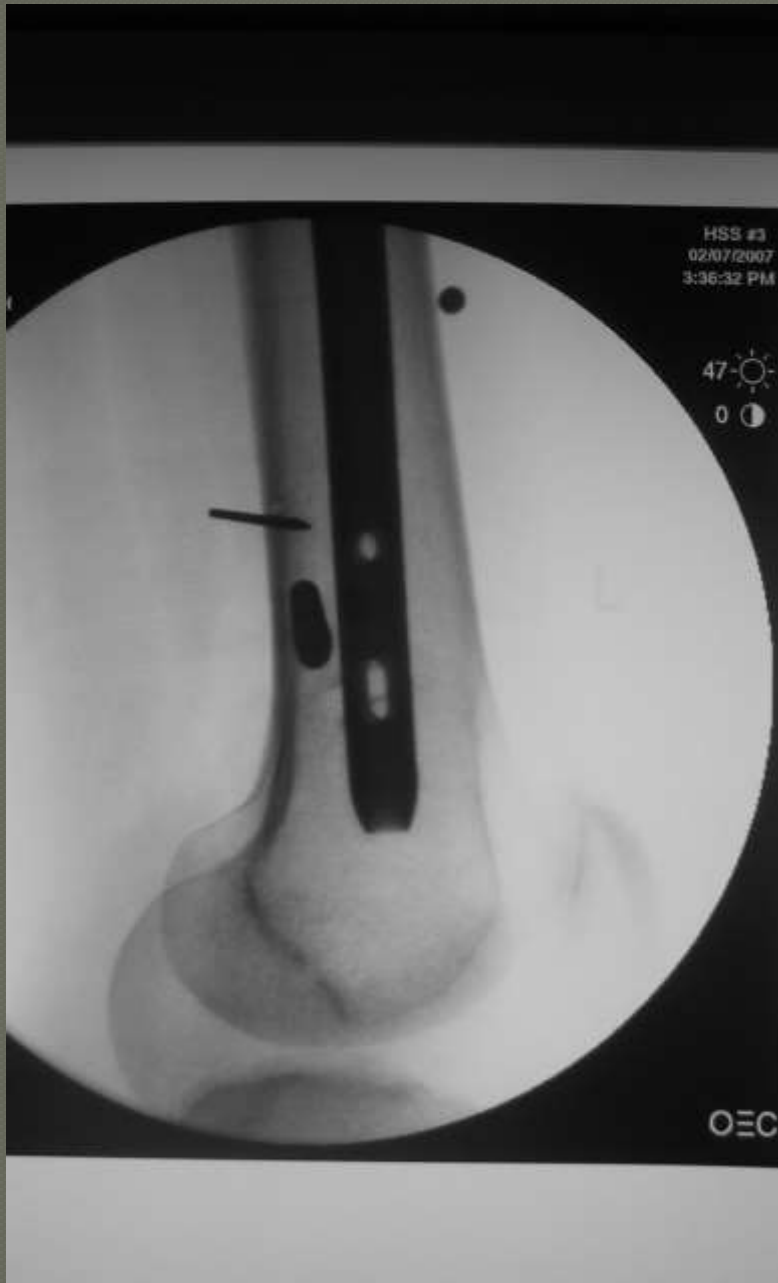When angular deformities result, the mechanical axis can be significantly affected, leading to asymmetric joint loads across the hip, knee, and ankle as well as alterations in the lever arms of muscle (ie, extension/flexion deformities). This can lead to quadriceps weakness as well as increased energy expenditure for gait.¹ Axial deformities that result in a significant leg length discrepancy and/or rotational deformities can also be problematic for the patient and may lead to hip, knee, and low back pain; awkward gait; and extensor mechanism weakness if left untreated.^{1,3–5}

Correcting these malunions can be challenging, and often reoperation can lead to significant morbidity for the patients. The abductors can become more scarred and weakened and sometimes the deformity can persist despite efforts for correction. This has led to a novel technique in which bony deformity can be corrected without nail removal obviating the need to surgically violate the hip abductors in anterograde nailing. In the case of retrograde nails, there is no need to perform an arthrotomy, split the patella tendon, or evert the patella.⁷

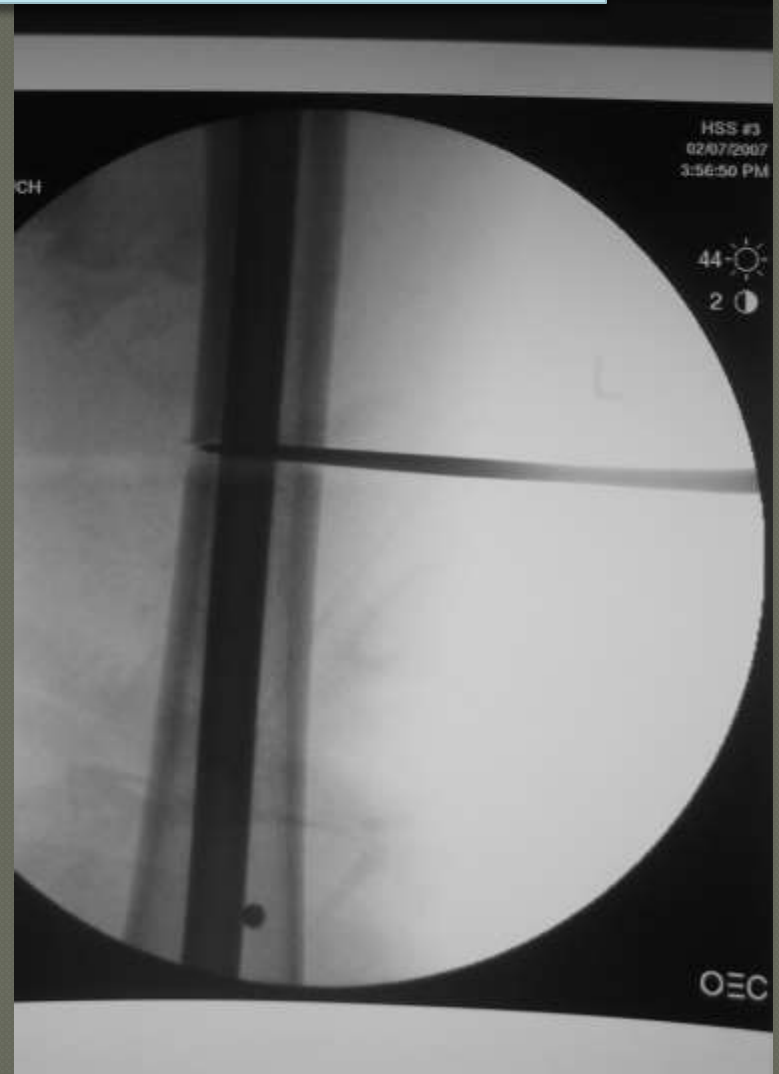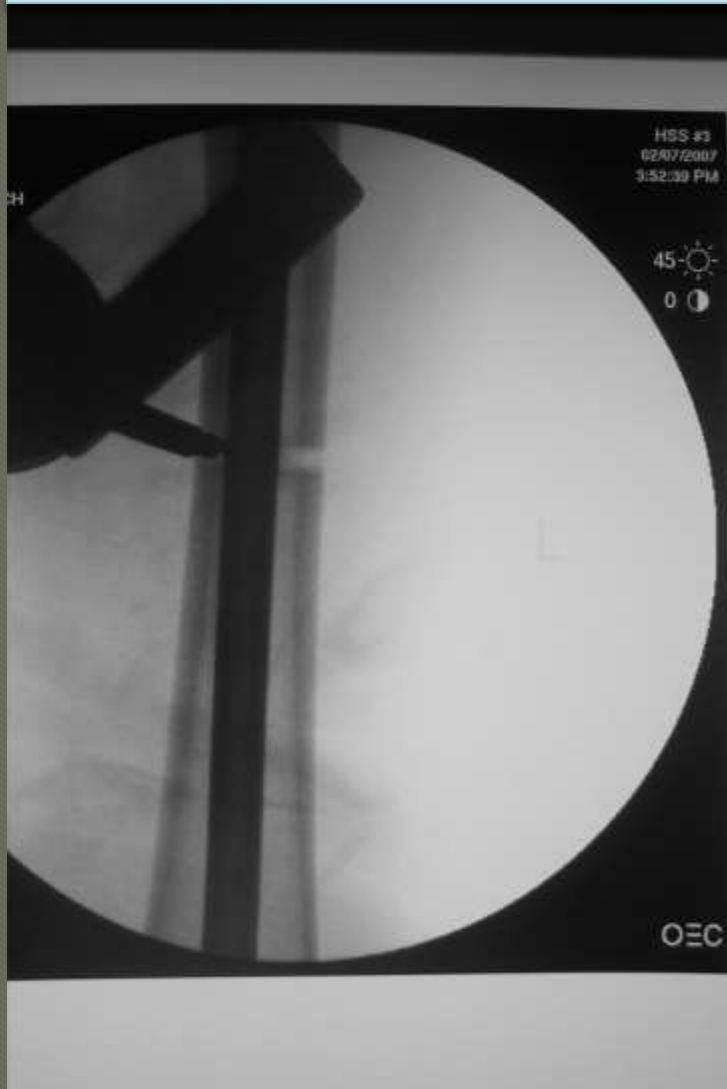


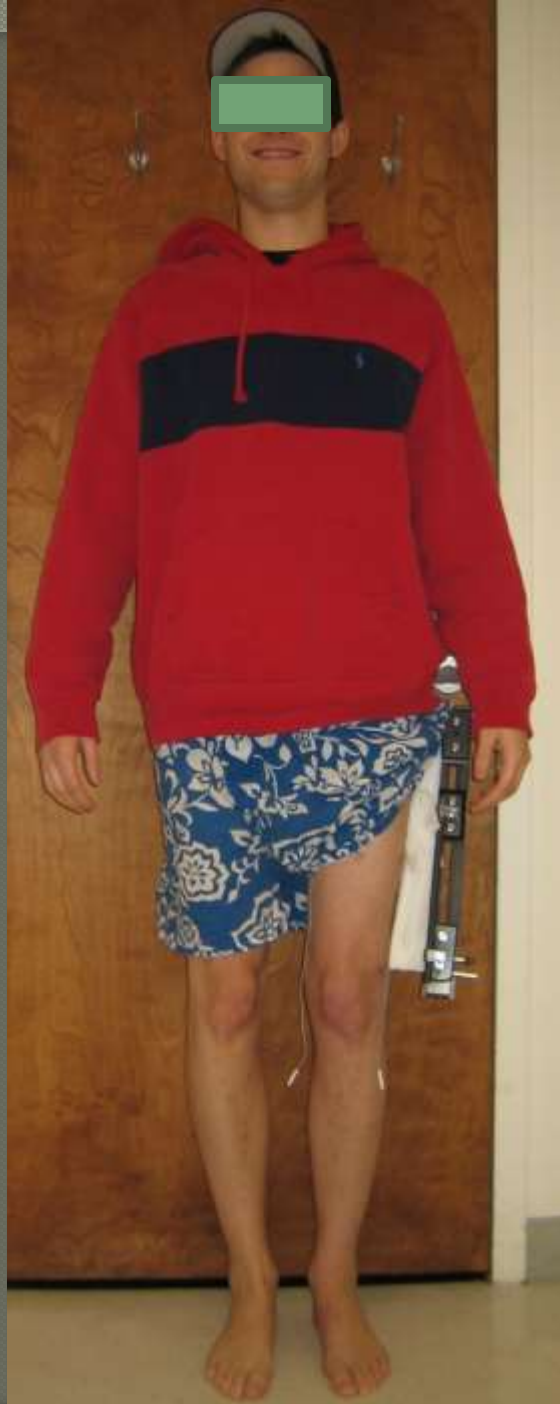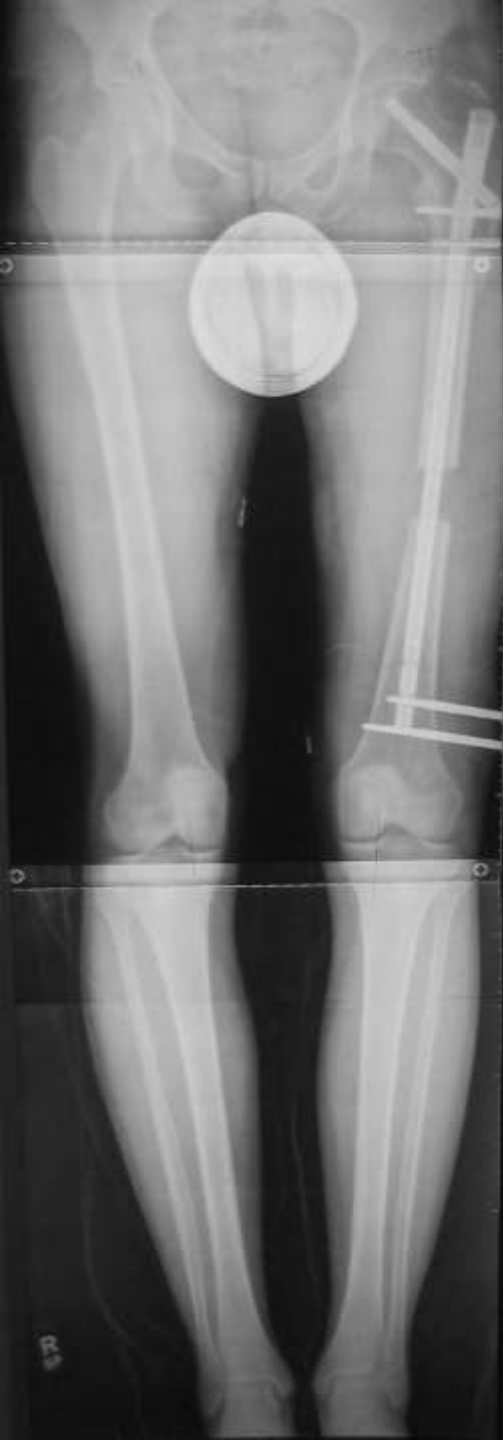Lengthening
Over an
Existing
IMN

LLD 3 cm



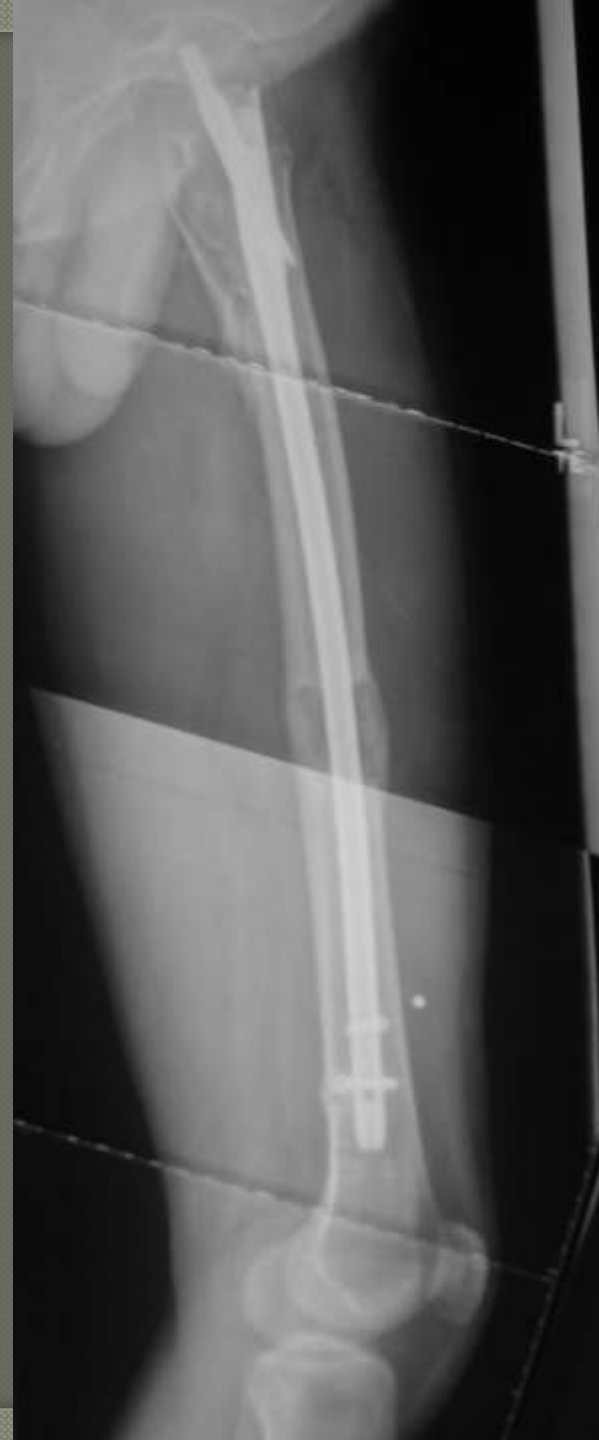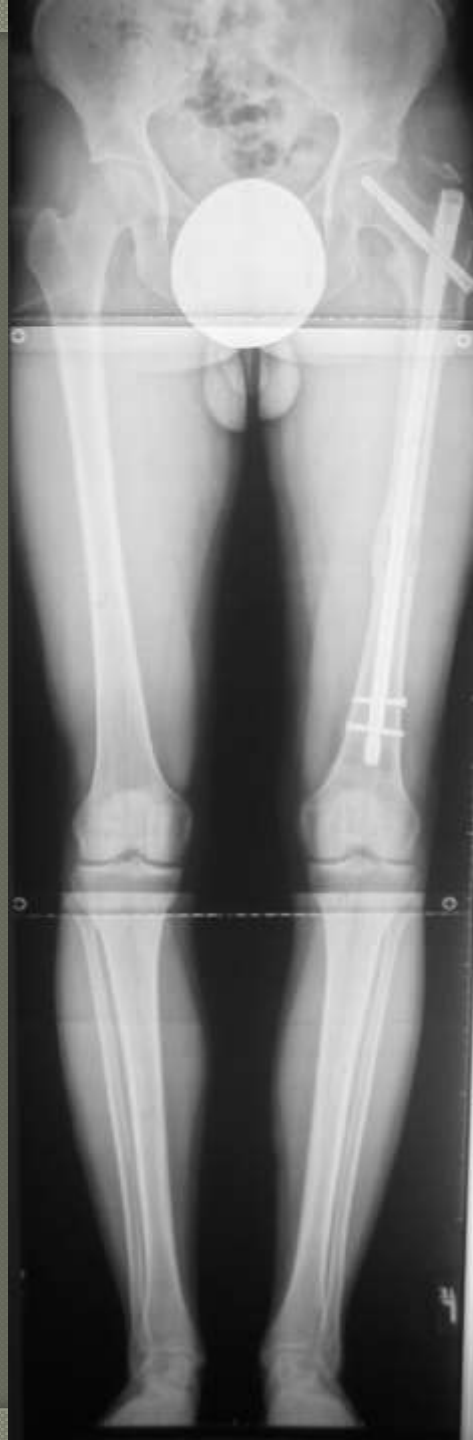CUT BONE AROUND EXISTING IM NAIL

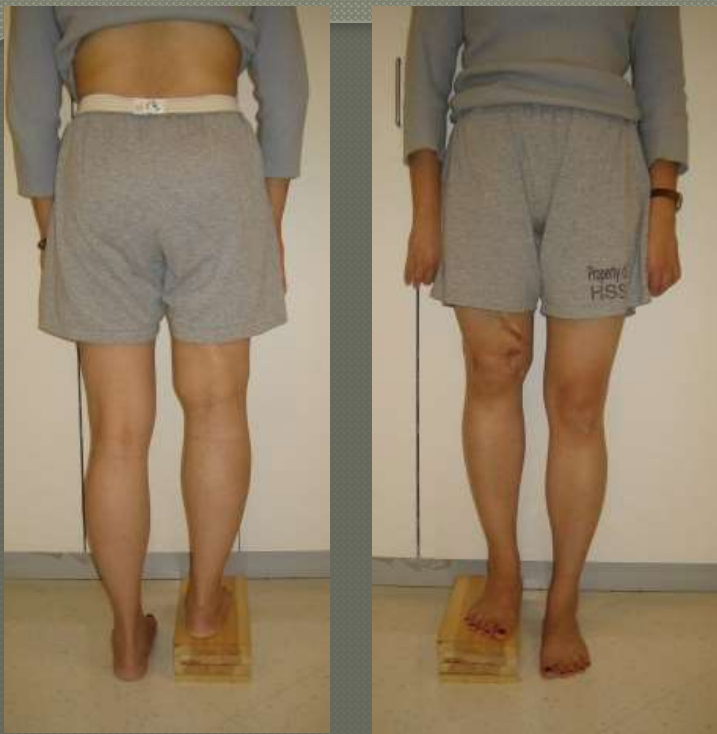




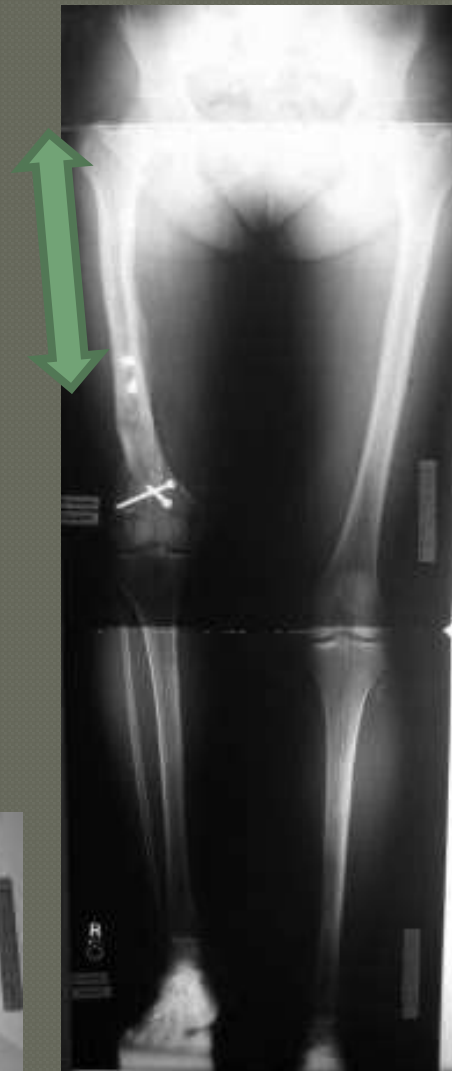
2.5
mo

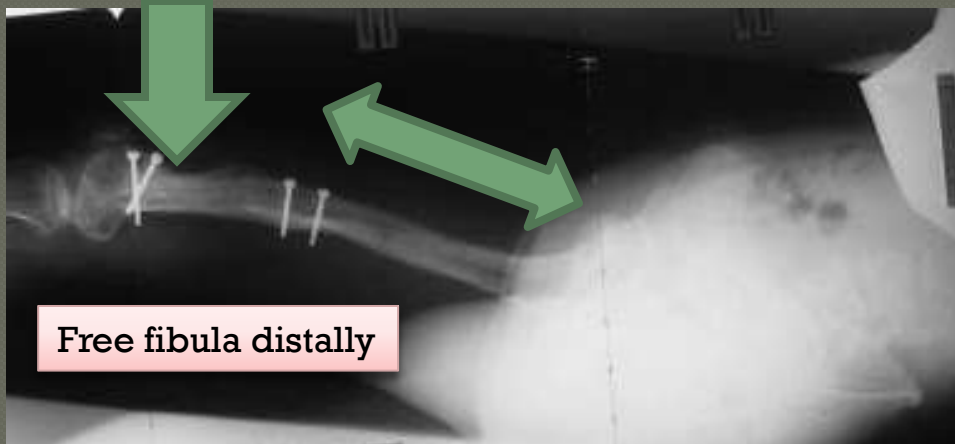




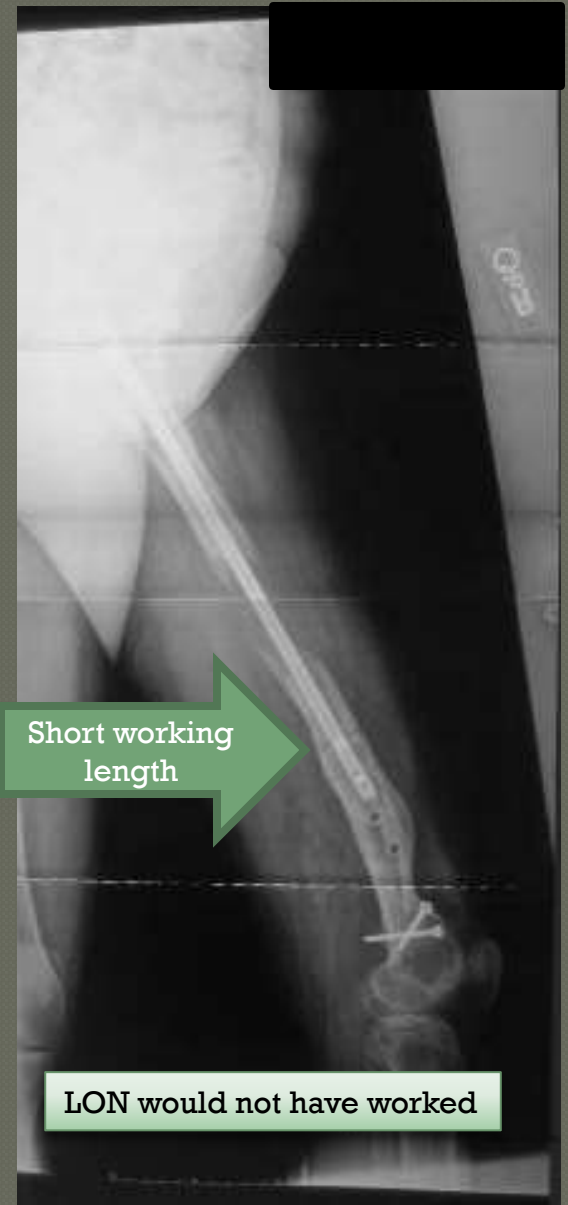
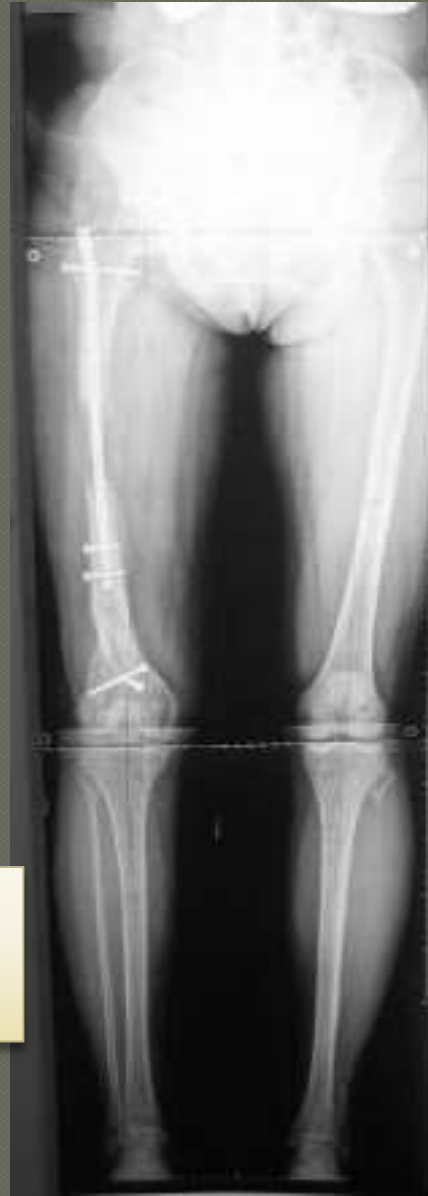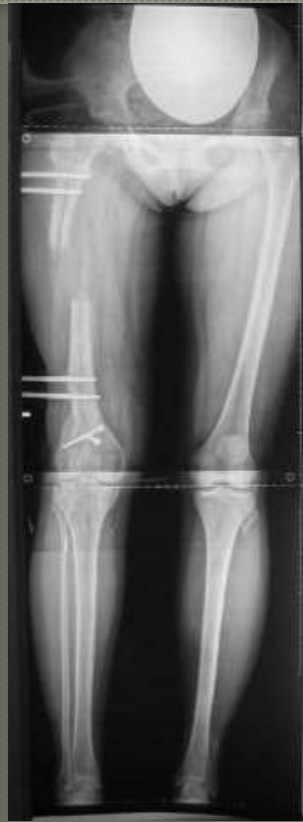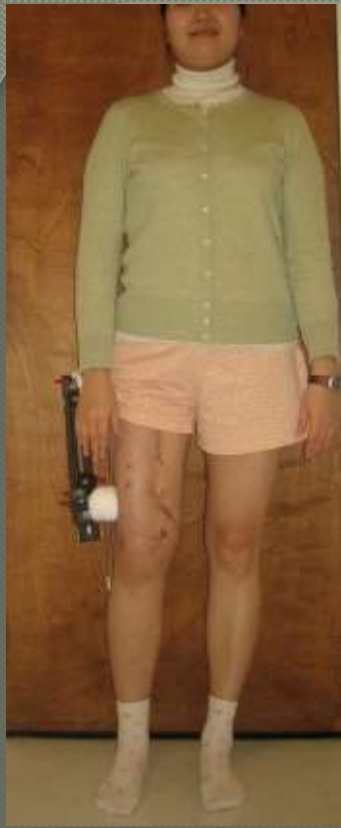LLD 7 cm, old osteomyelitis



LATN

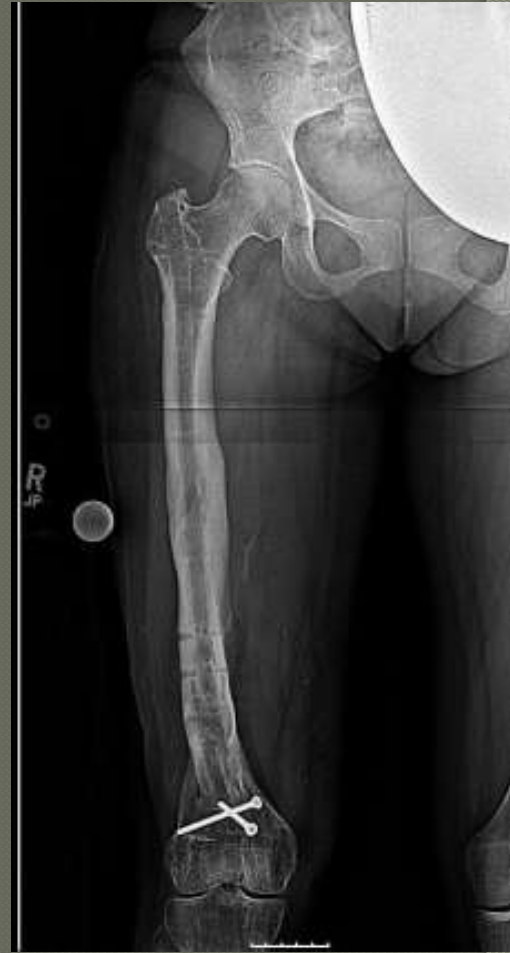
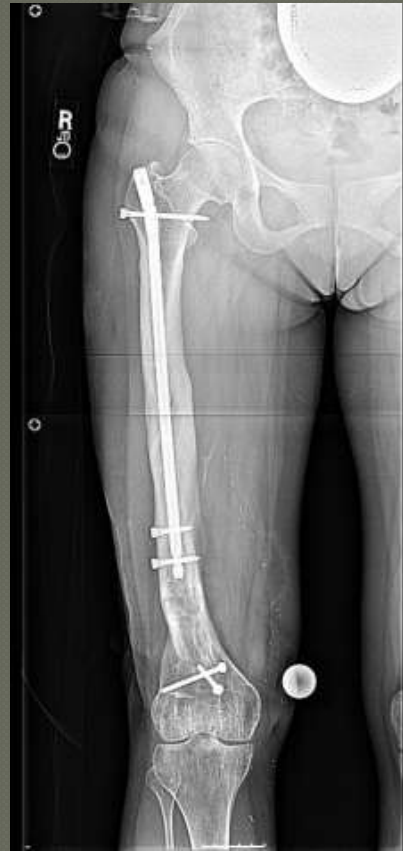
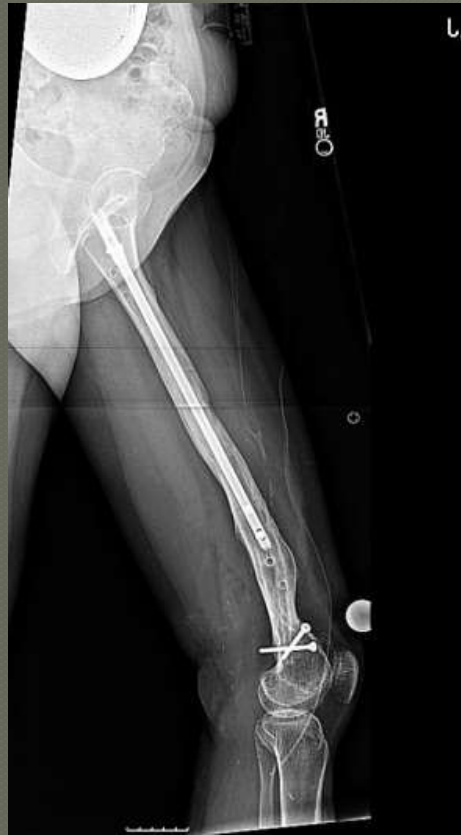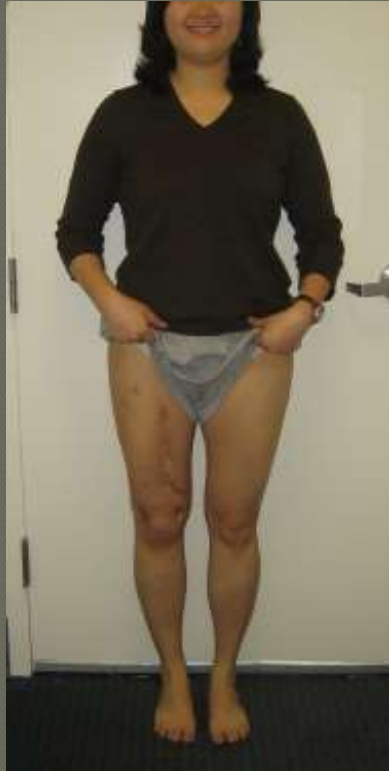Free fibula distally



Pins placed out of nail path
Poor control of alignment
Acute correction needed at nail insertion

LON would not have worked



CLINICAL RESEARCH

Does Lengthening and Then Plating (LAP) Shorten Duration of External Fixation?

Ryhor Harbacheuski MD, Austin T. Fragomen MD,
S. Robert Rozbruch MD

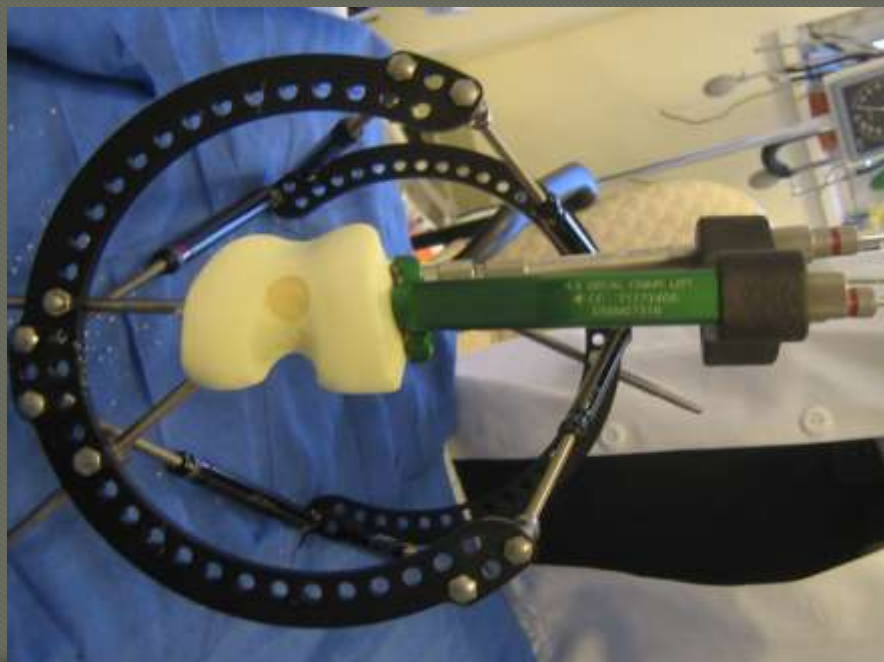
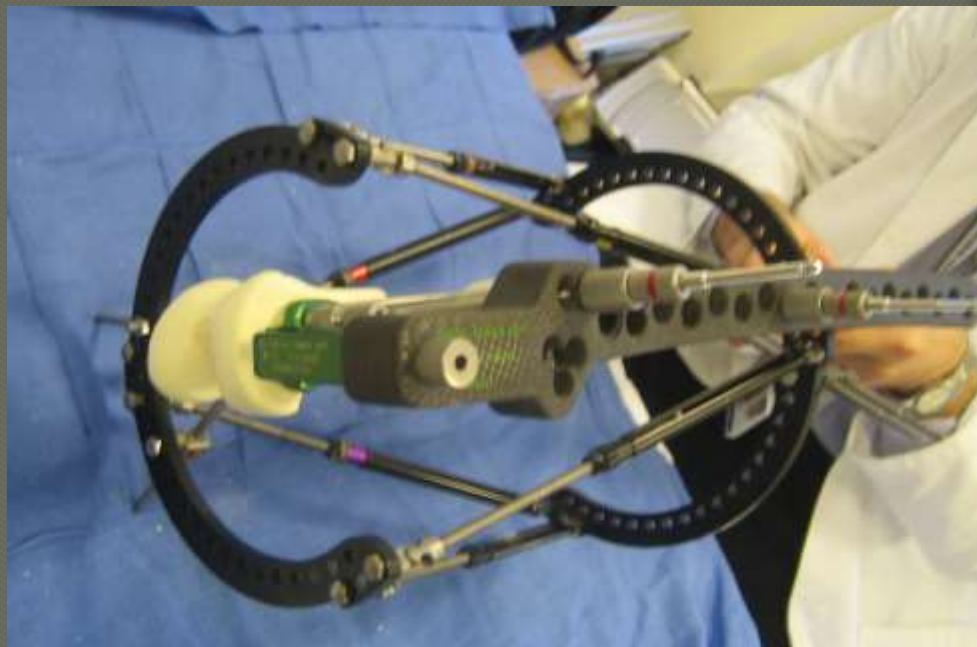Received: 18 June 2011 / Accepted: 3 November 2011 / Published online: 15 November 2011
© The Association of Bone and Joint Surgeons® 2011

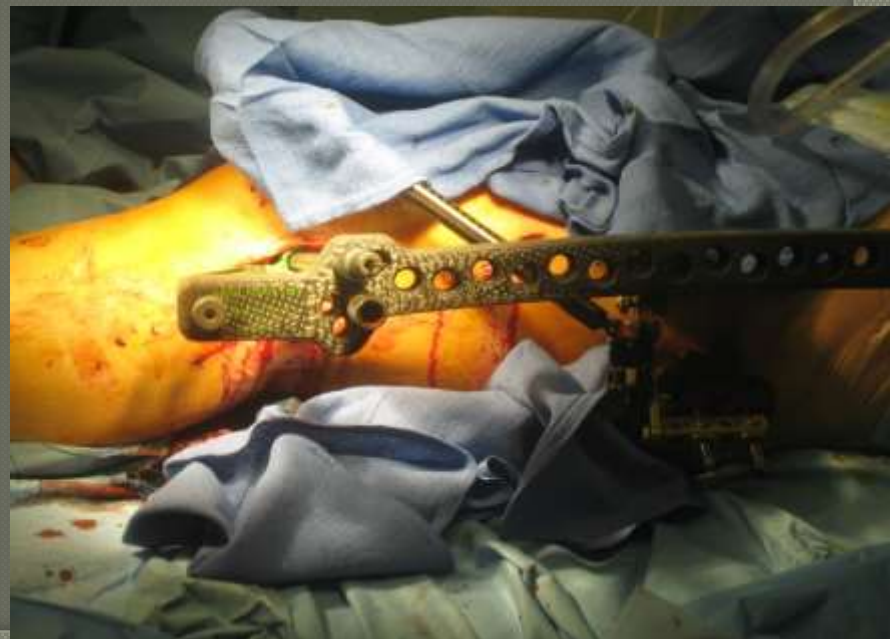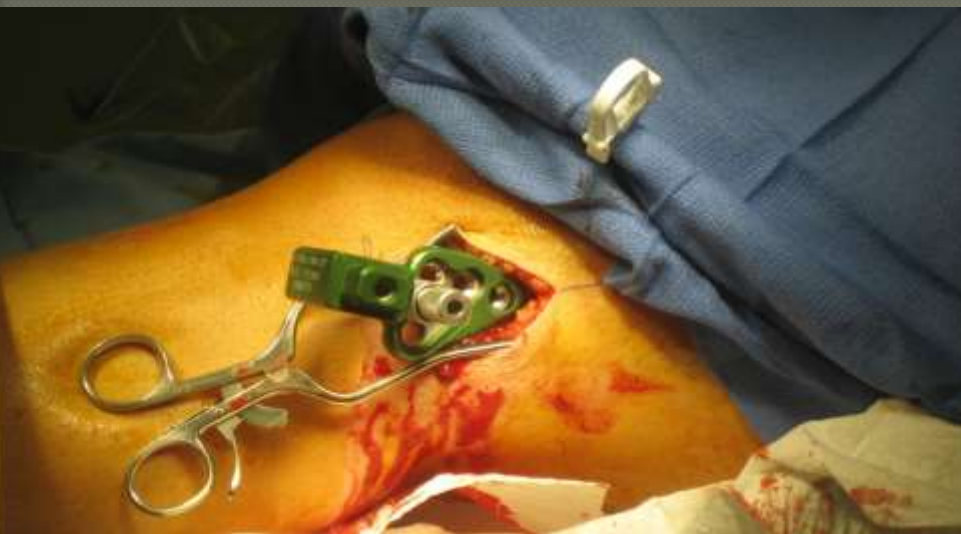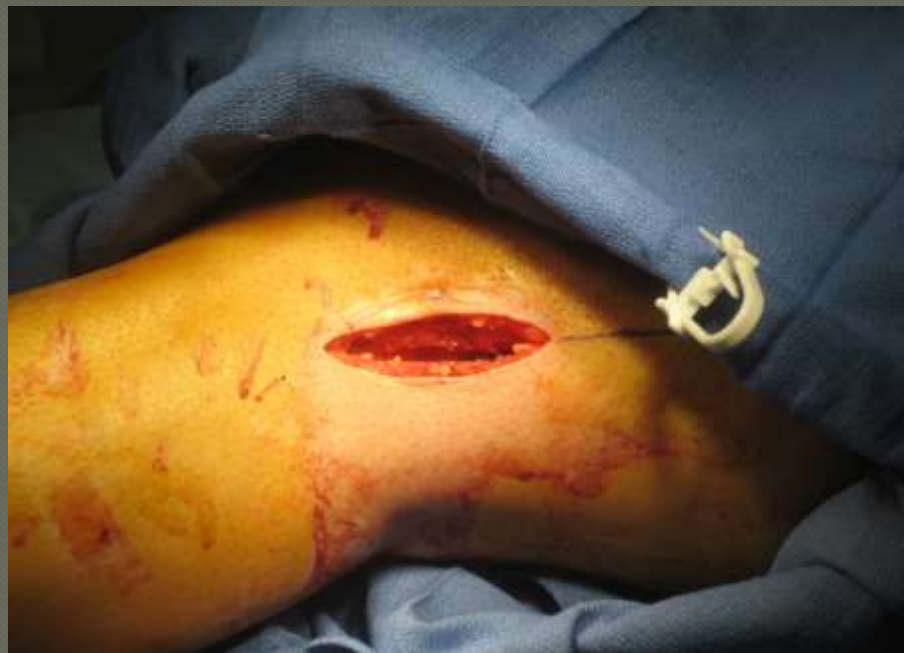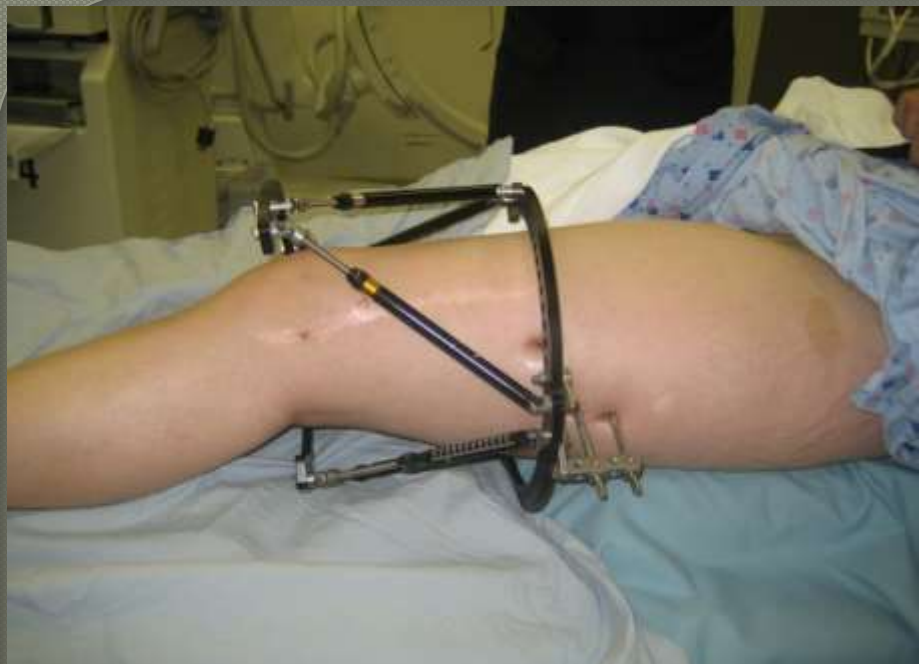Abstract

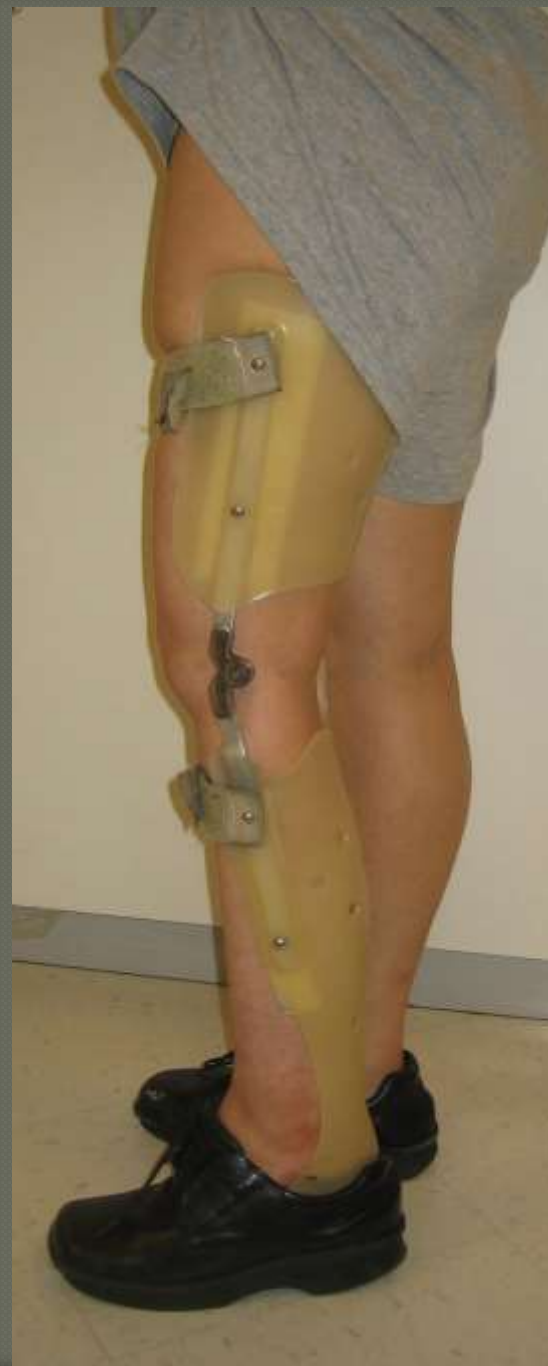Background Classic bone lengthening requires patients wear external fixation for the distraction and consolidation phases and there is fracture risk after frame removal. Our technique of lengthening with the Taylor Spatial Frame™ and then insertion of a locked plate allows earlier removal of the external fixator during consolidation. Plate insertion is accomplished through a clean pin-free zone avoiding contamination and before frame removal maintaining bone

27 extremities in each group. We compared time wearing the frame, bone healing index, external fixation index, joint ROM, alignment, and complications.

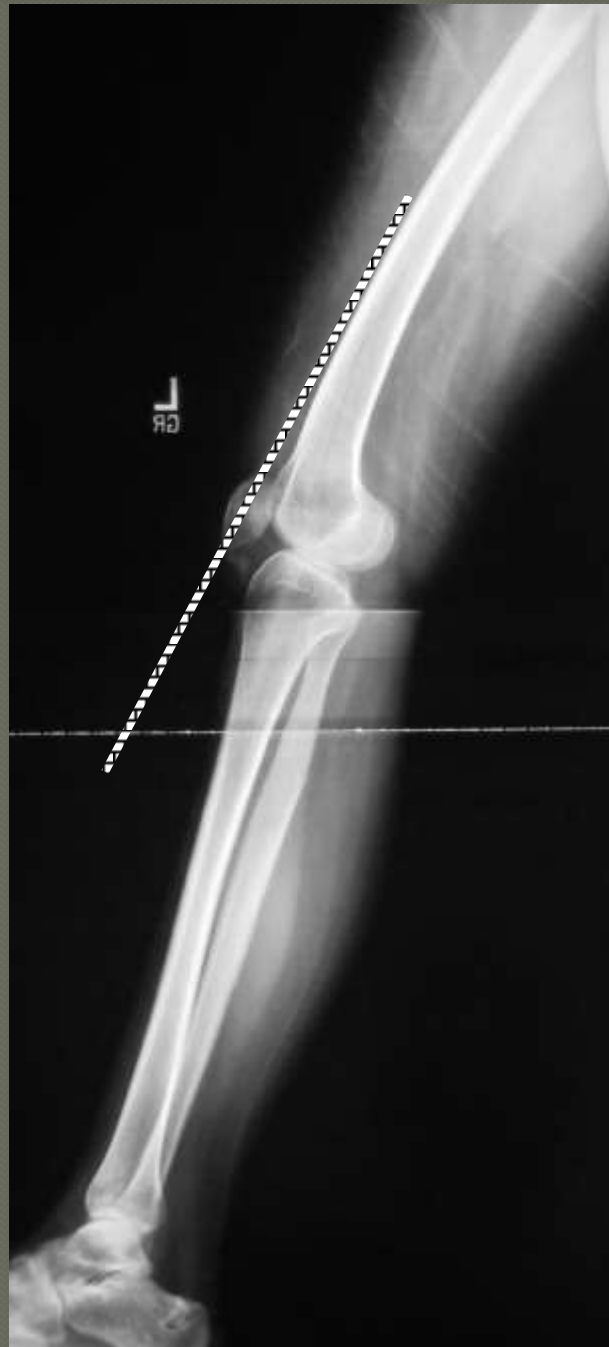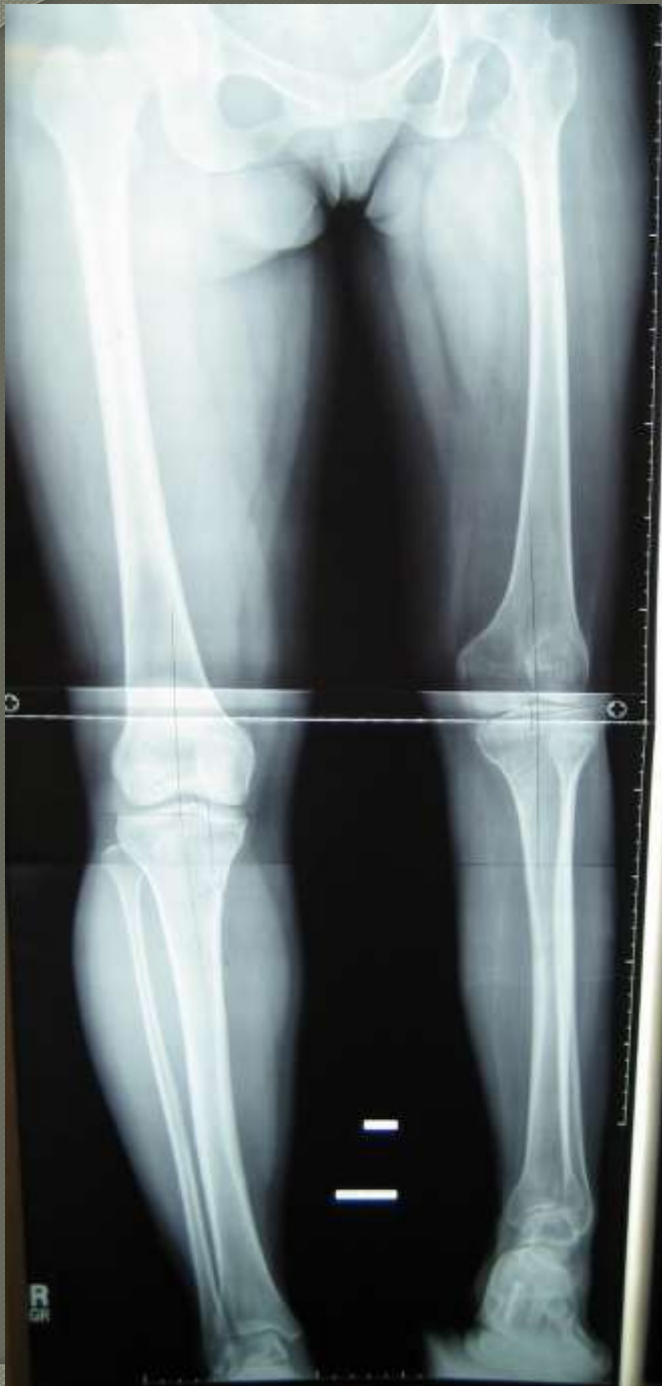Results The time wearing the frame and external fixation index were lower in the LAP group (4.5 versus 6.2 months and 1.5 versus 2 months/cm). Deviation from normal alignment was observed in seven and six patients in the LAP and classic group, respectively. Varus malalignment in two patients in the LAP group was associated with plate

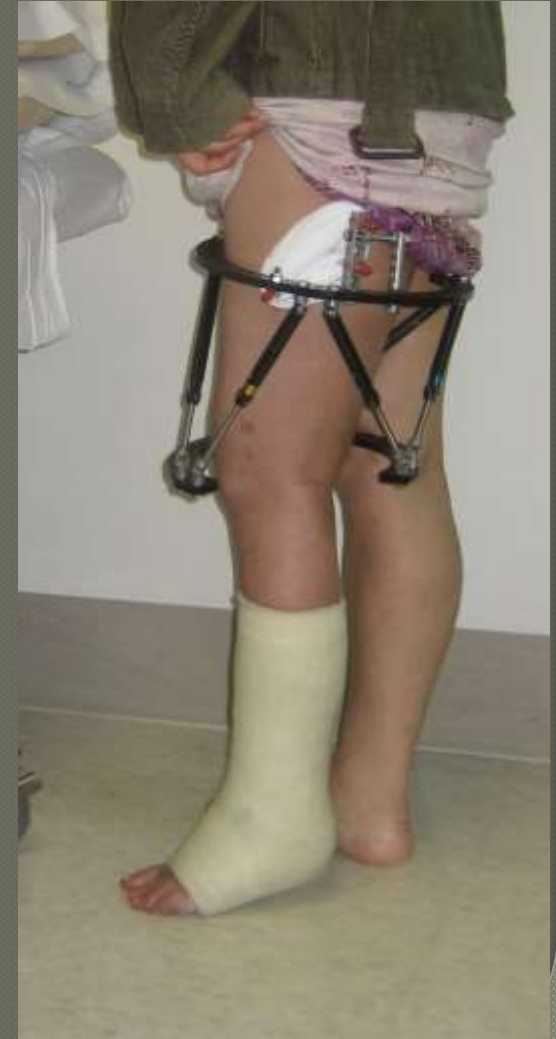
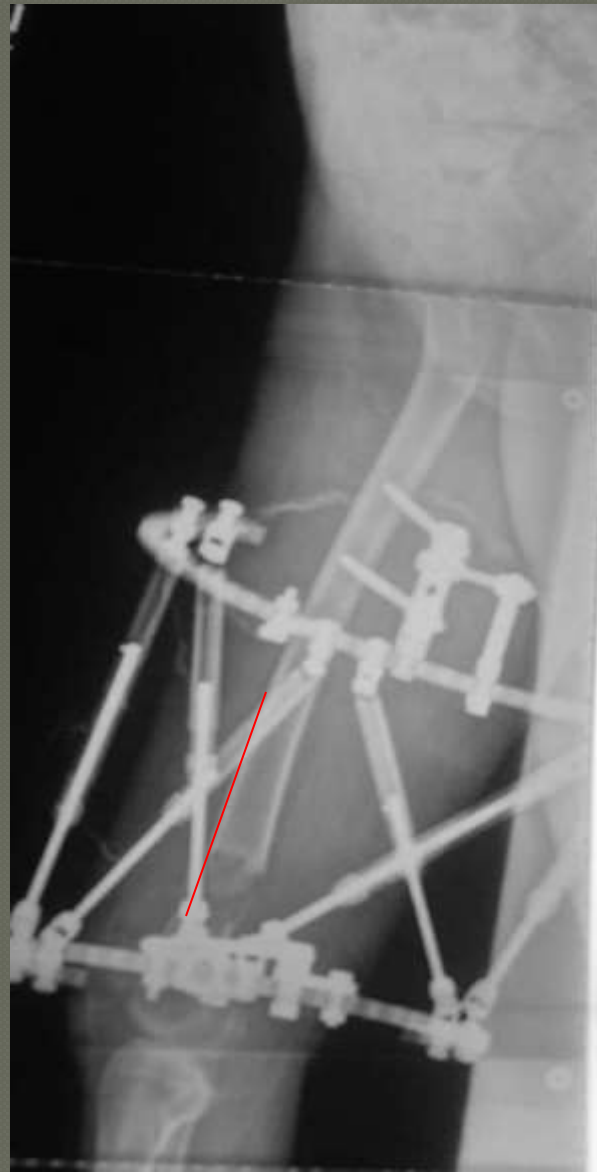


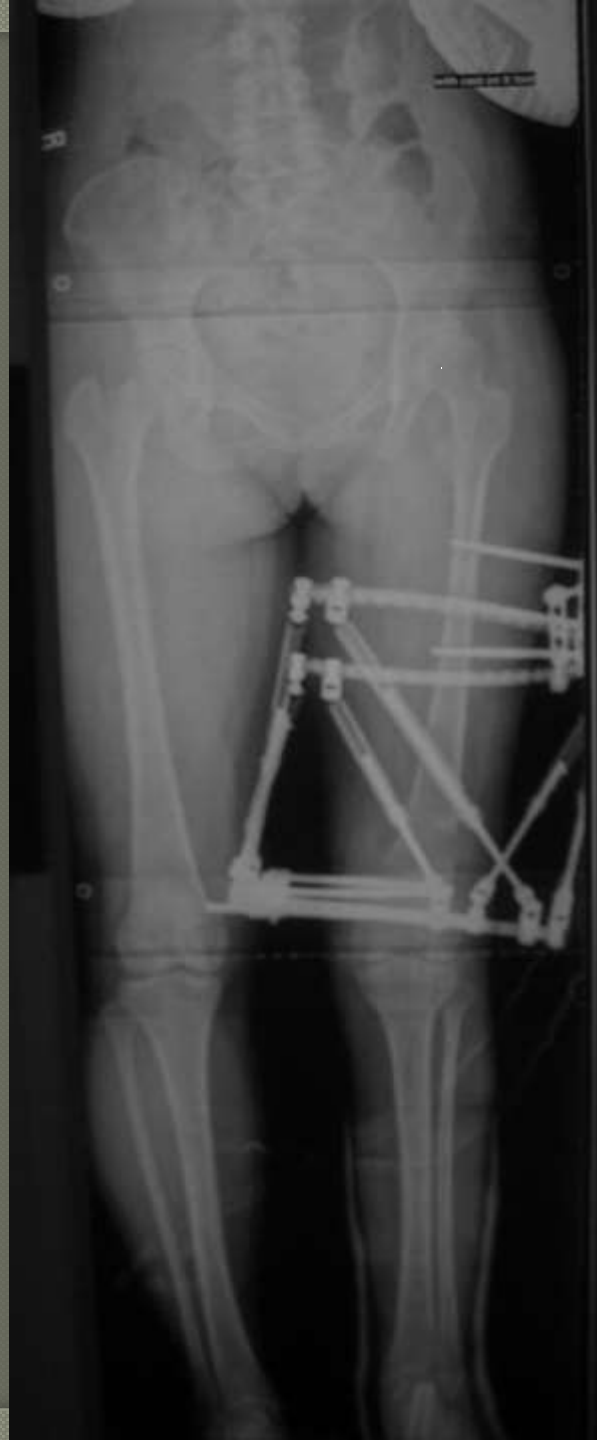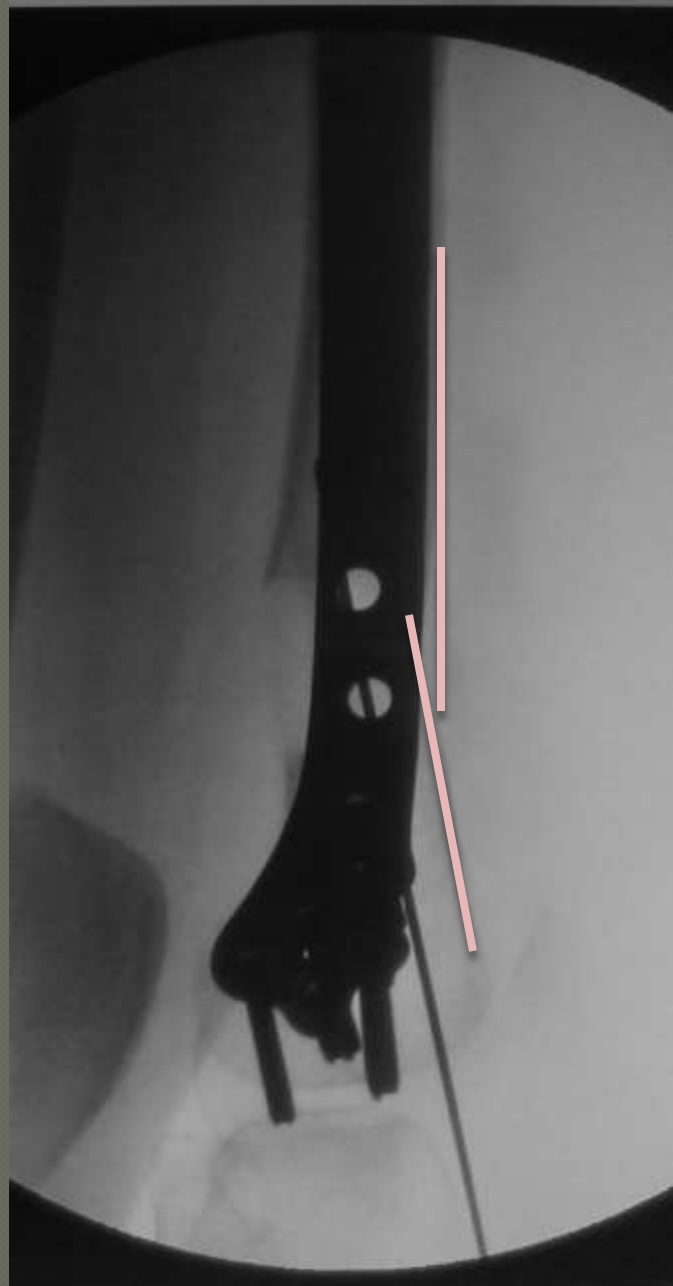


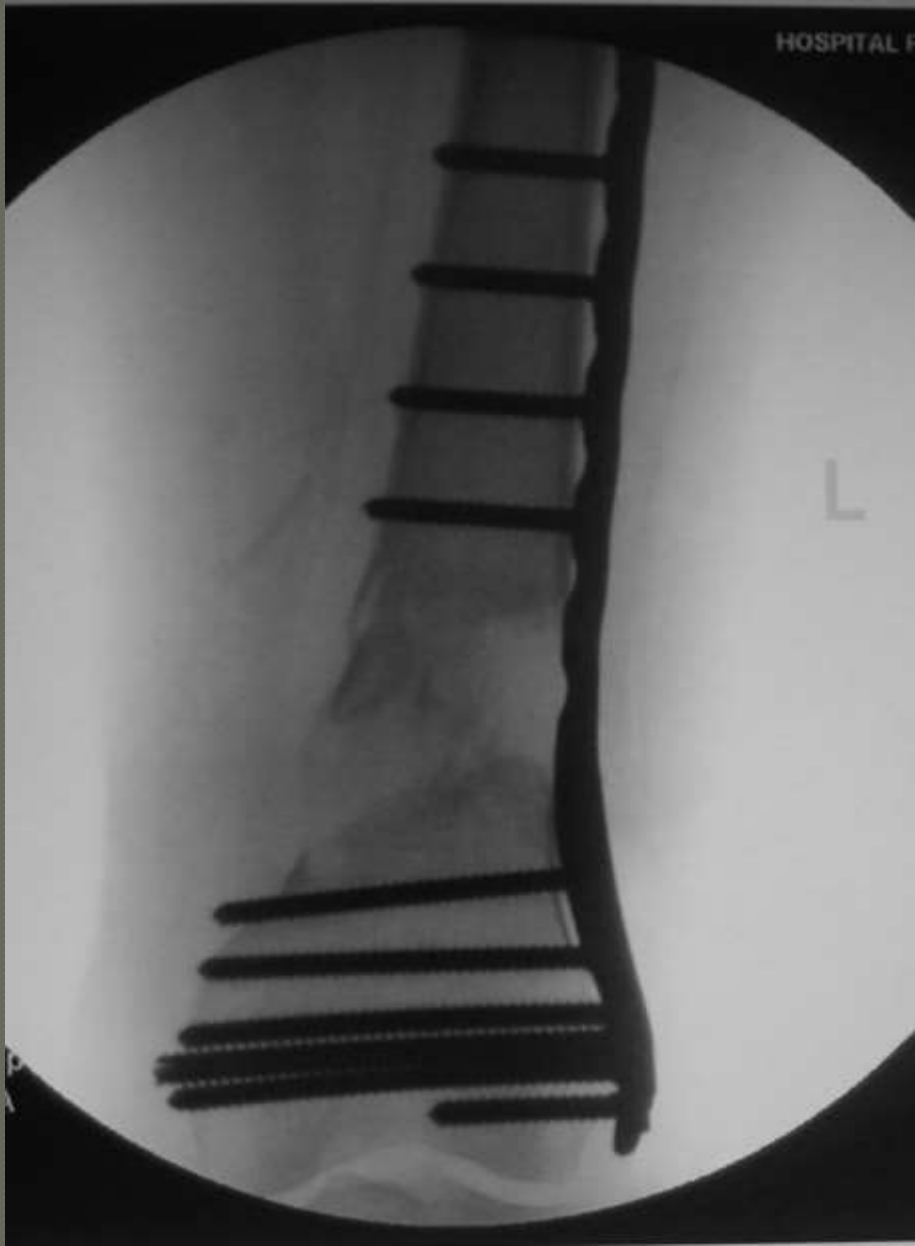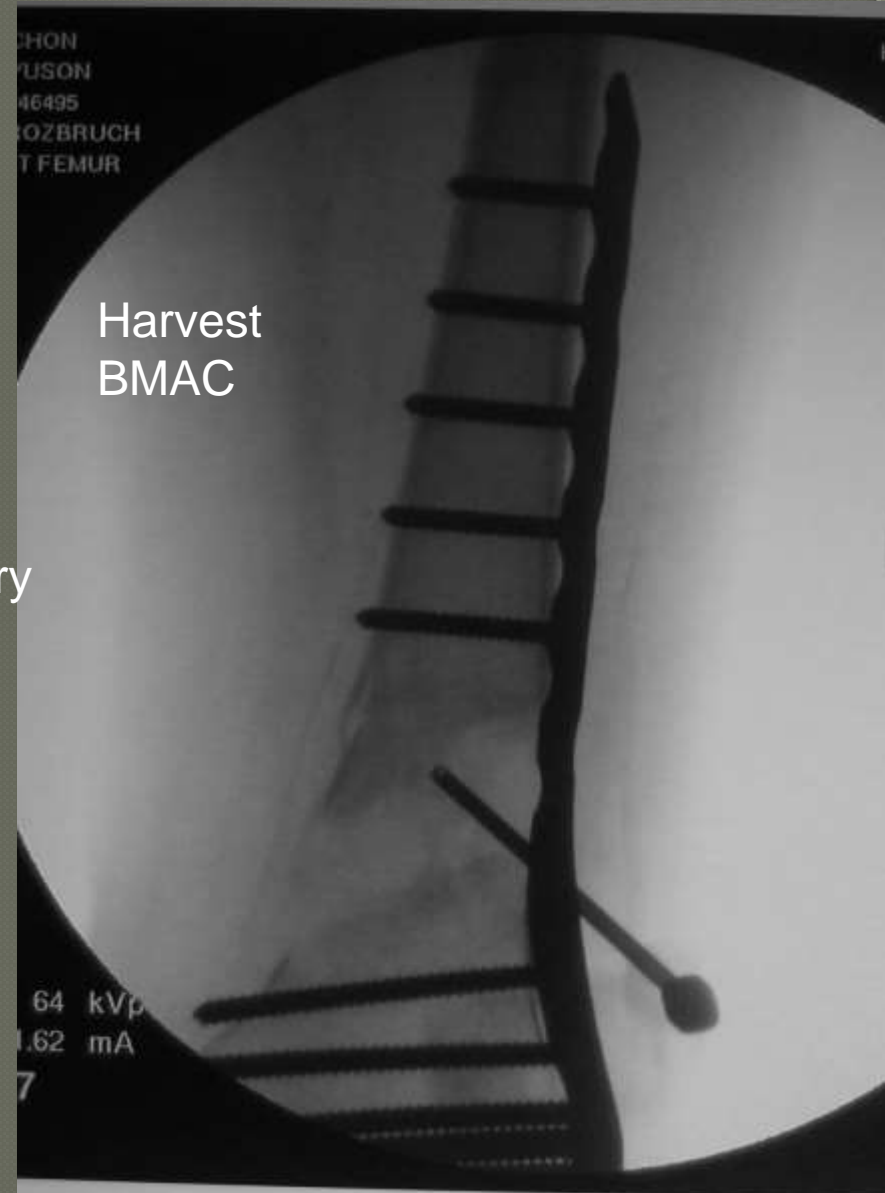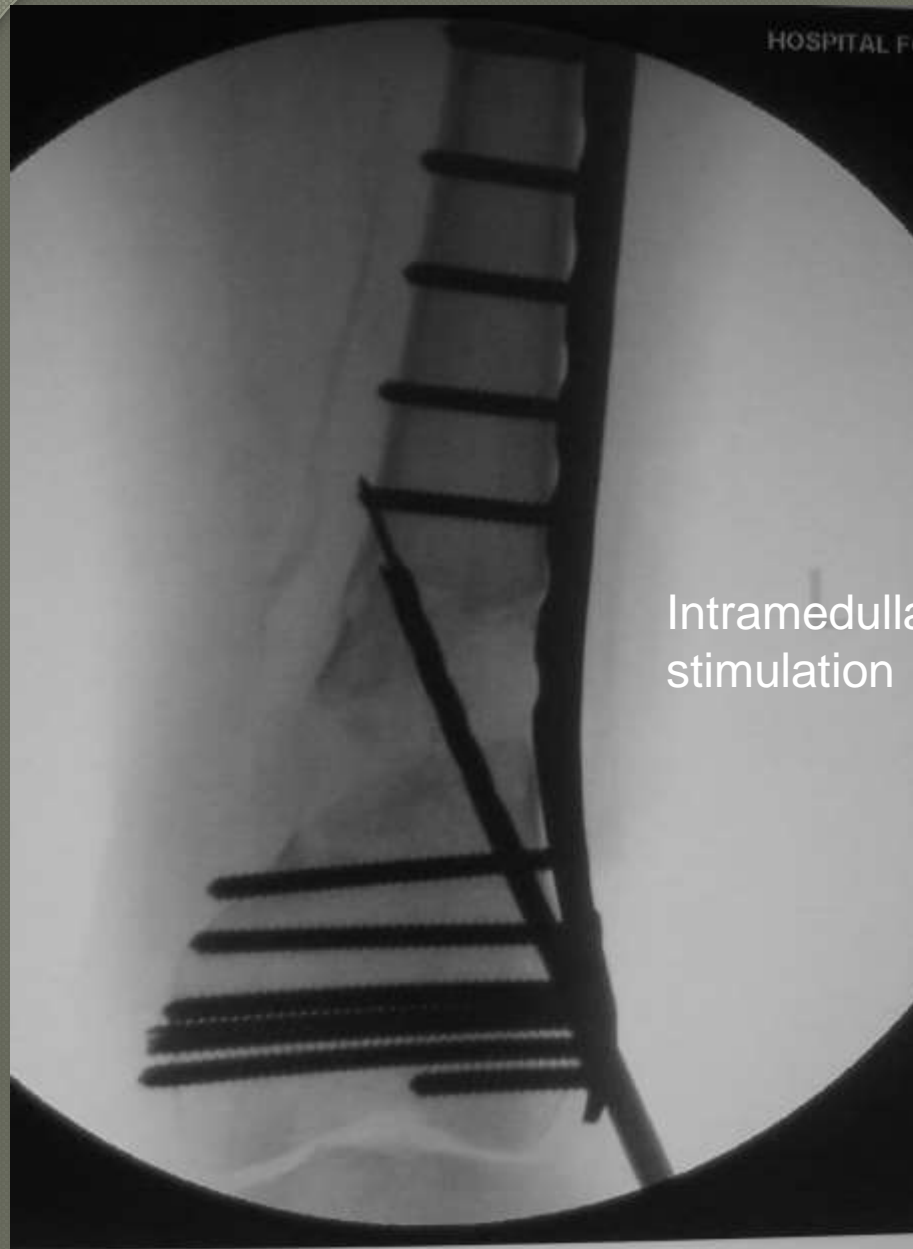
Polio
LLD
Flexion deformity
Weak quads

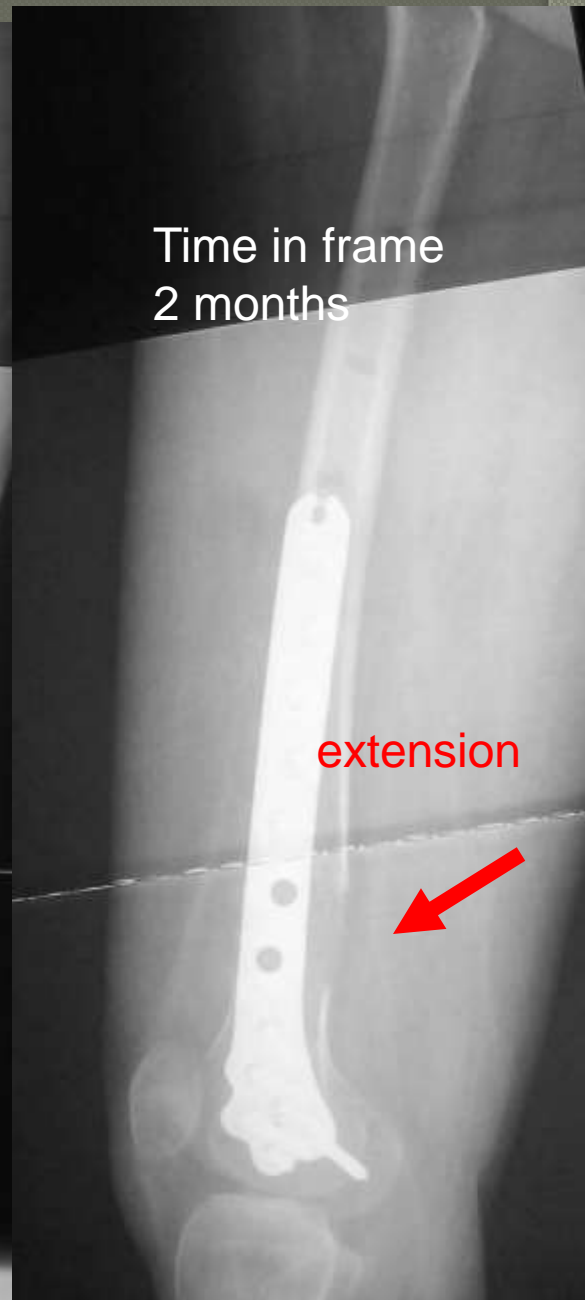
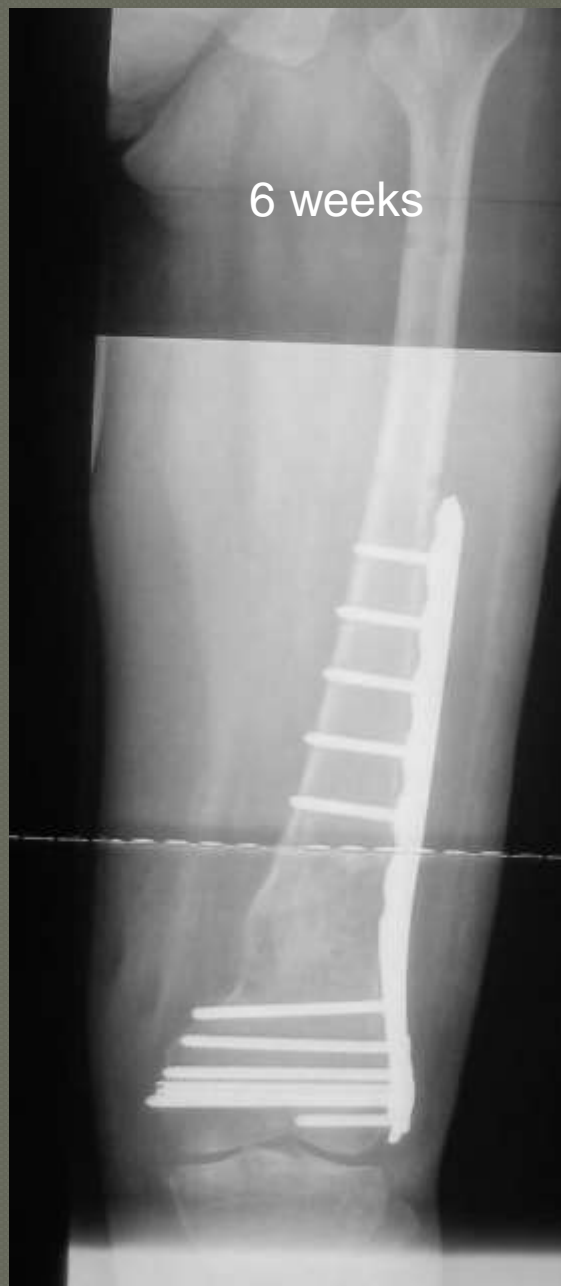











Internal Lengthening Nail

○ Requirements

- Reliable mechanism for rate and rhythm

○ IM canal must be suitable

- Size
- Geometry

○ Deformity

- Correct with nail
- Correct with plate @ different level

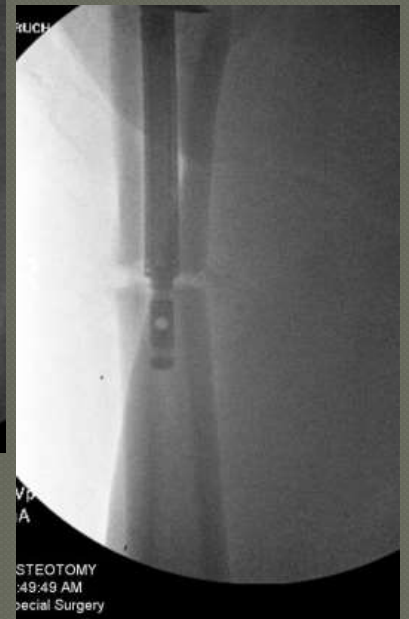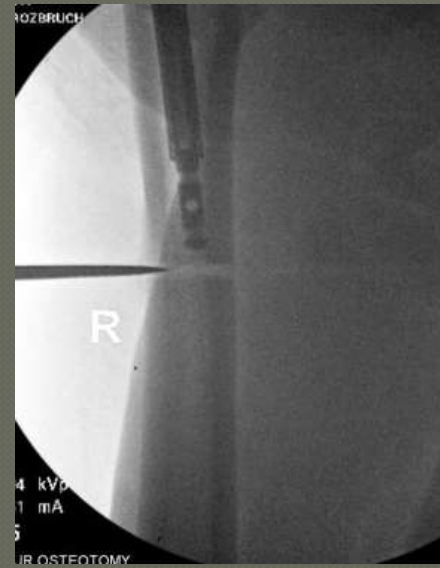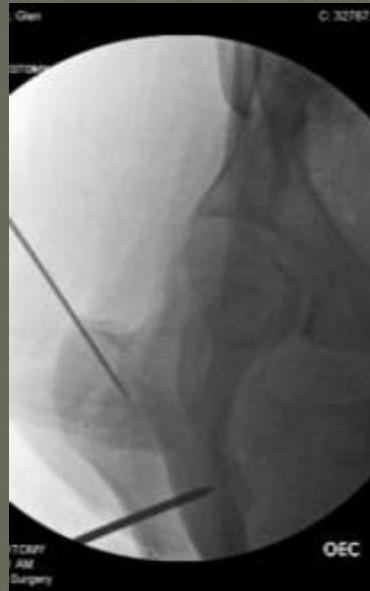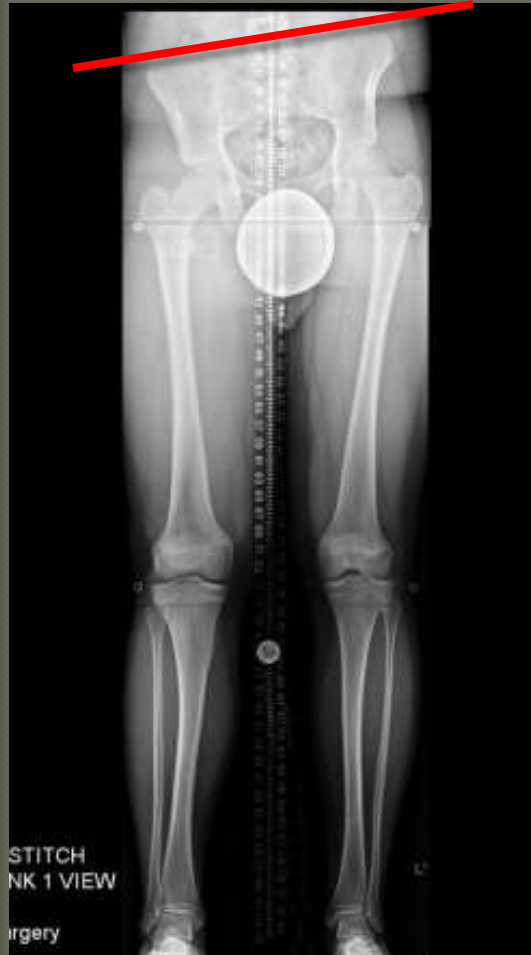○ Pros

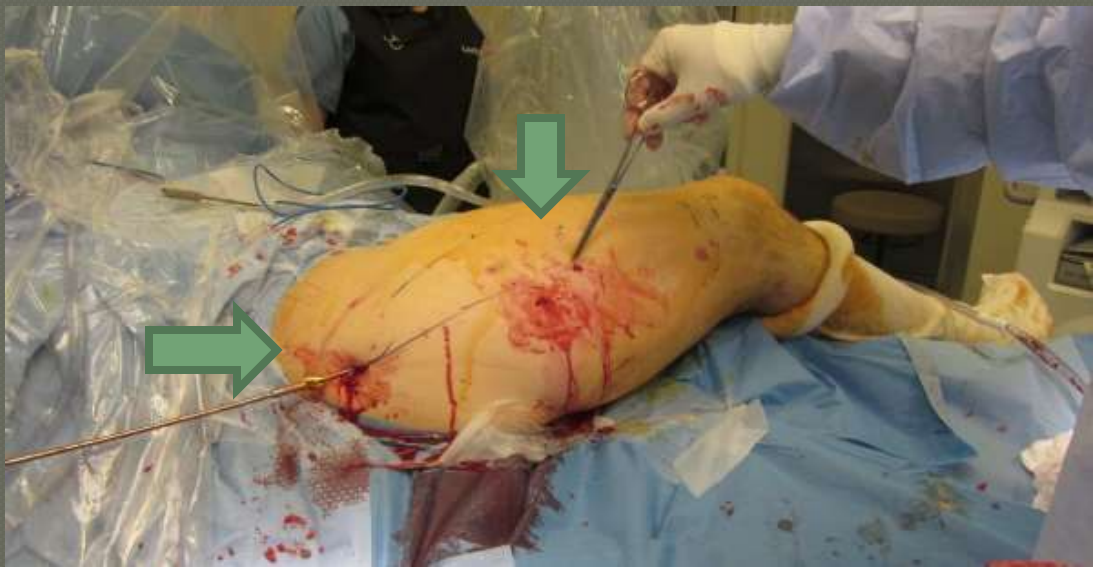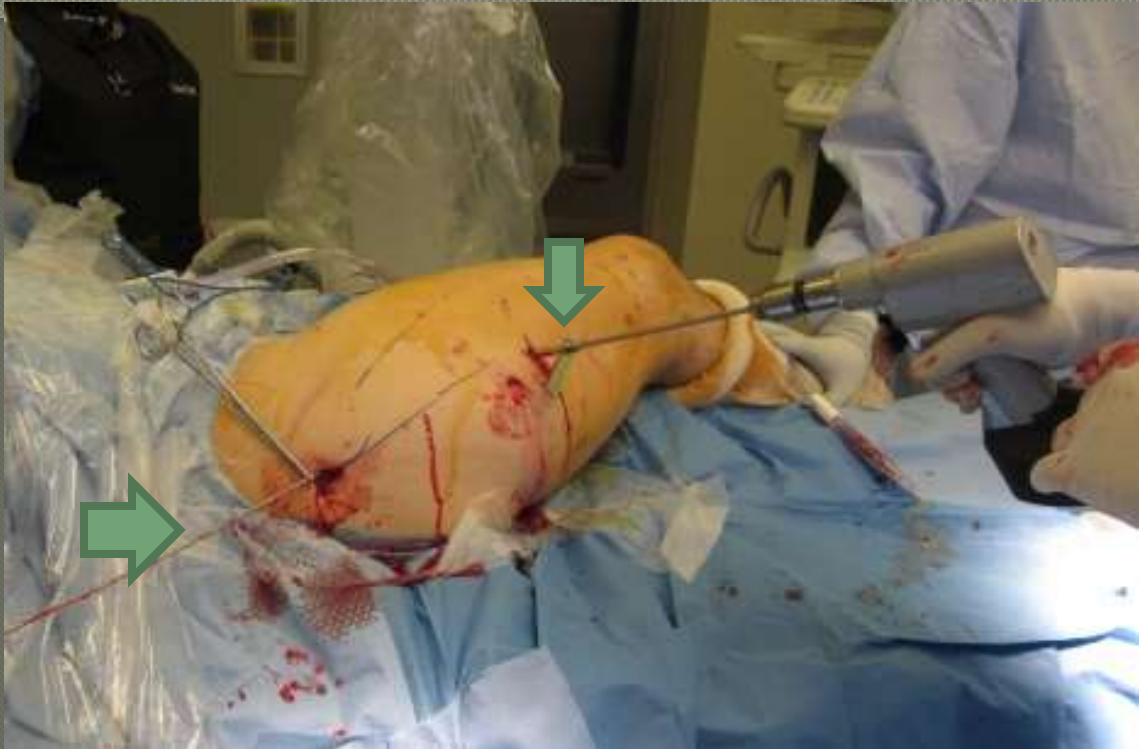- No ex fix
- No pin problems
 - Pin infections
 - Soft-tissue tethering
- Better joint ROM
- Very accurate

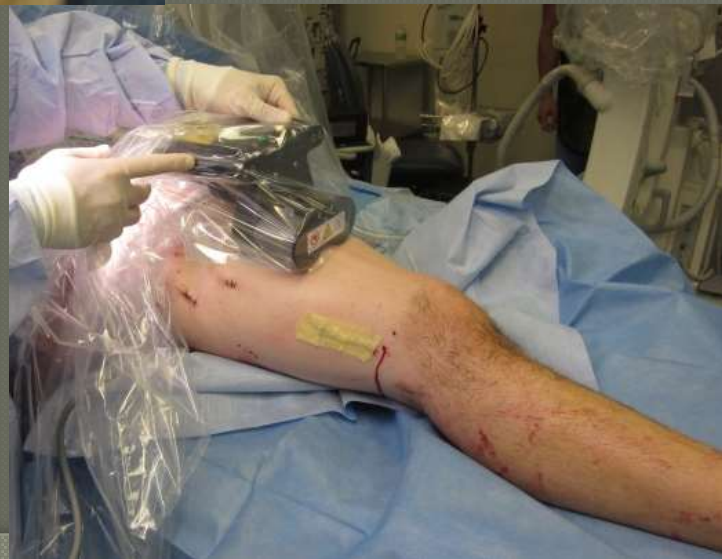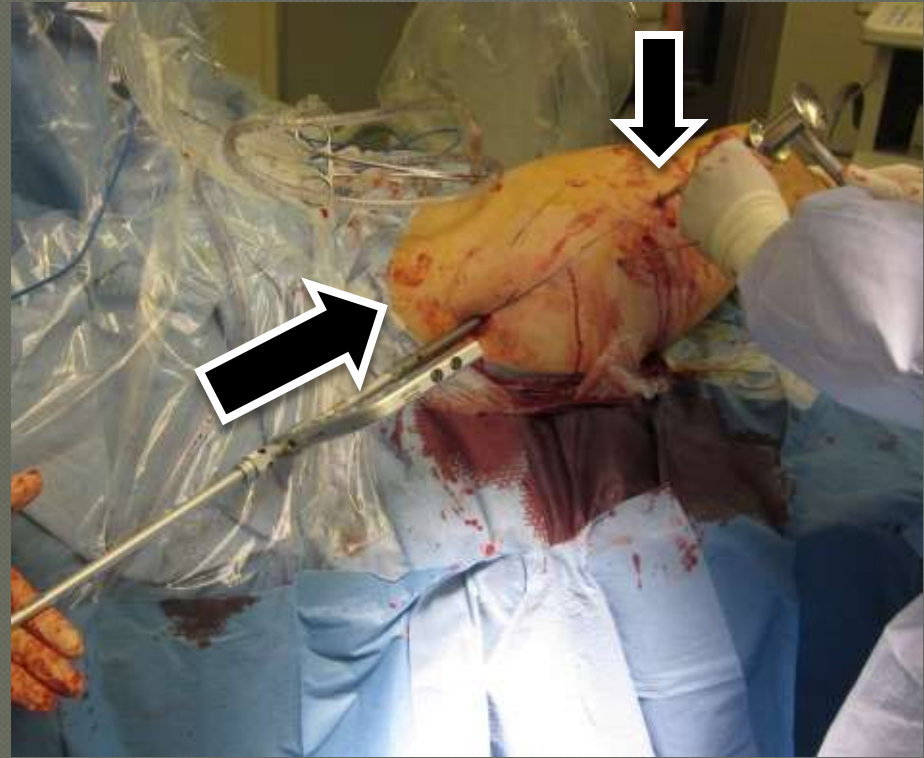
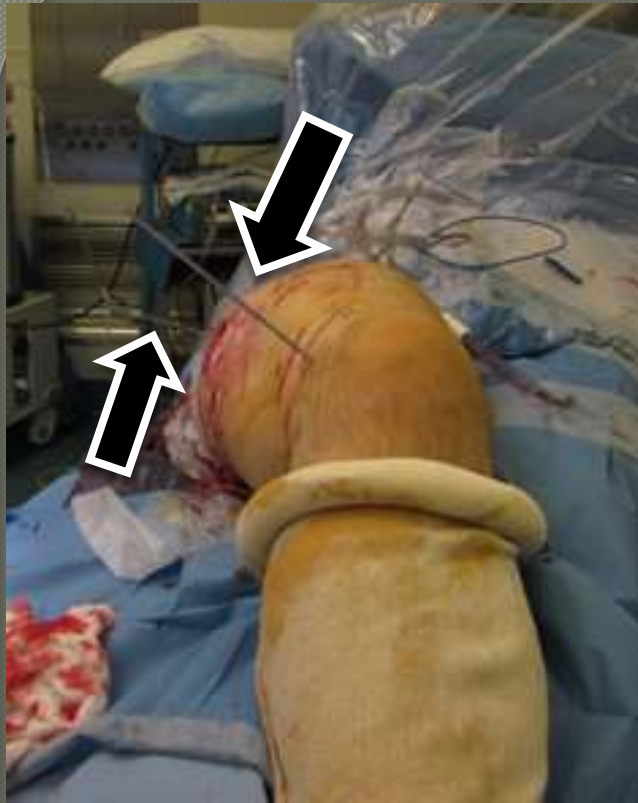
○ Cons

- Invasive
- Infection risk
- Blood loss

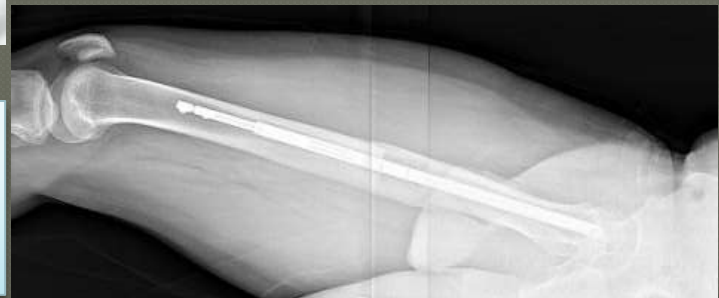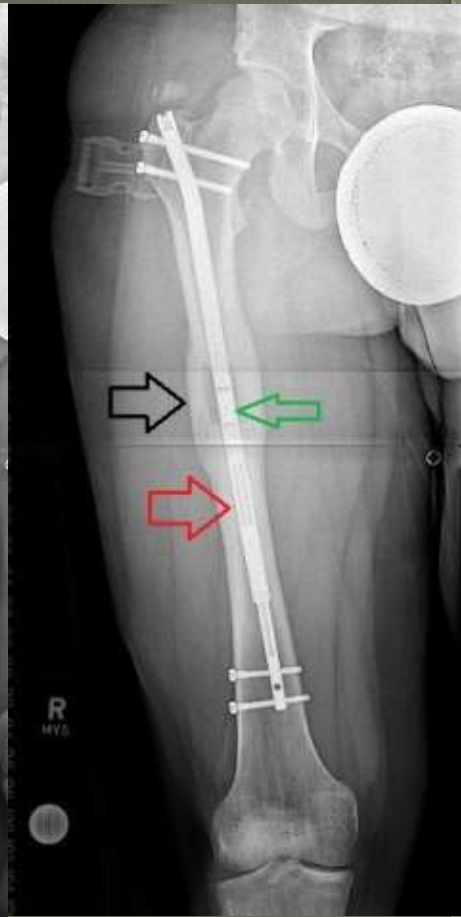
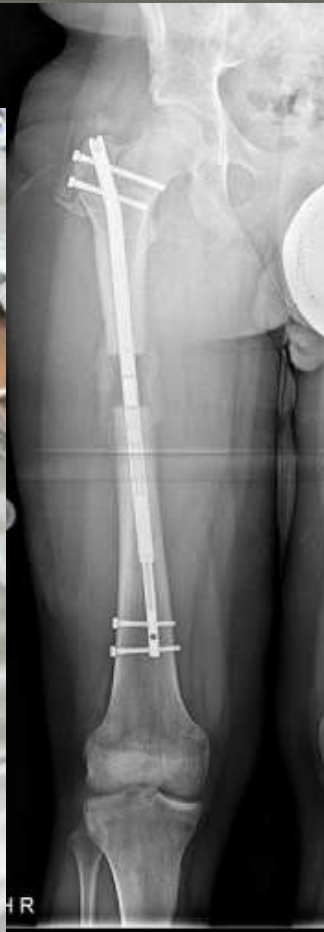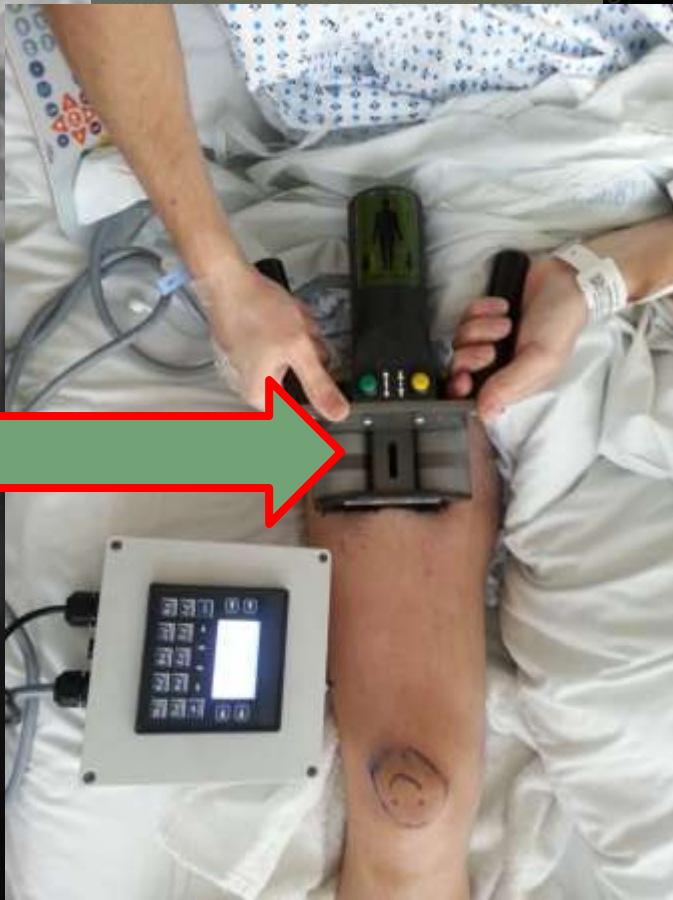
Motorized internal lengthening IM nail





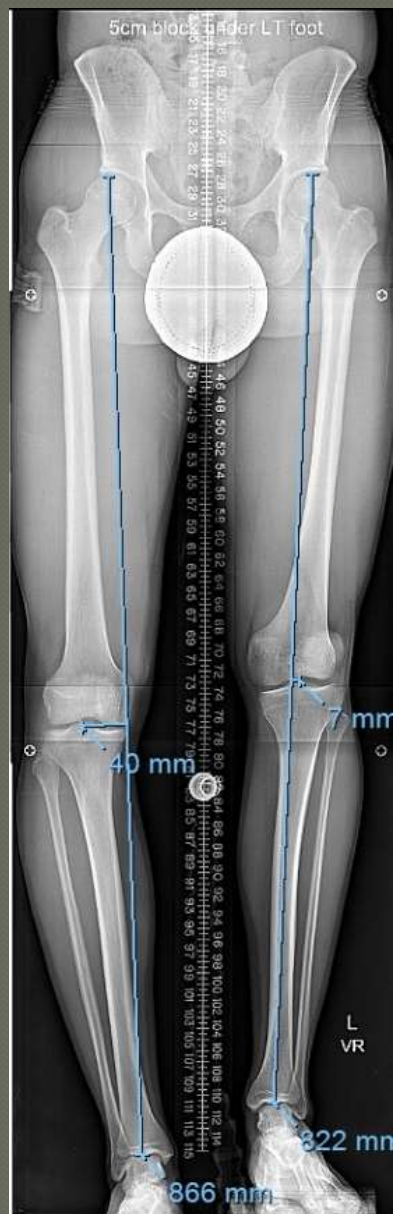

y, Glen



STITCH R
WS
59 AM
Surgery

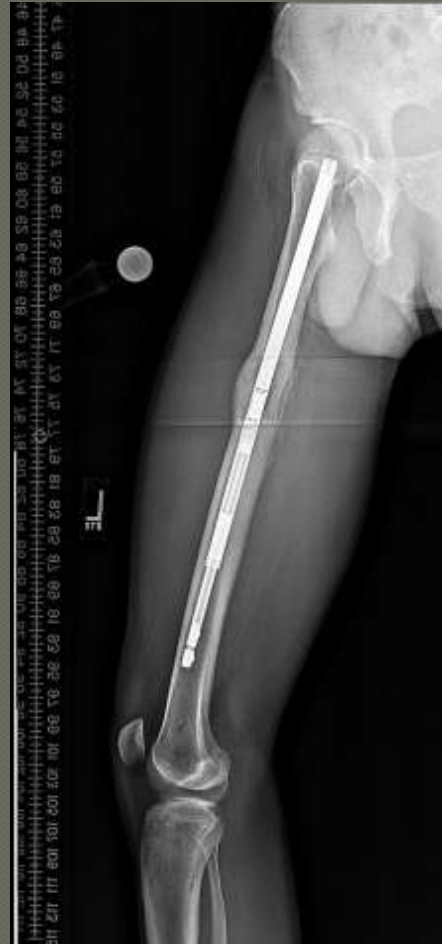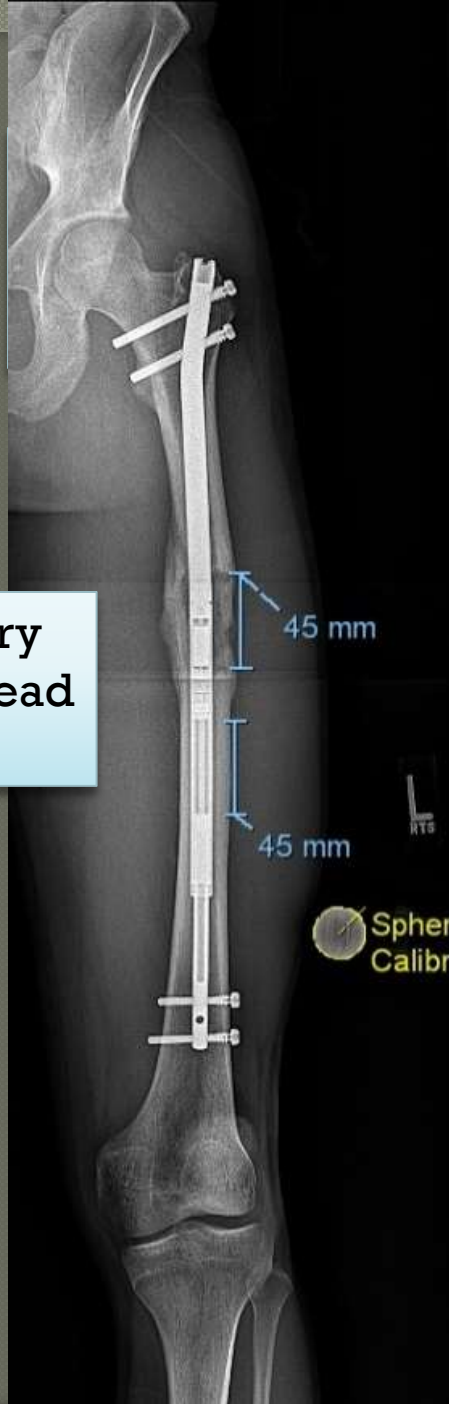Trochanteric Entry
Good for adolescent
< 18 yrs.

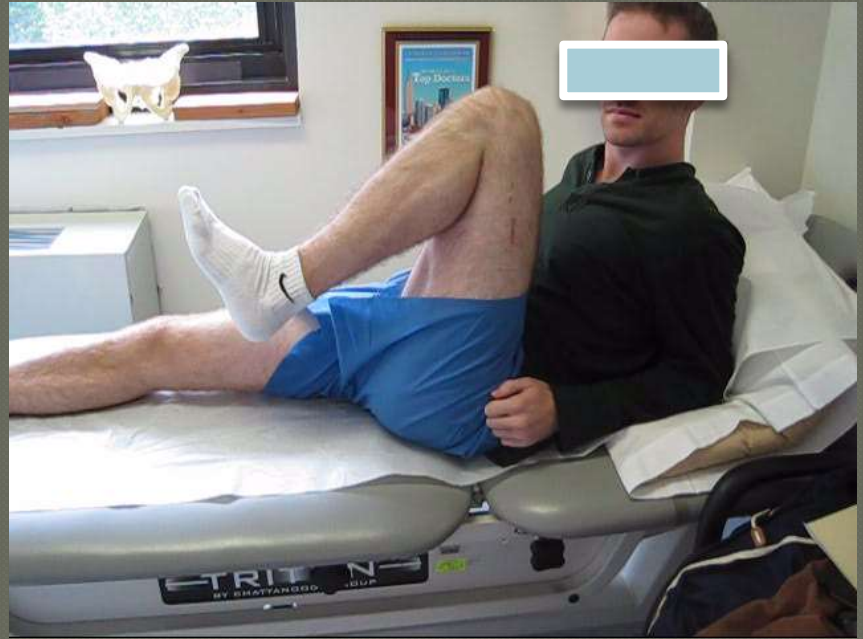
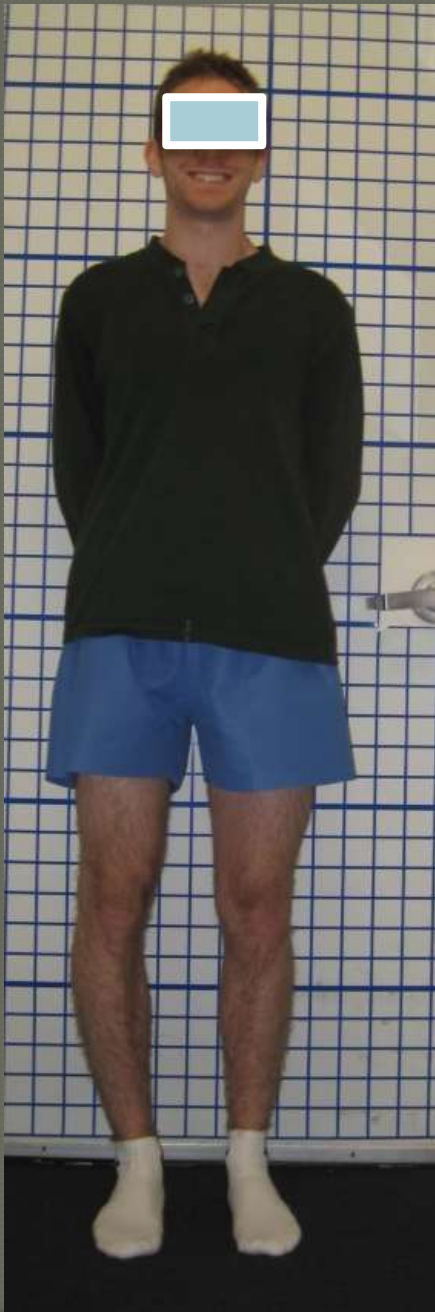
LLD = 4.5 cm
25 y/o male
Congenital LLD

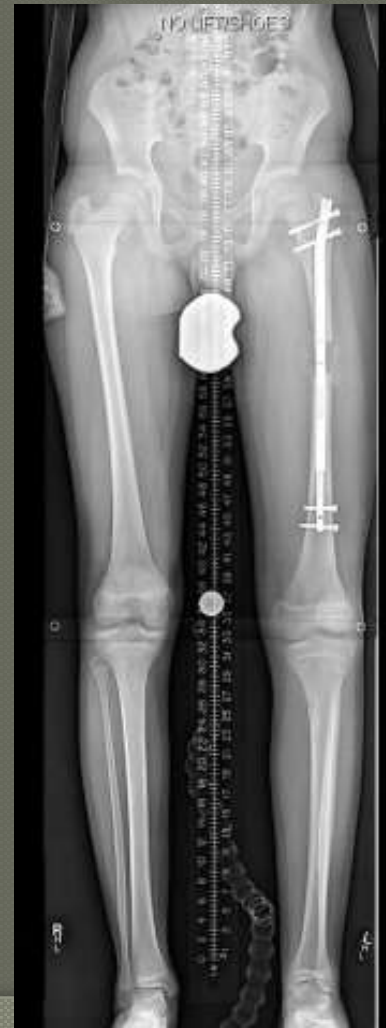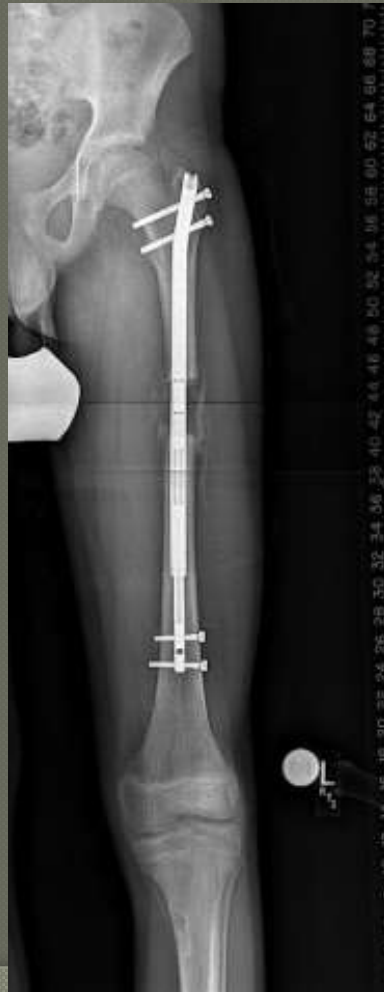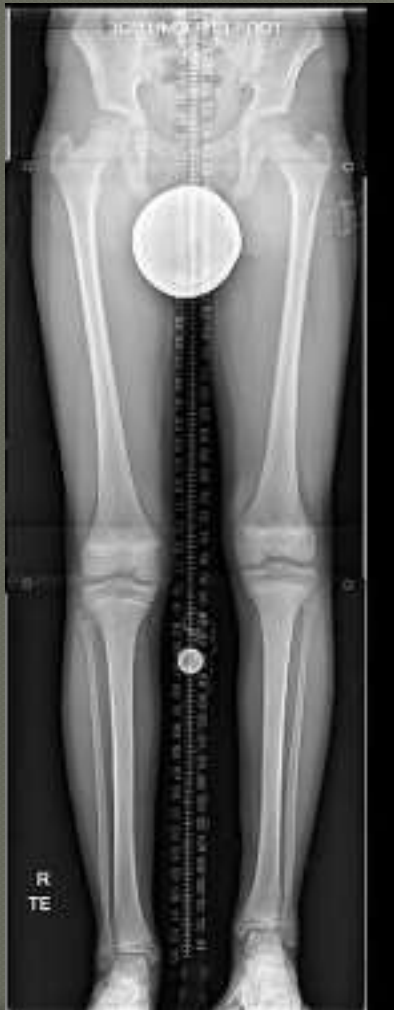3 months postop!

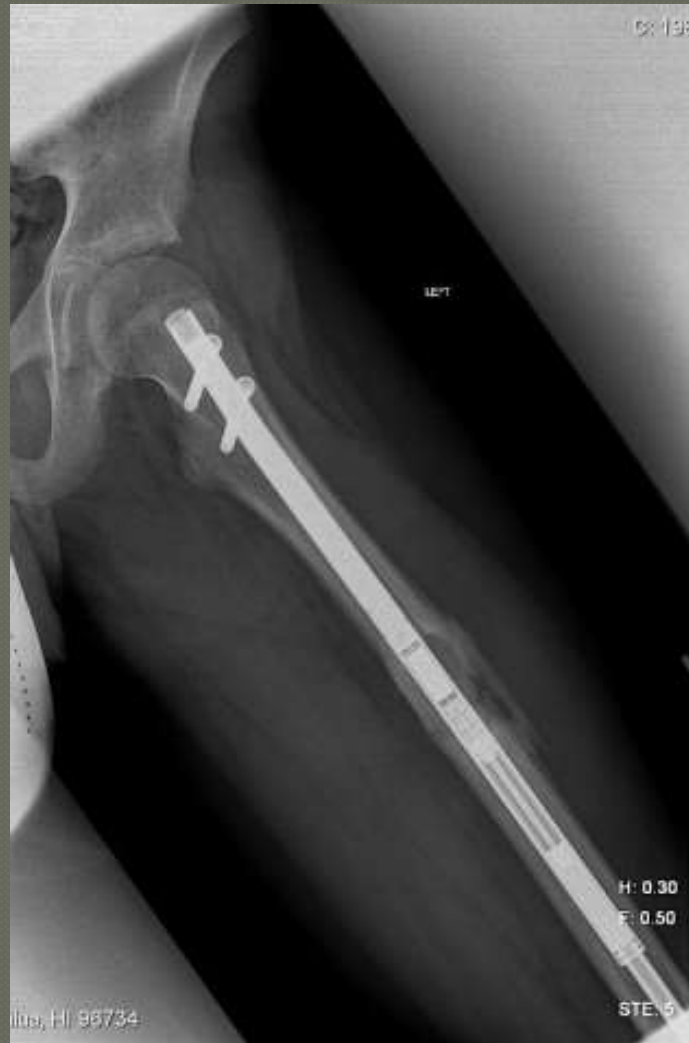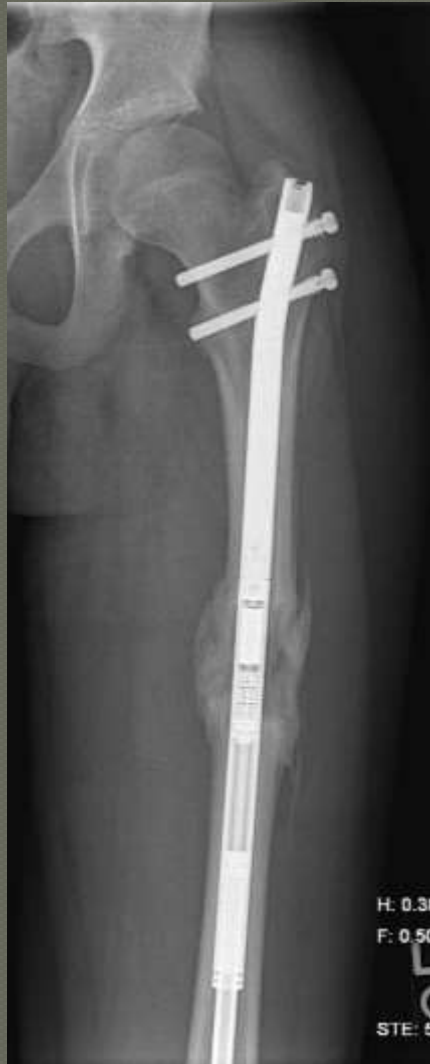Troch entry
Nail can lead
To varus

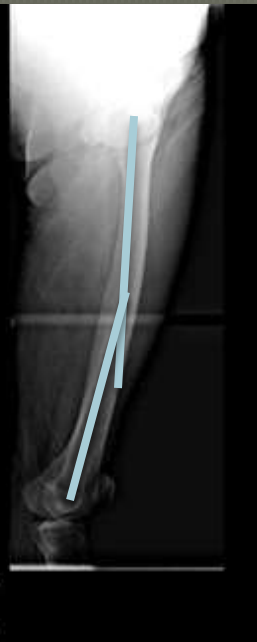
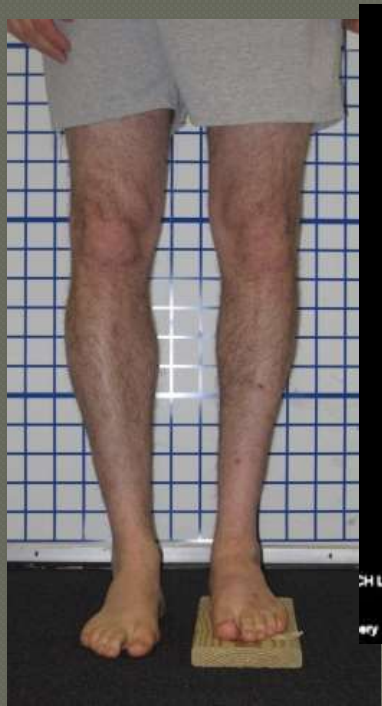
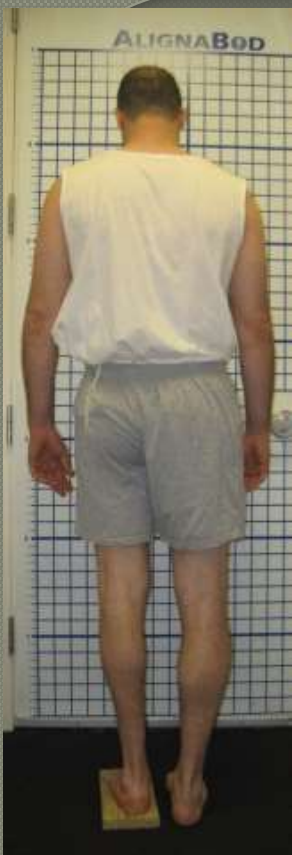


12 year old male with congenital LLD

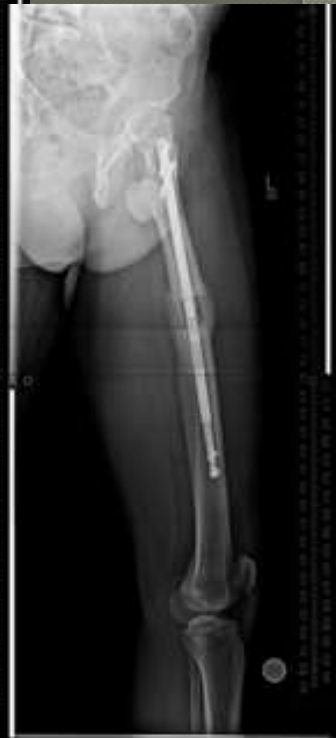
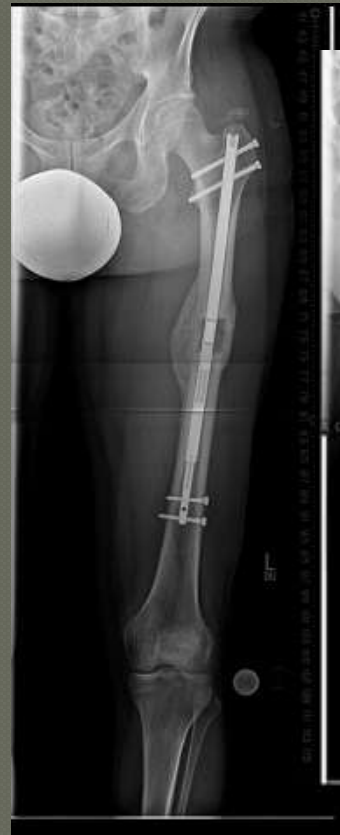
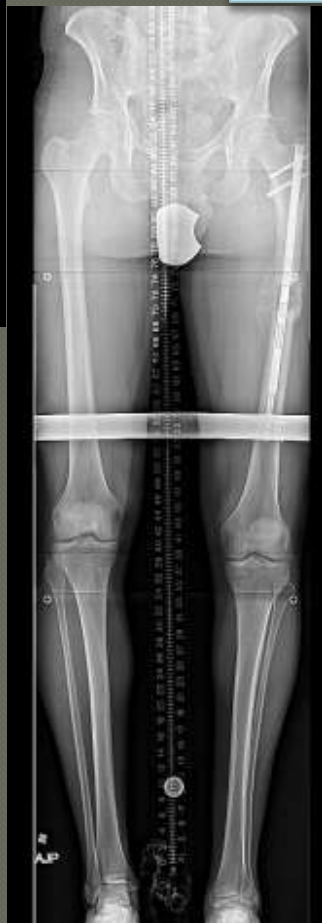


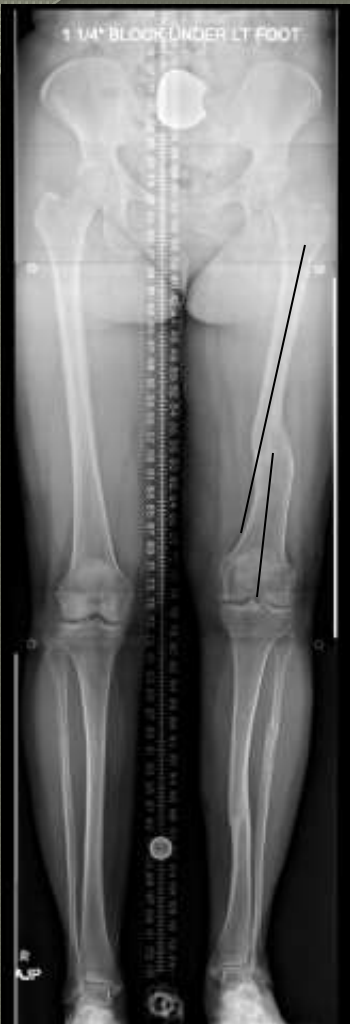
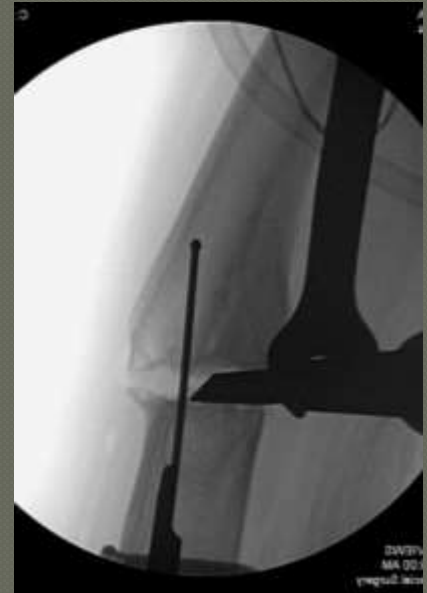
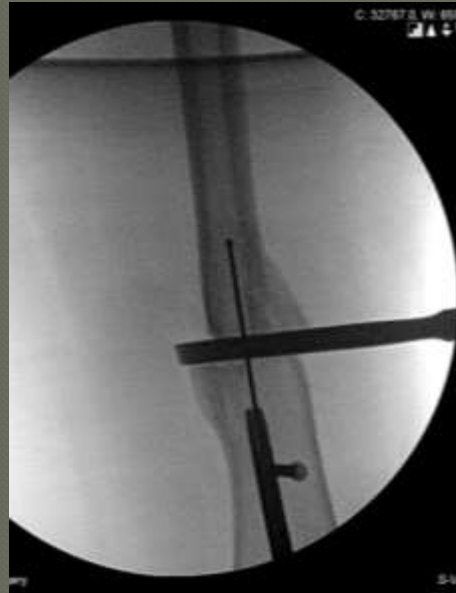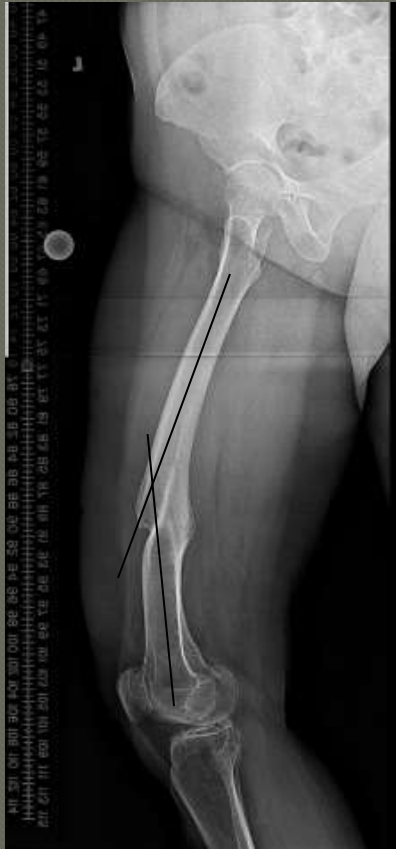Piriformis Entry- my preference
In adult

Clubfoot, LLD 1 inch

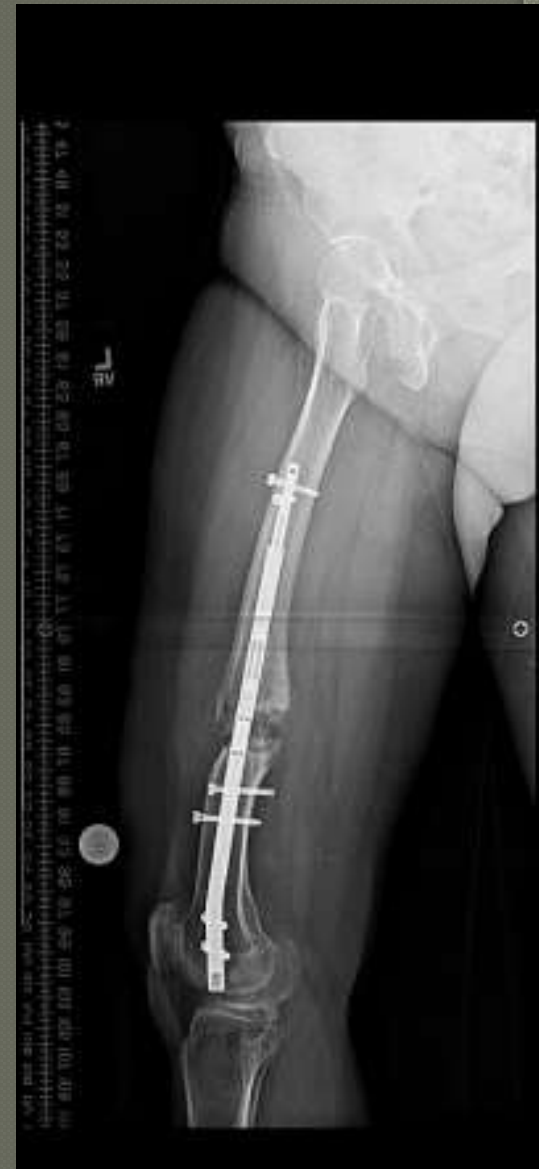
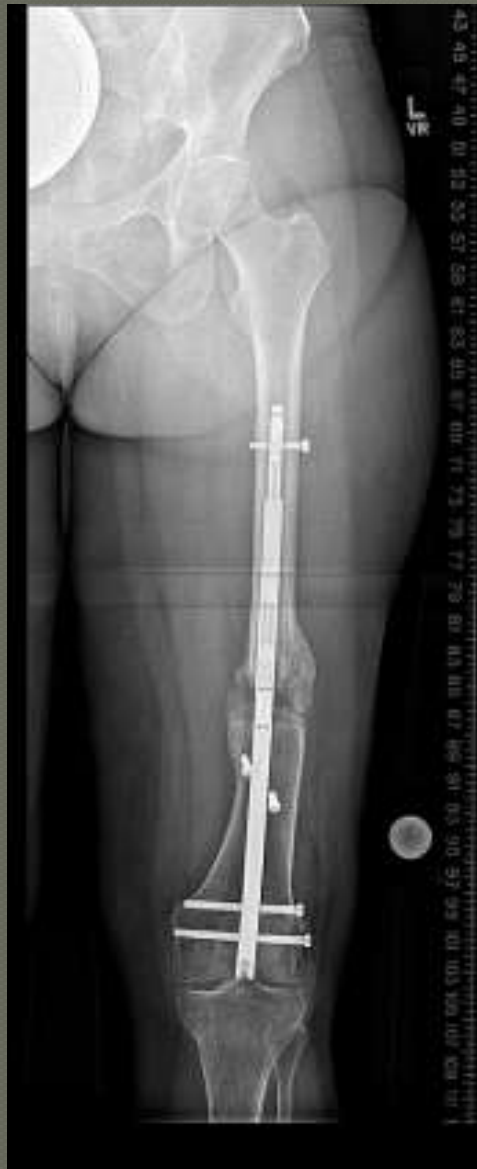
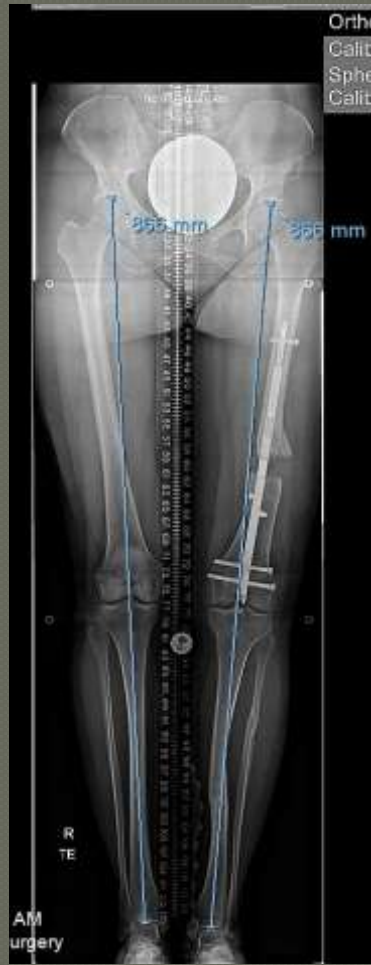
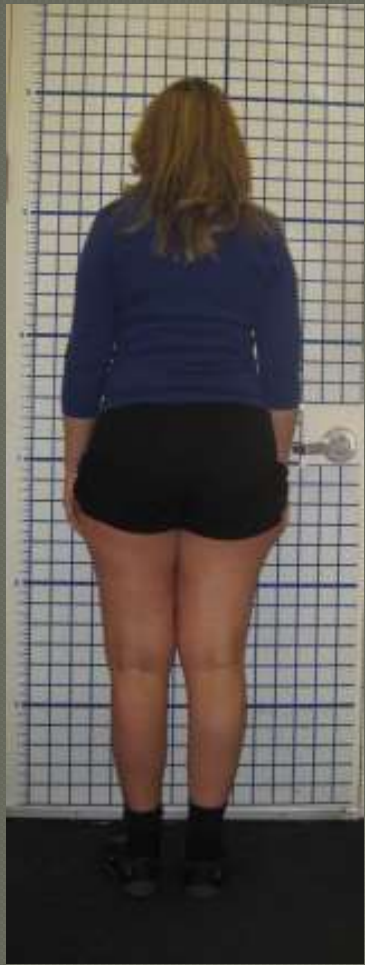
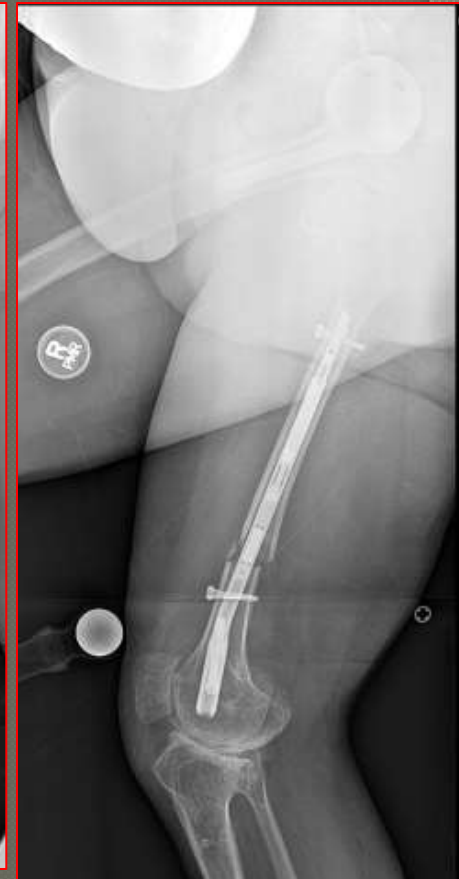
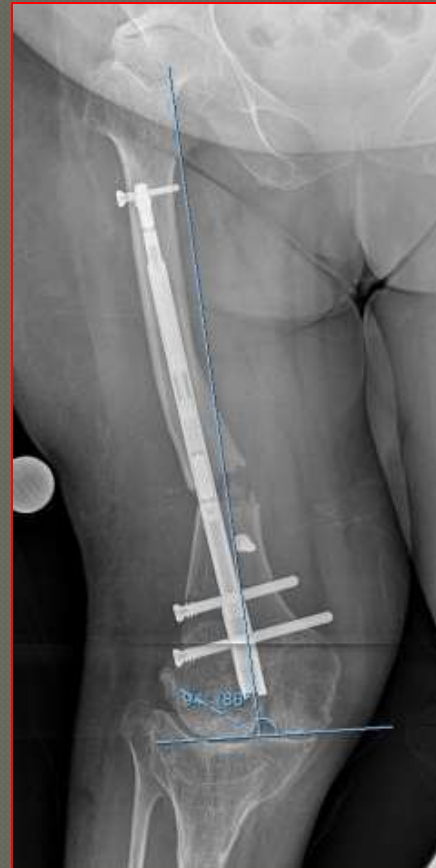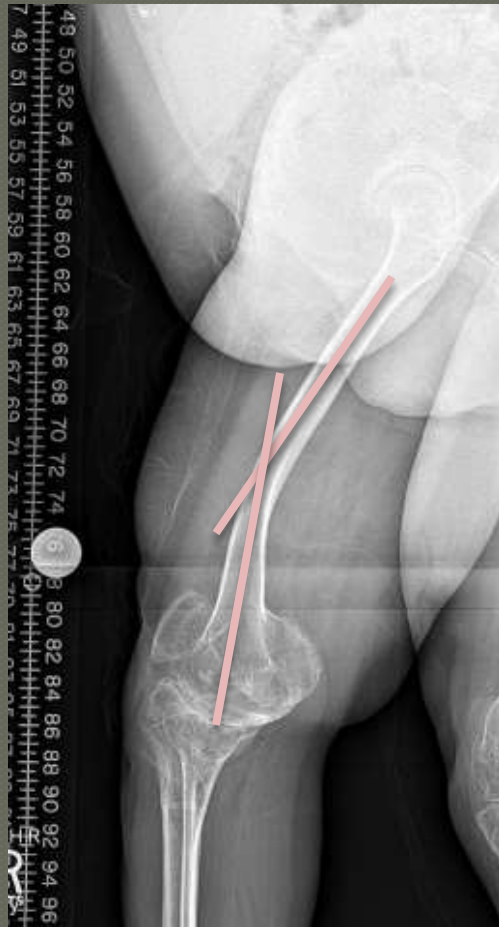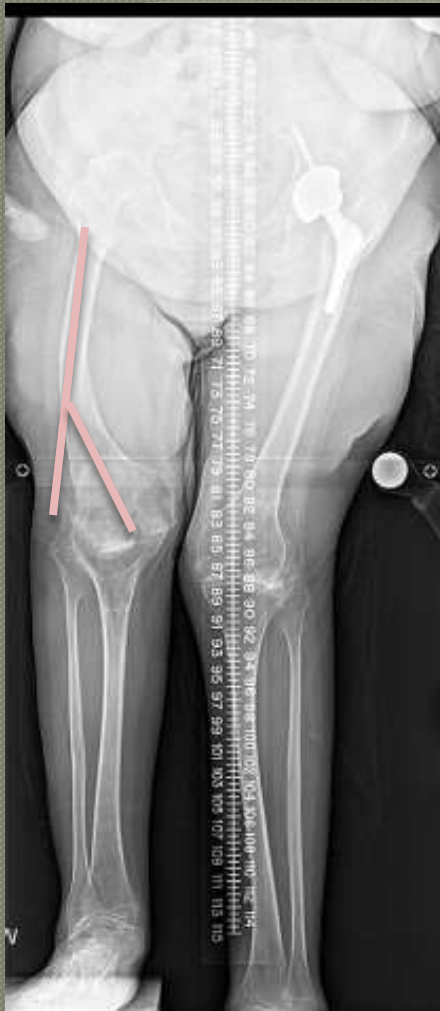Malunion, LLD 3 cm
AP translation & PC deformity



Osteotomy, translate with
Osteotome, pass wire,
Ream



Blocking screws needed to narrow canal



5 cm LLD; varus, procurvatum

Precision of the Precice[®] Internal Lengthening Nails

Yatin Kirane, MBBS, D.Ortho, MS, PhD
Austin T. Fragomen, MD
S. Robert Rozbruch, MD

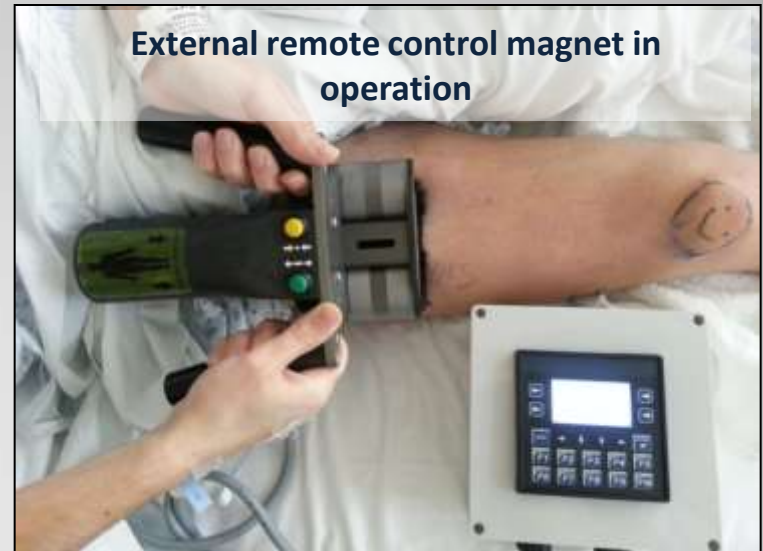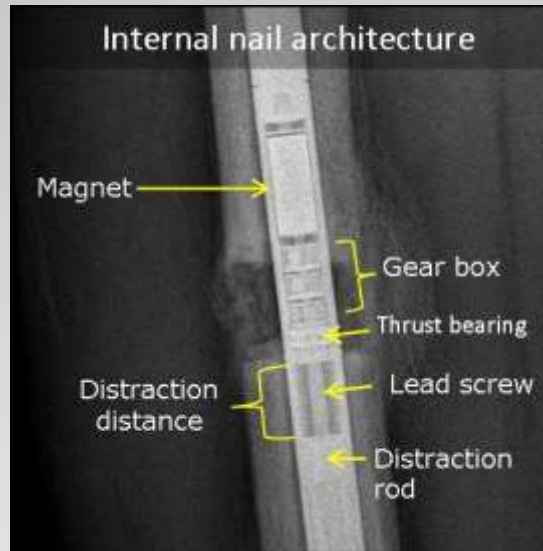

Limb Lengthening and Complex Reconstruction Service
Hospital for Special Surgery, New York, NY

Presented at LLRS July 2013
Accepted to CORR

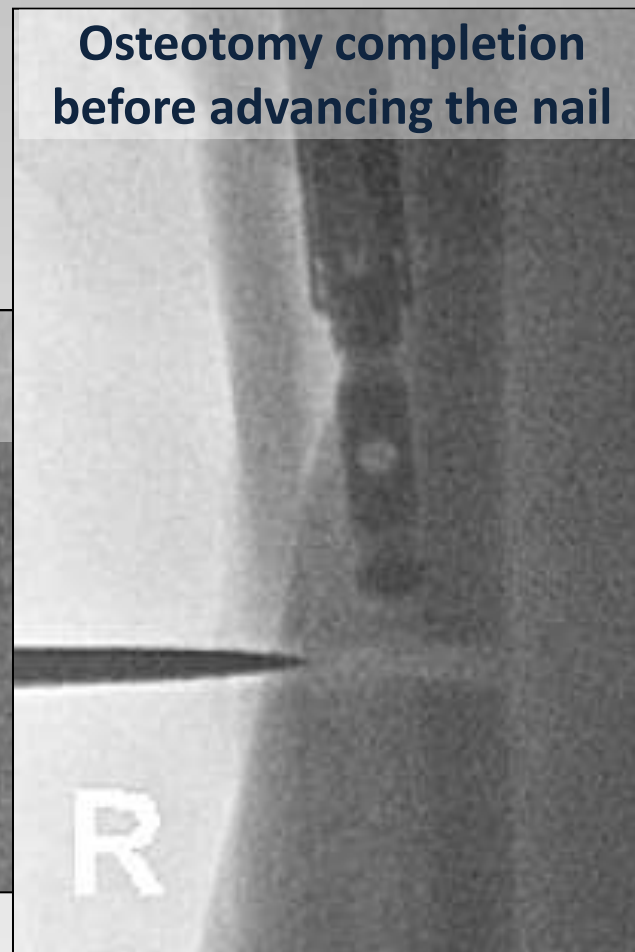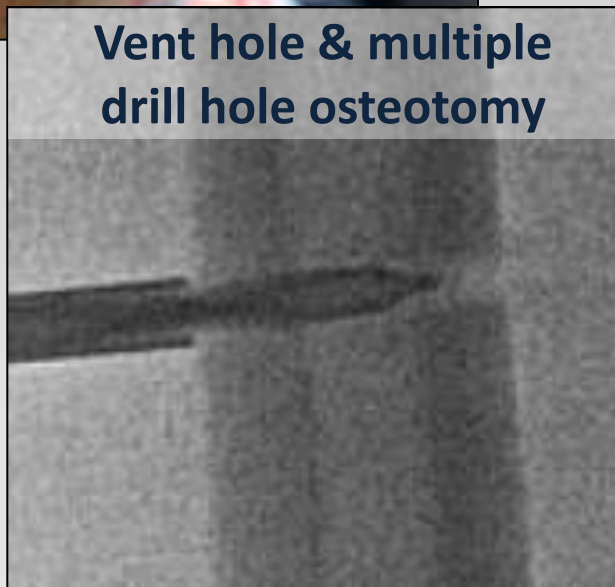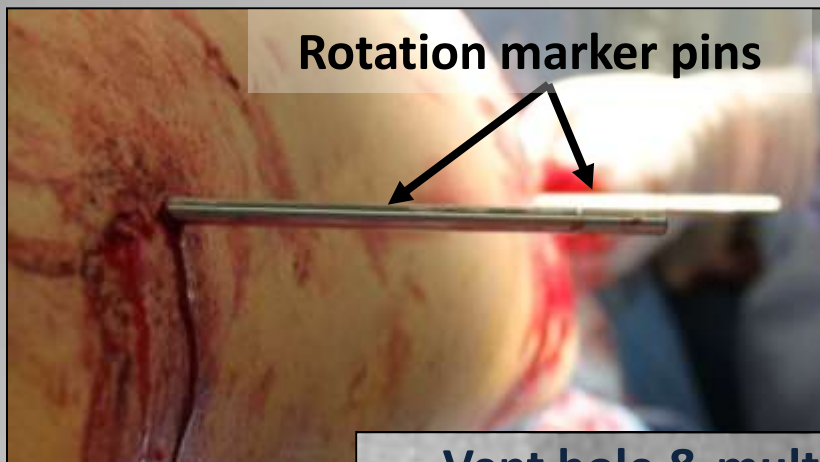
Precice® Nail

Ellipse Technologies Inc., Irvine, CA

- Telescopic, magnet-operated device
- Recent FDA approval
- Clinical efficacy not established





Surgical Technique

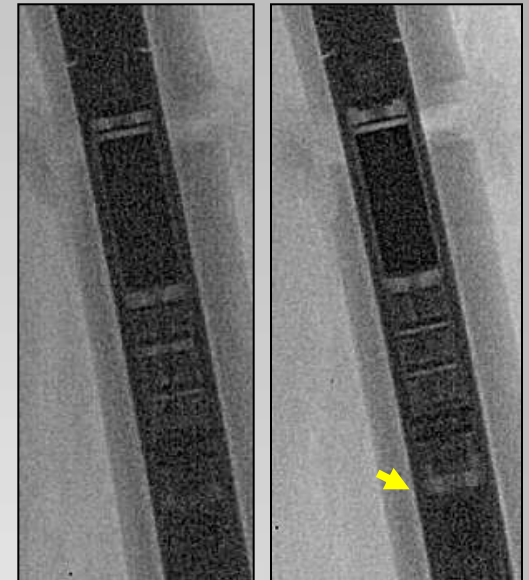


Intraop Magnet Localization & Distraction

Localization of the internal magnet



Intraop distraction



Methods

- 17 femur and 8 tibia lengthening cases
- Medical records were reviewed for:
 - Patient characteristics
 - Etiology
 - Surgery details
 - Distraction process
 - Bone alignment
 - Adjacent joint range of motion (ROM)
 - Any complications

Primary Outcome Variables

I. Accuracy of Lengthening

- Distraction distance & accuracy measured using a calibrated digital radiology system (PACS, OnePacs LLC, New York, NY)

$$A) \% \text{ Error} = \frac{\text{Distraction prescribed} - \text{Lengthening measured}}{\text{Distraction prescribed}} \times 100$$

$$B) \text{ Accuracy of distraction} = 100 - \% \text{ Error}$$

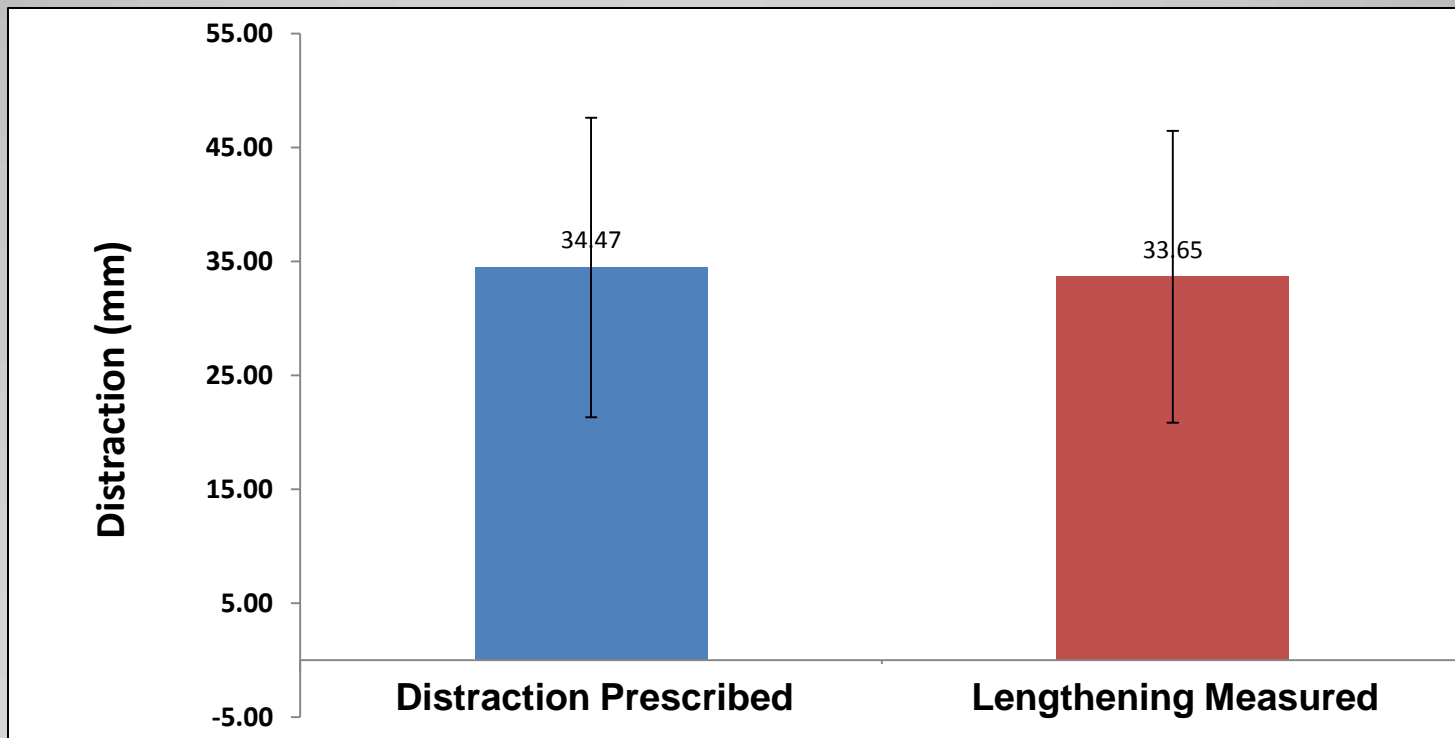
II. Change in bone alignment

III. Effect on adjacent joint ROM

I. Accuracy of Lengthening

At 19 weeks follow-up (range, 1-42 weeks):

- Average lengthening was **33.65 mm** (range, 14mm-61mm)
- Accuracy was **99.3% ± 0.23%**



II. Absolute Change in Bone Alignment

BONE	ANGLE	ABSOLUTE CHANGE (degrees)	
		Mean	Range
Femur	Lateral distal femoral angle (LDFA)	2	0-4
	Procurvatum/Recurvatum	6	0-12
Tibia	Medial proximal tibial angle (MPTA)	3	0-6
	Procurvatum/Recurvatum	3	1-5

- Intentional reduction of femur bow (5/17)
- Blocking screws (4/17 femur & 6/8 tibia)

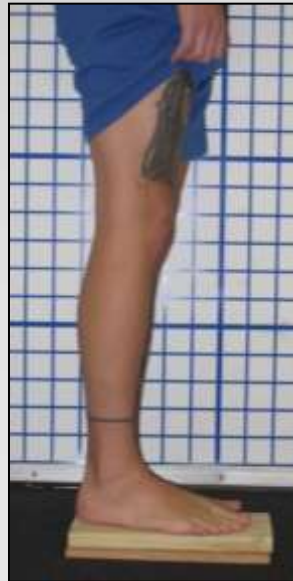
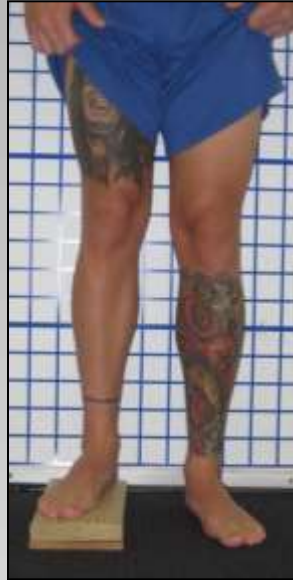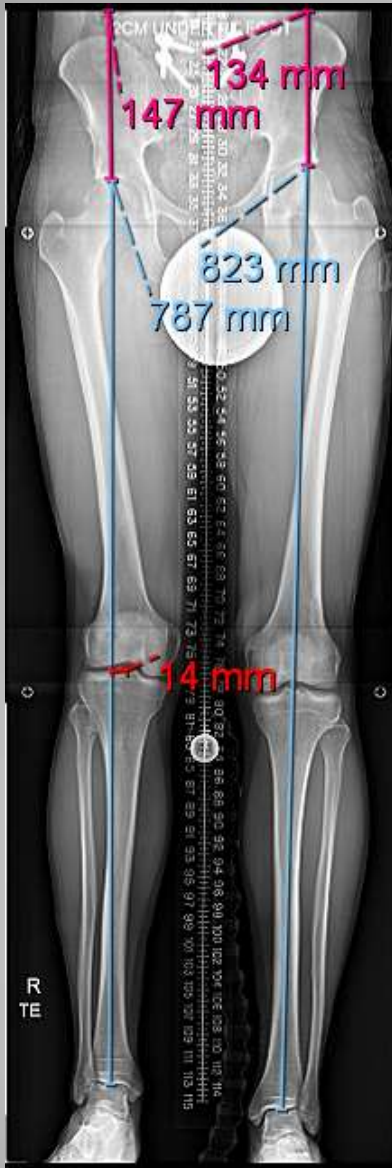III. Joint ROM

- Hip, knee and ankle ROM well maintained
- Temporary loss of motion in early postop period

MOTION	ABSOLUTE LOSS (degrees)	
	Mean	Range
Knee Flexion	13	0-30
Knee Extension	0	0-2
Ankle Dorsiflexion	3	0-15
Ankle Plantarflexion	6	0-20

- ITB release (10/17 femur)
- Gastrocnemius recession (5/8 tibia)

Example : Retrograde Femur

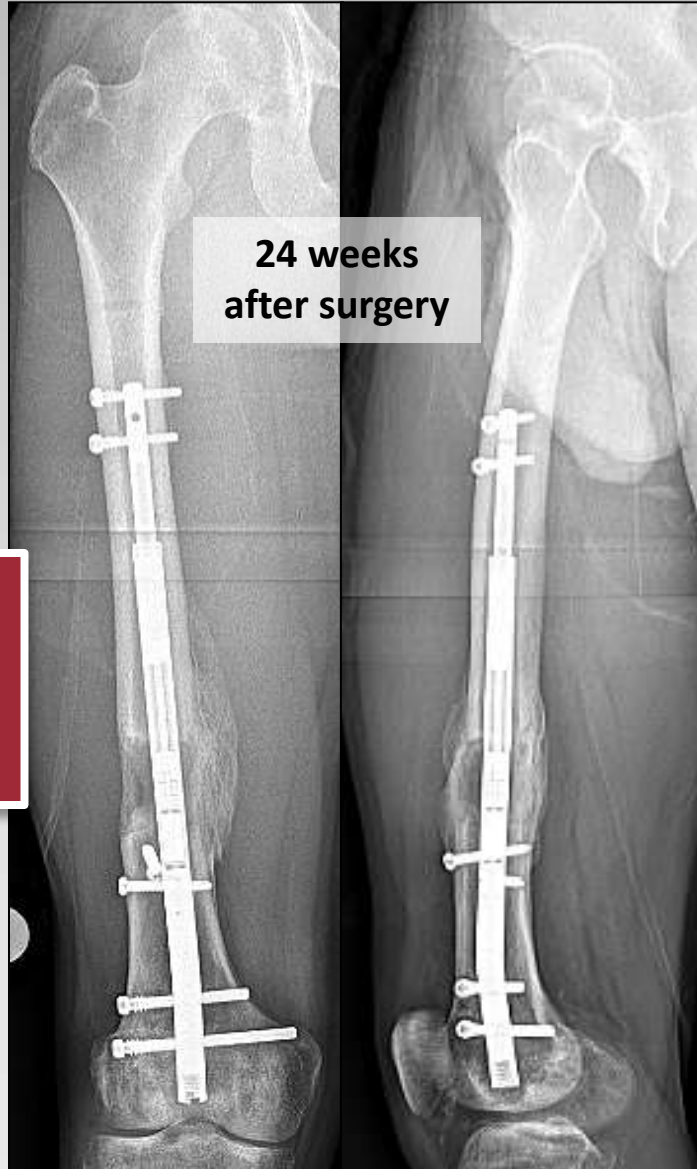

- 30M
- 3.6 cm LLD
- 7° genu valgum (MAD 14 mm lateral)
- 10° ER deformity
- Post-traumatic growth arrest after R femur Fx
- Lower back and R LL pain

Example : Retrograde Femur

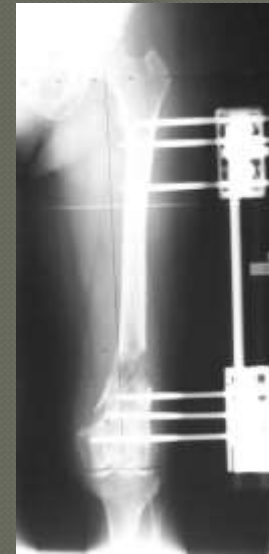
24 weeks
after surgery

- Blocking screws
- To narrow canal
- Placed in concavity of anticipated deformity



Treatment options

- ◉ External Fixation
- ◉ Integrated Fixation
 - LON
 - LATN
 - LAP
- ◉ Internal lengthening nail
 - Piriformis
 - Trochanteric entry
 - retrograde



Thank You



LIMB .COM

www.hss.edu/limblengthening